

İ. Teoman Benli  
Serdar Akalin  
Mahmut Kiş  
Mehmet Çitak  
Burhan Kurtuluş  
Evrin Duman

## The results of anterior fusion and Cotrel-Dubousset-Hopf instrumentation in idiopathic scoliosis

Received: 27 April 1999  
Revised: 13 April 2000  
Accepted: 2 May 2000

**Abstract** Anterior instrumentation for the correction of scoliotic curves has recently been gaining in popularity. The problems of high mortality and morbidity that were associated with the employment of anterior instrumentation in the first years it was used have now been overcome. Efforts are now being concentrated on increasing the correction rates in the frontal plane and decreasing the kyphotic effect in the sagittal plane. The anterior Cotrel-Dubousset-Hopf (CDH) system is a recently developed instrumentation that has been claimed to decrease the kyphotic effect through the use of double rods. This study aimed to investigate the impact of the anterior CDH system on idiopathic scoliotic curves in frontal and sagittal planes. To this end, 26 idiopathic scoliosis patients treated with the CDH system were followed for a mean period of  $32.8 \pm 5.3$  months. In the frontal plane, Cobb angles of major and secondary curves were measured, and postoperative and final correction rates determined. In the sagittal plane, sagittal contours of both the instrumented region and the thoracic and lumbar regions were measured, and their preoperative, postoperative and final control values were determined. In addition to clinical examination, lateral trunk shift (LT), shift of head (SH) and shift of stable vertebra (SS) were measured in vertebral units (VU), on the preoperative and post-

operative radiographs in order to evaluate the effect of the system on trunk balance. It was established that in patients with single flexible thoracolumbar and lumbar curves and those with rigid thoracic curves, the correction rates obtained in the frontal plane were respectively  $79.4 \pm 14.8\%$ ,  $68.0 \pm 9.4\%$  and  $61.5 \pm 8.0\%$ , with statistical significance. Their final corrections at the last control were  $76.3 \pm 17.4\%$ ,  $56.9 \pm 9.1\%$  and  $52.3 \pm 8.3\%$ , respectively. Although the corrections in the lumbar rigid curves were relatively low, they were still statistically significant. Taking all the patients together, the mean preoperative Cobb angle of the major curves of  $67.2^\circ \pm 20.2^\circ$  improved to a mean of  $28.6^\circ \pm 21.0^\circ$ , which was a statistically significant difference ( $P < 0.05$ ), giving a mean correction rate of  $61.2 \pm 20.3\%$ . The mean correction loss of major curves in the frontal plane in all patients was  $6.0^\circ \pm 3.8^\circ$  and the mean final correction rate was  $52.6 \pm 23.2\%$ . In the sagittal plane, there was a favorable kyphotic effect on the thoracic region of patients with hypokyphosis and lordosis pattern, whilst in patients with kyphotic pattern, this effect was minimal. In patients with a single flexible lumbar curve, kyphotic effect was not observed except in two patients. In these two patients, it was thought that excessive compression force may have been used. As to the pa-

İ. T. Benli · S. Akalin · M. Kiş · M. Çitak ·  
B. Kurtuluş · E. Duman  
First Department of Orthopaedics and  
Traumatology,  
Ankara Social Security Hospital,  
Ankara, Turkey  
e-mail: cutku@ada.net.tr,  
Tel.: +90-312-4350914,  
GSM: +90-542-2318292

İ. T. Benli  
Mithatpaşa Cad.,  
59/2, Kızılay,  
Ankara, Turkey 06420

tients with a rigid lumbar curve, there was a slight decrease in lumbar lordosis. No postoperative complaints were made about imbalance, and the mean overall correction in LT values was  $60.1 \pm 21.7\%$ . While preoperatively, the SH and SS values of all patients were over 0.5 VU, postoperatively, 12 patients (46.2%) were completely balanced (SH = 0 VU, SS = 0 VU) and 8 patients (30.8%) were balanced (0 VU < SH

and SS < 0.5 VU). The remaining six patients, whose balance values were corrected with statistical significance but were still over 0.5 VU, were found to be the ones with rigid lumbar curves. Implant failure and systemic complications were not noted in the follow-up period. In view of these findings, it was determined that CDH instrumentation achieves significant correction rates in the frontal and sagittal planes, particularly in

single flexible lumbar, thoracolumbar and thoracic rigid curves. It was found that the kyphotic effect was minimized with a double rod system. Significant clinical and radiological corrections were achieved in balance values, without any imbalance and decompensation problems.

**Key words** Idiopathic scoliosis · Anterior instrumentation · Surgical treatment · Complications

## Introduction

It is a commonly accepted idea that idiopathic scoliosis is a complex deformity with components in three planes, and hence correction is warranted in all of them. Yet, at present, the etiopathogenesis of deformity and the component of the vertebra from which pathology originates is not clear. After the introduction of Harrington systems, "the corner stone" of posterior surgical treatment of spinal deformity, new spinal systems were presented and widely used. From 1984 on, the most widely used and reported method in Europe and the United States were posterior multisegmental hook systems combined with posterior fusion. Among these systems are Cotrel-Dubousset instrumentation (CDI), the Texas Scottish Rite Hospital system (TSRH), Isola, the Universal Spine System (USS), Alici Spinal Instrumentation (ASI), and Moss-Miami instrumentation [1, 4, 15, 21, 22, 30, 35].

In 1964, Dwyer et al. first used anterior spinal instrumentation in the treatment of scoliosis [8]. This system, which consisted of screws and cable, had high pseudoarthrosis rates because it was resistant only to shearing forces biomechanically. Moreover, insufficiency in reconstructing sagittal contours and high morbidity rates have discouraged the employment of this system [12, 17].

It was Zielke et al. who, in 1976, first reported the results of a new anterior system comprised of rod screws [36]. Later, Moe et al., Ogiela and Chan, Kaneda et al., Kostuik et al., and Puno et al. reported correction rates ranging from 63% to 85% [10, 17, 20, 25, 26, 28].

Bridwell et al. in 1990 reported that they had obtained a moderate correction with posterior instrumentation at the hypokyphotic region in the frontal plane [3]. Yet, Lenke et al. and Richards et al. reported that sagittal contours, particularly hypokyphosis, could not be treated by posterior exposure [23, 29]. Ecker et al. and Transfeldt et al. showed in their computed tomography (CT) studies that, especially after the derotation maneuver, the deformity at the apical vertebra is transferred to vertebrae above and below [9, 33]. Coronal decompensation and imbalance problems have also been reported in some posteri-

orly applied systems [32]. Additionally, the "crankshaft phenomenon" is also reported in early surgically treated idiopathic scoliosis patients with posterior fusion [5].

In 1995, Hopf et al. introduced a new anterior instrumentation system, consisting of screws, vertebral implants and rods, that has high biomechanical rigidity and stability [13]. Early results with this system, termed the Cotrel-Dubousset-Hopf (CDH) system, were encouraging. In the present study, surgical results and balance analysis of 26 patients with idiopathic scoliosis treated with CDH instrumentation are evaluated.

## Patients and methods

From April 1995 to July 1997, 26 patients with idiopathic scoliosis were treated with anterior exposure and CDH instrumentation at the First Department of Orthopaedics and Traumatology of Ankara Social Security Hospital. Patients were randomly allocated and care was taken to evenly distribute the patients across the groups. The patients were last seen in July 1999. Mean age was  $15.1 \pm 1.2$ , ranging from 13 to 17. Sixteen were female and ten male.

Preoperatively, besides standing posteroanterior and lateral radiographs, bending and standing traction radiographs were taken lying on right and left sides. In these radiographs, the most rigid curve with the highest rotation at the apical vertebra and wide angle was considered as the major curve and the angles of the curves were measured by the Cobb method. The Cobb angles of the upper and lower secondary curves were also measured with a similar method. On lateral radiographs, sagittal contours between the T2 and T12 and the L1 and L5 vertebrae were measured, again using the Cobb method. Normal thoracic physiological kyphosis and physiological lumbar lordosis were regarded to be between  $30^\circ$  and  $50^\circ$  degrees and between  $-40^\circ$  and  $-60^\circ$ , respectively. All measurements were made in conjunction with radiologists. In the sagittal plane, along with the thoracic and lumbar contours, the preoperative and postoperative local sagittal contours of the instrumented vertebrae were measured. Sagittal contours were given positive (+) and negative (-) angle values if they had kyphotic and lordotic patterns, respectively. In addition, the patients were evaluated with magnetic resonance imaging (MRI) to detect any congenital abnormality.

Patients were assigned to four groups. The first group consisted of patients with a single lumbar flexible major curve (Single major curve pattern – Lumbar flexible curves: SL). The patients in the second and third groups had major curve patterns. The patients in the second group had more rigid and larger curves in the lumbar region (Double major curve pattern – Lumbar rigid curves: DL), and those in the third group had more rigid and larger curves in the

thoracic region (Double major curve pattern – Thoracic rigid curves: DT). As for the fourth group, it included patients with a single thoracolumbar curve (Single major curve pattern – Thoracolumbar flexible curves: ST). In our series, there was no patient with a single flexible thoracic curve, that is, King Moe Type III. There were 7, 6, 6 and 6 patients with SL, DL, DT and ST curves, respectively. The ages of the patients in groups I, II, III and IV were  $15.4 \pm 0.9$  (range 13–17),  $15.8 \pm 0.9$  (range 15–17),  $15.0 \pm 1.7$  (range 13–17) and  $14.3 \pm 0.9$  (range 13–15), respectively.

After clinical and laboratory investigations, all patients were operated in a lateral decubitus position, and thoracotomy was performed at the thoracic region and thoracolumbophrenotomy at the thoracolumbar region. All operations were made by the same team, headed by Dr. Benli. The operation was assisted by two residents.

After excision at the planned number of disc spaces (min. 3, max 6), an anterior release was performed. Prior to operation, it was decided that as well as discs in the proximity of the apex of the curve, discs found to be fixed in bending radiographs, i.e. discs with marked asymmetrical narrowing and those between the vertebrae, were to be released. The number of discs planned for release was related to the angle of rigidity of the curve. The instrumentation area was determined to include upper and lower vertebrae of the spinal segment to be released. At each level of release, after the anterior longitudinal ligament was dissected and fine bone chip was removed from the end plate with a fine chisel, discs were completely excised. In some patients ( $n = 3$ ), in whom release was considered inadequate with manual manipulation, posterior ligament was excised by a punch with a very fine end. Bleeding was not seen in any of these patients. In order to prevent the graft shifting to the spinal channel, tricortical rib grafts were securely fitted into vertebral spaces. In some patients ( $n = 4$ ), one further disc space was released if there was no significant movement with manual traction in the inferior and superior disc spaces. Vertebral arteries at these levels were ligated and implantation areas prepared. First, vertebral implants were placed by two spongy screws, and the (6-mm) rod, bent according to the curve, was inserted into the plates. Derotation maneuver followed compression. The other rod (4 mm) and drawers were placed and locking screws screwed.

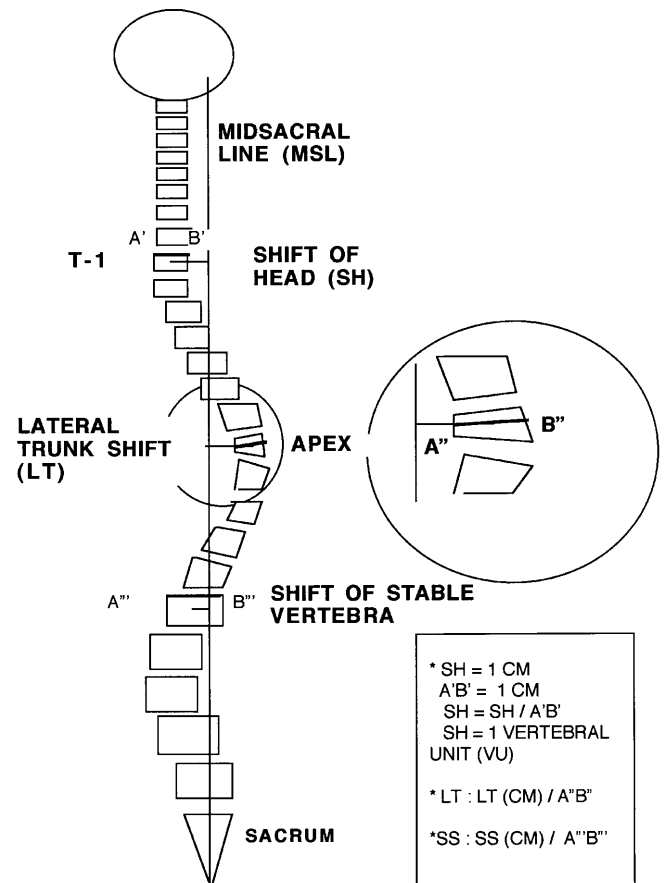
**Technical note:** It is important that rods are bent in accordance with the grooves in the plate. This is a manual skill, which develops only with experience. If it is not done properly, it is almost impossible to place the drawers. Another problem is that drawer holders do not have a firm hold on drawers. This situation requires the placement of drawers into the plates with the help of an impactor. Another difficulty is that, particularly in osteoporotic patients, the plate is derotated in the final tightening. This leads the plate to assume an oblique position in the vertebral corpus, making the placement of the rod more difficult. In order to prevent this, we placed the finest rod in the groove where screw was not inserted, and turned the rod in a counterclockwise direction.

The fusion area included all the disc space initially planned to be released and that released intraoperatively. Autologous grafts consisted of one costa graft removed during thoracotomy and spongy chips removed from iliac crista.

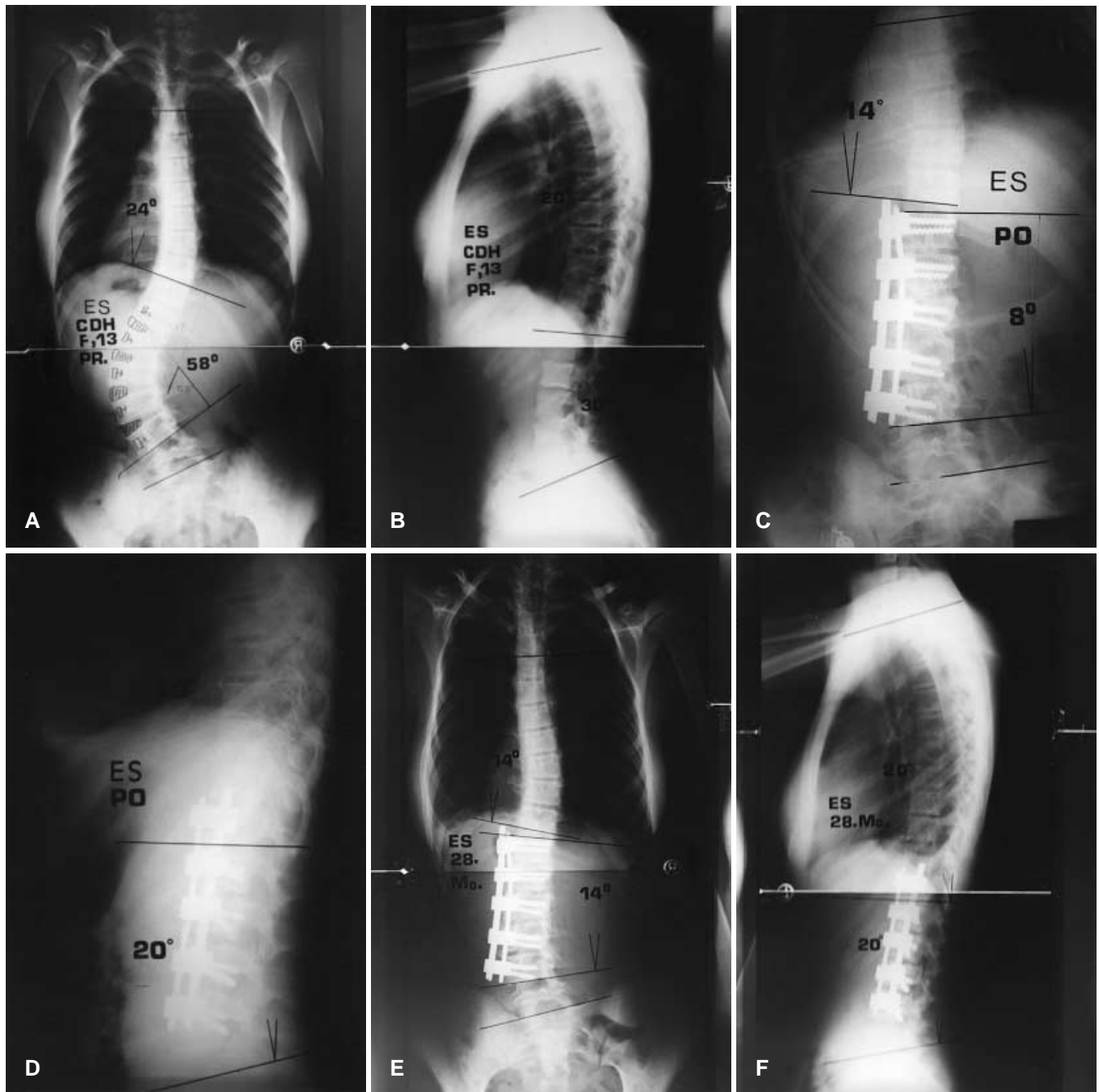
In patients with SL and ST curves, three to four vertebrae were fixed and included in fusion area; in those with DT curves it was five to six vertebrae, and in the ones with DL curves, four or five vertebrae. Thus, the numbers of vertebrae fixed and included in the fusion were less than with posterior instrumentation. Afterwards, anterior instrumentation was performed on a minimum of four, maximum seven, vertebrae using CDH vertebral plates and cancellous screws. Autologous blood transfusion was also performed in all patients. Intraoperatively, the autotransfusion unit saved an average of  $910 \pm 135.2$  cc of blood, and an average of  $1.9 \pm 0.6$  units of saved blood was transfused. None of these patients needed homologous blood transfusion. Hematocrit values decreased by on average  $0.9 \pm 0.6$  mg/dl, albeit the decrease was statistically non-significant ( $P > 0.05$ ). Mean operation time was  $1.6 \pm 0.9$  h. Chest tube or suction drainage was applied and layers were closed.

Patients were turned on their side on the 1st postoperative day, seated on the 2nd day and were allowed to walk after being weaned from chest tube or aspirative drainage. No postoperative cast or other external support was used. Average discharge time was 10 days. Only one patient, with a group 1 curve, had posterior instrumentation at the postoperative 14th day to improve their balance. All patients were called for control at the 1st, 3rd, 6th, 12th, 18th and 24th postoperative months for clinical and radiological evaluation. The thoracolumbar junction angle was also measured, by drawing a line parallel to the upper end plate of T12 and lower end plate of L1. Preoperative and postoperative mean values were compared statistically and correction loss rates noted. Early and late complications were recorded.

Balance analysis of patients was made clinically and radiologically. Shoulder asymmetry and distance between center of gravity determined by a plumb line swinging from C7 and intergluteal crisis was determined. In addition, the subjective complaints of the patients were sought. Additionally, lateral trunk shift (LT), shift of stable vertebra (SS) and shift of head (SH) were recorded preoperatively and postoperatively, with the method described by Benli et al. [2] (Fig. 1). The values measured by this method were divided into the radius of the vertebrae, determining the distance, and values were expressed as vertebral units (VU), not metrically. This was done in order to prevent possible magnifications due to the



**Fig. 1** Radiologic parameters of trunk balance. Lateral trunk shift (LT) is the distance between the midpoint of the apical vertebra and mid-sacral line. Shift of stable vertebra (SS) is the distance between the midpoint of the stable vertebra and mid-sacral line. Shift of head (SH) is the distance between the mid-sacral line and midpoint of seventh cervical vertebra



**Fig. 2 A–F** A 13-year-old female patient (E.S.) with single pattern lumbar curve (SL). Preoperative (A, B), postoperative (C, D) and last visit (E, F) radiographs are shown. The lumbar major curve, which measured  $58^\circ$  preoperatively, reduced to  $8^\circ$  postoperatively, with an 86.2% correction in the frontal plane. The upper secondary curve, which was  $24^\circ$  preoperatively, reduced spontaneously to  $14^\circ$  postoperatively, with 41.7% correction. The preoperative angle of lumbar lordosis, which was  $30^\circ$ , decreased to  $20^\circ$  postoperatively with kyphotic effect by the instrumentation. At the last visit (postoperative 28th month), the loss of correction in the Cobb angle value of the major curve was  $6^\circ$

age of patients and variations in position of patients when taking the radiographs. LT shows to what extent the apex of the curve can be shifted to the middle line, and reflects the correction obtained in frontal plane. If SH and SS values are 0 VU, i.e. if the vertebra is in the middle line, that curve is considered a completely balanced one. If SH and SS are higher than 0 VU but lower than 0.5 VU, there is no clinically recognizable imbalance, and such curves were regarded as clinically balanced. Curves with SH and SS values equal to 0.5 VU or higher were considered to be imbalanced. Preoperative and postoperative data were compared to evaluate the effect of CDH systems on trunk balance.

In a patient who was one of the first patients of our series with a DL curve (S.Y.), there was a mistake in the instrumentation

level. Therefore, it was not possible to perform an adequate anterior release, and correction could not be carried out as the instrumentation was too short (preoperative Cobb angle: 70°, postoperative Cobb angle: 55°). Moreover, as the anterior instrumentation was at a more superior position than it should have been, the spontaneous correction in the thoracic curve was higher than expected, the head of the patient shifted in the direction of the curve and balance values were impaired to a clinically recognizable extent. In order to compensate for this technical error, anterior reoperation was not considered, because of concern that morbidity may increase, and a long posterior instrumentation was planned. On the 14th postoperative day, the necessary explanations were made to the patient and her family, and Texas Scottish Rite Hospital system instrumentation and posterior fusion were carried out. A slight correction was obtained in the value of the curve in the frontal plane, and more importantly, balance values were considerably corrected. After this case, intraoperative radiological level detection was made routinely, and a similar problem was not encountered in any patient.

The statistical evaluation was made using the Difference Between Means For Paired Observations test and the Chi-square test ( $t: 0.05$ ).

**Results**

Frontal and sagittal plane

The Cobb angle values of final preoperative and postoperative frontal and sagittal curves (Fig. 2) and the age, sex,

and follow-up periods of patients are presented in Table 1. Table 2 and Table 3 present preoperative and postoperative mean Cobb angle values, postoperative mean correction rates, and mean correction loss at the last visit in the frontal and sagittal plane for the four curve types. Postoperatively, patients with SL, DL, DT and ST type curves showed a mean correction of the major curve in the frontal plane of  $68.0 \pm 9.4\%$  (range 55.6–86.2%),  $31.7 \pm 7.7\%$  (range 21.4–43.8%),  $61.5 \pm 8.0\%$  (range 50–73.4%), and  $79.4\% \pm 14.8\%$  respectively. Mean postoperative correction values of the Cobb angles were statistically significant ( $P < 0.05$ ). The highest correction was achieved in the patients with a single flexible thoracolumbar curve, followed by patients with single lumbar flexible curve, and those with double pattern thoracic major curve. The lowest correction rate in our series,  $31.7 \pm 7.7\%$ , was attained among patients with a double pattern lumbar major curve. In this group, which had the highest mean Cobb angle of  $88.2^\circ \pm 16.2^\circ$ , such low correction rates were ascribed to the fact that an anterior release was not sufficient in itself, and a posterior release and osteotomy needed to be performed as well. Taking all the patients together, the mean preoperative Cobb angle of the major curves was  $67.2^\circ \pm 20.2^\circ$ , which improved to  $28.6^\circ \pm 21.0^\circ$  (a statis-

**Table 1** Age, sex, follow-up (F-u), types of curve (T thoracic, L lumbar, SL single lumbar, DL double lumbar, DT double thoracic, STL single thoracolumbar), and preoperative (PR), postoperative

(PO) and final correction (FC) values for the Cobb angle of major curves in the frontal plane and the sagittal contour angle (T thoracic, L lumbar) for 26 patients with idiopathic scoliosis

No.	Pt.	Age	Sex	Curve type	F-u (months)	Cobb angle of major curve			Sagittal contour angle					
						PR	PO	FC	PR-T	PO-T	FC-T	PR-L	PO-L	FC-L
1	A.K.	14	F	SL	44	50°	18°	21°	20°	20°	25°	(-48°)	(-25°)	(-20°)
2	T.B.	16	M	SL	44	50°	15°	22°	20°	25°	19°	(-24°)	(-40°)	(-15°)
3	A.B.	16	F	SL	34	45°	20°	24°	30°	36°	40°	(-30°)	(-40°)	(-36°)
4	B.R.	15	M	SL	32	50°	15°	24°	16°	30°	36°	(-20°)	(-40°)	(-36°)
5	U.C.	17	M	SL	31	54°	18°	25°	30°	35°	39°	(-54°)	(-40°)	(-36°)
6	E.S.	13	F	SL	28	58°	8°	14°	10°	15°	29°	(-30°)	(-20°)	(-36°)
7	S.K.	17	F	SL	24	55°	20°	24°	18°	20°	24°	(-30°)	(-40°)	(-36°)
8	S.Y.	15	F	DL	40	70°	55°	66°	20°	20°	25°	(-20°)	(-25°)	(-16°)
9	S.A.	17	F	DL	34	115°	84°	100°	10°	10°	15°	(-20°)	0°	7°
10	K.T.	15	M	DL	33	78°	55°	64°	30°	30°	35°	(-20°)	(-15°)	(-8°)
11	M.Y.	16	F	DL	31	98°	64°	73°	24°	30°	36°	(-26°)	(-15°)	(-10°)
12	Z.A.	17	F	DL	30	88°	58°	65°	10°	12°	16°	0°	(-10°)	(-6°)
13	H.T.	15	M	DL	30	80°	45°	53°	28°	30°	35°	(-38°)	(-40°)	(-35°)
14	K.G.	14	F	DT	39	80°	40°	49°	(-10°)	30°	39°	(-60°)	(-50°)	(-45°)
15	N.T.	14	M	DT	37	99°	42°	48°	74°	50°	56°	(-40°)	(-40°)	(-35°)
16	H.S.	17	M	DT	36	76°	24°	31°	64°	50°	56°	(-40°)	(-40°)	(-36°)
17	D.N.	17	M	DT	36	94°	26°	35°	0°	30°	38°	(-10°)	(-30°)	(-37°)
18	S.S.	15	F	DT	32	74°	28°	37°	(-12°)	30°	36°	(-10°)	(-30°)	(-37°)
19	K.B.	13	F	DT	30	82°	34°	40°	72°	60°	66°	(-30°)	(-30°)	(-37°)
20	E.E.	13	F	STL	40	50°	6°	9°	30°	30°	33°	(-30°)	(-40°)	(-35°)
21	G.F.	15	F	STL	31	50°	24°	29°	30°	30°	33°	(-38°)	(-40°)	(-35°)
22	H.K.	13	F	STL	31	50°	8°	11°	30°	30°	33°	(-10°)	(-30°)	(-36°)
23	G.B.	14	M	STL	30	45°	4°	4°	10°	30°	30°	(-10°)	(-30°)	(-30°)
24	S.M.	15	F	STL	28	60°	20°	20°	24°	30°	30°	(-35°)	(-40°)	(-40°)
25	N.N.	15	M	STL	24	45°	8°	8°	30°	26°	26°	(-30°)	(-40°)	(-40°)
26	O.R.	15	F	STL	24	50°	4°	4°	24°	30°	30°	(-30°)	(-40°)	(-40°)

**Table 2** Preoperative and postoperative main Cobb angles of the major curves and the upper and lower curves of patients with idiopathic scoliosis treated with Cotrel-Dubousset-Hopf (CDH) instrumentation, and their correction percentages and loss of correction values in the frontal plane, according to the type of curve (mean  $\pm$ SD)

Type of curve	Preoperative	Postoperative	<i>t</i>	<i>P</i> -value	Correction (%)	Loss of correction
Single flexible curves – lumbar ( <i>n</i> = 7)						
Instrumented major curve	51.7° $\pm$ 4.3°	16.3° $\pm$ 4.2°	12.55	<0.05	68.0 $\pm$ 9.4	5.7° $\pm$ 2.1°
Upper curve	23.3° $\pm$ 9.8°	15.1° $\pm$ 10.8°	3.47	<0.05	42.0 $\pm$ 30.2	4.7° $\pm$ 1.1°
Lower curve	24.1° $\pm$ 4.9°	10.7° $\pm$ 5.1°	4.08	<0.05	52.9 $\pm$ 24.9	4.9° $\pm$ 0.7°
Double major curve pattern – lumbar rigid curves ( <i>n</i> = 6)						
Instrumented major curve	88.2° $\pm$ 16.2°	60.2° $\pm$ 13.2°	8.96	<0.05	31.7 $\pm$ 7.7	10.0° $\pm$ 3.2°
Upper curve	60.8° $\pm$ 11.8°	53.3° $\pm$ 13.9°	3.51	<0.05	13.3 $\pm$ 10.6	9.0° $\pm$ 2.1°
Lower curve	38.3° $\pm$ 7.5°	32.8° $\pm$ 7.4°	3.26	<0.05	14.1 $\pm$ 10.6	8.7° $\pm$ 1.0°
Double major curve pattern – rigid thoracic curves ( <i>n</i> = 6)						
Instrumented major curve	84.2° $\pm$ 10.1°	32.3° $\pm$ 7.5°	12.99	<0.05	61.5 $\pm$ 8.0	7.7° $\pm$ 1.5°
Upper curve	34.2° $\pm$ 7.7°	21.7° $\pm$ 4.8°	4.29	<0.05	35.0 $\pm$ 15.3	5.5° $\pm$ 1.4°
Lower curve	55.8° $\pm$ 9.9°	28.3° $\pm$ 4.8°	7.92	<0.05	48.8 $\pm$ 8.7	5.5° $\pm$ 1.4°
Single flexible curves – thoracolumbar ( <i>n</i> = 7)						
Instrumented major curve	50.0° $\pm$ 5.0°	10.6° $\pm$ 8.1°	15.83	<0.05	79.4 $\pm$ 14.8	1.6° $\pm$ 2.1°
Upper curve	29.4° $\pm$ 5.9°	13.7° $\pm$ 3.9°	9.79	<0.05	53.2 $\pm$ 9.3	1.9° $\pm$ 2.4°
Lower curve	23.4° $\pm$ 5.3°	10.6° $\pm$ 3.2°	8.18	<0.05	54.7 $\pm$ 10.7	1.7° $\pm$ 2.4°
Total group ( <i>n</i> = 26)						
Instrumented major curve	67.2° $\pm$ 20.2°	28.6° $\pm$ 21.0°	6.58	<0.05	61.2 $\pm$ 20.3	6.0° $\pm$ 3.8°
Upper curve	41.1° $\pm$ 18.8°	26.6° $\pm$ 18.2	10.09	<0.05	40.5 $\pm$ 22.3	5.1° $\pm$ 3.1°
Lower curve	29.5° $\pm$ 8.8°	18.3° $\pm$ 10.5°	4.26	<0.05	40.0 $\pm$ 22.6	5.0° $\pm$ 2.9°

**Table 3** Pre- and postoperative sagittal contour angles of different curve types (mean  $\pm$  SD)

Type of curve	Preoperative	Postoperative	<i>t</i>	<i>P</i> -value	Loss of correction
Single flexible curves – lumbar ( <i>n</i> = 7)					
Thoracic sagittal contours	20.6° $\pm$ 7.3°	25.9° $\pm$ 8.1°	(-3.2)	<0.05	4.4° $\pm$ 0.8°
Lumbar sagittal contours	(-33.7° $\pm$ 12.5°)	(-35.0° $\pm$ 8.7°)	(-1.28)	>0.05	4.3° $\pm$ 2.4°
Instrumented sagittal contours	(-34.1° $\pm$ 11.0°)	(-30.0° $\pm$ 15.0°)	(-0.76)	>0.05	3.7° $\pm$ 0.8°
Double major curve pattern – lumbar rigid curves ( <i>n</i> = 6)					
Thoracic sagittal contours	20.3° $\pm$ 8.7°	22.8° $\pm$ 9.4°	(-1.79)	>0.05	5.0° $\pm$ 0.6°
Lumbar sagittal contours	(-20.7° $\pm$ 12.3°)	(-17.5° $\pm$ 13.7°)	(-0.71)	>0.05	6.2° $\pm$ 1.8°
Instrumented sagittal contours	(-18.5° $\pm$ 14.7°)	(-17.5° $\pm$ 15.4°)	0.26	>0.05	5.2° $\pm$ 1.8°
Double major curve pattern – thoracic rigid curves ( <i>n</i> = 6)					
Thoracic sagittal contours	31.3° $\pm$ 42.7°	41.7° $\pm$ 13.3°	(-0.84)	>0.05	6.8° $\pm$ 1.3°
Lumbar sagittal contours	(-31.7° $\pm$ 19.4°)	(-36.7° $\pm$ 8.2°)	0.99	>0.05	3.8° $\pm$ 0.9°
Instrumented sagittal contours	33.3° $\pm$ 44.1°	43.3° $\pm$ 12.1°	(-0.75)	>0.05	5.8° $\pm$ 1.3°
Single flexible curves – thoracolumbar ( <i>n</i> = 7)					
Thoracic sagittal contours	25.4° $\pm$ 7.4°	29.4° $\pm$ 1.5°	(-1.35)	>0.05	1.3° $\pm$ 1.6°
Lumbar sagittal contours	(-26.1° $\pm$ 11.4°)	(-37.1° $\pm$ 4.9°)	4.22	<0.05	2.0° $\pm$ 2.5°
Instrumented sagittal contours	19.4° $\pm$ 10.8°	8.3° $\pm$ 7.7°	3.34	<0.05	2.1° $\pm$ 2.0°
Total group ( <i>n</i> = 26)					
Thoracic sagittal contours	24.3° $\pm$ 20.6°	29.6° $\pm$ 11.0°	(-1.86)	<0.05	4.3° $\pm$ 2.3°
Lumbar sagittal contours	(-28.2° $\pm$ 14.2°)	(-32.3° $\pm$ 11.6°)	1.69	>0.05	4.0° $\pm$ 2.2°
Instrumented sagittal contours	(-0.04 $\pm$ 35.4°)	0.12° $\pm$ 30.7°	(-0.05)	>0.05	4.1° $\pm$ 2.1°

tically significant difference,  $P < 0.05$ ), giving a mean correction rate of 61.2  $\pm$  20.3%.

In the patients with SL curves, spontaneous improvement was determined in the upper and lower curves, which was also statistically significant ( $P < 0.05$ ). The

second major curve in the thoracic region of patients with DL curves was 60.8°  $\pm$  11.8° preoperatively, with 13.3  $\pm$  10.6% spontaneous correction postoperatively. The lower secondary curve was found to be corrected by 14.1  $\pm$  10.6% postoperatively. Both corrections were statistically

significant ( $P < 0.05$ ). The second major lumbar curve of patients with DT curves, beyond the instrumentation area, had a preoperative mean Cobb angle of  $55.8^\circ \pm 9.9^\circ$ , with  $48.8 \pm 8.7\%$  spontaneous correction postoperatively. In the cervicothoracic curve above the major one,  $35.0 \pm 15.3\%$  correction was obtained postoperatively, with a statistically significant difference ( $P < 0.05$ ). In the upper and lower secondary curves of patients with ST curves, spontaneous correction rates of  $53.2 \pm 9.3\%$  and  $54.7 \pm 10.7\%$  were obtained, respectively. All the above corrections were determined to be statistically significant ( $P < 0.05$ ).

At the last control, correction losses of major curves in the frontal plane of the patients with SL, DL, DT and ST curves were  $5.7^\circ \pm 2.1^\circ$ ,  $10^\circ \pm 3.2^\circ$ ,  $7.7^\circ \pm 1.5^\circ$  and  $1.6^\circ \pm 2.1^\circ$ , with final correction rates of  $56.9 \pm 9.1\%$ ,  $20.3 \pm 10.1\%$ ,  $52.3 \pm 8.3\%$  and  $76.3 \pm 17.4\%$  respectively. However, in all types of curves, the difference between postoperative and final correction rates was statistically non-significant ( $P > 0.05$ ). Overall, the mean correction loss of major curves in the frontal plane in all patients was  $6.0^\circ \pm 3.8^\circ$  and the mean final correction rate was  $52.6 \pm 23.2\%$ .

In the sagittal plane, in the lumbar region where the major curve was found, mean postoperative sagittal contours were brought to  $-35.0^\circ \pm 8.7^\circ$  from  $-33.7^\circ \pm 12.5^\circ$ . In five patients (71.4%), lumbar lordosis within normal limits (between  $-40^\circ$  and  $-60^\circ$ ) was achieved. In the remaining two patients (28.6%), postoperative hypolordosis pattern was present. In this group, while lumbar sagittal contour changed as lordotic effect, kyphotic effect was observed in three patients. With the rotation of prebent rods, the curve in the frontal plane was transferred to the sagittal plane and lumbar lordosis increased in spite of compression. However, in one of the remaining three patients (U.C.), with normal lordosis ( $54^\circ$ ), lordosis decreased, as the rod was less prebent from this angle and compression was applied; yet the lumbar sagittal contour remained within normal limits. As for the other two patients, in spite of the derotation of properly prebent rods, excessive compression was thought to have caused a decrease in lordosis. At the last control, it was found that kyphotic effect remained, albeit slightly, and that there was a  $4.3^\circ \pm 2.4^\circ$  correction loss in lumbar lordosis.

The sagittal contours of the patients with DL curves in the lumbar region where the major curve was instrumented were corrected postoperatively to  $-17.5^\circ \pm 13.7^\circ$  from  $-20.7^\circ \pm 12.3^\circ$  preoperatively, with a decrease in lordosis. In this group, kyphotic effect was seen and postoperative hypolordosis pattern developed in all patients due to the fact that preoperative curve values were high, and that the curve in the frontal plane could not be transferred completely to the sagittal one by derotation maneuver. It was found that the local sagittal contour angle of the instrumented vertebrae was reduced from a mean of  $-18.5^\circ \pm 14.7^\circ$  to  $-17.5^\circ \pm 14.8^\circ$ . It was also determined that the preoperative mean sagittal contour in the thoracic region remaining beyond the instrumented area was corrected from  $20.3^\circ \pm 8.7^\circ$  to

$22.8^\circ \pm 9.4^\circ$ . While only one patient (16.7%) had normal physiological thoracic kyphosis ( $30^\circ$ – $50^\circ$ ) preoperatively, three patients (50%) did so postoperatively.

Preoperative sagittal contours of the patients with DT curves in the thoracic region were changed from a mean of  $31.3^\circ \pm 42.7^\circ$  (range  $-12^\circ$  to  $70^\circ$ ) to  $41.7^\circ \pm 13.3^\circ$  postoperatively (Table 3). Prior to operation, three patients had lordotic and three patients hyperkyphotic thoracic sagittal pattern. In all three patients with lordotic pattern, normal physiological thoracic kyphosis was achieved postoperatively ( $30^\circ$ – $50^\circ$ ). On the other hand, in hyperkyphotic patients, this effect increased thoracic kyphosis angles slightly. Local sagittal contours of the instrumented vertebrae were brought from a mean of  $33.3^\circ \pm 44.1^\circ$  to  $43.3^\circ \pm 12.1^\circ$  postoperatively, with an increase in kyphosis. In the lumbar region beyond the instrumentation area, sagittal contours were reduced to  $-36.7^\circ \pm 8.2^\circ$  from  $-31.7^\circ \pm 19.4^\circ$ .

Sagittal contours of the patients with ST curves in the instrumented thoracolumbar region were reduced from  $19.4^\circ \pm 10.8^\circ$  to  $8.3^\circ \pm 7.7^\circ$  postoperatively (Table 3), with a statistically significant difference ( $P < 0.05$ ). All patients had kyphotic pattern ( $10^\circ$ – $34^\circ$ ) at the thoracolumbar junction, and the junction angle was reduced to  $0^\circ$  in two patients (28.8%) and to under  $10^\circ$  in two patients (28.6%). Preoperative sagittal contours of the thoracic and lumbar regions above and below the instrumentation area were  $25.4^\circ \pm 7.4^\circ$  and  $-26.1^\circ \pm 11.4^\circ$ , respectively, and they were changed to  $29.4^\circ \pm 1.5^\circ$  and  $-37.1^\circ \pm 4.9^\circ$  postoperatively. It was determined that while the corrections obtained at the thoracic region were not statistically significant ( $P > 0.05$ ), those obtained at the lumbar region were so ( $P < 0.05$ ). Nevertheless, three patients (42.8%) had normal physiological kyphosis ( $30^\circ$ – $50^\circ$ ) at the thoracic region preoperatively, whilst five patients (71.4%) reached normal limits postoperatively. Besides, none of the patients had normal physiological lumbar lordosis (between  $-40^\circ$  and  $-60^\circ$ ) preoperatively, whereas five patients (71.4%) did so postoperatively.

Overall, the mean preoperative sagittal contour of  $24.3^\circ \pm 20.6^\circ$  at the thoracic region and  $-28.2^\circ \pm 14.2^\circ$  at the lumbar region were changed postoperatively to  $29.6^\circ \pm 11.0^\circ$  and  $-32.3^\circ \pm 11.6^\circ$ , respectively, which is statistically significant ( $P < 0.05$ ) (Table 3). Thus, whilst seven patients (26.9%) had normal thoracic kyphosis within physiological limits ( $30^\circ$ – $50^\circ$ ) preoperatively, after the operation 17 patients (65.4%) did so. In addition, while five patients (19.2%) had normal physiological lumbar lordosis (between  $-40^\circ$  and  $-60^\circ$ ) before the operation, the number of the patients with normal physiological lumbar lordosis reached 14 (53.8%) postoperatively.

#### Analysis of trunk balance

Clinically, it was determined that shoulder asymmetry decreased in almost all of the patients, and no patient re-

**Table 4** Preoperative and postoperative trunk balance of patients treated with CDH, according to different types of curve values, presented as mean  $\pm$  SD in vertebral units

Type of curve	Preoperative trunk	Postoperative	<i>t</i>	<i>P</i> -value	Loss of correction
Single curves – lumbar ( <i>n</i> = 7)					
Lateral trunk shift (LT)	1.2 $\pm$ 0.5 (0.8–2.0)	0.3 $\pm$ 0.2	6.33	<0.05	0.26 $\pm$ 0.11
Shift of stable vertebra (SS)	0.7 $\pm$ 0.3 (0.5–1.0)	0.1 $\pm$ 0.3	5.97	<0.05	0.16 $\pm$ 0.08
Shift of head (SH)	0.6 $\pm$ 0.2 (0.5–1.3)	0.1 $\pm$ 0.1	11.23	<0.05	0.16 $\pm$ 0.08
Double curve pattern – lumbar major ( <i>n</i> = 6):					
Lateral trunk shift (LT)	3.8 $\pm$ 1.0 (2.5–5.4)	2.7 $\pm$ 0.8	7.11	<0.05	0.55 $\pm$ 0.15
Shift of stable vertebra (SS)	2.0 $\pm$ 0.3 (1.5–2.2)	1.1 $\pm$ 0.3	5.67	<0.05	0.40 $\pm$ 0.09
Shift of head (SH)	2.2 $\pm$ 0.7 (1.5–3.5)	0.9 $\pm$ 0.2	4.26	<0.05	0.40 $\pm$ 0.09
Double curve pattern – major thoracic ( <i>n</i> = 6):					
Lateral trunk shift (LT)	2.9 $\pm$ 0.5 (2.4–3.7)	1.3 $\pm$ 0.8	7.59	<0.05	0.50 $\pm$ 0.15
Shift of stable vertebra (SS)	1.5 $\pm$ 0.5 (1.0–2.4)	0.5 $\pm$ 0.5	7.72	<0.05	0.20 $\pm$ 0.13
Shift of head (SH)	1.4 $\pm$ 0.6 (1.0–2.4)	0.3 $\pm$ 0.2	5.07	<0.05	0.23 $\pm$ 0.15
Single curves – thoracolumbar ( <i>n</i> = 7)					
Lateral trunk shift (LT)	1.5 $\pm$ 0.3 (1.0–2.0)	0.4 $\pm$ 0.3	7.51	<0.05	0.12 $\pm$ 0.14
Shift of stable vertebra (SS)	0.7 $\pm$ 0.2 (0.5–1.1)	0.1 $\pm$ 0.1	5.94	<0.05	0.04 $\pm$ 0.05
Shift of head (SH)	0.6 $\pm$ 0.1 (0.5–0.9)	0.1 $\pm$ 0.1	7.17	<0.05	0.04 $\pm$ 0.05
Total group ( <i>n</i> = 26)					
Lateral trunk shift (LT)	2.2 $\pm$ 1.2 (0.9–5.4)	1.1 $\pm$ 1.1	12.28	<0.05	0.35 $\pm$ 0.22
Shift of stable vertebra (SS)	1.2 $\pm$ 0.6 (0.5–2.4)	0.4 $\pm$ 0.5	10.98	<0.05	0.19 $\pm$ 0.16
Shift of head (SH)	1.1 $\pm$ 0.8 (0.5–2.4)	0.3 $\pm$ 0.4	7.83	<0.05	0.20 $\pm$ 0.16

ported any further complaint on this matter. The distance between center of weight and intergluteal crisis was preoperatively 2.7  $\pm$  1.4 cm, decreasing to 0.8  $\pm$  0.6 cm postoperatively ( $P < 0.05$ ).

Preoperative and postoperative radiological balance analysis values and correction losses are presented in Table 4. The values for preoperative SH and SS are over 0.5 VU in all patients, indicating a deterioration in trunk balance. In all curve types, LT, SS, and SH values were found to be corrected postoperatively, with statistical significance ( $P < 0.05$ ). In other words, the apex of the curves, the head and the stable vertebrae were all pulled towards the mid-line, to a significant extent. Of the patients with an SL curve, postoperative balance was completely achieved in five (71.4%) (SH: 0 VU, SS: 0 VU) and a balanced curve was achieved in two (28.6%) (0 VU < SH and SS < 0.5). In the patients with ST, the results were comparable (five patients with complete balance, two patients balanced). Of the patients with DT curves, two patients (33.3%) were observed to have achieved complete balance, and four (66.7%) had balanced curves. In none of the patients with DL curves was complete balance or a balanced curve obtained; however, there was a statistically significant correction. Overall, 20 patients (76.9%) were found to have complete balance or balanced curves. In the remaining six patients, statistically significant correction was obtained in balance values.

#### Follow-up and complications

Implant failure, neurological deficit and systemic complications did not ensue. Radiological views of marked consolidation between the disc spaces suggested fusion development, and findings such as lack of a pronounced correction loss (<10°) and pain also supported this. In our series, only two patients had more than 10° of correction loss (11° and 16°). However, over the 2-year follow-up, these patients reported no pain and suffered no implant failure or further progression of the correction loss, and showed evidence of significant radiologic consolidation; we also considered that these patients did not have pseudoarthrosis. Solid fusion mass was obtained among the patients followed for at least 2 years.

#### Discussion

The opinion that scoliotic deformity arises from the anterior vertebral column leads orthopedic surgeons to correct this deformity anteriorly by anterior fusion and instrumentation. The surgical correction of this deformity with anterior instrumentation was first made by Dwyer and co-workers in 1964 [8]. The system of screws and cables was insufficient to resist the biomechanically applied compressive forces, and it lost favor following reports of high rates of pseudoarthrosis and implant failure. However, in the late 1970s, the Zielke Ventrale Derotation – Spondylosis (VDS) system was introduced – a modification of



the Dwyer system, which had increased rigidity thanks to employment of rods instead of cables, enabling high correction rates. Reports published on experience with the Zielke system aroused renewed interest in anterior instrumentation [10, 12, 17, 36].

Dwyer and Schafer reported that they had obtained 70% and 58% correction of idiopathic thoracolumbar curves and double major curves, respectively, in their series of 51 cases [7]. Later, Dwyer reported higher correction rates in his study including more than 100 patients. Zielke et al. reported 77% and 92% correction rates with the VDS system for thoracolumbar and lumbar curves, respectively [36]. Moe, et al. reported that they had obtained 95% and 62% correction for single pattern and double curves, respectively, among 66 scoliotic patients treated with VDS instrumentation [25]. Hammerberg et al. reported correction rates as high as 80% [11]. Giehl and Zielke, in 1997, reported 70% correction in the frontal plane in over 1000 patients, with a follow-up of 5–12 years [10]. Turi et al. reported an initial 43% correction for thoracic curves, which improved spontaneously to an 82% correction at follow-up in scoliotic patients treated with anterior TSRH instrumentation [34]. Kaneda et al., in 1997, reported a 71% correction for thoracic curves, 32% for upper thoracic curves and 69% for lumbar curves with anterior treatment of scoliotic patients, using a system they had developed originally to correct vertebra fractures [16, 18,]. In our study with CDH instrumentation, the initial results of which were published by Hopf [13, 14], including 26 idiopathic scoliotic patients, with 2-years follow-up, the mean preoperative Cobb angle of  $67.2^\circ \pm 20.2^\circ$  was changed to  $61.2^\circ \pm 20.3^\circ$ , when all the patients were included. It was determined that the highest correction, which was  $79.4 \pm 14.8\%$ , was obtained for single pattern thoracolumbar curves, followed by patients with a single pattern flexible lumbar curve at a correction rate of  $68.0 \pm 9.4\%$ . There was a  $61.5 \pm 8.0\%$  postoperative correction in patients with DT curves and  $31.7 \pm 7.7\%$  postoperative correction in those with DL curves. The comparatively lower rates in patients with a double curve pattern and with more rigid preoperative curves were attributed to the fact that, while there had been an adequate anterior release, posterior release and osteotomy had not been performed. The obtained correction rates were statistically significant ( $P < 0.05$ ), and consistent with the reported findings in the literature.

The correction loss in the frontal plane with VDS reported by Kohler et al., Luk et al. and Suk et al. was  $7^\circ$ ,  $12^\circ$  and  $5^\circ$ , respectively [19, 24, 31]. This loss was  $5^\circ$  with the TSRH system and  $1.5^\circ$  with the Kaneda system [16, 34]. In the present study, when all the patients were included, a correction loss of  $6.0^\circ \pm 3.8^\circ$  was seen in the frontal plane. The highest mean correction loss,  $10.0^\circ \pm 3.2^\circ$ , was seen in patients with DL curves.. Otani et al. reported that, after a minimum of 10 years of follow-up, they found final corrections of 61% and 65% with Dwyer

instrumentation and Zielke instrumentation, respectively [27]. Luk and colleagues reported a 79% correction at the last control with Zielke instrumentation [24]. All their patients had flexible thoracolumbar curves. In the present study, patients with ST curves showed a  $76.3 \pm 17.3\%$  correction at the final control. In addition, patients with SL and DT curves showed respective final corrections of  $56.9 \pm 9.1\%$  and  $52.3 \pm 8.3\%$ . Final correction rates were found to be congruent with those reported in the literature. The reason why correction rates were relatively low in our study may be our lack of experience with this system. Harms et al., in their review of the indications for anterior instrumentation, stated that it should not be employed in rigid curves of over  $75^\circ$ , and its correction rates were low when used by itself [12]. In our study, in patients with DL curves, almost all of which are over  $75^\circ$ , there were lower rates of postoperative correction, higher losses of correction and lower final correction rates.

In our study, both upper and lower secondary curves improved spontaneously, with a statistically significant difference in all groups. In patients with a lumbar single curve pattern and in those with a thoracolumbar single curve pattern, respective correction rates of  $52.9 \pm 24.9\%$  and  $54.7 \pm 10.7\%$  were achieved at the lower secondary curves and  $42.2 \pm 30.2\%$  and  $53.2 \pm 9.3\%$  at the upper secondary curves. In addition, spontaneous corrections of  $35.0 \pm 15.3\%$  and  $48.8 \pm 8.7\%$  took place at the upper cervicothoracic curve and lower lumbar curve, respectively, in patients with a rigid thoracic curve, double curve pattern. On the other hand, in patients with a rigid lumbar, double major curve pattern, the upper and lower curves showed improvements of  $13.3 \pm 10.6\%$  and  $14.1 \pm 10.6\%$ , respectively. This was ascribed to the fact that lower correction rates tend to be obtained at major lumbar curves instrumented with derotation and compression compared to other curve patterns. Puno et al. reported a deterioration in secondary curves postoperatively [28]. At lower and upper curves, correction losses of  $5.1^\circ \pm 3.1^\circ$  and  $5.0^\circ \pm 2.9^\circ$ , respectively, were determined, which is correlated with loss of correction of secondary major curves beyond the instrumentation region.

One of the most important problems encountered in anterior instrumentation is that the instrumented site has a kyphotic effect on the sagittal plane, as a result of the compression applied on convex side [10, 14, 27]. Kohler et al. reported that VDS instrumentation produced a mean kyphotic effect of  $21^\circ$  [19]. Kaneda et al. noted that, although the same instrumentation produced a mean kyphotic effect of  $21^\circ$ , this decreased in the follow-up. Moe et al. claimed that this effect could be lessened with anterior wedged graft instrumentation described by themselves [25]. Turi et al. reported that this difficulty encountered with the VDS system could be overcome by using rigid rods, as with the TSRH system [34]. Hopf et al. reported that, as CDH employed rigid rods and formed a strong framework with double rods and plates, the kyphotic

effect was minimal [13, 14]. In our study, of seven patients with SL curves, normal lumbar lordosis (between  $-40^\circ$  and  $-60^\circ$ ) was achieved in five. In the remaining two patients, hypolordosis pattern was found (under  $-40^\circ$ ). Kyphotic effect resulting from compression, through the transfer of the curve in the frontal plane to the sagittal plane by derotation of the prebent rod, was not observed in four patients, and lordosis within normal limits was achieved. In one patient, irrespective of kyphotic effect, postoperative lumbar sagittal contours remained within normal limits. In the remaining two patients, the presence of hypolordosis in spite of derotation was put down to excessive compression. Therefore, excessive compression must strictly be avoided in the lumbar region. As the prebent rod could not be rotated adequately in DL patients, the correction rates were low in the sagittal plane, causing the kyphotic effect after compression to be more pronounced, with patients having hypolordosis pattern. In the patients with ST, kyphosis pattern in the thoracolumbar junction was corrected in all, with statistical significance ( $P < 0.05$ ). In patients with DT curves, where there was a preoperative hypokyphosis or lordosis pattern, the kyphotic effect brought about by the derotation of the prebent rod and transfer of the curve in frontal plane to the sagittal plane and also compression maneuver helped restoration of normal sagittal contours. In patients with hyperkyphosis, kyphotic effect was found to be minimal. In overall evaluation, there was a slight, but not statistically significant, difference in the sagittal contours of the instrumented vertebrae, tending to produce kyphosis.

The main drawback of posterior multi-segmental systems is decompensation and imbalance problems arising through the transfer of derotation effect to other stable segments. Thompson et al. encountered more imbalance problems than Richards et al. did, particularly in types II and III curves [29, 32]. Benli et al., drawing on their study with CDI, suggested decompensation and imbalance problems would be lowered if reverse hook pattern was used in type III curves and if lumbar curves are also included in the instrumented area when the secondary curve is over  $30^\circ$  in type II curves. They also reported particular difficulty in correcting thoracolumbar junction kyphosis in type IV patients with posterior instrumentation [2]. Kaneda et al. suggested being cautious in type II curves, as they observed decompensation in one patient [18]. Suk et al. noted that two patients instrumented with VDS and three patients treated with CD developed decompensation, and two patients instrumented with VDS and decompensation were treated with posterior CDI [31]. In our study, the shift of center of gravity decreased to 0.7 cm clinically, and the complaints of virtually all patients about balance stopped. In the radiological examination, it was determined that 71.4% of patients with single flexible lumbar and thoracolumbar curves had completely balanced curves. Together with these groups, 100% complete

balance or balanced curves were obtained in all patients with DT. The impairment in balance values of patients with DL curves remained postoperatively, in spite of a statistically significant correction ( $P < 0.05$ ). Overall, statistically significant improvement was found in LT, SS and SH values ( $P < 0.05$ ).

Giehl and Zielke reported an 11.6% rate of implant failure with VDS [10]. Moe et al. noted 8% of rod breakage with this system [25], whilst Turi et al. and Kaneda et al. reported no implant failure with the TSRH and Kaneda systems, respectively [16, 34]. Hopf et al. reported one screw breakage in their series [13]. We did not observe an implant failure or pseudoarthrosis with CDH application in our series. Neither were there any neurological or systemic early or late complications.

Even though CDH was a new system, it was possible for us to adapt to it. The advantages of the system are that it produces a rigid frame and drawers allow derotation when they are slightly squeezed. Nonetheless, our personal experience suggests that the system has some defects, the most important of which is the difficulties involved in the implantation technique. When the rods are not bent appropriately toward the plates, it is almost impossible for the drawers to be closed. For this reason, we believe that the system still needs to be improved.

---

## Conclusion

In patients with a single flexible curve in the lumbar and thoracolumbar regions, high correction rates were obtained in the frontal plane with CDH. Final correction rates were comparable to postoperative correction rates, with low correction losses at follow-up. In the lumbar region, the kyphotic effect due to compression by the anterior instrumentation, which leads to a decrease in lumbar lordosis, can be minimized by double rigid rods. The transfer of frontal curves by derotation to the sagittal plane by prebent rods yields successful results in achieving lumbar lordosis, particularly in flexible lumbar curves. It is thought that the kyphotic effect becomes pronounced only when compression is excessive. In the thoracic region, in patients with preoperative lordosis or hypokyphosis pattern, kyphotic effect is favorable for sagittal contours. For patients, with kyphosis pattern in thoracic region, kyphotic effect becomes minimal with CDH application. In all curve types, statistically significant correction was obtained for all balance values. In patients with a rigid thoracic curve or flexible lumbar and thoracolumbar single curves, CDH was able to achieve a complete balance or balanced curve. It is our conclusion, in selected idiopathic scoliosis cases, that curves can be corrected at satisfactory rates in the frontal and sagittal planes and substantial improvement can be made in the balance of the body with CDH.

## References

1. Asher MA (1997) Isola spinal instrumentation system for scoliosis. In: Bridwell KH, DeWald RI (eds) *The textbook of spinal surgery*, 2nd edn. Lippincott-Raven, Philadelphia, pp569–609
2. Benli İT, Tüzüner M, Akalın S, Kış M, Aydın E, Tandoğan R (1996). Spinal imbalance and decompensation problems in patients treated with Cotrel-Dubousset instrumentation. *Eur Spine J* 5: 380–386
3. Bridwell KH, McAllister JW, Betz RR, Huss G, Clancy M, Schoenecker PL (1991) Coronal decompensation produced by Cotrel-Dubousset “derotation” maneuver for idiopathic right thoracic scoliosis. *Spine* 16:769–777
4. Dubousset J, Cotrel Y (1991) Application technique of Cotrel-Dubousset instrumentation for scoliosis deformities. *Clin Orthop* 264:103–110
5. Dubousset J, Herring JA, Shuffelbarger HL (1989) The crankshaft phenomenon. *J Pediatr Orthop* 9:541–550
6. Dwyer AF (1973) Experiences of anterior correction of scoliosis. *Clin Orthop* 93:191–214
7. Dwyer AF, Schafer MF (1974) Anterior approach to scoliosis. Results of treatment in 51 cases. *J Bone Joint Surg Br* 56:218–224
8. Dwyer AF, Newton NC, Sherwood AA (1969) An anterior approach to scoliosis: a preliminary report. *Clin Orthop* 62: 192–202
9. Ecker ML, Betz RR, Trent PS, Mahboubi S, Mesgorzadeh M, Bonakdarpour A, Drummond DS, Clancy M (1988) Computer tomography evaluation of Cotrel-Dubousset instrumentation in idiopathic scoliosis. *Spine* 13: 1141–1144
10. Giehl JP, Zielke K (1997) Anterior Zielke instrumentation in thoracolumbar and lumbar cases. In: Bridwell KH, DeWald RI (eds) *The textbook of spinal surgery*. Lippincott-Raven, Philadelphia, pp627–639
11. Hammerberg KW, Rodts MF, DeWald RL (1988) Zielke instrumentation. *Orthopaedics* 11: 1365–1371
12. Harms J, Jeszensky D, Beele B (1997) Ventral correction of thoracic scoliosis. In Bridwell KH, DeWald RI (eds) *The textbook of spinal surgery*. Lippincott-Raven, Philadelphia, pp611–625
13. Hopf C, Eysel P, Dubousset J (1995) CDH: Preliminary report on new anterior spinal instrumentation. *Eur Spine J* 4:194–199
14. Hopf C, Eysel P, Dubousset J (1997) Operative treatment of scoliosis with Cotrel-Dubousset-Hopf instrumentation. *Spine* 22:618–628
15. Johnston CE, Ashman RB, Richards BS, Herring JA (1997) TSRH Universal Spine Instrumentation. In: Bridwell KH, DeWald RI (eds) *The textbook of spinal surgery*. Lippincott-Raven, Philadelphia, pp535–567
16. Kaneda K, Shono Y (1997) Kaneda anterior multisegmental instrumentation – two-rod system for the treatment of thoracolumbar and lumbar scoliotic curvatures. In: Bridwell KH, DeWald RI (eds) *The textbook of spinal surgery*. Lippincott-Raven, Philadelphia, pp641–664
17. Kaneda K, Fujiya N, Satoh S (1986) Results of Zielke instrumentation for idiopathic thoracolumbar and lumbar scoliosis. *Clin Orthop* 205:195–203
18. Kaneda K, Shono Y, Satch S, Abumi K (1997) Anterior correction of thoracic scoliosis with Kaneda Anterior Spinal System. A preliminary report. *Spine* 22:1358–1368
19. Kohler R, Galland OD, Mechin H, Michel CR, Onimus M (1990) The Dwyer procedure in the treatment of idiopathic scoliosis. A 10-year follow-up review of 21 patients. *Spine* 15: 75–80
20. Kostuik JP, Carl A, Ferron S (1989) Anterior Zielke instrumentation for spinal deformity in adults. *J Bone Joint Surg Am* 71:898–912
21. LaGrone MO, King HA (1997) Idiopathic adolescent scoliosis. In: Bridwell KH, DeWald RI (eds) *The textbook of spinal surgery*. Lippincott-Raven, Philadelphia, pp 425–449
22. Laxer E (1994) A further development in spinal instrumentation. Technical Commission for Spinal Surgery of the ASIF. *Eur Spine J* 3:347–252
23. Lenke LG, Bridwell KH, Baldisc C (1992) Cotrel-Dubousset instrumentation for adolescent idiopathic scoliosis. *J Bone Joint Surg Am* 74:1056–1067
24. Luk KD, Leong JC, Reyes L, Hsu LC (1989) The comparative results of treatment in idiopathic thoracolumbar and lumbar scoliosis using Harrington, Dwyer and Zielke instrumentation. *Spine* 14:275–280
25. Moe JH, Purcell GA, Bradford DS (1983) Zielke instrumentation (VDS) for the correction of spinal curvature. Analysis of results in 66 patients. *Clin Orthop* 180:133–153
26. Ogiela DM, Chan DP (1986) Ventral derotation spondylodesis. A review of 22 cases. *Spine* 11:18–22
27. Otani K, Saito M, Sibasaki K (1997) Anterior instrumentation in idiopathic scoliosis: a minimum follow-up of 10 years. *Int Orthop* 21:4–8
28. Puno RM, Johnson JR, Osterman PAW, Holt RT (1989). Analysis of the primary and compensatory curvatures following Zielke instrumentation for idiopathic scoliosis. *Spine* 14:738–743
29. Richards BS, Birch JG, Herring JA, Johnston CE, Roach JW (1989) Frontal plane and sagittal plane balance following Cotrel-Dubousset instrumentation for adolescent idiopathic scoliosis. *Spine* 14:733–737
30. Richards BS, Herring BA, Johnston CE, Birch JG, Roach JW (1994) Treatment of adolescent idiopathic scoliosis using Texas Scottish Rite Hospital instrumentation. *Spine* 19: 1598–1605
31. Suk SI, Lee CK, Chung SS (1994) Comparison of Zielke ventral derotation system and Cotrel-Dubousset instrumentation in the treatment of idiopathic lumbar and thoracolumbar scoliosis. *Spine* 19: 419–429
32. Thompson JP, Transfeldt EE, Bradford DS, Ogilvie JW, Boachie-Adjei O (1990) Decompensation after Cotrel-Dubousset instrumentation for idiopathic scoliosis. *Spine* 15: 927–931
33. Transfeldt E, Thompson J, Bradford DS (1989) Three dimensional changes in the spine following Cotrel-Dubousset instrumentation for idiopathic scoliosis. In: *Proceedings of the Sixth International Congress on Cotrel-Dubousset Instrumentation*, Sauramps Medical, Montpellier, pp: 73–80
34. Turi M, Johnston CE, Richards BS (1993) Anterior correction of idiopathic scoliosis using TSRH instrumentation. *Spine* 18:417–422
35. Webb JK, Burwell RG, Cole AA, Lieberman I (1995) Posterior instrumentation in scoliosis. *Eur Spine J* 4: 2–5
36. Zielke K, Stunkat R, Beaujean F (1976) Ventrale Derotations-spondylodese. *Arch Orthop Unfallchir* 85: 257–277