

M. Kramer
P. Katzmaier
R. Eisele
V. Ebert
L. Kinzl
E. Hartwig

Surface electromyography-verified muscular damage associated with the open dorsal approach to the lumbar spine

Received: 20 July 2000
Revised: 14 April 2001
Accepted: 17 April 2001
Published online: 13 June 2001
© Springer-Verlag 2001

M. Kramer (✉) · P. Katzmaier · R. Eisele
V. Ebert · L. Kinzl · E. Hartwig
Department of Trauma Surgery,
Hand and Reconstructive Surgery,
University of Ulm,
Steinhoevelstrasse 9,
89075 Ulm, Germany
e-mail:
michael.kramer@medizin.uni-ulm.de,
Tel.: +49-731-7130606,
Fax: +49-731-553100

Abstract The dorsal approach is increasingly preferred in the surgical treatment of vertebral fractures. However, the access and the implant's position cause muscle loss, which can lead to instability and a reduced capacity for rehabilitation. Morphological factors (bones, intervertebral discs) are typically blamed for chronic pain syndromes in the literature, while less importance is attached to functional factors (muscles). The objective of this study was therefore to investigate the isolated influence of dorsal spinal instrumentation on the back muscles by means of electromyography (EMG). A total of 32 patients with conditions after dorsal spondylodesis following the fracture of a vertebral body and 32 subjects with healthy backs were enrolled in this study. The EMG signal was recorded in three different muscle groups during isometric extension exercise. The evaluation was

performed by comparing the mean rectified amplitudes of the three muscle groups in the patients and controls. The patients had significantly lower amplitudes in the multifidus muscle (MF) and significantly higher amplitudes in the iliocostal muscle (IL). Patients with severe pain were found to have lower electric muscle potentials in all investigated muscle groups than patients with mild pain. The muscle damage which was established in the multifidus muscle is compensated by increased activity in the iliocostal muscle. On the basis of anatomical considerations, the damage pattern can be identified as having been caused by surgery. It is extremely unlikely that trauma is the cause.

Keywords Lumbar · Spine · Surgery · Muscle · Surface EMG · Vertebral fracture

Introduction

Since the classification by Magerl et al. [13] was introduced, there have been clear guidelines for the operative treatment of unstable fractures of the thoracolumbar junction. The dorsal approach with transpedicular stabilisation is considered the standard; additional ventral measures are usually only favoured for removal of fragments from the vertebral canal or for reconstructing the ventral column in patients with injuries including a compression component. The access morbidity of the ventral approach with

the possible complications it entails is frequently discussed, while muscular damage after the dorsal procedure is not generally considered in studies on the outcome of surgery or is even denied in textbooks and the literature [1, 4, 24]. The success of an operation is thus still primarily made conditional on the radiological result, although it is only in the event of substantial correction losses that there is a correlation with occurring pain. Transpedicular instrumentation involves subperiosteal detachment of the paravertebral muscles and a clean abscission of the tendon attachments of the multifidus muscles and the rotator muscles (Fig. 1). The operation thus destroys the segmen-

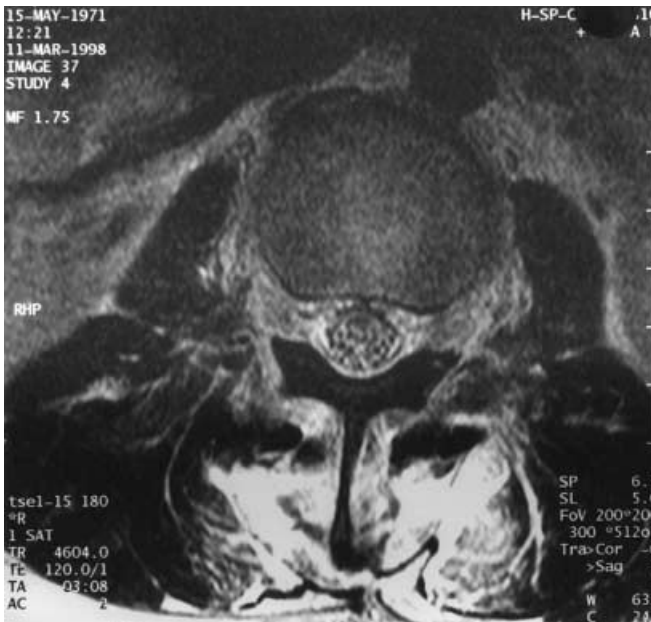

Fig. 1 Magnetic resonance imaging (MRI): Postoperative haematoma in the multifidus directly above the implant. No pathological findings in the longissimus or iliocostal muscles

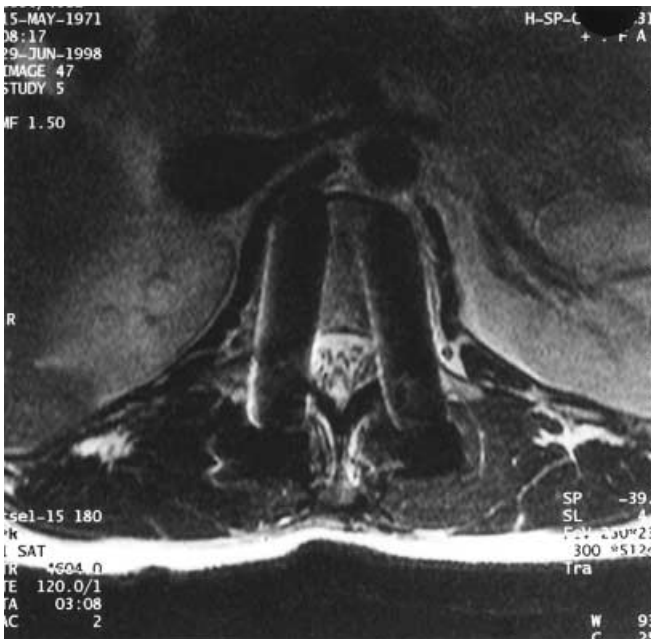

Fig. 2 Magnetic resonance imaging (MRI): Section at the level of the fixator 3 months after surgery. The volume of the multifidus is almost completely filled by the implant. Moreover, a physiological bond between muscle and bone is prevented by the metal

tal mechanisms of stabilisation, and reinsertion or healing to meet anatomical requirements cannot be expected with implant material in situ (Fig. 2). However, if the muscles actually suffer long-term damage during the operation,

this provides a possible explanation for chronic back pain and is very significant for all rehabilitation programmes designed to strengthen muscles. In view of these factors, this study investigates whether the dorsal approach causes damage to the erector muscle of spine and whether this damage is correlated with pain.

Methods

Patients and healthy subjects

A total of 19 male and 13 female patients were investigated; these patients had undergone a transitory dorsal spondylodesis to stabilise a fracture in an upper lumbar vertebra. Removal of the metal at least 6 months earlier was an inclusion criterion. Twenty-five patients had a fracture of the first lumbar vertebra, while seven patients had a fracture of the second lumbar vertebra. All the fractures were classified using computed tomography (CT) scans as unstable flexion injuries. Twenty-seven patients had a pure compression injury (type A [13]), and five patients had a flexion and distraction injury (type B [13]). The median follow-up periods were 4 years for the spondylodesis operation (minimum, 2 years; maximum, 7 years) and 2.5 years for metal removal (minimum, 6 months; maximum, 6 years). The patient group was subdivided according to a Visual Analogue Scale (VAS) related to back pain (0, no back pain; 10, very intense back pain) into a group with severe back pain and a group with mild back pain in order to investigate the relationship between EMG activity and back pain. The group of patients with severe pain comprised 13 patients with a VAS score of 7–10, while the group of patients with mild pain comprised 19 patients with a VAS score of 1–3. Patients with a VAS score of 4–6 were not enrolled in the study (Table 1). The control group consisted of 32 individuals who had been selected as matched partners for the above-mentioned patients. The selection criteria were sex, age (± 2 years), height (± 3 cm) and weight (± 5 kg). None of the controls' histories included any lumbar spine trouble in the previous 3 years (Table 2).

Electromyography

All the patients and healthy subjects were subjected to both a clinical and an EMG examination of the paravertebral muscles. The skin was first cleansed and electrodes were then attached bilaterally, following the course of the fibres, above the multifidus muscle at the level of the body of the second lumbar vertebra, above the longissimus muscle at the same level and above the iliocostal muscle at the level of the body of the tenth thoracic vertebra (Fig. 3). A bipolar recording was made with a reference electrode above the prominent vertebra. Self-adhesive silver/silver chloride surface electrodes with a gel pad 1.2 cm in diameter were used to record activity. The electrode centres were spaced 2 cm apart. The signal was conducted to the A/D converter via a stress-free double-insulated cable.

Signal processing

An eight-channel differential amplifier (Noraxon) was used to record signals. The raw EMG signal was band-pass filtered between 5 and 500 Hz, digitised using 1000 Hz and stored for later evaluation. The quality of the EMG signal was checked visually on the screen during the measurements and confirmed by evaluation of the spectral analysis (Myosoft Software).

Table 1 Comparison of rank distribution values of body-mass index (BMI), age, height and weight in patients with a Visual Analogue Scale (VAS) score of ≥ 7 ($n=13$) and patients with a VAS of ≤ 3 ($n=19$)

Characteristic	Patients with VAS ≥ 7				Patients with VAS ≤ 3			
	Median	Range	25% quartile	75% quartile	Median	Range	25% quartile	75% quartile
Age (years)	38	19–52	26	43	29	17–51	20.5	36
Height (cm)	172	159–183	168	175	174	160–186	170	179
Weight (kg)	68	53–87	58	72	70	50–92	59	81
BMI (kg/m ²)	23.7	18.8–28.7	20–2	24.1	22.1	18.2–29	20.1	26.1

Table 2 Comparison of rank distribution values of body-mass index (BMI), age, height and weight in patients ($n=32$) and healthy subjects ($n=32$)

Characteristic	Patients				Healthy Subjects			
	Median	Range	25% quartile	75% quartile	Median	Range	25% quartile	75% quartile
Age (years)	33	18–52	23	39	31	20–55	26	35
Height (cm)	174	159–186	168	179	174	158–188	170	180
Weight (kg)	70	50–92	60	80	70	50–94	60	82
BMI (kg/m ²)	23.1	18.2–29.0	20.3	25.3	23.2	18.5–29.7	21.0	26.2

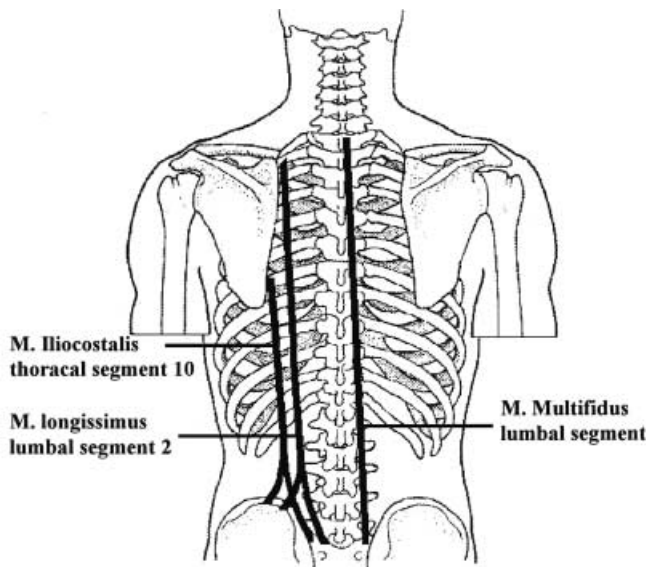


Fig. 3 Examined muscle groups and the corresponding electrode localisation

Experimental set-up

The test person was placed on an examination table in a prone position and strapped to the table with a broad belt across the legs. The chest section of the examination table was tilted downwards at the beginning of the measurements. The measurement started with the participant lifting the upper part of the body until it was horizontal, and he or she was urged to hold this position for as long as possible, keeping as still as possible. After the EMG signal had been recorded, the test person relaxed again on the examination table.

Analysis of data

During the contraction phase, the mean rectified amplitude of the EMG signal was determined for all three muscle groups during the first 5 s. To reduce the amount of data, the mean of the right and left mean rectified amplitude of each muscle group was calculated. This mean value was used for comparison. The data material obtained was evaluated descriptively and statistically by means of the Wilcoxon test. The mean rectified amplitude is influenced by various parameters, mainly the load, filtering quality of the fat tissue, the muscle fibre diameter and the number of fibres in the electrode's measuring range [6]. By matching the two groups with regards to weight and height, a similar fat distribution and thus similar filter properties of the fatty layer were assumed between the groups on the basis of the identical body mass index. On the basis of biomechanical considerations by Mannion et al. [14], the load in the examination task depends on the height and weight of the test person. As these values were nearly identical in the two groups, the load was comparable.

Results

Comparison of mean rectified amplitudes between all patients and the control group

The mean rectified amplitude of the multifidus group was 25% higher ($P<0.025$) in the healthy subjects than in the patients. In the iliocostal region, the mean rectified amplitude was 28% higher in the patients ($P<0.05$). No difference was found in the comparison of the longissimus muscle (Fig. 4).

Comparison of patients with VAS >7 and patients with VAS <3

We compared the percentage deviations of all patients against their matched partners. The median loss of the

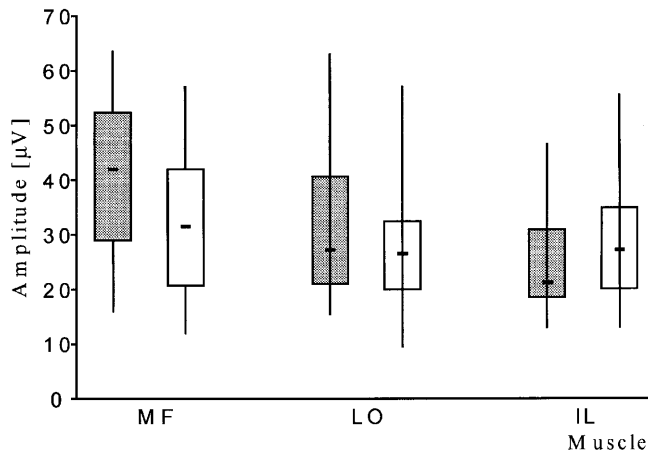


Fig. 4 Comparison of the rank distribution of the mean amplitudes (μV) of the three muscle groups between healthy subjects (*grey bars*) and patients (*white bars*). The 25% and 75% quartiles give the error indicators. *MF*, multifidus muscle; *LO*, longissimus muscle; *IL*, iliocostal muscle

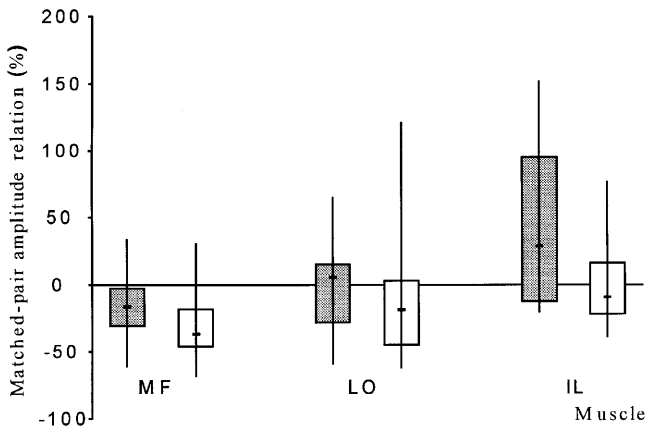


Fig. 5 Comparison of the rank distribution of the percentage difference in the muscle activities of patients with severe pain (*white bars*) and patients with mild pain (*grey bars*) as compared to healthy subjects. 0% represents the level of activity of the matched-pair partner with a healthy back. *MF*, multifidus muscle; *LO*, longissimus muscle; *IL*, iliocostal muscle

rectified amplitude of the multifidus was 37% in patients with severe pain, while it was only 16% in patients with mild pain ($P < 0.05$). At the same time, the patients with severe pain were found to have a median decrease of 9% in the iliocostal muscle, while patients with mild pain had an increase in electrical activity of 29% in this muscle group ($P < 0.05$).

Comparison of the longissimus muscle showed a loss of amplitude of 19% in the patient group with severe pain and a median increase of 9% in the group with mild pain. These differences were not significant (Fig. 5).

Discussion

Demonstration of muscle damage on EMG

The importance of the erector muscle of spine for stabilisation and active movement of the spine has been investigated in the literature on several occasions. With the aid of EMG measurements, it was possible to assign different functions in active movement to the different muscle groups. Jonsson [11] found that the multifidus muscles displayed a greater activity in extension movements than the longissimus muscle and that the latter has a greater activity than the iliocostal muscle. Verbout [23] mainly assigned functions in extension to the multifidus muscle, while the longissimus muscle and the iliocostal muscle were mainly exercised during lateral inclination and rotation. In the present study, the results of the healthy subjects, but not those of the patients, did in fact indicate that the individual paraspinal muscles display differing levels of activity in extension. However, confirmation would be required that the fatty layer overlying the respective muscles did not differ in order to substantiate this. Nonetheless, even if differing fatty layers were responsible for the absolute differences in EMG amplitude, it is still clear from the matched comparisons that the relative activity of the individual paraspinal muscles differed between the patients and the controls in that there was less activity in the multifidus muscle than in the iliocostal muscle. These changes in muscle activity may be the result of direct damage to muscle fibres of the multifidus group or indirect damage to these muscles by nerve or vascular damage. Both direct and indirect damage may be caused by the trauma or by the operation. We will begin by discussing the possibility of direct damage to the muscle fibres caused by the trauma or the surgical access.

Trauma as the "direct" cause

A total of 27 patients in this study had a pure compression injury. By definition, this is a compression of the vertebral body without injury to the dorsal tension band structures and includes the interspinous ligament and the muscles [13]. Due to the classification of the injury, direct muscle damage caused by the trauma can be ruled out in these 27 patients. The remaining five patients had a flexion and distraction injury. With this type of fracture, the muscles and dorsal ligaments are strained in addition to the compression of the vertebral body. The entire transverse section of the muscles is strained. Due to the convexity of the costal arch, a greater or at least equally large stretching distance must be assumed for the iliocostal muscles, which are located further laterally. However, as the damage is present in the multifidus only, direct damage to the muscle fibres is also extremely unlikely with this type of fracture.

Operation as the “direct” cause

During the operation, the multifidus is detached from the bone. In the further course of surgery, the implant is fitted directly to the bone, so that cicatricial bonding between the bone and the muscles cannot take place during wound healing. Since the longissimus and iliocostal muscles are not directly damaged by the surgical access, a decrease in the potential of these muscles is not to be expected. The increase in the electrical potential above the iliocostal muscles can be regarded as a compensation mechanism for the loss of multifidus activity.

Trauma and operation as the “indirect” cause

The third possibility, indirect muscle damage due to injury to the nerves during the accident or the operation, cannot be ruled out. Braunschwarz and Kallitzas [3] and Rantanen et al. [18] established fibre type grouping as a sign of nerve damage in a small percentage of the patients with conditions after spine surgery. The discussion on how a nerve injury can lead to the isolated damage established for the multifidus muscles should be guided by the anatomical course of the dorsal branch of the spinal nerve. The course of this nerve and the innervation of the erector muscle of spine were investigated thoroughly by Bogduk [2] and Kalimo et al. [12] (Fig. 6). The dorsal branch is rigidly fixed shortly after its ramification at the point of

passage through the transverse ligament [21]. Because it is fixed at this site, this is the most likely place for a nerve injury. It is conceivable that this nerve is injured because of a scissor movement during the accident or due to the abduction of the muscles during the operation. An injury to the nerve at this level (or more centrally) would, however, result in a decrease in the electrical activity of all the erector muscles of spine and is not consistent with the amplitudes measured in the longissimus and iliocostal muscles. Nerve-related isolated damage to the multifidus muscles can only be caused by isolated damage to the medial ramus of the dorsal branch of the spinal nerve. This nerve branch runs along the multifidus compartment. The traumatic mechanism cannot conclusively explain an isolated damage to this nerve branch, whereas the multifidus compartment is reached in the surgical procedure, making such damage conceivable. Both direct and indirect damage to the multifidus muscle can thus be explained by the surgical procedure, while trauma as the cause of the damage does not explain the different development of electrical activity in the individual muscles of the erector muscle of spine and is thus unlikely to be the cause. A further possibility for explaining the EMG amplitudes measured is damage to the proprioception organs. Due to the detachment of the muscles directly on the bone, the aponeuroses of the tendons, which contain the tendon organs, are damaged. Together with the muscles close to the tendon, they are later replaced by cicatricial tissue. The loss of the tendon attachments may result in non-physiological patterns of activation [5]. As the muscles close to the tendons have the highest concentrations of muscle spindles – assuming that the anatomical behaviour in healthy people is the same as that in people with idiopathic scoliosis in this respect [9] – destruction of these fibres would have a further influence on neuromuscular control. According to Gandevia and McCloskey [10], the perception of stress is decisive for the number of motor units activated. Attenuation of the afferent signal would thus result in a reduced activity of the multifidus muscles which have been detached from the bone. The increase in the activity of the iliocostal muscle could thus also be regarded as a neuro-physiological compensation mechanism.

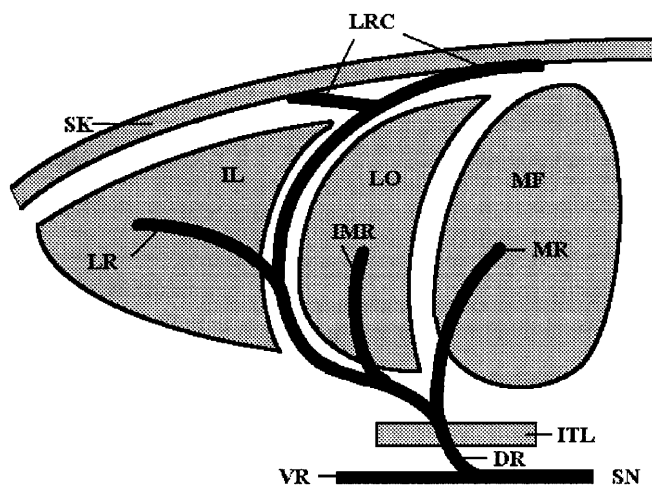


Fig. 6 Lumbar paravertebral muscles and their innervation. The spinal nerve (SN) branches into the ventral ramus (VR) and the dorsal ramus (DR). The latter passes through the intertransverse ligament (ITL), which is stretched out between the costal processes. In the muscles, the DR then separates into its three rami: the medial ramus (MR), which innervates the multifidus muscle (MF), the intermediary ramus (IMR), which innervates the longissimus muscle (LO), and the lateral ramus (LR), which innervates the iliocostal muscle (IL). The lateral cutaneous ramus (LRC) innervates the skin (SK)

Correlations between EMG and pain

In the patient group, we measured a loss of activity in the multifidus muscles which was compensated for by an increase in activity in the iliocostal muscles by the same amount. When looking at the patients, considerably greater losses of electrical activity in all three muscle groups were found in the group with severe pain than in the group with minor pain. In particular, there was no compensatory increase in activity in the iliocostal muscle in the severe pain group. According to the biomechanical pain model [25], the most likely explanation for this gen-

eralised loss of activity of all back muscles is an inactivity-related atrophy. The model describes a vicious circle between pain and instability. Thus instability leads to pain, pain and the resulting inactivity lead to muscle atrophy, and this leads to a further increase in instability which, in turn, sustains the pain, and so on. The phenomenon of muscle atrophy has also been measured by means of EMG in patients with lower back pain by other authors [16, 19, 20, 22] in the past. Park et al. [17] even established muscle atrophy in patients with lower back pain using CT scans and EMG examinations. Various biopsy studies [7, 8, 15] show an atrophy that mainly involves the type II fibres in patients with low back pain. It must be assumed that biopsy and EMG studies describe the same phenomenon. According to the results of this study, patients can probably reduce pain due to the compensatory activity of unaffected muscles, and the relationship between muscle damage caused by surgery and pain should therefore be examined closely. In the patient group studied, pain only occurred when there was a lack of compensation or a generalised atrophy; the causes are thus multifactorial. Considering this background, surgery-related soft tissue damage at least constitutes a predisposition for developing back pain. In patients with marginal muscle function, operative muscle damage is also conceivable as the cause of a functional decompensation.

Limitations of the study

We did not perform an invasive needle EMG examination, as other studies have already shown that signs of denervation only occur in a small percentage of patients with conditions after spine surgery and thus do not constitute an explanation for pain [3, 18]. Clinical examination did not reveal a sensibility deficit above the paravertebral muscles in any of the patients. Nerve-related muscle damage was considered extremely unlikely from this angle as

well. To obtain direct proof of surgery-related muscle damage, a conservatively treated patient population might have been better than a normal population as a control group. However, on the basis of internationally recognised indications for surgery, a group in which conservative treatment is indicated cannot be assumed to have the same traumatic severity as a group in which operative treatment is indicated. Because the injuries are different, there would be no basis for comparison. For this reason, we went to great lengths to put together a group of matched-pair subjects with healthy backs for comparison. Parameters which are relevant to the amplitude analysis were taken into account. In the literature, the significance of these parameters has been pointed out on numerous occasions; however, no EMG study was found which paid attention to this fact in the study design.

Conclusion

It was possible to demonstrate surgery-related muscle damage in comparing the groups. Although it is only the multifidus which is damaged by the operation, the entire muscle system of the erector muscle of spine reacts with changes in coordination. The amplitude changes in patients with severe pain are compatible with an additional generalised atrophy of the erector muscle of spine.

The results thus supported the hypothesis that surgery-related muscle damage *may* constitute a predisposition to the development of pain. Continuing pain itself may result in further alterations in muscle activation and coordination.

The study does not advocate the abolition of spine surgery, but instead stresses the importance of the soft tissue for the clinical outcome. Rehabilitation programmes designed to strengthen muscles and minimally invasive surgical techniques that spare soft tissue may thus be highly significant to avoid postoperative pain syndromes.

References

- Ahern DK, Follick MJ, Council JR, Laser-Wolston N (1986) Reliability of lumbar paravertebral EMG assessment in chronic low back pain. *Arch Phys Med Rehab* 67:762–765
- Bogduk N (1983) The innervation of the lumbar spine. *Spine* 8:286–292
- Braunsfurth A, Kallitzas J (1975) Elektromyographische Untersuchungen über den Einfluß von Operationen an der Wirbelsäule auf die Muskelfunktion. *Arch Orthop Unfall Chir* 82:147–155
- Cassisi JE, Robinson ME, O'Conner P, MacMillan M (1993) Trunk strength and lumbar paraspinal muscle activity during isometric exercise in chronic low-back pain patients and controls. *Spine* 18:245–251
- Cooper RG, Stokes MJ, Sweet C, Taylor RJ, Jayson MIV (1993) Increased central drive during fatiguing contractions of the paraspinal muscles in patients with chronic low back pain. *Spine* 18:610–616
- De Luca CJ (1979) Physiology and mathematics of myoelectric signals. *Trans Biomed Eng* 6:313–325
- Fidler MW, Jowett RL, Troup JDG (1975) Myosin ATPase activity in multifidus muscle from cases of lumbar spinal derangement. *J Bone Joint Surg [Br]* 57:220–227
- Ford MD, Bagnall KM, McFadden KD, Greenhill B, Raso VJ (1983) Analysis of vertebral muscle obtained during surgery for correction of a lumbar disc disorder. *Acta Anat* 116:152–157
- Ford MD, Bagnall KM, Clements CA, McFadden KD (1987) Muscle spindles in the paraspinal musculature of patients with adolescent idiopathic scoliosis. *Spine* 13:461–465

10. Gandevia SC, McCloskey DI (1978) Interpretation of perceived motor commands by reference to afferent signals. *J Physiol* 283:493–499
11. Jonsson B (1970) The functions of individual muscles in the lumbar part of the spinae muscle. *Electromyography* 1:5–21
12. Kalimo H, Rantanen J, Viljanen T, Einola S (1989) Lumbar muscles: structure and function. *Ann Med* 21:353–359
13. Magerl F, Aebi M, Gertzbein S, Harms J, Nazarian S (1994) A comprehensive classification of thoracic and lumbar injuries. *Eur Spine J* 4:184–201
14. Mannion A, Dolan P (1994) Electromyographic median frequency changes during isometric contraction of the extensors to fatigue. *Spine* 19:1223–1229
15. Mattila M, Hurme M, Alaranta H (1986) The multifidus muscle in patients with lumbar disc herniation. A histochemical and morphometric analysis of intraoperative biopsies. *Spine* 11:732–738
16. Nachemson A, Lindh M (1969) Measurement of abdominal and back extensor strength with and without low-back pain. *Scand J Rehabil Med* 1:60–65
17. Park ES, Park CI, Kim AY, Park MK (1993) Relationship between electromyography and computed tomography in the evaluation of low back pain. *Yonsei Med J* 34:84–89
18. Rantanen J, Hurme M, Falck B, Alaranta H, Nykvist F, Lehto M, Einola S, Kalimo H (1993) The lumbar multifidus muscle five years after surgery for a lumbar intervertebral disc herniation. *Spine* 18:568–574
19. Robinson ME, Cassisi JE, O'Connor PD, MacMillan M (1992) Lumbar iEMG during isotonic exercise: chronic low back pain patients versus controls. *J Spinal Disord* 5 8–15
20. Sihvonen T, Partanen J, Hänninen O, Soimakallio S (1991) Electric behavior of low back muscles during lumbar pelvic rhythm in low back pain patients and healthy controls. *Arch Phys Med Rehab* 72:1080–1087
21. Sihvonen T, Herno A, Paljärvi L, Airaksinen O, Partanen J, Tapaninaho A (1993) Local denervation atrophy of paraspinal muscles in postoperative failed back syndrome. *Spine* 18:575–581
22. Thorstensson A, Arvidsson A (1982) Trunk muscle strength and low back pain. *Scand J Rehabil Med* 14:69–75
23. Verbout AJ (1990) Functional and morphological events for a subdivision in the intrinsic back muscles. *Orthop Trans* 14:744–745
24. Weber BR, Grob D, Dvorák J, Müntener M (1997) Posterior approach to the lumbar spine and its effect on the multifidus. *Spine* 15:1765–1772
25. Wolf SL, Basmajian JV (1978) Assessment of paraspinal electromyographic activity in normal subjects and in chronic back pain patients using a muscle biofeedback device. In: Asmussen E (ed) *Biomechanics 6B*. University Park, Baltimore, pp 319–324