

Multiple rib fractures associated with severe coughing – a case report

H. Kawahara, H. Baba, M. Wada, M. Azuchi, M. Ando, S. Imura

Department of Orthopaedic Surgery, Fukui Medical School, Fukui, Japan

Accepted: 11 July 1996

Summary. We report a young man with multiple rib fractures which were caused by severe coughing associated with acute bronchitis.

Résumé. Nous rapportons ici le cas d'un jeune homme atteint de multiple fractures bilatérales des côtes provoquées par une toux constante due à une bronchite. Deux symptômes, la toux et la douleur costale, présents tout au long du traitement ont contribué à retarder la guérison de dix mois après la première apparition symptomatique. Les soins intensifs des bronchites sont de première importance pour favoriser la guérison rapide des fractures ou pour éviter les risques de fractures multiples.

Introduction

Severe chronic coughing infrequently causes rib fractures and these stress fractures usually occur in one rib.

We report an unusual case of multiple bilateral rib fractures caused by severe coughing associated with acute bronchitis.

Case report

A man, 27 years of age, complained of pain in the right side of the chest and a severe cough which followed a common cold. His symptoms became worse and pain spread to the left side of his chest.

Reprint requests to: H. Kawahara, Department of Orthopaedic Surgery, Fukui Medical School, Shimoaizuki 23, Matsuoka, Fukui 910-11, Japan

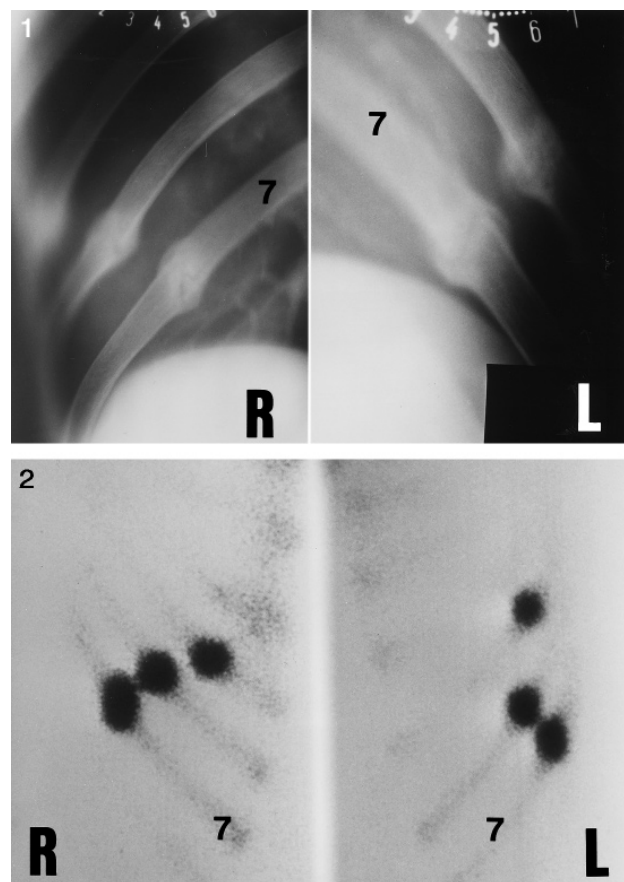


Fig. 1. Tomographs showing transverse fractures of the 5th, 6th and 7th ribs. R = right; L = left; 7 = 7th rib

Fig. 2. ^{99m}Technetium scintigraphy showing bilateral multiple uptake of the isotope

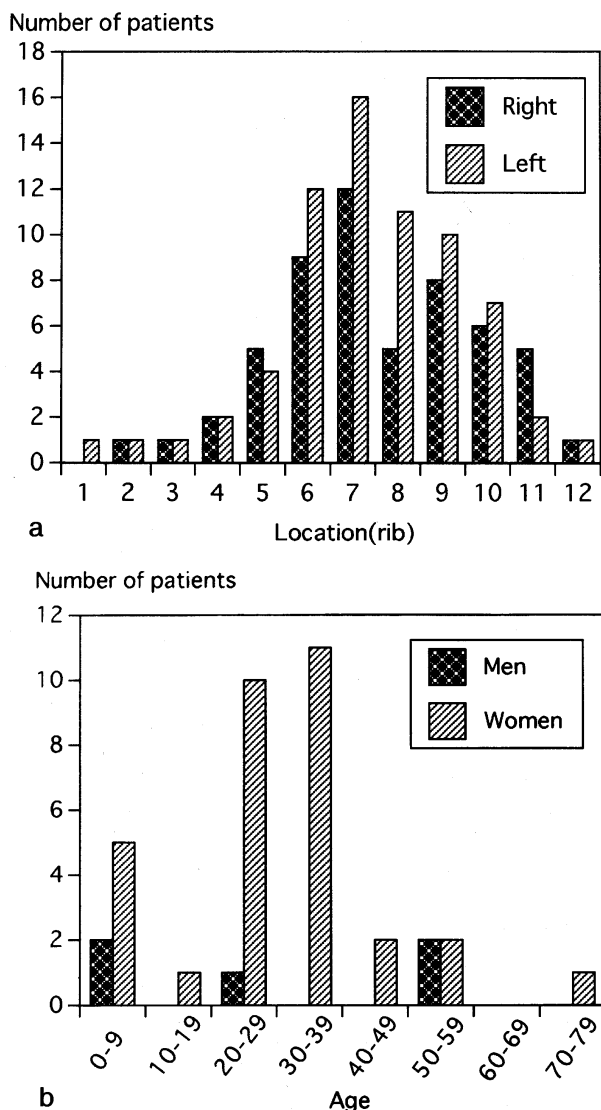


Fig. 3. **a** Distribution of the site of reported cough fractures of the ribs. **b** Age distribution of the reported fractures

He had signs of subacute bronchitis. Laboratory tests were negative. Radiographs showed oval hyperostoses on the right 5th to 7th ribs with similar appearances on the left side (Figs. 1, 2). MRI showed no pleural seeding or effusion. A skeletal survey and further investigations were negative. Open biopsy of the 6th rib on the right showed normal fracture healing with abundant cartilaginous tissue and revascularisation, rather than a pathological fracture. The diagnosis was cough-related stress fractures.

Treatment was antitussive medication, rest and restriction of work and vigorous movement. Symptoms continued for about 6 months. Complete healing occurred 10 months after the onset of bronchitis and the patient has had no symptoms since.

Discussion

We have been able to collect 37 reported cases of cough fracture (5 men and 32 women). The fractures were mainly of the 6th to 9th ribs with a slight predilection for the left side [3] (Fig. 3a). Most occurred in the 3rd and 4th decades and affected women more often than men (Fig. 3b) [1–19]. The fractures were unilateral in 24 and bilateral in 13. A case with fractures of 6 ribs has been reported [13].

The fracture usually occurs in the middle of the rib between the costochondral junction and the costal angle. Sheering forces are applied to the rib at the axillary line where serratus anterior and the external oblique muscles are attached [10]. The important role of bending stresses inducing a transverse, rather than oblique, fracture has also been emphasised [1, 3]. Longitudinal tensile stress usually produces a transverse stress fracture of compact bone [1], whereas sheering forces produce an oblique fracture.

Our patient showed transverse fracture lines suggesting tensile stress as the mechanism. The configuration of an arcuate and spiral rib is, however, unlikely to be affected only by tensile forces. We believe that multiple factors are involved including expansive force during respiratory movement, tensile as well as sheering forces, the reduced diameter and increased curvature of the rib at the fracture site, and traction by the external oblique abdominal muscles and the rectus abdominis fascia.

Multiple and bilateral cough fractures were an unusual feature of our case. Radiographs and scintigraphy showed a variable degree of healing and isotope accumulation ratios. Severe coughing may have caused one fracture at a time and continuous coughing may have delayed healing. Adequate treatment is needed to allow early healing of these fractures.

References

1. Carter DR, Hayes WC (1977) Compact bone fatigue damage. *Clin Orthop* 127: 265–274
2. Cohen RC (1949) Cough fracture of ribs. *Br Med J* 1: 133–135
3. Derbes VJ, Haran T (1954) Rib fractures from muscular effort with particular reference to cough. *Surgery* 35: 294–321
4. Douthwaite AH (1949) Cough fracture of ribs. *Br Med J* 2: 241
5. Edgcombe W (1935) Fracture of the ribs in whooping cough. *Lancet* II: 374
6. Evans FA (1949) Cough fracture in late pregnancy. *Br Med J* 2: 241

7. Even-Tov I, Yedwab GA, Persitz E, David MP (1979) Stress fracture of ribs in late pregnancy. *Int Surg* 64: 85–87
8. Halliwell BT (1929) Fracture of ribs caused by coughing. *Br Med J* 12: 1056
9. Howson CR (1934) Rib-fracture by cough. *Am Rev Tuberc* 30: 566–567
10. Long AE (1962) Stress fracture of the ribs associated with pregnancy. *Surg Clin North Am* 42: 909–919
11. Kópcsányi I, Laczay A, Nagy L (1969) Cough fracture of ribs in infants with dyspnoea. *Acta Paediatr Acad Sci Hung* 10: 93–98
12. Oren V, Kozenitzky I, Babiacki A, Stern A (1988) Unusual cough related stress injuries. *Eur J Nucl Med* 14: 108–111
13. Palmer PES (1953) Bilateral cough fractures. *Br Med J* 3: 732
14. Roberge RJ, Morgenstern MJ, Osborn H (1984) Cough fracture of the ribs. *Am J Emerg Med* 2: 513–517
15. Savage D (1956) Stress fracture of ribs in pregnancy. *Lancet* 4: 420–421
16. Swineford O Jr, Mckinnon J (1945) Multiple fractures of ribs by cough: report of a case. *Ann Intern Med* 23: 442–444
17. Warmington WT (1966) Four cases of cough fracture. *Ulster Med J* 35: 72–74
18. Webb GB, Gilbert GB (1923) Ribs fractured by coughing. *JAMA* 81: 25
19. Wynn-Williams N (1951) Cough fracture of the ribs unassociated with pulmonary tuberculosis. *Br Med J* 12: 1494–1496