

## Case Report: Simultaneous Infection with *Leishmania (Viannia) braziliensis* and *L. (V.) lainsoni* in a Peruvian Patient with Cutaneous Leishmaniasis

Nicolas Veland, Braulio Mark Valencia, Milena Alba, Vanessa Adai, Alejandro Llanos-Cuentas, Jorge Arevalo, and Andrea K. Boggild\*

Instituto de Medicina Tropical Alexander von Humboldt, Universidad Peruana Cayetano Heredia, Lima, Peru; Hospital Nacional Cayetano Heredia, Lima, Peru; Departamento de Ciencias Celulares y Moleculares, Facultad de Ciencias y Filosofía, Universidad Peruana Cayetano Heredia, Lima, Peru; Tropical Disease Unit, Division of Infectious Diseases, Department of Medicine, University Health Network-Toronto General Hospital, University of Toronto, Toronto, Ontario, Canada

**Abstract.** Conventional understanding suggests that simultaneous infection with more than one species of *Leishmania* is unlikely. In Peru, co-infections are clinically relevant because causative species dictates prognosis, treatment response, and follow-up. We describe a case of *Leishmania (Viannia) braziliensis* and *L. (V.) lainsoni* co-infection in a Peruvian patient with cutaneous leishmaniasis.

### INTRODUCTION

Cutaneous leishmaniasis (CL) is caused mainly by *Leishmania (Viannia)* species in the New World.<sup>1,2</sup> Among the subgenus *L. (Viannia)*, different species are widespread in South American regions to which leishmaniasis is endemic, which include areas from the tropical jungle to Andean valleys.<sup>1</sup> Moreover, *Leishmania (Viannia)* species are responsible for different clinical characteristics, such as the capacity of *L. (V.) braziliensis*,<sup>2,3</sup> *L. (V.) guyanensis*,<sup>4</sup> and *L. (V.) panamensis*,<sup>5</sup> although predominantly *L. (V.) braziliensis*, to metastasize in the human host, leading to mucosal leishmaniasis, or the variable clinical response to antimonial chemotherapy seen in patients infected with *L. (Viannia)* parasites in different geographic settings.<sup>6</sup>

It has been previously demonstrated that at 12 months post-treatment, 30% of *L. (V.) braziliensis*-infected patients showed treatment failure with pentavalent antimony compared with 25% of *L. (V.) peruviana*-infected patients and 8% of *L. (V.) guyanensis*-infected patients, thus reiterating a species specificity to treatment response.<sup>6</sup> In Peru, where approximately 10,000 new cases of leishmaniasis are reported annually,<sup>7</sup> four species of the *L. (Viannia)* subgenus, namely *L. (V.) peruviana*, *L. (V.) braziliensis*, *L. (V.) guyanensis*, and *L. (V.) lainsoni*, in addition to *Leishmania (Leishmania) amazonensis*, have been reported.<sup>1,6</sup>

Traditionally, it is assumed that leishmaniasis vectors and human hosts are infected with one single species. However, it has been reported in Brazil and Mexico that two different species have naturally co-infected the same reservoir.<sup>8–13</sup> Moreover, previous work in Bolivia using molecular methods detected patients with co-infection of different *Leishmania* species as well as *Leishmania-Trypanosoma cruzi* co-infections.<sup>14</sup> We report a case of two different *Leishmania (Viannia)* species, namely *L. (V.) braziliensis* and *L. (V.) lainsoni*, identified by molecular means as causing distinct lesions in a Peruvian patient with CL.

### CASE REPORT

A 33-year-old Peruvian woman presented to our center for evaluation of three painless ulcerative skin lesions with a duration of six weeks, which appeared simultaneously. Two months before presentation, the patient had spent two weeks working in the Iberia District of Madre de Dios, Peru. She did not normally reside in an endemic area for CL, but during the 12 months before admission, she had traveled to several jungle regions in Peru, including Ucayali, Loreto, Junin, and San Martín, for periods no longer than 20 days. The patient reported that her skin lesions developed as three papules, one on each of the left arm, right arm, and left leg two weeks after leaving Iberia, three months after leaving Ucayali, and five months after leaving Loreto. All papules quickly progressed to painless, moist, ulcerative lesions. Her past medical history was unremarkable and she was otherwise well without fever, weight loss, cough, or other systemic symptoms.

At examination, the patient appeared well and vital signs were normal. The three lesions in question were moist ulcers with raised, well-circumscribed violaceous borders. There was no evidence of cellulitis, lymphangitic streaking, or regional lymphadenopathy. The ulcer on the right arm was 1.0 × 1.2 cm, the ulcer on the left arm was 1.4 × 1.6 cm, and the ulcer on the left leg was 2.2 × 2.9 cm. There was no evidence of mucosal involvement in the nose, palate, or larynx.

The patient was enrolled in a diagnostic study reported elsewhere,<sup>15</sup> and as such, she underwent lesion scraping, aspiration, and filter paper impression of all three ulcers. Material from lesion scrapings was smeared on glass slides for Giemsa-stained microscopy and assayed for detection of *Leishmania (Viannia)* kinetoplast DNA (kDNA) by polymerase chain reaction (PCR) as described (Figure 1A).<sup>15</sup> Tissue fluid from lesion aspirates was inoculated into traditional *Leishmania* Novy-MacNeal-Nicolle culture medium as described,<sup>16</sup> and assayed by kDNA PCR. Filter paper lesion impressions (FPLIs) were assayed by kDNA PCR as described.<sup>15,16</sup> Identification of *Leishmania (Viannia)* causative species was performed by using mannose phosphate isomerase (*mpi*), cysteine proteinase B, and heat shock protein 70 PCR and PCR–restriction fragment length polymorphism (PCR-RFLP) analysis according to the algorithm described elsewhere.<sup>17</sup>

Specimens from lesions 1 and 2 on the arms amplified product in the *mpi* PCR when *mpi Leishmania (V.) braziliensis* primer

\*Address correspondence to Andrea K. Boggild, Tropical Disease Unit, Toronto General Hospital, Department of Medicine, University of Toronto, 200 Elizabeth Street, 13EN-218, Toronto, ON, M5G 2C4, Canada. E-mail: andrea.boggild@utoronto.ca

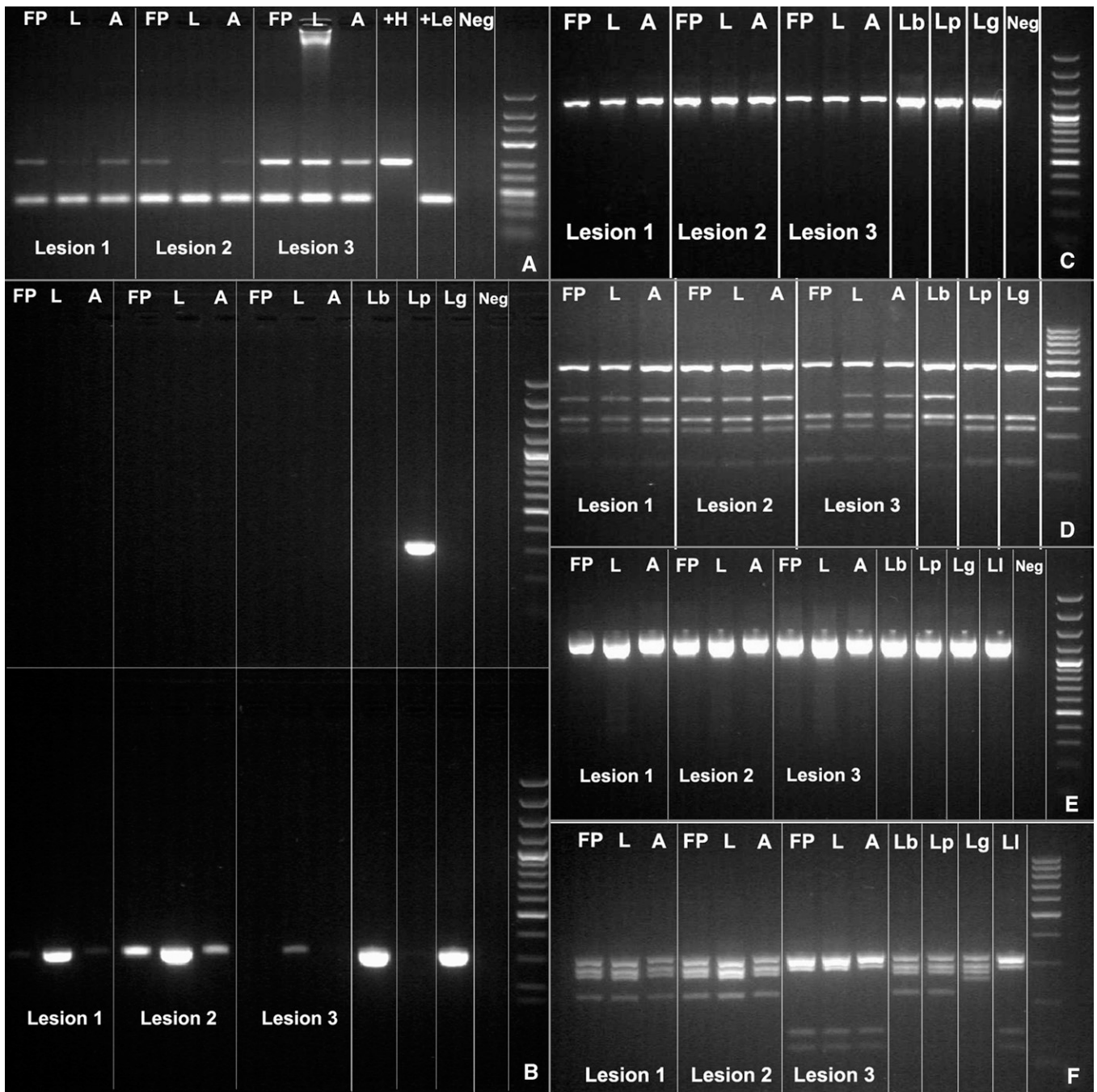


FIGURE 1. Results of polymerase chain reaction (PCR) and PCR–restriction fragment length polymorphism (RFLP) analysis for three types of clinical specimens (filter paper lesion impressions [FP], lancet scrapings [L], and aspirates [A]) obtained from three skin lesions of a Peruvian patient with cutaneous leishmaniasis. **A**, kinetoplast DNA PCR; **B**, mannose phosphate isomerase (*mpi*) PCR. Upper gel: *Leishmania* (*Viannia*) *peruviana* (Lp) *mpi* PCR; lower gel: *L. (V.) braziliensis* [Lb] *mpi* PCR, indicating amplification of *L. (V.) braziliensis mpi* target in all 3 lesions (note: only 1 of 3 specimens from lesion 3); **C**, cysteine proteinase B (*cpb*) PCR; **D**, RFLP analysis of *cpb* PCR products, indicating *L. (V.) braziliensis* pattern of banding for lesions 1 and 2, and a mixed banding pattern (*L. (V.) peruviana* or *L. (V.) guyanensis* [Lg]) with filter paper specimen and *L. (V.) braziliensis* with lancet and aspirate specimens for lesion 3; **E**, heat shock protein 70 (*hsp70*) PCR; **F**, RFLP analysis of *hsp70* PCR products, indicating an *L. (V.) braziliensis* or *L. (V.) peruviana* banding pattern for lesions 1 and 2, and an *L. (V.) lainsoni* banding pattern for lesion 3. Neg = negative. Right lane in each panel is a molecular mass marker.

was used, allocating their identity to either *L. (V.) braziliensis* or *L. (V.) guyanensis* (Figure 1B).<sup>17</sup> In contrast, specimens from lesion 3 on the leg did not yield any amplification product with *mpi* PCR; *mpi* PCRs distinguish *L. (V.) peruviana* from *L. (V.) braziliensis* and *L. (V.) guyanensis*.<sup>17</sup> When cysteine proteinase B PCR-RFLP analysis, which distinguishes *L. (V.) braziliensis*

from *L. (V.) peruviana* and *L. (V.) guyanensis*, was performed on specimens from lesions 1 and 2, the resulting band pattern identified them as *L. (V.) braziliensis* (Figure 1C and D). As per our *Leishmania* species identification strategy,<sup>17</sup> specimens from lesion 3 were then subjected to heat shock protein 70 PCR-RFLP analysis, which discriminates other *L. (Viannia)*

species, and the resulting band pattern identified them as *L. (V.) lainsoni* (Figure 1E and F).

The patient was treated with 20 mg/kg/day of sodium stibogluconate for 20 days. By the end of treatment, the ulcers on the left arm (lesion 2) and left leg (lesion 3) showed complete re-epithelialization, and the ulcer on the right arm (lesion 1) showed more than 90% re-epithelialization and little inflammation. During subsequent follow-up evaluations at 1, 2, 3, 6, 12, and 24 months after therapy, the three ulcers remained completely re-epithelialized with characteristic scars and no evidence of inflammation and or mucosal involvement.

## DISCUSSION

We report a case of human *Leishmania (V.) braziliensis* and *L. (V.) lainsoni* causing different lesions in the same person. This case is notable for several reasons. First, in countries such as Peru with multiple co-endemic species, the occurrence of co-infections in humans is important to document because different causative species portend different clinical outcomes,<sup>2</sup> and demonstrate notable differences in intrinsic sensitivity to different anti-leishmanial drugs.<sup>6,18–20</sup> For economic reasons, if species identification is performed, it is typically conducted for just one lesion. Our documentation of two causative species infecting a single host suggests that species identification for each lesion may be justified, particularly in areas where *L. (V.) braziliensis*, the main causative species of mucosal leishmaniasis, is highly endemic. Had this particular patient only undergone diagnostic sampling of her lower extremity lesion, her infection with *L. (V.) braziliensis* would have gone undocumented, potentially resulting in a shortened duration of follow-up and lack of counseling regarding potential future risk of mucosal involvement.

In addition to the clinical significance of simultaneous *Leishmania* spp. infections, these cases also have pathophysiologic importance. It has been generally believed that leishmaniasis is caused by “infection with one of several different species of protozoan parasites of the genus *Leishmania*,”<sup>21</sup> rather than one or more species of *Leishmania*. However, simultaneous infection with more than one causative species of *Leishmania* has been documented.<sup>8–14</sup> It has long been postulated that infection of the host with one species of *Leishmania* might protect against re-infection with homologous or heterologous species.<sup>22,23</sup> However, *in vitro* studies of individual macrophage co-infections with different species of *Leishmania* suggest an absence of mutual exclusion if a second infection with a different strain occurs within a short window,<sup>24</sup> and recurrent infections in humans also imply some plasticity of this protective immune phenomenon.<sup>25,26</sup> The patient described in this report probably acquired the infection in the last leishmaniasis-endemic region (Iberia), and although we cannot demonstrate definitively where this patient was infected, she was likely bitten by sand flies carrying different species over a short period in the same geographic location, thereby precluding development of any kind of partially protective immune response to infection by a second species. Irrespective of this suggestion, the patient had a favorable response to standard pentavalent antimony treatment, and no further relapsing cutaneous disease or mucosal involvement was identified.

Finally, this report adds significantly to our understanding of the molecular epidemiology of leishmaniasis in Peru. *Leishmania (V.) lainsoni* is known to exist in the Brazilian

Amazon region,<sup>27</sup> the Department of La Paz, Bolivia,<sup>28</sup> and the sub-Andean or high jungle regions of Peru.<sup>1,29</sup> Although the preferred vector of *L. (V.) lainsoni*, *Lutzomyia ubiquitousis*, has been found in Madre de Dios,<sup>27</sup> this report is the first documented case of probable human infection occurring from this region. In their study of the geographic distribution of leishmaniasis in Peru based on 350 clinical samples from patients in 15 Peruvian departments, Lucas and others isolated *L. (V.) lainsoni* from seven patients in high jungle regions.<sup>1</sup> Of 136 samples from Madre de Dios, all isolates were confirmed to be *L. (V.) braziliensis*.<sup>1</sup> Until this report, *L. (V.) lainsoni* human infections have only been documented in residents of areas 600–2,000 meters above sea level.<sup>27–29</sup> Thus, this case adds to the scientific literature regarding the epidemiology of this protozoan parasite.

In summary, we have reported the first documented case of simultaneous *L. (V.) braziliensis* and *L. (V.) lainsoni* infection in a patient from Madre de Dios, Peru, an area not known to be endemic for *L. (V.) lainsoni*. Documentation of *Leishmania* co-infections is essential to our understanding of the epidemiology, pathophysiology, and clinical course of cutaneous leishmaniasis, particularly in highly leishmaniasis-endemic countries such as Peru.

Received September 21, 2012. Accepted for publication December 29, 2012.

Published online February 4, 2013.

Acknowledgments: We thank Ana Luz Quispe and Carmen Medina (Instituto de Medicina Tropical Alexander von Humboldt) for logistical support.

Financial support: Andrea K. Boggild was supported by a Detweiler Traveling Fellowship from the Royal College of Physicians and Surgeons of Canada. Personnel and facility fees for the Arevalo molecular laboratory (Nicolas Veland, Milena Alba, Vanessa Adai, and Jorge Arevalo) were supported by the Institutional Collaboration Framework Agreement 3 from the Belgian Directorate-General for Development Cooperation.

Authors' addresses: Nicolas Veland, University of Texas, MD Anderson Cancer Center, Smithville, TX, E-mail: nicolasveland@yahoo.com. Braulio Mark Valencia and Alejandro Llanos-Cuentas, Institute of Tropical Medicine Alexander von Humboldt, Universidad Peruana Cayetano Heredia, Lima, Peru, E-mails: braulio.valencia@upch.pe and elmer.llanos@upch.pe. Milena Alba, Vanessa Adai, and Jorge Arevalo, Departamento de Bioquímica, Biología Molecular y Farmacología, Facultad de Ciencias, Universidad Peruana Cayetano Heredia, Lima, Peru, E-mails: milenacollado@yahoo.es, vanessa.adaui@upch.pe, and biomoljazz@gmail.com. Andrea K. Boggild, Tropical Disease Unit, UHN-Toronto General Hospital, Toronto, Ontario, Canada, E-mail: andrea.boggild@utoronto.ca.

## REFERENCES

- Lucas CM, Franke ED, Cachay MI, Tejada A, Cruz ME, Kreutzer RD, Barker DC, McCann SH, Watts DM, 1998. Geographic distribution and clinical description of leishmaniasis cases in Peru. *Am J Trop Med Hyg* 59: 312–317.
- Reithinger R, Dujardin JC, Louzir H, Pirmez C, Alexander B, Brooker S, 2007. Cutaneous leishmaniasis. *Lancet Infect Dis* 7: 581–596.
- David CV, Craft N, 2009. Cutaneous and mucocutaneous leishmaniasis. *Derm Ther* 22: 491–502.
- Santrich C, Segura I, Arias AL, Saravia NG, 1990. Mucosal disease caused by *Leishmania braziliensis guyanensis*. *Am J Trop Med Hyg* 42: 51–55.
- Osorio LE, Castillo CM, Ochoa MT, 1998. Mucosal leishmaniasis due to *Leishmania (Viannia) panamensis* in Colombia: clinical characteristics. *Am J Trop Med Hyg* 59: 49–52.



6. Arevalo J, Ramirez L, Adauí V, Zimic M, Tulliano G, Miranda-Verástegui C, Lazo M, Loayza-Muro R, De Doncker S, Maurer A, Chappuis F, Dujardin JC, Llanos-Cuentas A, 2007. Influence of *Leishmania* (*Viannia*) species on the response to antimonial treatment in patients with American tegumentary leishmaniasis. *J Infect Dis* 195: 1846–1851.
7. Pan American Health Organization, Peru. *Resumen del Analisis de Situacion y Tendencias de Salud*. Available at: [http://www.paho.org/spanish/dd/ais/cp\\_604.htm](http://www.paho.org/spanish/dd/ais/cp_604.htm). Accessed April 23, 2012.
8. Silveira FT, Lainson R, Shaw JJ, Ribeiro R, 1984. Cutaneous leishmaniasis in Amazonia. Report of the 1st human case of mixed infection, determined by 2 different *Leishmania* species: *Leishmania brasiliensis* and *Leishmania mexicana amazonensis*. *Rev Inst Med Trop Sao Paulo* 26: 272–275.
9. Oliveira Neto MP, Marzochi MCA, Grimaldi G, Pacheco RS, Toledo LM, Momen H, 1985. Concurrent human infection with *Leishmania donovani* and *Leishmania braziliensis braziliensis*. *Ann Trop Med Parasitol* 80: 587–592.
10. Hernandez-Montes O, Monroy-Ostria A, McCann S, Barker DC, 1998. Identification of Mexican *Leishmania* species by analysis of PCR amplified DNA. *Acta Trop* 71: 139–153.
11. Martinez E, Mollinedo S, Torrez M, Munoz M, Banuls A-L, Le Pont F, 2002. Co-infection by *Leishmania amazonensis* and *L. infantum/L. chagasi* in a case of diffuse cutaneous leishmaniasis in Bolivia. *Trans R Soc Trop Med Hyg* 96: 529–532.
12. Aldiwany LJ, Alawakati NA, Atia M, Rassam MB, 1995. Concomitant natural infection with *L. donovani* and *L. major*: a case report from Iraq. *Soz Praventivmed* 40: 234–238.
13. Ibrahim ME, Smyth AJ, Ali MH, Barker DC, Kharazmi A, 1994. The polymerase chain reaction can reveal the occurrence of naturally mixed infections with *Leishmania* parasites. *Acta Trop* 57: 327–332.
14. Bastrenta B, Mita N, Buitrago R, Vargas F, Flores M, Machane M, Yacsik N, Torrez M, Le Pont F, Brenière F, 2003. Human mixed infections of *Leishmania* spp. and *Leishmania-Trypanosoma cruzi* in a sub Andean Bolivian area: identification by polymerase chain reaction/hybridization and isoenzyme. *Mem Inst Oswaldo Cruz* 98: 255–264.
15. Boggild AK, Pilar Ramos A, Veland N, Valencia BM, Calderon F, Arevalo J, Low DE, Llanos-Cuentas A, 2011. Diagnostic performance of filter paper lesion impression PCR in both secondarily infected ulcers and non-ulcerative lesions caused by cutaneous leishmaniasis. *J Clin Microbiol* 49: 1097–1100.
16. Boggild AK, Valencia BM, Espinosa D, Veland N, Pilar Ramos A, Arevalo J, Llanos-Cuentas A, Low DE, 2010. Detection and species identification of *Leishmania* kDNA from filter-paper lesion impressions for patients with American cutaneous leishmaniasis. *Clin Infect Dis* 50: e1–e6.
17. Veland N, Boggild AK, Valencia C, Valencia BM, Llanos-Cuentas A, Van der Auwera G, Dujardin JC, Arevalo J, 2012. *Leishmania* (*Viannia*) species identification in clinical samples from cutaneous leishmaniasis in Peru: assessment of a molecular step-wise approach. *J Clin Microbiol* 50: 495–498.
18. Croft SL, Sundar S, Fairlamb AH, 2006. Drug resistance in leishmaniasis. *Clin Microbiol Rev* 19: 111–126.
19. Yardley V, Ortuño N, Llanos-Cuentas A, Chappuis F, Doncker SD, Ramirez L, Croft S, Arevalo J, Adauí V, Bermudez H, Decuyper S, Dujardin JC, 2006. American tegumentary leishmaniasis: is antimonial treatment outcome related to parasite drug susceptibility? *J Infect Dis* 194: 1168–1175.
20. Yardley V, Croft SL, De Doncker S, Dujardin JC, Koirala S, Rijal S, Miranda C, Llanos-Cuentas A, Chappuis F, 2005. The sensitivity of clinical isolates of *Leishmania* from Peru and Nepal to miltefosine. *Am J Trop Med Hyg* 73: 272–275.
21. Kaye P, Scott P, 2011. Leishmaniasis: complexity at the host-pathogen interface. *Nat Rev Microbiol* 9: 604–615.
22. Osorio Y, Gonzalez SJ, Gama VL, Travi BL, 1998. Reinfection in American cutaneous leishmaniasis: evaluation of clinical outcomes in the hamster model. *Mem Inst Oswaldo Cruz* 93: 353–356.
23. Pérez H, Arredondo B, Machado R, 1979. *Leishmania mexicana* and *Leishmania tropica*: cross immunity in C57BL/6 mice. *Exp Parasitol* 48: 9–14.
24. Abdullah SM, Flath B, Presber W, 1998. Mixed infection of human U-937 cells by two different species of *Leishmania*. *Am J Trop Med Hyg* 59: 182–188.
25. Aebischer T, 1994. Recurrent cutaneous leishmaniasis: a role for persistent parasites? *Parasitol Today* 10: 25–28.
26. Killick-Kendrick R, Bryceson AD, Peters W, Evans DA, Leaney AJ, Rioux JA, 1985. Zoonotic cutaneous leishmaniasis in Saudi Arabia: lesions healing naturally in man followed by second infection with the same zymodeme of *Leishmania major*. *Trans R Soc Trop Med Hyg* 79: 363–365.
27. Correa JR, Brazil RP, Soares MJ, 2005. *Leishmania* (*Viannia*) *lainsoni* (Kinetoplastida: Trypanosomatidae), a divergent *Leishmania* of the *Viannia* subgenus: a mini review. *Mem Inst Oswaldo Cruz* 100: 587–592.
28. Martinez E, Le Pont F, Mollinedo S, Cupolillo E, 2001. A first case of cutaneous leishmaniasis due to *Leishmania* (*Viannia*) *lainsoni* in Bolivia. *Trans R Soc Trop Med Hyg* 95: 375–377.
29. Lucas CM, Franke ED, Cachay MI, Tejada A, Carrizales D, Kreutzer RD, 1994. *Leishmania* (*Viannia*) *lainsoni*: first isolation in Peru. *Am J Trop Med Hyg* 51: 533–537.