

J. Alfaro-Adrian · H.S. Gill · B.E. Marks
D.W. Murray

Mid-term migration of a cemented total hip replacement assessed by radiostereometric analysis

Accepted: 17 May 1999

Abstract We have previously reported the short-term migration of cemented Hinek femoral components using radiostereometric analysis (RSA). We now report the mid-term migration. During the first 2 years after implantation the prosthesis subsided into varus and rotated internally. Between years 3 and 8 the prosthesis continued to rotate internally with the head moving posteriorly (0.07 mm/year, $P=0.004$). It also continued to fall into varus with the tip moving laterally (0.07 mm/year, $P=0.04$). The head (0.06 mm/year, $P<0.0001$), shoulder (0.04 mm/year, $P=0.0001$) and tip (0.04 mm/year, $P=0.001$) continued to migrate distally. There were two cases of failure due to aseptic loosening during the follow-up period. During the second year both of these had posterior head migration, which was abnormally rapid (>2 SD from the mean). We have demonstrated that a cemented implant has slow but significant levels of migration and rotation for at least 8 years after implantation. Our study confirms that implants with abnormally rapid posterior head migration during the second year are likely to fail.

Résumé Nous avons récemment étudié la migration à court terme des composants cimentés Hinek en utilisant l'analyse radiostéréométrique (RSA). Nous atteignons maintenant un recul de 3 à 8 ans. Entre la 3^{ème} et la 8^{ème} année, il est évident que la prothèse continue une rotation interne avec la tête, elle-même en mouvement postérieur (0.07 mm/an, $P=0.004$). La prothèse a continué de progresser en varus, le bout migrant latéralement (0.07 mm/an, $P=0.07$). La tête (0.06 mm/an, $P<0.0001$), l'épaule (0.04 mm/an, $P=0.001$) et le bout (0.04 mm/an, $P=0.001$) ont continué de migrer distalement. Il y a eu deux cas d'échec pendant la période qui suivit, les deux présentant une migration anormalement élevée pendant la deuxième année. Dans les deux cas, une anomalie majeure était une rapide migration postérieure de la tête. Nous

avons démontré que l'implant cimenté présente des niveaux de migration et rotation lents mais significatifs pendant au moins 8 ans après l'implantation. Nos études confirment que des implants qui ont une migration postérieure de la tête anormalement rapide pendant la deuxième année présentent un plus grand risque d'échec précoce.

Introduction

Migration measurements are the only early method of assessment of total hip replacement (THR) that have been shown to correlate with early failure [4,11,12,15]. Femoral component migration is a complex combination of translation and rotation in three dimensions that can only be measured accurately by radiostereometric analysis (RSA). For satisfactory primary implants there is rapid migration during the first year, which then slows [8,9,13]. Implants that have failed because of aseptic loosening have been shown to migrate rapidly after the early phase [6,7]. It has been concluded, therefore, that implants with continuing rapid migration are likely to fail [14]. However, there is little detailed information about the long-term three-dimensional (3D) pattern of migration and rotation for cemented femoral stems and about its clinical significance.

The Hinek prosthesis is made of titanium and its surface is matt proximally and polished distally. The implant is designed so as not to sink within the cement mantle and also to allow neck preservation in order to resist rotation [3]. It has a prominent shoulder that extends up to the greater trochanter. We have reviewed our clinical results for the Hinek and find that the survival rate is 95% at 7 years. In a previous short-term RSA study [9] we demonstrated that during the first year after implantation the cemented Hinek femoral component subsided, tilted into varus and rotated internally. Subsequently there was slow distal migration of the femoral stem.

The aim of this study was to determine the medium-term migration pattern of the Hinek cemented femoral component and to compare this with the previously pub-

lished reports on migration of this implant during the first and second year.

Patients and methods

In our previously published [9] short-term migration study of the Hinek cemented femoral component (Corin Medical, Cirencester, UK) there were 58 hips. Fifteen of these have been studied with RSA from 3 to 8 years after operation and are currently asymptomatic. In addition two hips that failed due to aseptic loosening were studied.

All the patients had osteoarthritis (OA) of the hip and had the THR implanted through an anterolateral approach to the hip. Stem centralisers were not used. Patients were mobilized fully weight bearing as soon as possible after the operation. At each RSA examination a clinical questionnaire was completed.

Our new RSA system is reliable, accurate and user-friendly and has been described by Gill et al. [5] and Alfaro-Adrian et al. [2]. It is based on the earlier system described by Kiss [10].

At the time of surgery, 1 mm stainless steel marker balls were placed into the bone in the greater trochanter, lesser trochanter and distal to the tip of the prosthesis. Stereo RSA X-rays were taken with the patients standing fully weight bearing within a calibration frame. The position in 3D of the X-ray tubes and films is determined from the image of the calibration cage on the X-rays. The position of the implants and the marker balls inserted in the bone were then calculated. To determine the migration of the implant at least two sets of stereo X-ray pairs were analyzed. Migration of the center of the head, the shoulder, the tip and the center of the implant were determined. The shoulder is a virtual point defined as the point of intersection of the stem axis, and a perpendicular to this passing through the head. The center of the implant was defined as the centroid of head, shoulder and tip. Movement of the component was converted to an axis system defined by the implant, with proximal/distal (z axis) in the direction of the stem axis, medio/lateral (y axis) in the direction of a line drawn from head to shoulder, and anterior/posterior (x axis) perpendicular to the other axes. The accuracy of the system has been described previously [2]. Migration and rotation rates were calculated by linear regression. Student's *t*-test was used for statistical analysis.

Results

A comparison of the migration rate during the first year, the second year and between years 3 to 8 is shown in Figs. 1–3 and in Table 1.

The migration of the implant continued slowly between years 3 and 8. There was significant distal migration at all landmarks. Distal migration at the center of the implant was 0.05 mm/year (SE 0.01, $P < 0.001$), at the head it was 0.06 mm/year ($P < 0.0001$), at the shoulder it was 0.04 mm/year ($P = 0.001$) and at the tip it was 0.04 mm/year (SE 0.01, $P = 0.001$). The distal migration of the center of the prosthesis between years 3 to 8 was 6 times slower than that during the first year after implantation and 3 times slower than that during the second year. The prosthesis orientation continued to change during years 3 to 8. The stem rotated internally 0.17 degrees/year (SE 0.04, $P < 0.001$). This was associated with posterior head migration of 0.07 mm/year (SE 0.02, $P = 0.004$). Internal rotation was 7 times slower than that during the first year. The prosthesis rotated significantly

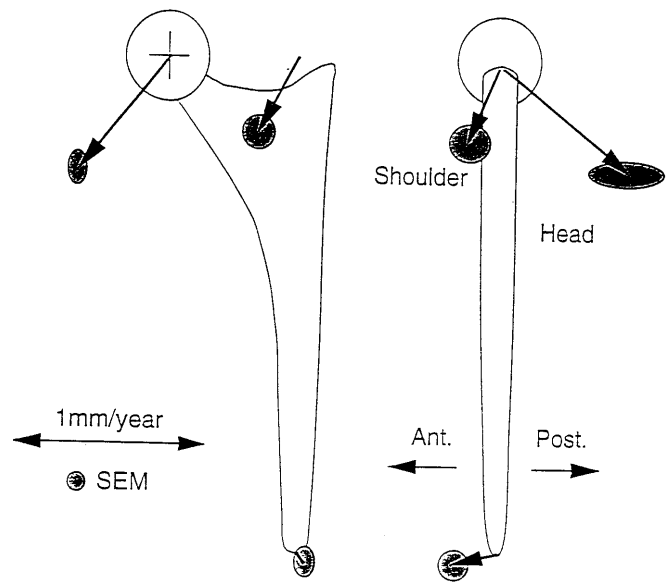


Fig. 1 Migration of the Hinek prosthesis during the first year. Migration rates and directions at various landmarks are shown by arrows. The length of the arrow represents the migration rate and the scale for this is also shown. Shaded areas represent the standard error

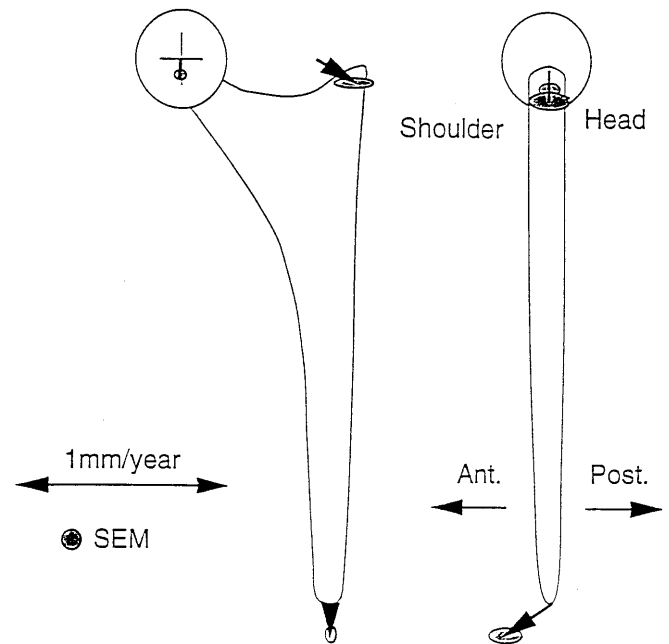


Fig. 2 Migration of the Hinek prosthesis after the first year. Migration rates and directions at various landmarks are shown by arrows. The length of the arrow represents the migration rate and the scale for this is also shown. Shaded areas represent the standard error (SE)

into varus (0.03 degrees/year, SE 0.01, $P = 0.01$). This was associated with significant lateral migration of the tip (0.07 mm/year, SE 0.03, $P = 0.04$). However, the head did not migrate significantly medially (0.002 mm/year, SE 0.02, $P = 0.9$).

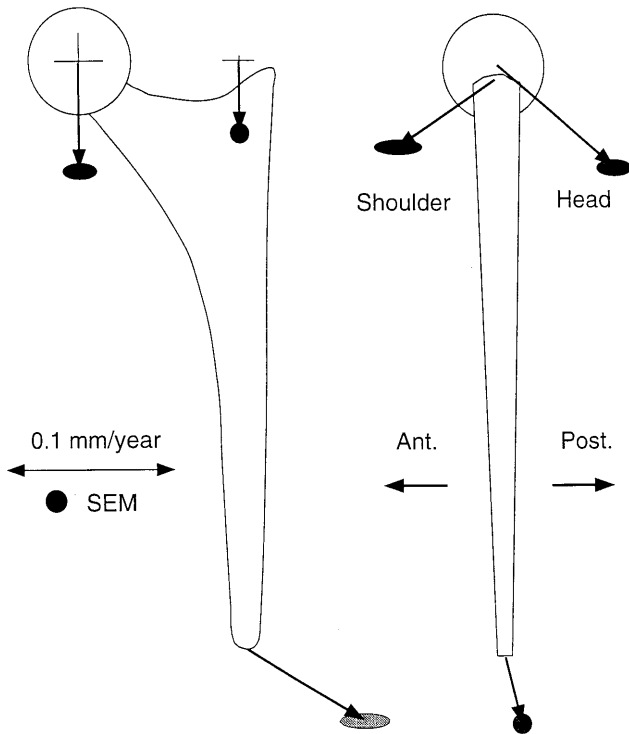


Fig. 3 Migration of the Hinek prosthesis between years 3 and 8. Migration rates and directions at various landmarks are shown by arrows. The length of the arrow represents the migration rate and the scale for this is also shown. The scale is about 10 times larger than in Figs. 1 and 2. Shaded areas represent the standard error (SE)

Table 1 Migration rate (mm/year mean \pm SEM) and rotation rate ($^{\circ}$ /year) for 3 landmarks and the center of the Hinek prosthesis during years 1, 1–2 and 3–8. The significance of the 3–8 year migration is also given. Overall migration is calculated as the square root of the sum of the square values of x , y and z

Landmark	Year 1	Years 1–2	Years 3–8	Significance (Pvalue)
Head				
Anterior (x)	-0.61 ± 0.43	0.001 ± 0.11	-0.07 ± 0.02	0.004
Medial (y)	0.48 ± 0.10	0.01 ± 0.04	0.002 ± 0.02	0.9
Proximal (z)	-0.54 ± 0.16	-0.09 ± 0.04	-0.06 ± 0.01	<0.0001
Overall migration	0.94	0.09	0.09	
Shoulder				
Anterior (x)	0.16 ± 0.23	0.005 ± 0.18	0.06 ± 0.03	0.07
Medial (y)	0.20 ± 0.17	-0.19 ± 0.14	-0.003 ± 0.01	0.8
Proximal (z)	-0.39 ± 0.18	-0.12 ± 0.06	-0.04 ± 0.01	0.001
Overall migration	0.47	0.22	0.07	
Tip				
Anterior (x)	0.13 ± 0.43	-0.23 ± 0.14	-0.01 ± 0.01	0.3
Medial (y)	-0.05 ± 0.11	0.01 ± 0.05	-0.07 ± 0.03	0.04
Proximal (z)	-0.29 ± 0.15	-0.15 ± 0.05	-0.04 ± 0.01	0.001
Overall migration	0.37	0.37	0.08	
Center				
Anterior (x)	-0.10 ± 0.18	-0.08 ± 0.07	-0.01 ± 0.01	0.3
Medial (y)	0.21 ± 0.08	-0.06 ± 0.05	-0.02 ± 0.02	0.3
Proximal (z)	-0.29 ± 0.15	-0.12 ± 0.04	-0.05 ± 0.01	<0.001
Overall migration	0.37	0.15	0.05	
Rotation				
Anterior	-0.10 ± 0.14	0.10 ± 0.08	0.02 ± 0.01	0.07
Valgus	0.32 ± 0.12	-0.02 ± 0.04	-0.03 ± 0.01	0.01
Internal	1.17 ± 0.69	0.20 ± 0.29	0.17 ± 0.04	<0.001
Overall rotation	1.22	0.22	0.17	

Two of the Hinek prostheses failed during the follow-up period. At the time of revision, both femoral components were found to be loose and frozen section showed no evidence of infection. One failed at 4 years (45 months): it migrated distally at a rate of about 4.0 mm/year and, in addition, it rapidly rotated internally with the head migrating posteriorly at a rate of 2.1 mm/year. The other failed at 9 years: it migrated distally at a rate of 0.63 mm/year and, in addition, it rapidly rotated internally with the head migrating posteriorly at a rate of 1.7 mm/year (Fig. 4).

We have defined the normal range of migration as mean \pm 2SD. The normal range of migration rates for the Hinek during year 2 and the migration rates for the two failures are shown in Table 2. During year 2, the first failure had very abnormal distal migration, posterior head migration and lateral head migration. The second failure only had abnormal posterior head migration. During the first year only the implant that failed at 4 years had abnormal migration. Both had abnormal migration between years 3 and 8.

Discussion

The rate and pattern of migration of an implant change with time. We have demonstrated that migration of the Hinek stem continues at a slow but significant rate between years 3 and 8 following operation, with the average migration rate being about 0.1 mm/year.

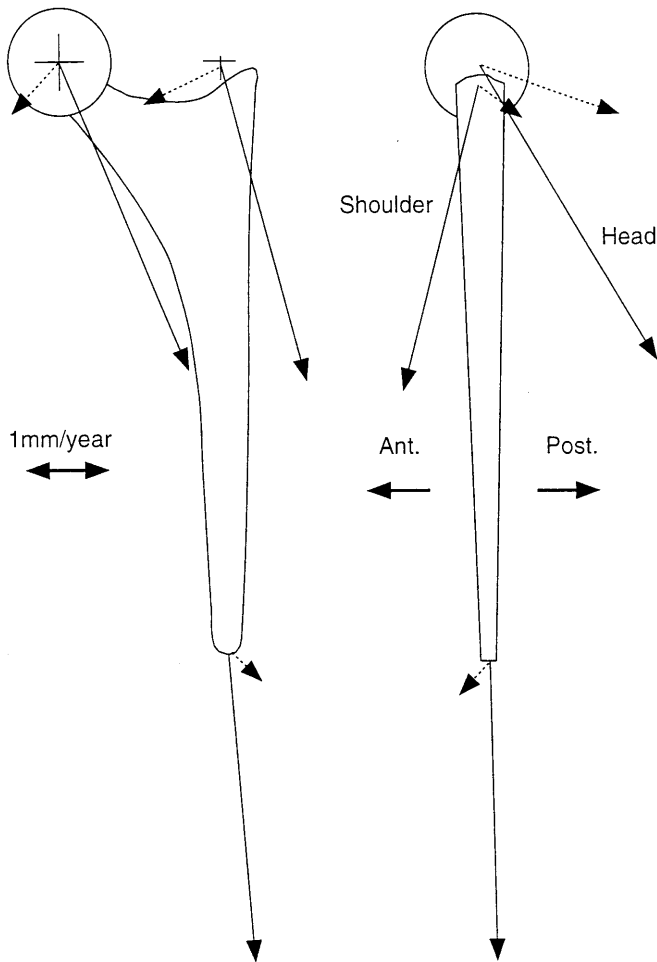


Fig. 4 Hinek failures. Migration rate (mm/year), $n=2$

Implant migration is usually rapid during the first year, after which it slows down [9]. We found that the migration rate was 6 or 7 times faster during the first year than during the third to eighth year. Although the migration rates decreased with time the pattern of migration remained the same: associated with distal migration there was internal rotation with posterior head migration and varus rotation with lateral tip migration. We are not aware of any long-term migration data on other implants with which to compare the Hinek. It is of interest, however, that the Hinek collapses into varus with the tip migrating laterally, whereas we have previously shown that the Charnley Elite and Exeter collapse into valgus with medial tip migration [1]. This difference is probably due to the high shoulder of the Hinek that prevents it from sliding over the calcar into valgus.

Two of the Hinek prostheses followed with RSA failed. The first at 4 years and the second at 9 years. The former had abnormally fast migration during the first year, and both had abnormally (>2 SD from mean) fast posterior head migration during the second year (Table 2). This suggests that although some failures can be detected in the first year, the majority will be detected during the second year. In order to predict the failures at

Table 2 Range of normal migration rates (mean \pm 2SD) for satisfactory implants during year 2 compared the mean migration rate (mm/year) of the 2 failed implants

	Satisfactory implants		Failed implants	
	Mean+2SD	Mean-2SD	Year 4 failure	Year 9 failure
Head				
Anterior (x)	1.5	-1.5	-2.1	-1.7
Medial (y)	0.6	-0.6	-1.5	0.6
Proximal (z)	0.5	-0.6	-3.4	-0.6
Shoulder				
Anterior (x)	2.5	-2.5	0.9	-0.4
Medial (y)	1.8	-2.0	-1.0	0.8
Proximal (z)	0.7	-0.8	-3.6	-0.3
Tip				
Anterior (x)	1.7	-2.0	0.2	0.3
Medial (y)	0.7	-0.7	-0.3	-0.3
Proximal (z)	0.6	-0.7	-3.6	-0.3

2 years, it is necessary to measure posterior head migration. An RSA system is therefore essential as it is impossible to measure posterior migration with uniplanar X-rays. Posterior head migration appears to be one of the important factors leading to loosening. It is induced by large posteriorly directed loads acting on the femoral head during activities such as getting out of a chair or climbing stairs. The Hinek prosthesis, which retains the femoral neck and has a high shoulder, is particularly resistant to rotation. This suggests that this type of failure may be more common with other implants.

Our study demonstrates that for cemented femoral implants slow migration continues up to 8 years. Internal rotation with posterior head migration is likely to be an important cause of failure. Assessment of posterior head migration during the second year is useful; implants with abnormally large posterior head migration at this stage are likely to fail early.

References

- Alfaro-Adrian J, Gill HS, Marks B, Murray DW (1998) Migration of cemented Charnley and Exeter femoral components. An RSA study. *J Bone Joint Surg [Br]* 80:270
- Alfaro-Adrian J, Gill HS, Murray DW (1999) Cement migration after THR. A comparison of Charnley Elite and Exeter femoral stems using RSA. *J Bone Joint Surg [Br]* 81:130-134
- Freeman MAR (1986) Why resect the neck? *J Bone Joint Surg [Br]* 68:346-349
- Freeman MAR, Plante-Bordeneuve P (1994) Early migration and late aseptic failure of proximal femoral prostheses. *J Bone Joint Surg [Br]* 76:432-438
- Gill HS, Alfaro J, Murray DW, Marks B (1998) A new hybrid video/digitiser based roentgen stereometric measurement system. *J Biomech* 31:88
- Karrholm J, Borsen B, Lowenhielm G, Snorrason F (1994) Does early micromotion of femoral stems prostheses matter? 4-7 year stereoradiographic follow-up of 84 cemented prostheses. *J Bone Joint Surg [Br]* 76:912-916

7. Kärrholm J, Borssén B, Löwenhielm G, Snorrason F (1994) Does early micromotion of femoral stems prostheses matter? 4-7 year stereoradiographic follow-up of 84 cemented prostheses. *J Bone Joint Surg [Br]* 76-B:912-916
8. Kärrholm J, Snorrason F (1993) Subsidence, tip and hump micromovements of noncoated ribbed femoral prostheses. *Clin Orthop* 287:50-60
9. Kiss J, Murray DW, Turner-Smith AR, Bulstrode CJ (1995) Roentgen stereophotogrammetry analysis for assessing migration of total hip replacement femoral components. *J Engin Med* 209:169-175
10. Kiss J, Murray DW, Turner-Smith AR, Bithell J, Bulstrode CJ (1996) Migration of cemented femoral components after THR. Roentgen stereophotogrammetry analysis. *J Bone Joint Surg [Br]* 78-B:796-801
11. Mjoberg B, Hansson LI, Selvik G (1984) Instability, migration and laxity of total hip prosthesis. *Acta Orthop Scand* 55:141-145
12. Mjoberg B, Hansson LI, Selvik G (1984) Instability of total hip prosthesis at rotational stress. *Acta Orthop Scand* 55:504-506
13. Mjoberg B, Selvik G, Hansson LI, Onnerfalt R (1986) Mechanical loosening of total hip prosthesis. A radiographic and roentgen stereophotogrammetric study. *J Bone Joint Surg [Br]* 68:770-774
14. Nistor L, Blaha JD, Kjellstrom U, Selvik G (1991) In vivo measurements of relative motion between an uncemented femoral total hip component and the femur by roentgen stereophotogrammetric analysis. *Clin Orthop* 269:220-227
15. Walker PS, Mai SF, Cobb AG, Bentley G, Hua J (1995) Prediction of clinical outcome of THR from migration measurements on standard radiographs. A study of cemented Charnley and Stanmore femoral stems. *J Bone Joint Surg [Br]* 77:347-366