

ORIGINAL PAPER

D. Weber · D.L. Pomeroy · L.A. Schaper
 W.E. Badenhausen Jr · J.I. Curry · M.W. Smith
 K.E. Suthers

Supracondylar nailing of distal periprosthetic femoral fractures

Accepted: 7 December 1999

Abstract Seven patients who sustained complex distal femoral fractures above total knee arthroplasties all treated by supracondylar (retrograde) femoral nailing were retrospectively evaluated. All the patients demonstrated uncomplicated postoperative follow-ups and returned to weight bearing between 2 and 3 months after surgery. No delayed healing occurred and alignment of the femur was satisfactory.

Résumé Nous avons réalisé une étude rétrospective comprenant sept fractures periprotétiques complexes du fémur distal chez sept porteurs de PTG. Toutes les fractures ont été traitées par enclouage rétrograde du fémur. L'évolution post-opératoire et la rééducation à la marche étaient sans particularités chez tous les patients. Toutes les fractures ont consolidés sans problèmes avec un bon alignement.

Introduction

Distal femoral fractures proximal to knee arthroplasties are rare. The reported incidence ranges from 0.3 to 2.5% [1,5,11]. The treatment of these fractures remains controversial. Conservative treatment, generally used for non-displaced, more stable fractures, is very demanding for both patient and physician [4,5,7,8,17]; whereas, open reduction and internal fixation is often the preferred

No benefits in any form have been received or will be received from a commercial party related directly or indirectly to the subject of this article.

D. Weber (✉)

Clinic of Orthopaedic Surgery and Traumatology, University Hospital, Rue Micheli-du-Crest 24, 1211 Geneva, Switzerland
 e-mail: danielweber61@hotmail.com
 Tel.: +41-22-3723311, Fax: +41-22-3727799

D.L. Pomeroy · L.A. Schaper · W.E. Badenhausen Jr · J.I. Curry
 M.W. Smith · K.E. Suthers
 The Louisville Institute for Joint Replacement and
 The Arthroplasty Foundation, 234 East Gray Street, Suite 332,
 Louisville 40202, KY, USA

method in displaced and comminuted (unstable) fractures [1,2,5,9,11,20]. This modality allows for early mobilization of patients and reduces, theoretically, the potential risks of prolonged rest. However, surgical treatment does not reduce the reported [5] overall complication rate (30%). The results are similar for the surgical and non-surgical treatment of displaced and/or comminuted fractures as demonstrated in a literature review by Chen et al. [5]. More recent studies (only partially included in Chen's review) demonstrate excellent results [13,14,15,18] and lower morbidity rates. The purpose of this study is to present our results of supracondylar nailing in distal femoral periprosthetic fractures.

Subjects and methods

Seven patients presented with seven distal femoral supracondylar (unstable) fractures and were treated surgically in our institution between February 1994 and January 1999. All the implants were low-constrained, posterior cruciate preserving total knee arthroplasties. All but one femoral component was cemented. All components appeared stable at the time of fracture. There were six females and one male, ranging in age from 65 to 90 years (mean 75 years). The primary diagnosis for the knee procedure was osteoarthritis in 5 cases, rheumatoid arthritis in 1 and psoriatic arthritis in another case. One knee had been revised 1 year prior to the fracture for patellar loosening. Other co-morbidities included chronic alcohol abuse, coronary vascular insufficiency, cerebral vascular insufficiency and emphysema. The average time from the primary joint replacement to fracture ranged from 2 to 114 months (mean 67 months). One patient sustained an intraoperative, incomplete fracture (fissure) at the time of joint implantation. The fracture displaced at 2 months and was reported as an early complication. All fractures were the result of low velocity trauma.

All fractures were classified as type II according to the classification by Chen et al. [5], to include any displaced and/or comminuted fracture, with or without malalignment. No notching of the anterior femoral cortex was observed. The knee fractures were approached either through a short midline incision with a trans-patellar ligament approach or the initial standard midline incision. Fracture reduction was achieved under fluoroscopic control and a GSH supracondylar femoral nail (Smith and Nephew Richards, Memphis, Tennessee, USA) was introduced. After correct alignment was achieved, the position of the two main fragments was locked by 2 proximal and 2 distal screws.

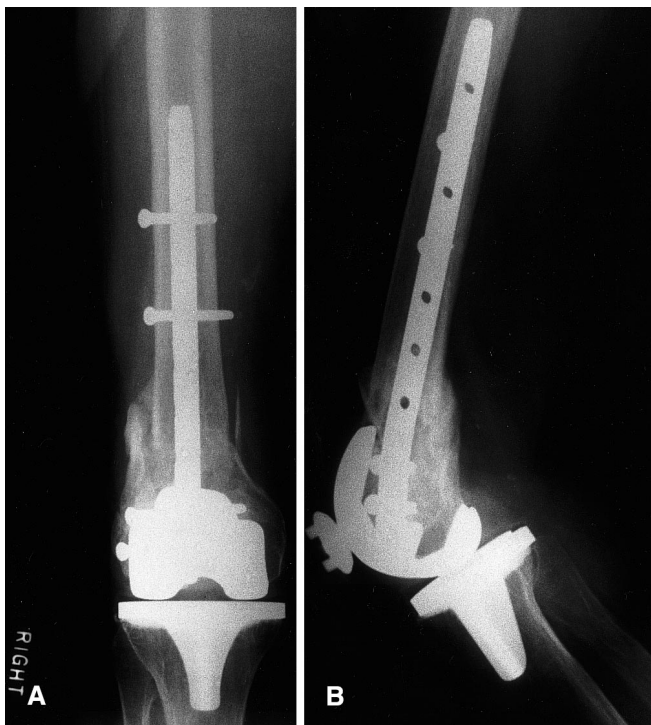


Fig. 1A,B Distal femoral periprosthetic fracture in a 78-year-old female patient. **A.** anteroposterior and **B.** lateral radiographs at 6 months after supracondylar nailing. The fracture has healed in good alignment

In the early post-operative period, patients were immobilized in a simple removable splint until straight leg raise was possible. Active and active-assisted mobilization was started the second post-operative day. Partial weight bearing with half body weight was allowed at 4–6 weeks and full weight bearing at 8–12 weeks in six cases. One patient returned to full weight bearing at 16 weeks post-surgery.

All patients underwent clinical and radiological evaluation. The follow-up period was from 6 to 56 months (mean 2.5 years). Alignment of the knee joint as well as fracture consolidation were measured on antero-posterior and lateral radiographs. Knee mobility with respect to the pre-fracture status and patient satisfaction with the procedure were assessed. The patients were also analyzed using Chen's scoring system [5], which classifies the results as good when the fracture is healed, alignment is almost anatomic and clinical function is comparable to pre-fracture status and the patient is satisfied.

Results

Six of the seven fractures (Fig. 1) healed within 3 months after retrograde nailing. One fracture was displaced 2 mm laterally without disturbing the healing process. The alignment of the remaining fractures was almost anatomic. Two patients demonstrated 10–15% loss of flexion at follow-up. One of these patients was debilitated and was non-ambulatory before fracture and the other patient showed a range of motion of flexion/extension 85/0/0, which was rated as good. All the other patients had at least 90° of motion. No postoperative complications such as deep venous thrombosis or infections oc-

curred. Six of the seven patients were satisfied and the one debilitated patient seemed satisfied with the result of the procedure. According to Chen's scoring system [5], all patients had a satisfactory result.

Discussion

Supracondylar, periprosthetic fractures of the distal femur are rare and their treatment has always been controversial [5,17], especially for displaced and comminuted fractures. For the more stable type I fractures (non- or minimally displaced), a conservative approach is generally accepted and gives good results. However, conservative fracture management is very demanding for both patient and physician and complications due to immobilization such as muscle wasting, infections, thromboembolism, psychological disorders and extended time to union may occur [5,9,13].

The discussion is still open, however, concerning operative versus non-operative treatment for unstable, comminuted and or displaced fractures [9]. In 1994 Chen et al. published the most recent comprehensive review of the English literature [5] dealing with the problem of periprosthetic distal femoral fractures. They reported a successful outcome of 67% for the conservatively managed and 61% for surgically treated type II (comminuted and/or displaced) fractures. The two groups showed the same total complication rates of 30% (infection, malunion, nonunion). However, infections were more frequently sited in the operative group.

Many techniques of surgical treatment are available. These include stabilization with buttress plates, condylar blade-plates, dynamic compression plates, external fixation, intramedullary nailing and revision arthroplasty with and without allograft and massive prostheses [2,3,5,6,9,11,12,16,19,20]. Most of the published series dealing with surgical treatment options present open techniques with utilization of plates. Use of intramedullary, supracondylar nails has been reported only sporadically, e.g. Brooker-Wills intramedullary nail (Biomet, Warsaw, Ind., USA) until the beginning of the 1990s [10]. In 1990 the intramedullary supracondylar nail (Smith and Nephew Richard) was introduced. McLaren et al. [14] published in 1994 a series of seven periprosthetic fractures treated with this device. The results were satisfactory for all 7 patients. The outcome of the supracondylar nailing technique demonstrated a 33% improvement of good results when compared to the treatment by „standard“ open reduction internal fixation according to McLaren's literature research [14]. This review included 63 cases of open reduction internal fixation, 6 cases of external fixation, 25 long-stem revision cases and only 6 cases of intramedullary nailing. Other authors have reported similar good results adapting this technique since this publication in 1994 [15,18]. Maniar [13] reports that even in the unique case of a posterior cruciate-substituting total knee arthroplasty, a „retrograde“ nail can be inserted after enlarging the aperture

for insertion of an intramedullary nail by a metal cutting burr.

Our own series of 7 patients, presenting with 7 supracondylar, periprosthetic distal femoral fractures, treated with a supracondylar intramedullary nail, demonstrates good results in all patients. No postoperative complication was observed, all fractures healed uneventfully in good alignment and the patients returned to weight bearing after 3 to 4 months. These results are superior to the reported overall results for operative treatment of type II fractures in the literature review by Chen et al. The advantage of this surgical approach is minimized trauma to the soft tissues around the fracture site and the preservation of the remaining blood supply to the distal femur; thus, favoring healing of the fracture and soft tissues.

We conclude that supracondylar fractures above total knee arthroplasties present a challenge for the orthopaedic surgeon. The supracondylar nail, offers advantages over the non-operative course of treatment as well as the traditional open reduction internal fixation as demonstrated by this and previous studies. However, the surgeon must match the size of the notch of the femoral component and the intramedullary nail before the above described technique is used.

Acknowledgements This work was supported by a grant from the Swiss Society of Orthopaedic Surgeons.

References

1. Ayers DC, Dennis DA, Johanson NA, Pellegrini Jr. VD (1997) Common complications of total knee arthroplasty. *J Bone Joint Surg [Am]* 79:278–311
2. Anderson SP, Matthews LS, Kaufer H (1990) Treatment of juxtaarticular nonunion fractures at the knee with long-stem total knee arthroplasty. *Clin Orthop* 260:104–109
3. Biswas SP, Kurer MH, Mackenney RP (1992) External fixation for femoral shaft fracture after Stanmore total knee replacement. *J Bone Joint Surg [Br]* 74:313–314
4. Cain PR, Rubash HE, Wissinger HA, McClain EJ (1986) Periprosthetic femoral fractures following total knee arthroplasty. *Clin Orthop* 208:205–214
5. Chen F, Mont MA, Bachner RS (1994) Management of ipsilateral supracondylar femur fractures following total knee arthroplasty. *J Arthroplasty* 9:521–526
6. Cordeiro EN, Costa RC, Carazzato JG, Dos Santos Silva J (1990) Periprosthetic fractures in patients with total knee arthroplasties. *Clin Orthop* 252:182–189
7. Courpied JP, Watin-Augouard L, Postel M (1987) Fractures du femur chez les sujets porteurs de protheses totales de hanche ou de genou. *Int Orthop* 11:109–115
8. DiGioia AM, Rubash HE (1991) Periprosthetic fractures of the femur after total knee arthroplasty. a literature review and treatment algorithm. *Clin Orthop* 271:135–142
9. Figgie MP, Goldberg VM, Figgie HE, Sobel M (1990) The results of treatment of supracondylar fracture above total knee arthroplasty. *J Arthroplasty* 5:267–276
10. Hanks GA, Mathews HH, Routson GW, Loughran TP (1989) Supracondylar fracture of the femur following total knee arthroplasty. *J Arthroplasty* 4:289–292
11. Healy WL, Siliski JM, Incavo SJ (1993) Operative treatment of distal femoral fractures proximal to total knee replacements. *J Bone Joint Surg [Am]* 75:27–34
12. Kraay MJ, Goldberg VM, Figgie MP, Figgie HE (1992) Distal femoral replacement with allograft/prosthetic reconstruction for treatment of supracondylar fractures in patients with total knee arthroplasty. *J Arthroplasty* 7:7–16
13. Maniar RN, Umlas ME, Rodriguez JA, Ranawat CS (1996) Supracondylar femoral fracture above a pfc posterior cruciate-substituting total knee arthroplasty treated with supracondylar nailing. A unique technical problem. *J Arthroplasty* 11:637–639
14. McLaren AC, Dupont JA, Schroeber DC (1994) Open reduction internal fixation of supracondylar fractures above total knee arthroplasties using the intramedullary supracondylar rod. *Clin Orthop* 302:194–198
15. Murrell GA, Nunley JA (1995) Interlocked supracondylar intramedullary nails for supracondylar fractures after total knee arthroplasty. a new treatment method. *J Arthroplasty* 10:37–42
16. Porsch M, Galm R, Hovy L, Starker M, Kerschbaumer F (1996) Totaler Femurersatz nach mehrfachen periprosthetischen Frakturen zwischen ipsilateralem Hueft- und Kniegelenkersatz bei chronischer Polyarthritits. *Z Orthop Ihre Grenzgeb* 134:16–20
17. Sochart DH, Hardinge K (1997) Nonsurgical management of supracondylar fracture above total knee arthroplasty. Still the nineties option. *J Arthroplasty* 12:830–834
18. Smith WJ, Martin SL, Mabrey JD (1996) Use of a supracondylar nail for treatment of a supracondylar fracture of the femur following total knee arthroplasty. *J Arthroplasty* 11:210–213
19. Weber D, Peter RE (1999) Distal femoral fractures after knee arthroplasty. *Int Orthop* 23:236–239
20. Zehntner MK, Ganz R (1993) Internal fixation of supracondylar fractures after condylar total knee arthroplasty. *Clin Orthop* 293:219–224