

K. Shirakura · M. Terauchi · M. Katayama  
H. Watanabe · T. Yamaji · K. Takagishi

## The management of medial ligament tears in patients with combined anterior cruciate and medial ligament lesions

Accepted: 7 December 1999

**Abstract** The management of patients with combined medial collateral (MCL) and anterior cruciate (ACL) rupture remains controversial. We studied 25 such patients who elected to have the ACL lesion treated conservatively; 14 underwent MCL repair with early mobilization and 11 were treated with immobilization for two weeks. The mean follow up was 5.9 years (2 to 11). There was no difference in the clinical assessment of ligamentous laxity, KT-1000 measurements or Tegner activity scores between the two groups but there were significantly higher Lysholm function scores in the operated group.

**Résumé** Le traitement optimal des cas associant des lésions du ligament croisé antérieur (ACL) à des lésions médiales collatérales (MCL) est controversé. Nous avons réalisé une étude sur le suivi du traitement de telles lésions dans le but d'évaluer si le traitement opératoire des déchirures de MCL peut apporter une amélioration des résultats fonctionnels pour des patients choisissant de ne

pas subir une reconstruction de ACL. Notre étude portait sur 14 patients ayant subi une reconstruction du MCL et 11 patients traités sans opération. Nous n'avons pas observé de différences significatives entre les deux groupes pour les tests de relâchement manuel, ni pour les mesures KT-1000, ni pour les niveaux d'activité de Tegner. En revanche les patients du groupe opératoire ont obtenu un meilleur score fonctionnel de Lysholm.

### Introduction

Non-operative management, with early protected movement is the accepted treatment for isolated MCL injury [7]. Early mobilization however may not be recommended when MCL lesions are combined with other ligament injuries, particularly those involving the ACL [1]. Good results have been reported with operative management of ACL ruptures in conjunction with non-operative management of MCL tears [11]. However, quadriceps weakness, extension loss and anterior knee pain are common complications of ACL reconstruction [6], and many patients with ACL lesions may be managed conservatively [2, 3, 11], with secondary reconstruction when required [8]. In combined MCL-ACL injuries surgery to the MCL with non-operative management of the ACL has been advised [5]. Little attention, however has been given to comparing the functional results after operative and non-operative treatment for MCL ruptures in patients with unreconstructed ACL tears. A retrospective study of patients with combined MCL-ACL injuries was therefore undertaken to compare these two groups.

### Material and methods

Between April 1983 and March 1995 the authors performed arthroscopy on 95 consecutive patients with acute ACL tears and the following criteria : 1) the arthroscopy was performed within 2 weeks of injury; 2) there were no posterior cruciate ligament ruptures and 3) there were no bony fragments associated with the ACL rupture. 28 (29%) of the 95 patients had associated MCL in-

K. Shirakura (✉)  
Department of Orthopaedic Surgery,  
Gunma University Faculty of Medicine, 3-39-22 Showa-machi,  
Maebashi-shi, Gunma-ken, Japan 371-8511  
e-mail: kshiraku@akagi.sb.gunma-u.ac.jp;  
Tel: +81 27 220 7111, Fax: +81 27 220 8275

M. Terauchi  
Department of Orthopaedic Surgery,  
Gunma University Faculty of Medicine, Gunma, Japan

M. Katayama  
Division of Orthopaedic Surgery, Gunma University Hospital,  
Gunma, Japan

H. Watanabe  
Department of Orthopaedic Surgery,  
Gunma University Faculty of Medicine, Gunma, Japan

T. Yamaji  
Department of Physical Therapy,  
Gunma University Faculty of Health Sciences, Gunma, Japan

T. Takagishi  
Department of Orthopaedic Surgery,  
Gunma University Faculty of Medicine, Gunma, Japan

**Table 1** Group mean data for the subjects (mean±SD)

	Operated group (n=14)	Non-operated group (n=11)	P-value	
<sup>a</sup> from injury to arthroscopy	Age (years)	30.9±13.7	33.6±10.2	0.580
<sup>b</sup> blood aspirated from the joint at the initial visit to hospital	Duration (days) <sup>a</sup>	7.0±2.7	8.2±3.8	0.342
	Aspiration (ml) <sup>b</sup>	15.2±8.4	26.6±13.7	0.031*
	Follow-up period (months)	67.6±30.1	74.4±33.0	0.597

**Table 2** Data for sex and site and grade of MCL injury (number of cases)

		Operated group (n=14)	Non-operated group (n=11)
Sex	Male	6	3
	Female	8	8
Site <sup>a</sup>	Femoral	11	7
	Tibial	2	2
	Unknown	1	2
Severity <sup>b</sup>	Grade 2	0	4
	Grade 3	14	7

<sup>a</sup> site of MCL tear<sup>b</sup> severity of MCL injury**Table 3** Associated injuries at the initial arthroscopy (number of cases)

Associate injury	Operated group (n=14)	Non-operated group (n=11)
Lateral meniscus	3	3
Lateral meniscus + medial meniscus	3 <sup>a</sup>	0
Lateral meniscus + Segond's fracture	1	2
None	7	6

<sup>a</sup> 2 of the 3 underwent small flap excisions of the lateral meniscus

juries. Two patients were excluded from the study due to their age (>70 years). One patient refused to undergo a follow up examination. The remaining 25 patients were studied.

Aspiration of the joint, plain radiographs and double contrast arthrography, manual laxity tests under anaesthesia and arthroscopy were performed on all patients. All ACL ruptures were confirmed arthroscopically. Valgus instability was graded as: Grade 1 – fully stable at 0° and 30° of flexion; Grade 2 – full stability at 0° of flexion but unstable to valgus stress at 30°; and Grade 3 – unstable to valgus stress at 0° and 30° of flexion. The site of the MCL pathology was identified as femoral or tibial according to the arthroscopic and arthrographic findings. No surgery was performed on the torn ACL. 14 MCL tears were repaired (operated group) and 11 were managed conservatively (non-operated group). The selection for operative or non-operative management depended on the severity of the MCL injury. Grade 3 tears which showed anterior subluxation of the medial tibial plateau during laxity tests under anaesthesia were repaired. Surgery involved suturing of the torn ligament or stapling of an avulsed ligament to bone.

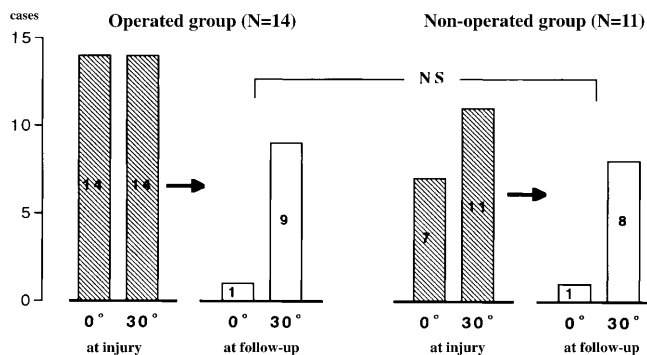
Ten of the operated group and 9 of the non-operated group sustained their injury during sporting activities. The age, time from injury to arthroscopy, amount of aspirate and follow-up details are summarised in Table 1. Sex, site and severity of the MCL injury are shown in Table 2. Other associated injuries are shown in Table 3. Two patients in the operated group who had both lateral and medial meniscal tears underwent small flap excisions of the lateral meniscus. The other meniscal tears were small (<5 mm) and/or partial thickness and did not require surgical treatment. In the operated group continuous passive motion was started immediately post-operatively and increased as tolerated to 90°. A bivalved long-leg cast was worn when the passive motion machine was not in use, and weight bearing allowed at 2 weeks, after which an active exercise programme was instigated with partial weight bearing in a brace. Full weight bearing was permitted at 4 weeks. In the non-operated group the knee was immobilized in a long-leg cast for 2 weeks, followed by partial weight bearing with a bivalved cast and an exercise programme for 2 weeks with full weight bearing in a brace thereafter. At follow-up, clinical exami-

nation included laxity tests, meniscal signs, measurements of range of movement and the girth of the thigh 10 cm proximal to the upper pole of the patella, with objective antero-posterior laxity as measured by the KT-1000 arthrometer (Medmetric, San Diego, CA), and standard X-rays. Arthrometer measurements were recorded at 30° of flexion at 134 N, and compared with the contralateral knee. Radiographs were evaluated for signs of degenerative change using the criteria described by Noyes [10]. The results were compared with initial findings except for the KT-1000 measurements, as the arthrometer was not available during the early stage of the study. Knee scores were determined using Lysholm's function scores and Tegner's activity scores, with an available total of 100 points, and 10 points respectively. Functional scores of 91–100 points were rated as excellent, 84–90 points good, 65–83 points fair, and those with less than 64 points rated poor. Activity levels of 7–10 points indicated active competitive sports, 4–6 points recreational sports and 0–3 points routine daily activities [13].

The *t*-test was employed for statistical analyses of time from injury to arthroscopy, amount of aspirate, side-to-side variation in KT-1000 measurements and follow-up intervals between the groups. The Mann-Whitney's test was employed to analyse differences in knee scores between the groups. A Chi-square test was employed to analyse the incidence of muscle wasting and positive laxity tests.

## Results

No patients in either group had an effusion, restriction of knee movement or meniscal signs at the time of follow-up, and there was no difference in the incidence of muscle wasting between the two groups. Laxity tests at follow-up showed that there were patients with positive valgus stress tests at the initial examination which had be-



**Fig. 1** Number of patients with positive abduction stress test at injury and follow-up

**Table 4** Functional rates and activity levels for the groups at follow-up (number of cases)

		Operated group (n=14)	Non-operated group (n=11)
Functional rate	Excellent	14	6
	Good	0	5
	Fair, poor	0	0
Activity level	Competitive	2 (5)	0 (2)
	Recreational	9 (7)	8 (8)
	Work	3 (2)	3 (1)

( ): Pre-operative level

come negative, with no difference between the two groups (Fig. 1); neither were there differences in the KT-1000 measurements. Radiographic examination showed differences between the injured and uninjured knees in 12 of the 14 patients in the operated group and in 6 of the 11 in the non-operated group; 5 in the former and 3 in the latter were found to have minor degenerative changes. Two patients in the non-operated group suffered further sports injuries requiring limited medial meniscectomy at 44 and 73 months after the initial injuries.

The mean Lysholm's functional scores were significantly higher in the operated group (98.5 vs. 93.8) and the mean Tegner's activity scores were 5.2 in the operated group and 4.4 in the non-operated group. Function and activity levels are shown in Table 4. Neither gender nor the site of MCL injury affected the stability or functional outcome.

## Discussion

Shelbourne [11] recommended non-operative treatment for MCL tears, with a brace for 4–8 weeks and subsequent ACL reconstruction for combined MCL/ACL injuries. Noyes [9] advised surgery to the medial ligament in athletes with gross disruption and associated ACL ruptures. Gillquist and Odensten [4] showed that surgical repair of the MCL might increase the success rate of ACL reconstruction in combined injuries. Hughston [5] suggested that MCL repair converts a knee with a combined MCL/ACL

injury into one with an isolated ACL injury which may be treated conservatively. The treatment of combined MCL/ACL injuries remains however controversial.

The present study was limited by the lack of objective assessment of medial laxity and quadriceps strength, and because it was neither prospective nor randomized. Although objective evaluation of medial laxity could be performed using stress radiography [9], most patients were unwilling to consent to frequent further X-rays. Objective isokinetic tests of quadriceps strength could be performed but require anterior translation of the tibia when the knee is extended, which may be harmful in an ACL deficient knee [12]. Isokinetic exercises at less than 60° of flexion were not permitted in our patients. The treatment program was selected for each patient according to the severity of the MCL injury. The MCLs in the operative group were more severely injured than those in the non-operative group. It might be expected that patients with more severe injuries would have a poor outcome; however those who underwent MCL repair had higher Lysholm knee scores, which provides support for the view that MCL repair should be considered in patients who have combined MCL/ACL lesions and who elect not to undergo ACL reconstruction. Immobilization has been shown to be detrimental to healing medial ligaments, while early movement increases their tensile strength [7, 8]. Lechner and Dahners [7] have shown increased laxity in a healing MCL when associated with ACL transections in rats; and Bray [1] has shown that short-term immobilization is required after combined MCL and ACL transections in rabbits. Tegner activity levels showed that 19 of the 25 patients returned to sporting activities. However, further injury with subsequent meniscal lesions and degenerative changes are common sequelae [10]. Three patients in the non-operated group sustained further injury during sports activity and two required meniscectomy.

In summary patients with combined MCL/ACL lesions undergoing operative repair of the MCL with early mobilization show higher functional levels than those managed non-operatively with short-term immobilization. There were no differences in girth, stability, activity levels when comparing patients who underwent operative and non-operative management of the MCL without ACL reconstruction.

**Acknowledgments** The authors wish to thank Mr. Kiichi Osawa for his contribution to the study.

## References

1. Bray RC, Shrive NG, Frank CB, Chimich DD (1992) The early effects of joint immobilization on medial collateral ligament healing in an ACL-deficient knee. A gross anatomic and biomechanical investigation in the adult rabbit model. *J Orthop Res* 10: 157–166
2. Ciccoti MG, Lombardo SJ, Nonweiler B, Pink M (1994) Non-operative treatment of ruptures of the anterior cruciate ligament in middle-aged patients. Results after long-term follow-up. *J Bone Joint Surg [Am]* 76: 1315–1321

3. Daniel DM, Stone ML, Dobson BE, Fithian DC, Rossman DJ, Kaufman KR (1994) Fate of the ACL-injured patient. A prospective outcome study. *Am J Sports Med* 22: 632–644
4. Gillquist J, Odensten M (1993) Reconstruction of old anterior cruciate ligament tears with a Dacron prosthesis. A prospective study. *Am J Sports Med* 21: 358–366
5. Hughston JC (1994) The importance of the posterior oblique ligament in repairs of acute tears of the medial ligaments in knees with and without an associated rupture of the anterior cruciate ligament. *J Bone Joint Surg [Am]* 76: 1328–1344
6. Kartus J, Magnusson L., Stener S, Brandsson S, Eriksson BI, Karlsson J (1999) Complications following arthroscopic anterior cruciate ligament reconstruction. A 2–5-year follow-up of 604 patients with special emphasis on anterior knee pain. *Knee Surg Sports Traumatol Arthrosc* 7: 2–8
7. Lechner CT, Dahners LE (1991) Healing of the medial collateral ligament in unstable rat knees. *Am J Sports Med* 19: 508–512
8. Mok DW, Good C (1989) Non-operative management of acute grade 3 medial collateral ligament injury of the knee: A prospective study. *Injury* 20: 277–280
9. Noyes FR, Barber-Westin SD (1995) The treatment of acute combined ruptures of the anterior cruciate and medial ligaments of the knee. *Am J Sports Med* 23: 380–391
10. Noyes FR, Mooar PA, Matthews DS, Butler DL (1983) The symptomatic anterior cruciate-deficient knee. Part 1: The long-term functional disability in athletically active individuals. *J Bone Joint Surg [Am]* 65: 154–162
11. Shelbourne KD, Patel DV (1995) Management of combined injuries of anterior cruciate and medial collateral. *J Bone Joint Surg [Am]* 77: 800–806
12. Shirakura K, Kato K, Udagawa E (1992) Characteristics of the isokinetic performance of patients with injured cruciate ligaments. *Am J Sports Med* 20: 754–760
13. Tegner Y, Lysholm J (1985) Rating systems in the evaluation of knee ligament injuries. *Clin Orthop* 198: 43–49