

M. Hinsenkamp · F. Ryppens · F. Begaux · F. Mathieu  
V. De Maertelaer · M. Lepeire · E. Haubruge  
C. Chasseur · B. Stallenberg

## The anatomical distribution of radiological abnormalities in Kashin-Beck disease in Tibet

Accepted: 16 January 2001 / Published online: 1 May 2001  
© Springer-Verlag 2001

**Abstract** A radiological study of osteoarticular changes in Kashin-Beck Disease (KBD) was undertaken on the appendicular skeleton in 105 patients with KBD, in 31 healthy subjects living in an endemic area and in 30 healthy subjects living in a non-endemic area. The bone age was delayed in all three populations with no significant difference between the three studied Tibetan populations. Radiological changes occur in 56% of patients with KBD, and are usually bilateral. An analysis of the distribution of lesions shows a proximo-distal gradient. The changes are more common in the distal aspect of the limb and the lower limb is involved more commonly than the upper limb. The foot and ankle are involved in 89.5% of cases. The radiological changes and their distribution might be explained by the hypothesis of inhibition of angiogenesis by mycotoxins, exacerbated by chemical and physical environmental factors.

**Résumé** Une étude radiographique des lésions ostéoarticulaires produites par la maladie de Kashin-Beck (KBD) a été réalisée au Tibet sur le squelette appendiculaire de 105 patients atteints de KBD, de 31 sujets cliniquement

sains vivant en région endémique et de 30 sujets en région non endémique. La détermination de l'âge osseux révèle un retard de la maturité osseuse dans les trois groupes. Les lésions radiologiques sont présentes dans 56% des cas cliniques de KBD et sont bilatérales dans presque tous les cas. Le nombre de lésions augmente vers la périphérie. Le membre inférieur est plus souvent atteint que le membre supérieur. Le pied et la cheville sont atteints dans 89.5% des cas présentant une lésion radiologique. Les lésions radiologiques observées et leur distribution pourraient être expliquées par une inhibition de l'angiogénèse aggravée par les facteurs environnementaux chimiques et physiques.

### Introduction

In China, the diagnosis and severity of KBD is determined by radiological criteria [17, 19]. The classification is based on changes seen on X-rays of the bones and joints of the hand. In this study, we describe the changes throughout the appendicular skeleton and propose a grading system based on these changes and their relation to clinical staging [9].

### Materials and methods

The population which we studied included 166 children between 6 and 15 years of age who were divided into three groups: P1, 105 KBD patients; P2, 31 non-KBD patients living in an endemic area; and P3, 30 non-KBD subjects living in a non-endemic area. The endemic area includes Nyemo and Lundrup Counties (Lhasa Prefecture), Neudong County (Lhoca Prefecture) and Shetome County (Shigatse Prefecture). The non-endemic area includes Rimpung County (Shigatse Prefecture [6]). In each group, there was an equal age distribution and boys represented two-thirds of cases. Informed consent was obtained from the parents. AP X-rays of the appendicular skeleton were taken, and lateral views of the knee and ankle. A Lowenstein view of the hip and an oblique view of the foot were also taken. X-rays were interpreted by two radiologists and one orthopaedic surgeon. The skeletal maturity was determined according to the criteria of Greulich and Pyle [7]. The difference between the actual age and skeletal maturity was analy-

M. Hinsenkamp (✉)  
Hôpital Erasme, Service d'Orthopédie Traumatologie,  
808 route de Lennik, 1070 Brussels, Belgium  
e-mail: mhinsenk@ulb.ac.be  
Fax: +322-555-49-91

F. Ryppens · M. Lepeire · B. Stallenberg  
Hôpital Erasme, Service Radiologie, 808 route de Lennik,  
1070 Brussels, Belgium

F. Begaux · F. Mathieu  
Médecins Sans Frontières, Rue Dupré 94, 1090 Brussels, Belgium

V. De Maertelaer  
I.R.I.B.H.N., 808 route de Lennik, 1070 Brussels, Belgium

E. Haubruge  
Unité de Zoologie Générale et Appliquée,  
Faculté Universitaire des Sciences Agronomiques de Gembloux,  
Passage des Déportés 2, 5030 Gembloux, Belgium

C. Chasseur  
Scientific Institute of Public Health, Louis Pasteur,  
Brussels, Belgium

sed by linear regression. The following metaphyseal or epiphyseal changes were deemed to be diagnostic of KBD: irregularities of bony margins, sclerosis, a cone-shaped metaphysis, fusion or fragmentation.

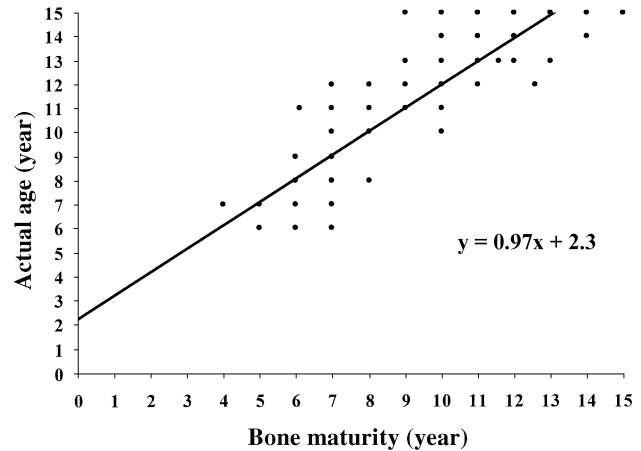
The following grading system was applied:

- Grade 0: no radiological changes.
- Grade 1: radiological changes of the epiphysis or metaphysis.
- Grade 2: radiological changes of the epiphysis or metaphysis without fusion.
- Grade 3: local fusion of the metaphyseal growth plate.

The radiological scale for the whole patient consisted of the sum of the more severe radiological changes seen in the following areas: both hands and wrists; elbows, shoulders, ankles, knees and hips. This sum gives a scale from 0 to 36. This scale is divided into four stages: stage 0, I (1–10), II (11–20) and III (21–36). The bilateral presence of radiological signs was tested for each variable with the  $\kappa$ -test. The relationship between the radiological changes and the clinical staging was studied by the  $\chi^2$ -test.

## Results

Depending on the site, the reproducibility of the agreement of the interpretation of two X-rays by the two radiologists and the orthopaedic surgeon varied from good to excellent ( $0.60 < k < 1$ ). Bone maturity as determined from X-rays of the left hand was compared with actual age using the method of Greulich and Pyle [7]. The bone maturity of the Tibetan population in all three groups is significantly less than the western equivalent. Figure 1 shows the linear regression of actual age and bone maturity for the KBD population. In the present KBD population P1, the evolution of the bone maturity is 2.3 years delayed below the actual age ( $P < 0.001$ ). In the healthy



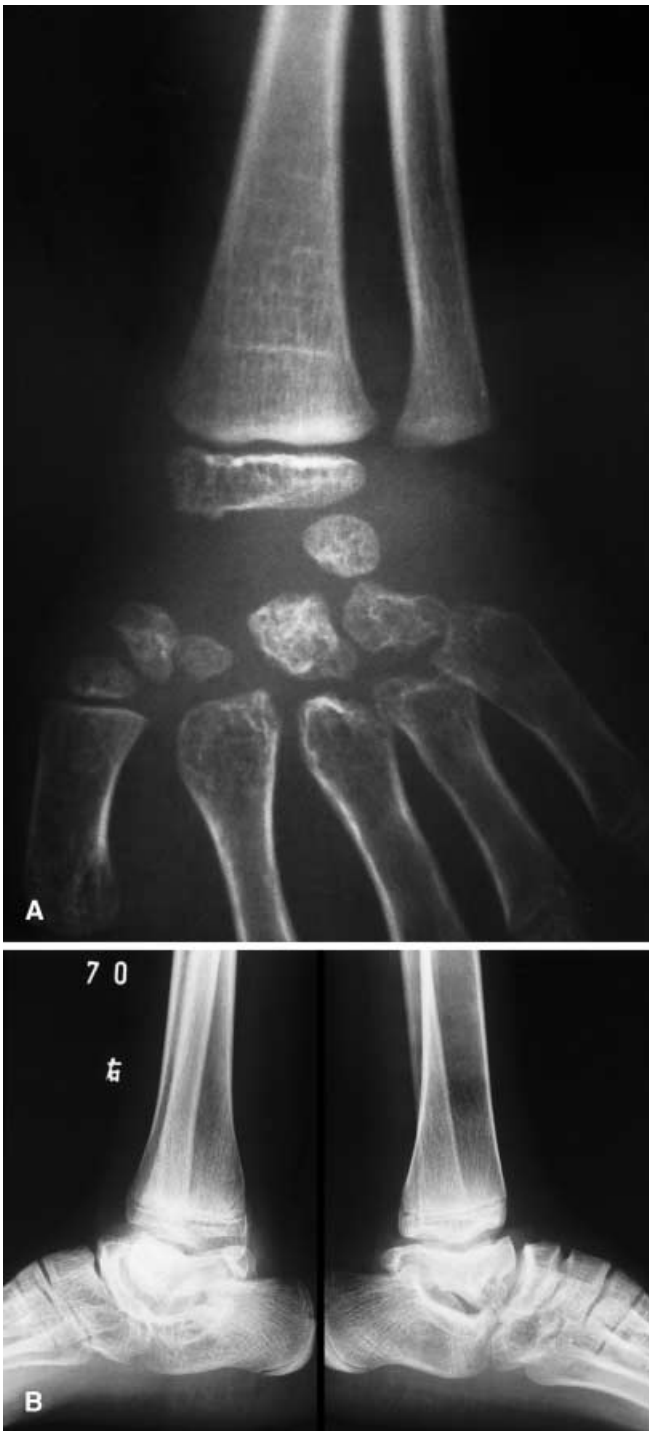**Fig. 1** Linear regression of the actual age on bone maturity for the KBD population P1 (nb=91)

population in endemic area (P2) and in non-endemic area (P3) the delay is respectively 3.4 ( $P < 0.001$ ) and 3.5 years ( $P < 0.001$ ) below the actual age. In between the three Tibetan populations (P1, P2 and P3) the differences are not significant.

The changes are bilateral in 96.6–100% of cases, depending on the site. The left side was used as a reference when comparing the frequency of lesions in different sites. In the KBD population at least one radiological lesion was seen in 56% of cases. In the P2 and P3 groups the percentage of lesions was respectively 13% and 7%. The details of the distribution and grading of the radiological signs are shown in Table 1. The lesions of the

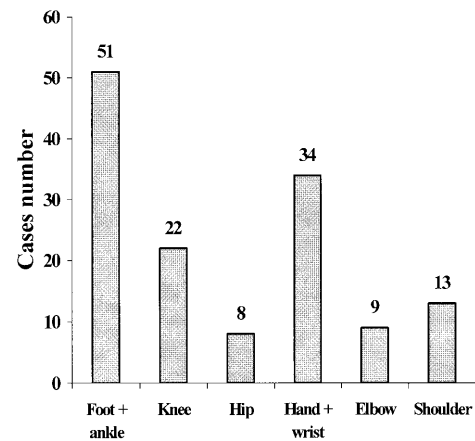
**Table 1** Radiographic features for the different osteoarticular locations in 105 KBD cases (Lhasa, Lhoca and Shigatse Prefecture, T.A.R.)

Osteoarticular location (left)	Nb	Radiographic grade					Total 1, 2, 3
		Grade 0	Grade 1 (metaphysis)	Grade 1 (epiphysis)	Grade 2	Grade 3	
Hand phalanx	104	94	8	0	2	0	10
Distal metacarp	104	91	11	0	2	0	13
Proximal metacarp	105	98	4	0	2	1	7
Carpal bones	105	98	0	7	0	0	7
Distal ulna	102	78	22	0	2	0	24
Distal radius	103	84	16	0	3	0	19
Proximal ulna	104	97	4	2	1	0	7
Proximal radius	104	98	2	0	4	0	6
Distal humerus	104	95	1	0	7	1	9
Proximal humerus	104	92	4	1	6	1	12
Foot phalanx	103	79	17	0	5	2	24
Distal metacarp	103	74	27	0	2	0	29
Proximal metatars	105	86	7	1	9	2	19
Tarsal bones	105	91	0	14	0	0	14
Distal tibia	104	77	18	1	8	0	27
Distal fibula	104	84	17	1	2	0	20
Proximal tibia	105	94	6	1	4	0	11
Proximal fibula	105	99	3	0	3	0	6
Distal femur	105	86	13	0	6	0	19
Proximal femur	102	96	0	0	5	1	6
Cotyl	105	98	0	7	0	0	7
Total	2185	1889	180	35	73	8	296
Percentage (%)	100	86.5	8.2	1.6	3.3	0.4	



**Fig. 2** **A** Carpal bone lesions in a 6-year-old boy. **B** Bilateral lesions of the talus in a 15-year-old girl

carpus and tarsus were classed as epiphyseal lesions and when present were often very advanced (Fig. 2). The frequency and sites of the lesions are shown in Fig. 3. An obvious proximo-distal gradient is seen, with more lesions seen distally than proximally. The lower limb is more frequently and more severely affected than the upper limb. A lesion of the foot and ankle is present in



**Fig. 3** Frequency of the skeletal lesions by anatomical location (nb=105)

**Table 2** Relation between the different clinical and radiographic stages in the population P1 and P2 in endemic area (nb=133)

X-ray	Clinical stage				
	0	1	2	3	Total
Stage					
0	27	16	15	14	72
I (1-10)	4	10	25	15	54
II (11-20)	0	0	1	2	3
III (21-36)	0	0	0	4	4
Total	31	26	41	35	133

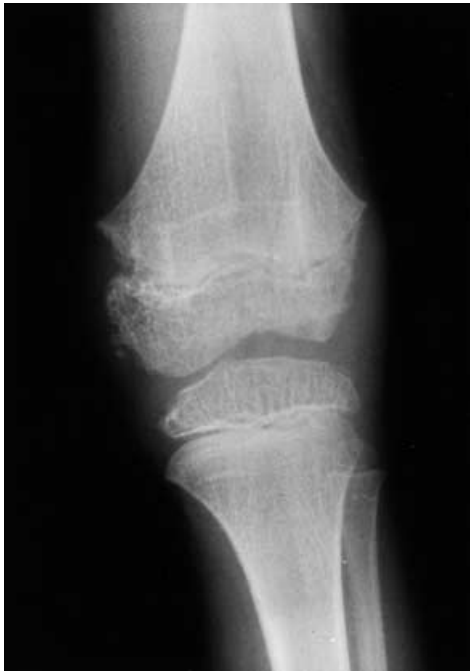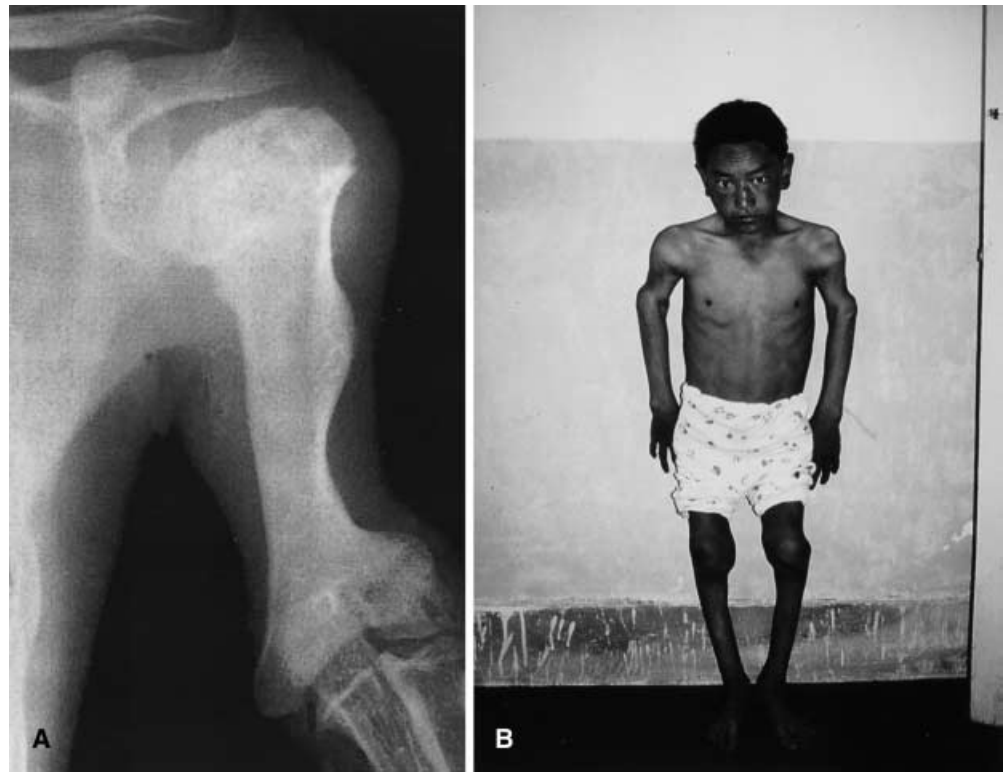89.5% of cases with positive radiological findings, and in 48.6% of the total KBD population. Figure 4 shows a typical lesion of the humerus and the clinical appearance of the same patient. Figure 5 shows the knee of a 6-year-old boy.

The relationship was analysed between the radiological features and the clinical staging as described by Mathieu et al. [9, 10]. There is a significant relationship between the radiological appearances of a particular anatomical site and the clinical stage, carpus ( $P=0.009$ ), proximal ulna ( $P=0.028$ ), proximal radius ( $P=0.042$ ), distal humerus ( $P=0.012$ ), tarsus ( $P=0.001$ ), distal tibia ( $P=0.020$ ), proximal fibula ( $P=0.039$ ) and the hip ( $P=0.016$ ). Table 2 shows the relationship between the severity of the radiological changes in the four clinical stages. A significant correlation exists between the two classifications ( $\chi^2$ :  $P<0.001$ ). The sensitivity of the radiological examination is only 56% of the clinical diagnosis whereas the specificity reaches 90% for the X-ray examination.

## Discussion

The present radiological study was undertaken under extremely difficult circumstances, and the plain X-rays were not always of a high quality. However, we have

**Fig. 4** **A** Characteristic shortening of the humerus in a 16-year-old boy. **B** Clinical appearance of the patient



**Fig. 5** Radiographic changes in the distal femur of a 6-year-old boy

been able to describe for the first time in Tibet the characteristic radiological features of KBD in the appendicular skeleton. Bone maturity was delayed in all our KBD populations and controls in endemic and non-endemic areas. The delayed bone maturity appeared not to be spe-

cifically related to KBD and may be linked to iodine deficiency in these areas. A significant prevalence of goitre exists in Tibet. An appropriate dietary programme of iodine and selenium supplements should be encouraged [11, 12, 16].

The bilateral nature of the symptoms seen in 79% of the cases on a clinical basis [9, 10] is even more evident on radiological examination where 99.4% of the lesions are bilateral. According to the sensitivity and specificity calculation, the early diagnosis of KBD should be made clinically with the severity of the lesions being identified radiologically.

The proximo-distal gradient already described in clinical studies [9, 10] is confirmed by the radiological study. This gradient and also the fact that more frequent and severe lesions are present in the lower limb than the upper limb may be explained by the hypothesis of inhibition of angiogenesis by a mycotoxin produced by fungi present in barley grain [6, 8]. An absence of normal vascular development as observed by Pasteels et al. [13] may be exaggerated by environmental factors such as cold, hypoxia and microtrauma. The cartilage of the growth plate, for instance, and the epiphyseal cartilage seem particularly sensitive to cold, as seen after frostbite in childhood [1, 2, 3, 4, 5, 14, 15, 18]. The characteristics of the radiological lesions may be caused by ischaemia of the growing cartilage. In order further to understand the aetiology of KBD, it will be necessary to investigate the outcome of protecting the extremities from adverse environmental factors, before significant changes in the subchondral bone have occurred. The lesions of

the articular cartilage may appear late, and seem to be the result of deformity of joints caused by altered epiphyseal growth.

---

## References

1. Bennett RB, Blount WP (1935) Destruction of epiphyses by freezing. *JAMA* 105:661–662
2. Bigelow DR, Ritchie GW (1963) The effects of frostbite in childhood. *J Bone Joint Surg* 45:122–131
3. Brown FE, Spiegel PK, Boyle WE (1983) Digital deformity: an effect of frostbite in children. *Pediatrics* 71:955–959
4. Carrera GF, Kozin F, Flaherty L, McCarty DJ (1979) Arthritis after frostbite injury in children. *Arthritis Rheum* 22:1082–1087
5. Carrera GF, Kozin F, Flaherty L, McCarty DJ (1981) Radiographic changes in the hands following childhood frostbite injury. *Skeletal Radiol* 6:33–37
6. Chasseur C, Suetens C, Michel V, Mathieu F, Begaux F, Nolard N, Haubruge E (2001) Mycological approach of Kashin-Beck disease in Tibet: an overview of 4 years' study, and future. *Int Orthop* DOI 10.1007/s002640000218
7. Greulich W, Pyle S (1989) Radiographic atlas of skeletal development of hand and wrist. Stanford University Press, Stanford
8. Haubruge E (2001) Mycotoxins prevalence in KBD. *Int Orthop* DOI 10.1007/s002640100240
9. Mathieu F, Begaux F, Zhang Yong Lan, Suetens C, Hinsenkamp M (1997) Clinical manifestations of Kashin-Beck disease in Nyemo Valley, Tibet. *Int Orthop* 21:151–156
10. Mathieu F, Suetens C, Begaux F, De Maertelaer V, Hinsenkamp M (2001) Effects of physical therapy for patients suffering from Kashin-Beck disease in Tibet. *Int Orthop* DOI 10.1007/s002640000206
11. Moreno-Reyes R et al (1998) Kashin-Beck osteoarthropathy in rural Tibet in relation to selenium and iodine status. *N Engl J Med* 339:1112–1120
12. Moreno-Reyes R, Suetens C, Mathieu F, Begaux F, Dun Zhu, Rivera T, Boelaert M, Nève J, Perlmutter N, Vanderpas J (2001) Kashin-Beck disease and iodine deficiency in Tibet. *Int Orthop* DOI 10.1007/s002640000216
13. Pasteels JL, Liu Fu-De, Hinsenkamp M, Rooze M, Mathieu F, Perlmutter N (2000) Histology of Kashin-Beck lesions. *Int Orthop* DOI 10.1007/s002640000190
14. Selke AC (1969) Destruction of phalangeal epiphyses by frostbite. *Radiology* 93:859–860
15. Thelander HE (1950) Epiphyseal destruction by frostbite. *J Pediatr* 36:105–106
16. Utiger RD (1998) Kashin-Beck disease – expanding the spectrum of iodine-deficiency disorders. *N Engl J Med* 339:1156–1158
17. Wang Y, Yang Z, Gilula L, Zhu C (1996) Kashin-Beck disease: radiographic appearance in the hands and wrists. *Radiology* 201:265–270
18. Wenzl JE, Burke EC, Bianco AJ (1967) Epiphyseal destruction from frostbite of the hands. *Am J Dis Child* 114:668–670
19. Ying M, Wang Y, Chu Q, Fu G, Jin L (1982) Radiology and pathology of Kashin-Beck disease. In: Chinese Academy of Preventive Medicine (CAPM): proceedings of the international workshop on Kashin-Beck disease and non-communicable diseases. WHO, Beijing, pp 56–62