

M. Synder · H. T. Harcke · K. Conard · J. R. Bowen

## Experimental epiphysiodesis: magnetic resonance imaging evaluation with histopathologic correlation

Accepted: 10 May 2001 / Published online: 24 August 2001  
© Springer-Verlag 2001

**Abstract** We performed an experimental epiphysiodesis on the tibia in 16 immature New Zealand white rabbits. The purpose was to study the process of trauma-induced growth plate closure. The animals were killed at weekly intervals over 8 weeks. We correlated the histological findings with serial magnetic resonance images. The undamaged, central part of the growth plate became histologically abnormal within 1 week. Mature bone bridge formation in the area of the epiphysiodesis was seen after 3 to 4 weeks. The study suggests that growth arrest starts before the bone bridge formation. Factors regulating cartilage growth may also play a role.

**Résumé** Nous avons réalisé une épiphysiodèse expérimentale sur le tibia de 16 lapins blancs de Nouvelle Zélande immatures. Le but était d'étudier le processus de fermeture du cartilage de conjugaison après un traumatisme. Les animaux ont été sacrifiés à intervalle hebdomadaire, sur 8 semaines. Nous avons comparés les aspects histologiques avec les images de la résonance magnétique nucléaire. La partie centrale, en bon état, du cartilage de conjugaison est devenue anormale histologiquement en une semaine. Un pont osseux mature dans la région de l'épiphysiodèse a été visible après trois à quatre semaines. L'étude suggère que l'arrêt de croissance débute avant la formation du pont osseux. Les facteurs régulant la croissance cartilagineuse peuvent aussi jouer un rôle.

### Introduction

The growth plate is the structure responsible for longitudinal growth of the immature bone [14]. During growth

and development, the growth plate is often exposed to injury and different diseases that can induce premature closure [1, 5, 16]. Magnetic resonance imaging (MRI) has proved to be a successful method for studying growth plate changes [1, 5, 7, 9, 10, 13, 16, 19]. The physiologic significance of anatomically observed changes in an injured growth plate needs to be established for these studies to be of predictive value in clinical situations.

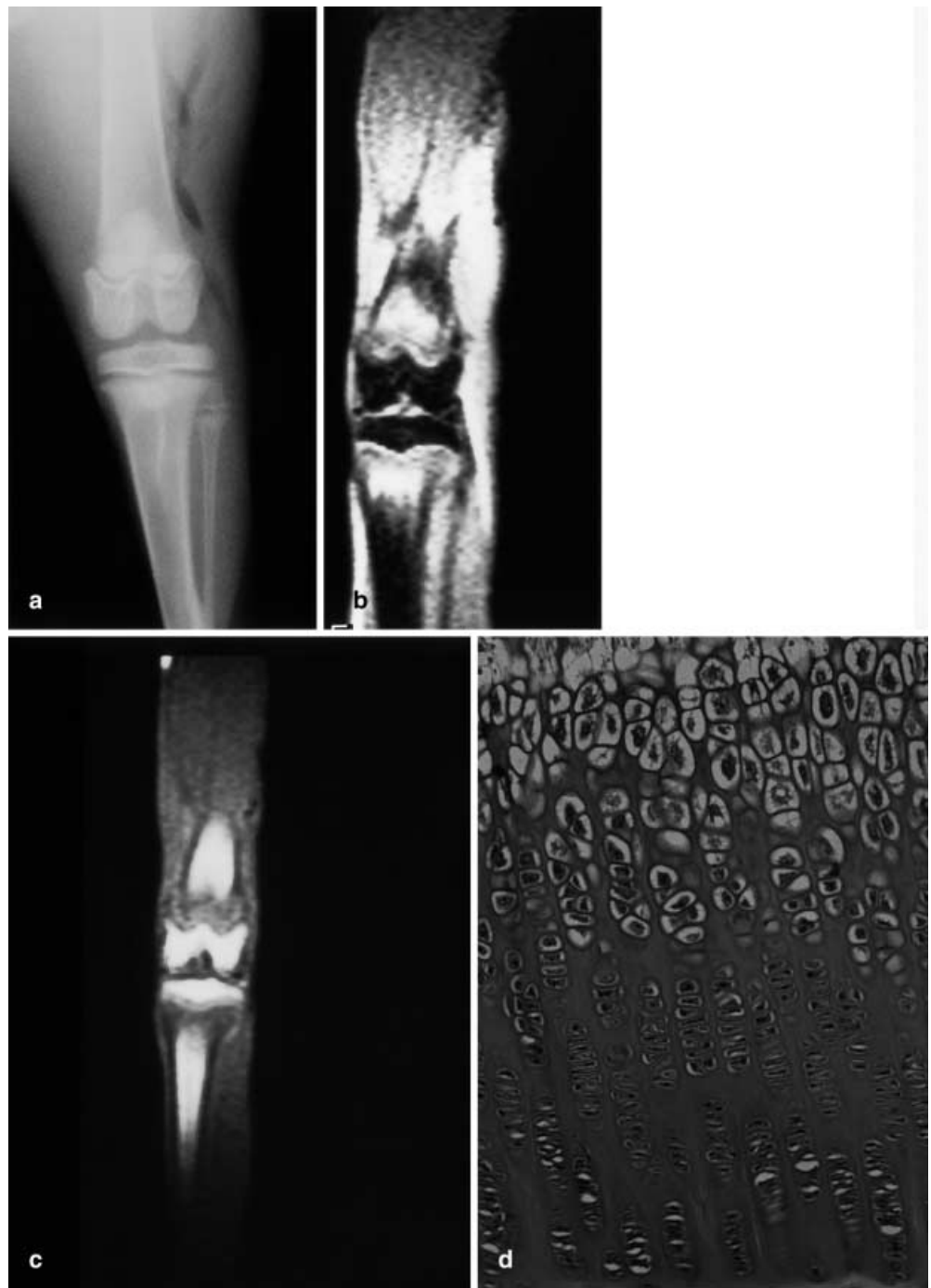In a previous study, we established the normal appearance of the growth plate on MRI and showed characteristics of the growth plate according to the age of the patients and technical variation [7]. To understand plate response to trauma, we studied *in vivo* changes that occurred in different areas of the physal cartilage of children following elective epiphysiodesis [19]. This evaluation, did not correlate histologically with the changes observed. To obtain histological correlation with magnetic resonance changes and to understand the physiologic significance in more depth, a parallel study of epiphysiodesis was conducted in an experimental rabbit model.

Rabbit epiphyses mature quickly; however, skeletal growth is not complete until 28 weeks of age [12]. Radiographically, the growth plate is a thin, undulating band of lucency with some increased density along the margins in the metaphysis and epiphysis (Fig. 1a). On MRI, the cartilage has less intensity on T1-weighted images than on gradient echo images where it shows high signal intensity. The growth plate cartilage has high signal intensity and in the metaphysis adjacent to the plate there is a band intermediate-signal intensity (Fig. 1b). A T1-weighted sequence shows a high signal in the marrow of the epiphysis and metaphysis with a broad area of intermediate signal in the metaphysis adjacent to the growth plate (Fig. 1c). Histologically, the narrow cartilage band has the regular columns of chondrocytes, which are progressively enlarged toward the zone of provisional calcification (Fig. 1d).

M. Synder (✉)  
Orthopedic Clinic Medical University of Lodz,  
Drewnowska Str. 75, 91-002 Lodz, Poland  
e-mail: syndermarek@netscape.net  
Tel.: +48-42-6540243, Fax: +48-42-6540243

H.T. Harcke · K. Conard · J.R. Bowen  
Alfred I. DuPont Hospital for Children, Wilmington,  
Delaware 19899, USA

**Fig. 1a–d** *The normal rabbit knee at 6 weeks. a.* Anteroposterior radiograph. **b.** MRI: normal gradient echo image (450/20/20). **c.** MRI: normal T1-weighted image (450/20). Note high signal intensity in proximal tibial growth plate (*arrows*), and broad band of increased intensity in the adjacent metaphysis. **d.** Histological section of the normal growth plate (200 $\times$ ). Note regular chondrocyte columns



## Materials and methods

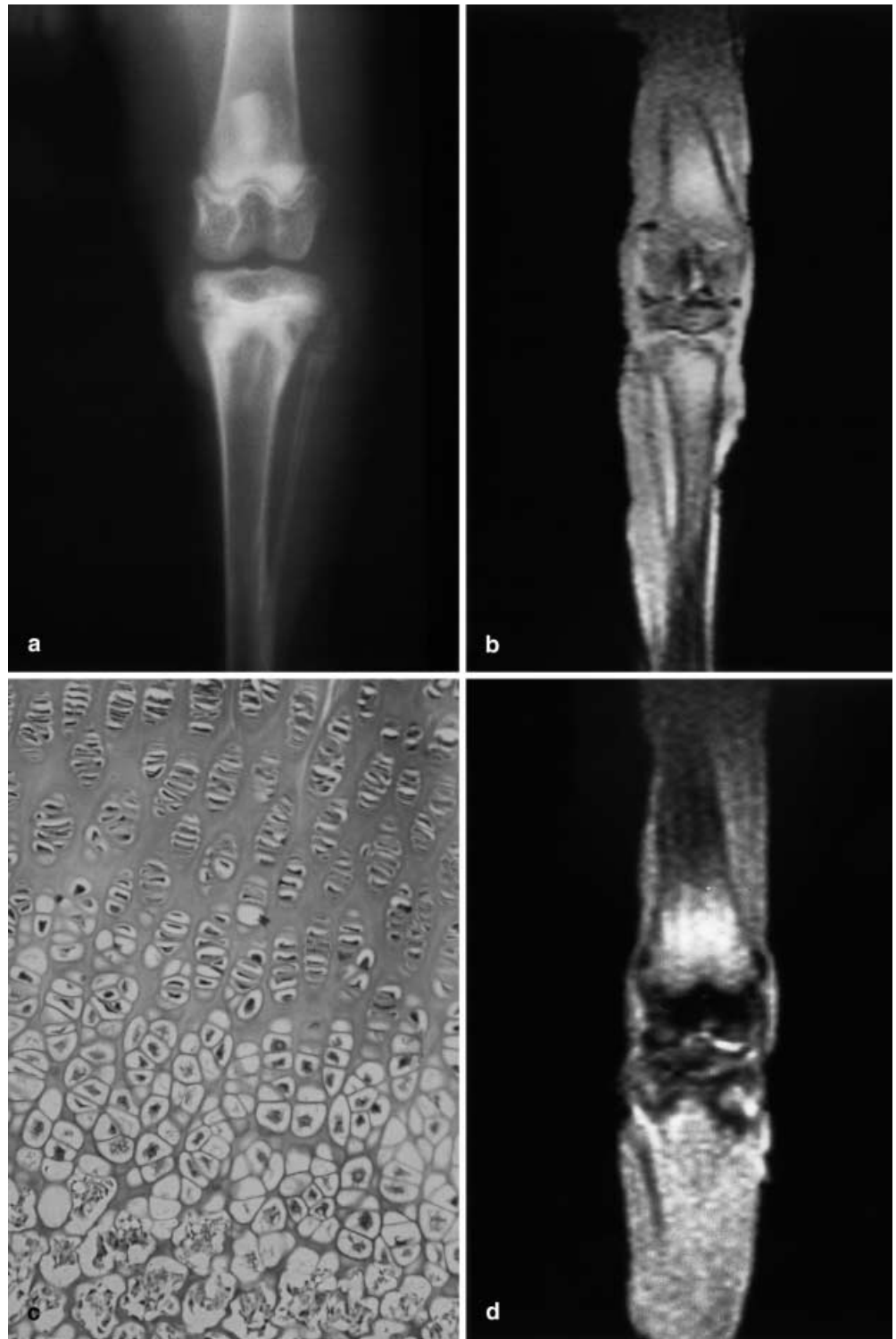
Sixteen New Zealand white rabbits, approximately 6 weeks of age and weighing about 1000 g, were used in this study. The handling of the animals was in compliance with national regulations. Epiphysiodesis of the proximal epiphysis of the right tibia was carried out under sterile operating room conditions. Approximately one-third of the growth plate from each side was damaged during the procedure. The left tibia was left untouched and used for control data.

Rabbits were evaluated postoperatively by MRI at weekly intervals. For imaging, rabbits were anesthetized and immobilized on a wooden pegboard. All MRI studies were performed on an

0.5T Mobile Unit (Picker HP Vista, Cleveland, OH, USA) and used temporo-mandibular joint coil. The MRI evaluation included coronal T1-weighted spin echo images (TR 450, TE 20) and coronal gradient echo images (TR 450, TE 20, flip angle 20°). A total of 23 MRI studies of the rabbits' knees were obtained. The images included the operated and control knees in each case. Immediately after MRI, posterior-anterior roentgenograms of both legs were also obtained (100 mAs, 015 s, 44 kV).

Two rabbits were killed each week to accrue serial data from postoperative weeks 1 through 8. A total of 260 sections of right tibias and 50 sections of left tibias were obtained for evaluation. The bone bridge formation peripherally at the areas of epiphysiodesis and behavior of the undamaged central area of the growth plate cartilage

**Fig. 2a–d** Growth plate changes in the rabbit knee 1 to 2 weeks following proximal tibial epiphysiodesis. **a.** Radiograph. Note surgical defects medial and lateral. The central plate is visible. **b.** T1-weighted MRI at 1 week (450/20/20). **c.** Histological changes in the growth plate 1 week post-epiphysiodesis (200 $\times$ ). Note minor architectural disarray in chondrocyte columns. **d.** Gradient echo MRI at 2 weeks (450/20/20)



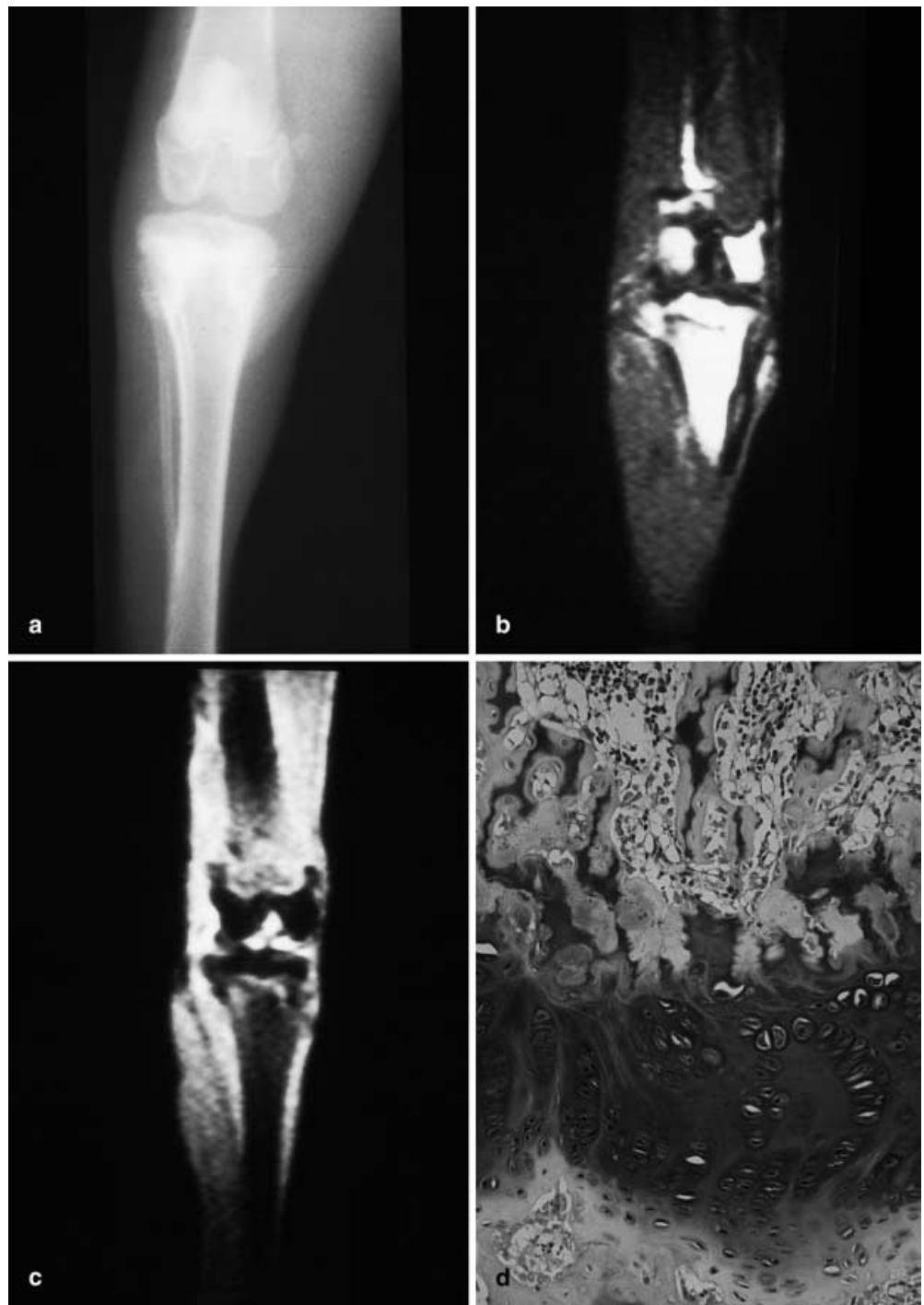were evaluated. An intraocular micrometer was used to measure the width of the central part of the operated and control growth plates.

## Results

One week after epiphysiodesis, the surgical defect was clearly visible radiographically (Fig. 2a). Some new

bone formation was evident at the surgical sites. On both T1-weighted and gradient echo images (Fig. 2b), the surgical defects showed mixed but mostly high signal intensity throughout the damaged areas. The intact central part of the growth plate showed high-signal intensity and the appearance of the adjacent marrow was essentially normal. Histologically, the cartilage band in the physis

**Fig. 3a–d** Growth plate changes in the rabbit knee 4 weeks following epiphysiodesis. **a.** Radiograph with complete bone bridge formation. **b.** T1-weighted MRI (450/20). Note bone bridge formation medially and laterally. **c.** Gradient echo MRI (450/20/20). There is loss of the high signal cartilage at the growth plate margins and no increased signal in the central adjacent metaphysis. **d.** Histology of the growth plate (200×). Chondrocyte orientation is totally disrupted and disorganized



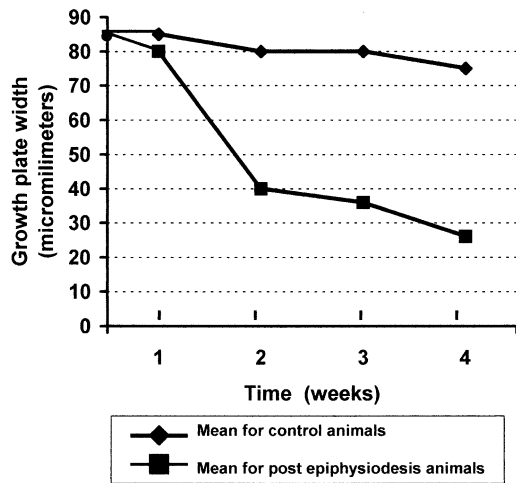
showed minor architectural disarray in the chondrocyte columns; however, the width of the growth plate was only minimally decreased (Fig. 2c).

Two weeks after operation, early bone bridge formation was observed radiographically at the surgical sites. The surgical margins of the defects had begun to obliterate. On T1-weighted MRI, the surgical site showed low signal intensity and obliteration of the growth plate. On gradient echo images, the immature bone bridge formation presented with a low signal intensity rim at the mar-

gin of the damaged area, but the centre of the surgical defect retained bright high signal intensity. Narrowing of the undamaged central growth plate cartilage was observed on the field echo images (Fig. 2d). Histologically, loss of chondrocyte column organization was observed in the central area of the growth plate.

At the third and fourth week after epiphysiodesis, mature bony bridging was visible radiographically, the growth plate was closed and remodelling had begun to occur at the site of epiphysiodesis (Fig. 3a). The





**Fig. 4** Tibial growth plate width in the immature rabbit. Comparison between control and epiphysiodesis animals

T1-weighted MRI showed high-signal intensity in the area of the surgical defect. The intermediate signal zone of provisional calcification was obliterated with marrow signal approaching the residual line of the physis (Fig. 3b). On the gradient echo images, intermediate and low-signal intensity was noted at the surgical sites, and there was loss of the high signal cartilage band at the zone of provisional calcification (Fig. 3c). In the fourth week, peak disruption in growth plate cartilage was seen (Fig. 3d). Further progression of these changes did not occur in animals examined through week 8 as plate closure progressed.

Serial measurements of the width of the growth plate cartilage were obtained in the central undisturbed part of the tibial plate undergoing epiphysiodesis. Measurements were obtained from the contralateral knee for comparison. By the second postoperative week, there was a marked decrease in the width of the physis between the areas of epiphysiodesis. This narrowing progressed through the fourth week but occurred at a slower rate between the second and fourth week. The normal control physis showed a very slight decrease in width during the 4 weeks of observation (Fig. 4).

## Discussion

The growth plate responds to traumatic, metabolic and physiologic influences and while the process is recognized little is understood about the mechanism [4, 16]. Operative epiphysiodesis as performed by Phemister [15] and simplified by the technique of Bowen and Johnson [2] represents intentional injury to the growth plate to induce early closure. Use of this technique offers an opportunity to observe not only bone bridge formation at the surgical site but also to monitor changes that occur in the central, undisturbed portion of the growth plate [5].

The correlative imaging of the growth plate in the rabbit documented the accelerated closure that occurred

as a result of the epiphysiodesis. Radiographically, the changes of complete closure were observed 3 to 4 weeks after surgery, at the surgical site with obliteration of the intact portion of the plate occurring as well. While this process takes more than 8 months in the human [13], it can be observed in the rabbit model in 4 weeks.

In 1998, Jaramillo et al. reported MRI characteristics of the normal newborn lamb epiphysis with histological correlation [11]. This study allowed differentiation of the growth plate and epiphyseal cartilage in a larger animal model. Our MRI-histopathological correlative study based on surgical damage of the growth plate revealed all the cartilage and surgical effects with similar high signal intensity.

The central part of the growth plate showed progressive narrowing as bone fusion occurred at the site of epiphysiodesis. Loss of cartilage width occurred rapidly between the first and second postoperative weeks. This loss then slowed to a more gradual loss. The corresponding high-signal metaphyseal band (on gradient echo images) demonstrated progressive loss of width (Fig. 2d). A surprising finding was the alteration in the architecture of the chondrocyte columns that appeared in the first week after epiphysiodesis. These changes in the central part of the growth plate were noted in advance of the development of mature medial and lateral bridging. While the mechanism for plate closure after epiphysiodesis has been attributed to compression as a consequence of tethering [14, 17, 18], the early changes were noted before mature bony tethering occurred, raising the possibility that other mechanisms play a role.

Experiments have shown that use of staples or wires that loop around the growth plate can induce plate arrest [6]. Removal of staples or wires leads to resumption of growth in some cases [6, 18]. However, it is not clear at what point arrest of the growth plate is still reversible.

We have previously reported a study of growth plate closure in humans who had undergone epiphysiodesis [19]. While some variations in the architecture and intensity of signal are noted, the human and rabbit physes exhibit similarities in the pattern of growth plate closure. We know from the histology that the band of cartilage was only 23 to 25 microns thick at this time. General correlations between what occurs in the rabbits and humans suggest that what occurs in 1 week in the rabbit (from a growth stand point) is temporally equivalent to what occurs in 8 weeks for the human. Our conclusion after extrapolating the animal study results to humans would suggest that early changes occurring in the central non-traumatized portion of the growth plate could relate to factors other than mechanical compression. Support for this early cessation of growth is found in our human description of no linear growth after percutaneous epiphysiodesis [19] and the study by Bylander et al. [3].

We think it is interesting that histological changes in the chondrocyte architecture occurred so quickly. Such findings raise questions about the regulation of cartilage activity in the plate remote to a site of damage. It is possible that the surgical damage lateral and medial to the central area affected the blood supply to this zone [20]. However, other

regulating factors need to be considered. This model for studying cartilage may prove useful in further experiments.

## References

1. Borsa JJ, Peterson HA, Ehman RL (1996) MR imaging of physeal bars. *Radiology* 199:683–687
2. Bowen JR, Johnson WJ (1984) Percutaneous epiphysiodesis. *Clin Orthop* 190:170–173
3. Bylander B, Egund N, Hansson LI, Selvik G (1980) Growth arrest by stapling and epiphysiodesis. *Acta Orthop Scand* 51:377–378
4. Carey J, Spence L, Blickman H (1998) MRI of pediatric growth plate injury: correlation with plain film radiographs. *Skeletal Radiol* 27:250–255
5. Gabel GT, Peterson HA, Berquist TH (1991) Premature partial physeal arrest. *Clin Orthop* 272:242–247
6. Hall-Craggs ECB (1968) The effect of experimental epiphysiodesis on growth in length of the rabbit's tibia. *J Bone Joint Surg [Br]* 50:392–400
7. Harcke HT, Synder M, Caro PA, Bowen JR (1992) Growth plate of the normal knee: evaluation with MR imaging. *Radiology* 183:119–113
8. Havranek P, Lizler J (1991) Magnetic resonance imaging in the evaluation of partial growth plate arrest after physeal injuries in children. *J Bone Joint Surg [Am]* 73:1234–1241
9. Jaramillo D, Shapiro F, Hoffer FA, Winalski CS, Koskinen MF, Frasso R, Johnson A (1990) Posttraumatic growth-plate abnormalities: MR imaging of bony-bridge formation in rabbits. *Radiology* 175:767–773
10. Jaramillo D, Laor T, Zaleske DJ (1993) Indirect trauma to the growth plate: results of MR imaging after epiphyseal and metaphyseal injury in rabbits. *Radiology* 187:171–178
11. Jaramillo D, Connolly SA, Mulkern RV, Shapiro F (1998) Developing epiphysis: MR imaging characteristics and histologic correlation in the newborn lambs. *Radiology* 207:637–645
12. Masoud I, Shapiro F, Kent R, Moses A (1986) A longitudinal study of the growth of the New Zealand white rabbit: cumulative and biweekly incremental growth rates for body length, body weight, femoral length, and tibial length. *J Orthop Res* 4:221–231
13. Modl JM, Sether LA, Haughton VM, Kneeland JB (1991) Articular cartilage: correlation of histologic zones with signal intensity at MR Imaging. *Radiology* 181:853–855
14. Ogden JA (1987) The evaluation and treatment of partial physeal arrest. *J Bone Joint Surg [Am]* 69:1297–1302
15. Phemister DB (1933) Operative arrestment of longitudinal growth of bones in the treatment of deformity. *J Bone Joint Surg* 15:1–15
16. Rogers LF, Poznanski AK (1994) Imaging of epiphyseal injuries. *Radiology* 191:297–298
17. Schaffler MB, Li XJ, Jee WS, Ho SW, Stern PJ (1988) Skeletal tissue responses to thermal injury: an experimental study. *Bone* 9:397–406
18. Siffert RS (1956) The effect of staples and longitudinal wires on epiphyseal growth. *J Bone Joint Surg [Am]* 38:1077–1078
19. Synder M, Harcke HT, Bowen JR, Caro PA (1994) Evaluation of physeal behavior in response to epiphysiodesis with the use of serial magnetic resonance imaging. *J Bone Joint Surg [Am]* 76:224–229
20. Trueta J (1963) The role of the vessels in osteogenesis. *J Bone Joint Surg [Br]* 45:402–408