

Penile Augmentation with Resultant Foreign Material Granuloma and Sequelae

Fam Xeng Inn¹, Farrah-Hani IMRAN¹, Mohd Faizal ALI¹,
Rizuana IH², Zulkifli Z¹

Submitted: 5 Apr 2012

Accepted: 4 Jun 2012

¹ Department of Surgery, Faculty of Medicine, Universiti Kebangsaan Malaysia Medical Centre, Jalan Yaacob Latif, Bandar Tun Razak, 56000 Cheras, Kuala Lumpur, Malaysia

² Department of radiology, Department of Surgery, Faculty of Medicine, Universiti Kebangsaan Malaysia Medical Centre, Jalan Yaacob Latif, Bandar Tun Razak, 56000 Cheras, Kuala Lumpur, Malaysia

Abstract

Throughout history, a proportion of men appear to correlate penis size and dimensions directly with physical fitness and sexual prowess. Foreign materials, such as paraffin oil, paraffin balm, mineral oils, and silicone, have been used to promise an improvement in penile shaft contour and dimensions. These materials are injected directly into the penis; inducing granuloma formation to achieve increased penis length and girth. However, the result is a severely disfigured and swollen penis, which cannot achieve erection. Local complications of penile lipogranuloma include infection, ulceration, local migration, and cavernosal invasion; leading to functional impairment. Meanwhile, systemic complications include foreign body embolization, organ infarct, and death. Penile lipogranuloma is best treated surgically. Granulomatous skin needs to be completely excised; wound closure with a scrotal skin flap, Cecil's inlay operation and split thickness skin graft commonly used options. Our case series has shown that penile lipogranuloma, induced by subcutaneous foreign body injections into the penile shaft, and its subsequent adverse outcomes to patients and their partners.

Keywords: augmentation, foreign body reaction, granuloma, silicone, penis

Introduction

Throughout history a proportion of man appear to correlate penis size and dimensions directly with physical fitness and sexual prowess. Foreign materials, such as paraffin oil, paraffin balm, mineral oils, and silicone, have been used to improve penile shaft contour and dimensions. Various dubious establishments offer treatments where foreign material is injected directly into the penis to achieve an increase in length and girth. Our case series has shown that this results in adverse outcomes to patients and their partners.

Case Report

Three men aged between 32 to 59-years-old were given subcutaneous foreign body injections into their penile shafts by non-medical practitioners (Table 1). Two were given silicone and one was given paraffin oil. They volunteered to take the injections in a non-sterile environment, with their motivation being a larger penile size. They denied influence from their sexual partners.

They began to notice abnormal reactions to their penises, about 14 months after the injection. Over this time, their penile shafts gradually became deformed, swollen, and hard. Each patient was able to achieve an erection. However, erections and sexual intercourse were painful to both the patient and their partner, due to the irregular hard lumps around the penile shaft. In all cases, treatment was sought between four to six years after the injection.

Physical examinations showed similar changes for all three patient's penises. The penile shafts were swollen and disfigured, with irregular semi-mobile masses extending into the scrotum (Figure 1). Masses did not involve the corpus cavernosum and both testes. The overlying skin was diffusely dark with no cutaneous ulceration.

After full history taking and physical examination, followed by patient counselling, the decision was made to proceed with surgical excision and reconstruction. Full skin excision was required in these patients, because the granulomas were extensive; involving subcutaneous tissue of the penile shaft with extension into the

overlying penile skin. The different approaches available, including immediate skin excision or replacement, as well as, trial at skin preservation, will be discussed below. The fibrotic skin and subcutaneous tissue were circumferentially excised from the corona distally to the scrotum proximally down to the level of Buck's fascia. Thick split skin grafts, harvested from the inner thigh, were used to cover the denuded penile shaft in all three cases. All three grafts were minimally fenestrated to prevent hematoma formation under the grafts.

All three patients were discharged five to seven days post-operatively, with full graft take. Wounds were fully healed at the outpatient review, one month post-operatively (Figure 2). All three patients were able to achieve full erection with normal sexual intercourse with their partners after the operation. Histopathological examination results were consistent with lipogranuloma; where two were induced by silicone and one by paraffin oil.

Discussion

Mineral oil injections, used to enlarge penis contours, were popular in early 1900. Currently, penile augmentations through foreign material injections are still practice worldwide by non-medical practitioners; despite the severe destructive effects that have been recognized and described above. Local complications include infection, ulceration, local migration, and cavernosal invasion; which usually leads to functional impairment. Systemic complications include foreign body embolization, organ infarction, and death. Rollins et al. reported a sudden death case, secondary to disseminated lipogranulomas to the lung, causing acute severe pulmonary oedema (1).

Granuloma formation is caused by a natural host response to walled off exogenous substances with multinucleated giant cell and chronic inflammatory cells. However, they are too large to be broken down naturally. Immunological and

Table 1: Patient Demographics

Patient	Age	Foreign material used	Initial indication	Occupation	Location of procedure	Time of presentation
1	32	Silicone	Group trial	Construction workers	Friend's house	5 years
2	46	Silicone	Own initiative	Businessman	Hotel	5 years
3	59	Parafine Oil	Own initiative	Government servant	Hotel	4 years

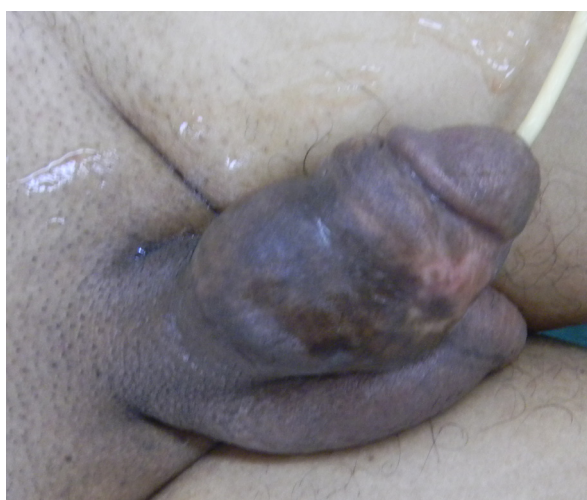

Figure 1: Pre-operative image showing grossly swollen, disfigured penis with masses. The overlying skin was diffusely dark.

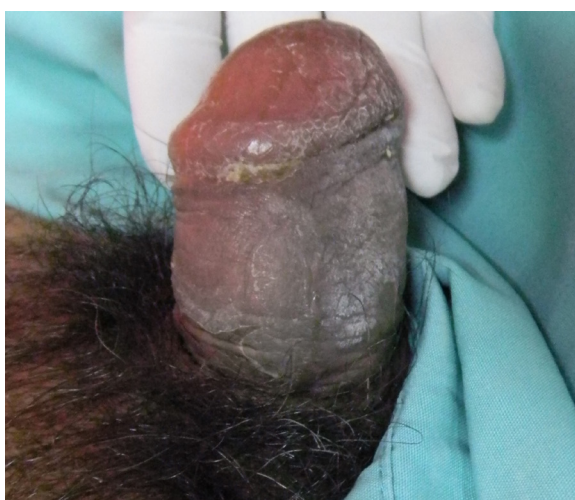


Figure 2: Post-operative image showing the skin graft was fully taken and healthy. The penis appeared grossly normal.

inflammation reaction, induced by silicone and paraffin oil, are similar; as shown in our case series. Granulomatous and fibrotic reactions occur in the subcutaneous fat from the injection of silicone or mineral oil. This is known as lipogranulomas, due to the recipient tissue involved. Physically, the lipogranulomas appears as firm, disfiguring subcutaneous masses, with surrounding skin fibrosis, and thickening. The patients were told that this expected augmentation would be a result of immunological reaction. However, the actual outcome was disastrous, resulting in a severely disfigured and swollen penis, which was unable to achieve erection.

The main aim of treatment is to restore penis function, as a conduit for bodily fluids and as a sexual organ; with an acceptable cosmetic appearance. The medical treatment of sclerosing lipogranuloma involves the use of antibiotics and topical and/or systemic steroids. Corticosteroid therapy is effective in treating primary sclerosing lipogranuloma (2). However, for foreign body induced lipogranuloma, no corticosteroid treated cases have been reported.

Penile lipogranuloma is best treated surgically. Granulomatous skin needs to be completely excised. Primary closure offers the best cosmetic and functional outcome, but is usually impossible, due to the large defect size. Wound closure using a scrotal skin flap, Cecil's inlay operation, and a Split thickness Skin Graft (SSG), are the more commonly used options (3). Penile split thickness skin grafts demonstrate good graft survival and remains the most successful management technique for a denuded penis (4). Our series showed excellent reconstructive outcomes using SSG. Lee et al described using a scrotal skin flap supplied by posterior branch of internal pudendal artery for wound closure in their series of 19 patients; of which 17 patients were treated successfully (3). If the granulomas are not extensive, granulomas mass may be excised via circumferential subcoronal incision with skin preservation; which was demonstrated by Shaeer et al., (5). This technique is not possible for our patients, because the granulomas extended to the penile skin circumferentially. Any remaining skin (following degloving) would be at a high risk of being compromised vascularity; leading to eventual necrosis.

Penile augmentation using foreign body injections can be a misleading concept that has been capitalised by unethical practises. From case series reported worldwide, the majority of foreign body injections were performed by non-specialist personnel. For this reason, we should increase

public awareness on the detrimental effects of such injections. In an ideal world, strict legal action would limit unethical procedures taking place, but this calls for continuous widespread education and enforcement from various organisations.

Authors' Contribution

Conception and design, drafting of the article, critical revision of the article for important intellectual content, final approval of the article, and collection and assembly of data: FXE

Conception and design, analysis and interpretation of the data, drafting of the article, final approval of the article, and obtaining of funding: FHI, RIH, ZMZ

Critical revision of the article for important intellectual content, provision of study materials or patients, and administrative, technical, or logistic support: FHI, RIH, ZMZ

Critical revision of the article for important intellectual content, administrative, technical, or logistic support, and collection and assembly of data: MFA

Correspondence

Dr Fam Xeng Inn
MD (UKM), MRCS (IE)
Department of Surgery
Universiti Kebangsaan Malaysia Medical Centre
Jalan Yaakob Latiff
Cheras 56000
Kuala Lumpur, Malaysia
Tel: +6012-723 9108
Fax: +603-9145 6684
Email: xenginn@gmail.com

Reference

1. Rollin CE, Reiber G, Guinee DG, Lie JT. Desseminated lipogranuloma and sudden death from self-administered mineral oil injection. *Am J Forensic Med Pathol.* 1997;**18(1)**:100–103.
2. Lawrentschuk N, Angus D, Bolton DM. Sclerosing lipogranuloma of the genitalia treated with corticosteroids. *Int Urol Nephrol.* 2006;**38(1)**: 97–99.
3. Lee T, Choi HR, Lee YT, Lee YH. Paraffinoma of the penis. *Yonsei Med J.* 1994;**35(3)**:344–348.
4. Cavalcanti AG, Hazan A, Favorito. Surgical reconstruction after liquid silicone injection for penile augmentation. *Plast Reconstr Surg.* 2006;**117(5)**:1160–1161.
5. Shaeer O., Shaeer K. Delayed complications of gel injection for penile girth augmentation. *J Sex Med.* 2009;**6(7)**:2072–2078.