

Functional neural correlates of emotional expression processing deficits in behavioural variant frontotemporal dementia

Karim Virani, MSc; Sarah Jesso, BA; Andrew Kertesz, MD;
Derek Mitchell, PhD; Elizabeth Finger, MD

Virani — Graduate Program in Neuroscience, University of Western Ontario; Jesso, Kertesz, Finger — Cognitive Neurology and Alzheimer Research Centre, St. Joseph's Hospital; Kertesz, Finger — Department of Clinical Neurological Sciences, Schulich School of Medicine, University of Western Ontario; Mitchell, Finger — Department of Psychology, University of Western Ontario; Mitchell — Departments of Psychiatry and Anatomy and Cell Biology and the Centre for Brain and Mind, Schulich School of Medicine, University of Western Ontario, London, Ont., Canada

Background: Frontotemporal dementia (FTD) is a neurodegenerative disorder resulting in social-cognitive deficits partially attributed to abnormalities processing social cues, such as facial expressions. However, to our knowledge, the functional neuroanatomy of deficient social cue processing in individuals with FTD has not been examined. The objective of this study was to delineate the functional abnormalities underlying altered facial expression processing in individuals with FTD using functional magnetic resonance imaging (fMRI). **Methods:** Patients meeting Neary criteria for behavioural variant FTD (bvFTD) with supportive neuroimaging and 18 age-matched healthy controls completed an implicit facial expression task during fMRI. We conducted volumetric brain morphometry to correct functional imaging data for volume differences. **Results:** We included 20 patients with bvFTD and 18 controls in our study. The results demonstrate emotion-specific functional abnormalities in frontal and limbic regions in patients with bvFTD. Patients also showed decreased activity in posterior ventral visual regions, specifically the fusiform cortex, possibly reflecting reduced afferent input from limbic regions. Finally, bvFTD was associated with increased activity in posterior regions, including the inferior parietal cortex. **Limitations:** Autopsy validation of frontotemporal dementia is not yet available for this cohort. **Conclusion:** Together, these findings suggest that fMRI combined with tasks targeting social-cognitive deficits is a powerful technique to objectively measure neural systems involved in emotion processing in individuals with bvFTD. As viewing emotional expressions is known to engage many of the same neural systems that are active when experiencing the emotion itself, fMRI during expression processing provides a novel window into the emotions of patients with FTD.

Introduction

Behavioural variant frontotemporal dementia (bvFTD) is a neurodegenerative disorder characterized by progressive dysfunction in social behaviour typically beginning in midlife (50s–60s). A hallmark of bvFTD is the loss of empathy for others, a symptom thought to be partially accounted for by a reduction in emotion recognition.¹ Facial expressions are one way in which we communicate emotional information critical for successful social

behaviour.^{2,3} Deficient facial expression recognition, particularly for negative expressions, such as fear and anger, is associated with inappropriate social behaviours.^{4,5} Previous studies have demonstrated that patients with bvFTD with frontally or temporally predominant atrophy show deficits in facial expression recognition, while general face processing abilities, such as facial identity and gender discrimination are preserved.^{6–8} Whereas a growing body of research has associated regions of atrophy with bvFTD clinical symptoms, to our knowledge, the

Correspondence to: E. Finger, Department of Clinical Neurological Sciences, University of Western Ontario, B10-004, 339 Windermere Rd., London ON N6A 5A5; Elizabeth.Finger@lhsc.on.ca

J Psychiatry Neurosci 2013;38(3):174–82.

Submitted Jan. 15, 2012; Revised May 29, July 5, 2012; Accepted July 10, 2012.

DOI: 10.1503/jpn.120008

functional neural correlates of the core emotion processing deficits in individuals with bvFTD remain unexamined.

The neural regions supporting facial expression processing in healthy adults show great overlap with the neural regions affected early in the course of bvFTD. In the early stages of bvFTD, atrophy is predominant in a frontal paralimbic network, including the anterior cingulate cortex, anterior insula, frontal pole, amygdala and striatum, with frequent right hemisphere predominance.^{9,10} In patients with bvFTD who later experience semantic deficits in addition to behavioural and personality symptoms, atrophy is commonly observed bilaterally in the temporal poles, amygdala, ventromedial prefrontal cortex, insula and inferoposterior temporal regions.⁹ A number of lesion and functional neuroimaging studies have delineated the neural regions associated with healthy facial expression processing. Regions of the temporal-occipital cortex, namely the fusiform gyrus, are robustly activated when viewing faces and processing basic facial features.^{11,12} Activity in this region is augmented for emotional relative to neutral expressions.^{13,14} Emotional faces also activate frontotemporal limbic regions, with some unique emotion-specific patterns. The amygdala is typically active when fearful, sad or happy faces are viewed.^{15,16} Rostral anterior cingulate/ventromedial prefrontal cortex activity is greatest when viewing happy and fearful faces.¹⁵ In contrast, the anterior insula and ventrolateral prefrontal cortex are activated by disgusted and angry facial expressions, respectively.^{15,17,18}

Functional MRI (fMRI) combined with targeted cognitive tasks offers a potentially powerful technique to detect neural dysfunction directly related to symptomatology associated with a neurodegenerative disease prior to detectable atrophy.¹⁹ In the present study, we used fMRI while correcting for voxel-wise atrophy across the brain to index the functional brain activity during implicit emotional facial expression processing in patients with bvFTD and matched controls. We hypothesized that patients with bvFTD would show decreased blood oxygen level-dependent (BOLD) signal, following corrections for atrophy, in frontotemporal regions that are both directly affected by bvFTD pathology and critical for facial expression processing. Specifically, we predicted that patients with bvFTD would show reduced BOLD signal compared with controls in the ventrolateral prefrontal cortex (inferior frontal gyrus) and anterior insula while viewing angry expressions, in the amygdala while viewing fearful expressions and in the insula while viewing disgusted expressions. Second, owing to functional abnormalities in limbic regions, we predicted that patients with bvFTD would show indirect reductions in BOLD signal in posterior downstream targets of the limbic system that are typically unaffected in these patients, but that perform a more general role in face processing (e.g., the fusiform cortex.) Finally, we also hypothesized that patients with bvFTD may show increased BOLD activity reflecting compensatory efforts in regions unaffected by FTD pathology. We predicted that functional abnormalities would be present even after a whole-brain voxel-wise grey matter correction for atrophy/volume differences, representing a critical target in the development of tools for early diagnosis and treatment.

Methods

Participants

We recruited patients from the Cognitive Neurology and Alzheimer Research Centre at St. Joseph's Hospital in London, Ont., Canada. Patients included in the study met Nears criteria for bvFTD²⁰ with supportive neuroimaging (MRI, computed tomography [CT] or single-photon emission computed tomography [SPECT]). Study exclusion criteria included any history of traumatic brain injury or other neurologic or psychiatric disorder apart from bvFTD. Eligible patients were assessed with the Nears criteria and the revised international criteria for bvFTD.²¹ We recruited healthy controls through announcements made at the local FTD caregiver support group and phone calls to the centre's volunteer pool. Patients with bvFTD were matched as closely as possible to healthy controls in age, sex, handedness and education. If participants were unable to complete fMRI scanning successfully (e.g., scans terminated early owing to claustrophobia or excessive movement greater than 6 mm), we excluded them from our analyses, as per our prior protocols.²² The Ethics Board at the University of Western Ontario approved our study protocol, and all participants provided written informed consent.

Functional MRI task

Participants were presented with photographs of angry, disgusted, fearful, happy and sad facial expressions from the Karolinska Directed Emotional Faces, a cross-culturally validated stimulus set²³ (Fig. 1). Expressions were morphed with neutral facial expressions from the same actors using FantaMorph version 4 software (Abrosoft) to create 2 levels of emotional intensity (40% and 100% intensity). A total of 160 different faces were available for random selection for each run of the paradigm. As in previous studies,¹⁷ participants were required to indicate the sex of the actors via button presses. We selected an implicit facial emotion processing task over an explicit one to reduce confounds related to emotion recognition deficits in patients with FTD. Implicit




Fig. 1: Emotional facial expression functional magnetic resonance imaging task. Trial schematic depicting the time course for 2 consecutive trials. The first face shows a disgusted man at 40% emotional intensity; the second shows a fearful woman at 100% emotional intensity.

emotion recognition tasks are known to activate emotion related regions with even greater limbic system activation compared with explicit emotion recognition paradigms.²⁴ Stimuli were presented in a rapid event-related manner using E-Prime software (Psychology Software Tools Inc.). Participants completed 3 independent runs of the task, each comprising 104 randomly occurring trials: 80 emotional faces presented for 2.5 seconds followed by a fixation cross for 0.5 seconds, and 24 interspersed “jittered” trials consisting of a fixation cross presented for 3 seconds. Each run lasted 342 seconds. Button presses to indicate sex occurred during the 2.5 seconds during which the facial expression was displayed. All participants completed practice trials outside of the scanner to ensure comprehension of task instructions.

Image acquisition

Data were acquired using a 3 T Siemens Tim Trio MRI scanner with a 32-channel head coil. Functional data were acquired using a T_2^* -gradient echo-planar imaging sequence: 45 contiguous slices of 2×2 mm in plane, slice thickness 2.5 mm, repetition time (TR) 3000 ms, echo time (TE) 30 ms, field of view (FOV) 24 cm, 120×120 matrix. This sequence generated a voxel resolution of $2 \times 2 \times 2.5$ mm. After the final task run, we obtained a high-resolution structural T_1 -weighted acquisition of the complete brain volume in the axial plane: TR 2300 ms, TE 4.25 ms, FOV 25.6 cm, 192 slices, voxel size 1 mm^3 , 256×256 matrix.

Image processing and analysis

Structural imaging

To account for grey matter volume differences influencing the fMRI signal, we performed a volumetric brain analysis. Volume differences were corrected by including a covariate into the fMRI analysis reflecting participants' voxel-wise grey matter tissue probabilities. We analyzed the T_1 -weighted MRI images using FSL tools²⁵ (www.fmrib.ox.ac.uk/fsl). First, structural images were brain-extracted using BET.²⁶ Second, tissue was segmented into grey matter, white matter and cerebrospinal fluid using FAST4.²⁷ The resulting grey matter volume images were aligned to the Montreal Neurological Institute (MNI) 152 template using the affine registration tool FLIRT and smoothed with an isotropic Gaussian kernel with a sigma of 4 mm (~9 mm full-width at half-maximum [FWHM]). Prior to fMRI analysis, we realigned grey matter probability maps to Talarach standard space (see Appendix 1, Fig. S1, available at cma.ca/jpn, for voxel-based morphometry group contrast map). We entered voxel-wise grey matter probabilities as a covariate for the functional contrasts, as described in the functional imaging section.

Functional imaging

We preprocessed and analyzed the fMRI data using the Analysis of Functional NeuroImages (AFNI)²⁸ software package according to prior published protocols.^{22,29} Participants' functional data were spatially smoothed with a 4 mm isotropic Gaussian kernel (~9 mm FWHM). Regression coefficients rep-

resenting the percent signal change relative to the mean were created for each emotion/intensity trial by convolving the stimulus events with a γ -variate basis function to account for the slow hemodynamic response. A baseline plus linear drift and quadratic trend were modelled to the time series of each voxel to correct for voxel-wise correlated drifting, producing a β coefficient and t statistic for each voxel and regressor. We registered participants' anatomic scans to Talarach standard space, allowing each participant's functional data to be aligned to their own normalized anatomic template for group analysis. Examination of participants' movement parameters demonstrated no significant difference between maximum movement across all task runs in patients with bvFTD compared with controls ($F_{1,37} < 1$, $p = 0.34$; patient mean 2.7 (standard deviation [SD] 1.8 mm); control mean 2.1 [SD 1.3] mm).

Participants' regressors for 40% and 100% emotional intensity were initially averaged within emotions. Planned voxel-wise t tests were performed to characterize emotion-specific group differences in BOLD signal. We conducted t tests within AFNI to permit simultaneous inclusion of voxel-wise measures of grey matter probabilities to covary for atrophy using the 3dttst++ program in AFNI. To elucidate changes in activation patterns in response to emotional faces, we compared patients with bvFTD with healthy controls. Whole-brain contrasts were thresholded at $p < 0.005$ and corrected for multiple comparisons to $p < 0.05$ using AFNI's 3dClustSim program with 10 000 Monte Carlo simulations on a whole-brain echo planar imaging matrix. The one exception was the amygdala, for which we applied a small volume correction ($p < 0.05$, corrected) because of a priori predictions concerning this structure's involvement in face processing.¹⁵

Results

Participants

Between Apr. 21, 2008, and Sept. 21, 2010, 28 patients with bvFTD were identified for possible participation in the study. Following publication of the revised international criteria for bvFTD,²¹ review of participants demonstrated that all 28 patients with bvFTD met the revised criteria. Three patients declined to participate, and 1 patient was ineligible owing to a pacemaker. Thus, 24 patients with bvFTD were initially enrolled in the study. We identified 23 eligible controls; 3 declined to participate (2 men and 1 woman with a mean age of 67 yr), and 2 had contraindications to MRI scanning at 3 T. Thus, 18 healthy controls were initially enrolled. Twenty patients with bvFTD successfully completed the fMRI scan, whereas 4 patients' scans were terminated early owing to claustrophobia or excessive movement greater than 6 mm. Of the 20 patients who completed the scan, 9 had diagnoses of frontal variant bvFTD and 11 had temporal variant FTD based on clinical MRI or SPECT scans. Participant demographic and clinical characteristics are summarized in Table 1.

Participant characteristics and scores on standardized neuropsychological tasks are described in detail in Table 1. Our χ^2 analysis revealed no significant group differences for sex ($\chi^2_1 = 0.2$, $p = 0.88$) or handedness ($\chi^2_2 = 1.3$, $p = 0.51$). As

t tests demonstrated a significant difference in years of education (Table 1), all functional imaging results were assessed using analyses of covariance, with years of education as a covariate and the β weights of the BOLD signal as the dependent variable for each significant region and contrast. No significant effects of education were found for any cluster, and all clusters reported in the subsequent sections remained significant when education was included as a covariate.

Behavioural data

All participants made successful sex discriminations in the majority of trials. Healthy controls performed the sex discrimination with greater accuracy than patients with bvFTD (91%–95% trials correct v. 76%–77% trials correct, all $p < 0.05$; Appendix 1, Table S1). We observed that patients with bvFTD were often inconsistent with the response buttons used for male versus female sex. Thus, we evaluated sex discrimination data that were available for 12 of the 20 patients with bvFTD from an independent study that presented a subset of 16 of the same facial stimuli for which patients verbally indicated the sex of the actors. When responses were reported verbally, performance improved (mean 88.54%, SD 9.82%) relative to the button-press sex discrimination task in the present study. Although patients with bvFTD responded to substantially fewer trials than controls (Appendix 1, Table S1), patients' overall response frequency remained high (mean 85.2%, SD 15.0%). Given these findings, while the main contrasts of the functional imaging data were conducted on all trials for which a response was made, follow-

up analyses were conducted using only correct response trials to ensure that the results in the sections that follow were not due the greater number of incorrect trials in the bvFTD group.

Imaging data for patients with bvFTD versus healthy controls

The neural regions demonstrating significant BOLD differences between patients with bvFTD and healthy controls are listed in Table 2.

Anger

As predicted, relative to healthy controls, patients with bvFTD showed reduced activity in the inferior frontal gyrus while viewing angry expressions (Fig. 2A). Consistent with

Table 2: Neural regions demonstrating significant BOLD differences between patients with bvFTD and healthy controls during emotional face processing

| Facial expression; group contrast; brain region* | BA | Volume, mm ³ | MNI coordinate | | | <i>t</i> value |
|--|------|-------------------------|----------------|----------|----------|----------------|
| | | | <i>x</i> | <i>y</i> | <i>z</i> | |
| Angry expressions | | | | | | |
| bvFTD < controls | | | | | | |
| Right inferior frontal gyrus | 47 | 189 | 23 | 9 | -22 | -3.78 |
| Left fusiform gyrus | 37 | 675 | -35 | -51 | -14 | -3.18 |
| Right cuneus | 17 | 324 | 23 | -89 | 8 | -3.43 |
| bvFTD > controls | | | | | | |
| Left posterior cingulate gyrus | 31 | 351 | -2 | -46 | 26 | 3.12 |
| Right inferior parietal lobule | 39 | 270 | 38 | -62 | 32 | 3.66 |
| Disgusted expressions | | | | | | |
| bvFTD < controls | | | | | | |
| Right insula | 13 | 432 | 38 | 14 | 7 | -3.21 |
| Left insula | 13 | 270 | -35 | 23 | 4 | -3.49 |
| Left lingual/fusiform gyrus | 18 | 324 | -20 | -73 | -5 | -3.41 |
| Right middle occipital gyrus | 18 | 351 | 23 | -89 | 11 | -3.12 |
| Happy expressions | | | | | | |
| bvFTD < controls | | | | | | |
| Left amygdala† | NA | 648 | -26 | -4 | -26 | -2.31 |
| bvFTD > controls | | | | | | |
| Right inferior parietal lobule | 39 | 432 | 41 | -69 | 38 | 3.05 |
| Fearful expressions | | | | | | |
| bvFTD < controls | | | | | | |
| Left medial frontal gyrus | 6 | 270 | -2 | -4 | 52 | -3.26 |
| Left lingual/fusiform gyrus | 18 | 216 | -5 | -91 | -17 | -3.60 |
| Left middle occipital gyrus | 18 | 216 | -20 | -92 | 11 | -3.23 |
| Right cuneus | 17 | 432 | 23 | -89 | 8 | -3.25 |
| Sad expressions | | | | | | |
| bvFTD < controls | | | | | | |
| Left anterior cingulate gyrus | 6/24 | 459 | -2 | 7 | 51 | -4.04 |
| Left lingual/fusiform gyrus | 18 | 270 | -17 | 73 | -5 | -3.08 |
| Right insula | 13 | 243 | 44 | -14 | 8 | -4.03 |
| Right cuneus | 17 | 324 | 23 | -89 | 8 | -3.45 |
| Left precuneus | 7 | 324 | -8 | -81 | 44 | -3.12 |
| Right superior frontal gyrus | 9 | 297 | 32 | 49 | 35 | -3.27 |
| Right inferior parietal lobule | 40 | 297 | 41 | 34 | 34 | -3.46 |

BA = Brodmann area; BOLD = blood oxygen level-dependent; bvFTD = behavioural variant frontotemporal dementia; MNI = Montreal Neurological Institute.

*All regions were corrected for whole-brain voxel-wise grey matter volumes.

Hemispheric location, BA, volume, MNI coordinates at the centre of peak activation and maximum activity (*t* value) for each significant cluster are shown. Functional threshold was set at $p < 0.005$; $p < 0.05$, corrected.

† $p < 0.05$; $p < 0.05$, small-volume corrected.

Table 1: Participant demographic and neuropsychological characteristics

| Characteristic | Group; mean (SD)* | | Degrees of freedom | <i>p</i> value‡ |
|----------------------------|-------------------|-------------|--------------------|-----------------|
| | Controls | bvFTD† | | |
| Age, yr | 62.4 (10.8) | 65.3 (8.1) | 36 | 0.30 |
| Sex, male: female, no. | 13:5 | 15:5 | 1 | 0.88 |
| Handedness right:left, no. | 16:2 | 18:1§ | 1 | 0.51 |
| Education, yr | 15.1 (3.5) | 11.3 (3.0) | 36 | 0.001 |
| Illness duration, yr | NA | 5.4 (3.3) | NA | NA |
| MMSE | 27.1 (4.2) | 20.6 (6.9) | 35 | 0.002 |
| Immediate prose recall | 9.9 (4.1) | 4.3 (3.7) | 29 | < 0.001 |
| Delayed prose recall | 8.9 (4.2) | 3.0 (3.5) | 29 | < 0.001 |
| Letter fluency | 31.8 (15.5) | 17.6 (11.8) | 32 | 0.006 |
| Semantic fluency | 15.4 (6.7) | 9.6 (6.3) | 32 | 0.010 |
| Object naming | 19.5 (1.5) | 16.6 (4.4) | 28 | 0.020 |
| Spontaneous clock draw | 8.5 (2.0) | 7.9 (2.5) | 29 | 0.41 |
| Clock copying | 9.3 (1.3) | 8.2 (2.4) | 28 | 0.11 |
| Trails A, s | 38.6 (11.1) | 55.5 (29.8) | 27 | 0.05 |
| ANART | 13.4 (8.9) | 33.8 (8.7) | 27 | < 0.001 |
| WCST categories | 5.5 (0.9) | 3.1 (2.1) | 24 | 0.001 |

ANART = American National Adult Reading Test; bvFTD = behavioural variant frontotemporal dementia; MMSE = Mini Mental Status Examination; SD = standard deviation; Trails A = Trail Making Test A; WCST = Wisconsin Card Sorting Task.

*Unless otherwise indicated.

†Not all patients completed all neuropsychological tests (Appendix 1, Table S2, for neuropsychological test sample sizes).

‡Values are bvFTD compared with controls for *t* tests. We used the χ^2 analysis for sex and handedness.

§One patient with bvFTD was ambidextrous.

predictions that secondary reductions would be observed in temporal-occipital visual areas in patients with bvFTD, we observed reduced BOLD signal in the fusiform gyrus (Fig. 2B) and cuneus in patients compared with controls. In contrast, we observed increased BOLD signal in patients with bvFTD compared with controls in the inferior parietal lobule and posterior cingulate gyrus (Fig. 2C).

Disgust

Consistent with the role of the insula in the processing of disgusted stimuli and the involvement of this region early in the course of bvFTD, patients with bvFTD demonstrated decreased BOLD signal in the insula in response to disgusted facial expressions (Fig. 2D). In addition, patients showed reduced activation in the lingual gyrus (extending into the fusiform cortex) and middle occipital gyrus compared with controls.

Happiness

Relative to healthy controls, patients with bvFTD demonstrated decreased BOLD signal in the amygdala (Fig. 2E) and increased BOLD signal in the inferior parietal lobule.

Fear

Patients with bvFTD demonstrated decreased BOLD signal relative to controls in the medial frontal gyrus, lingual gyrus (extending into the fusiform cortex), middle occipital gyrus and cuneus while viewing fearful expressions.

Sadness

Compared with healthy controls, patients with bvFTD demonstrated decreased BOLD signal in the anterior cingulate gyrus (Appendix 1, Fig. S2), lingual gyrus (extending into the fusiform cortex), insula, cuneus, precuneus, superior frontal gyrus and inferior parietal lobule while viewing sad facial expressions.

Emotional intensity contrast

We conducted an additional contrast to further explore the association between bvFTD and increased activity in posterior parietal and cingulate cortices while viewing angry and happy expressions. Recent evidence implicates parietal regions in stabilizing goal-relevant stimuli that are weakly represented, perhaps owing to reduced afferent input from

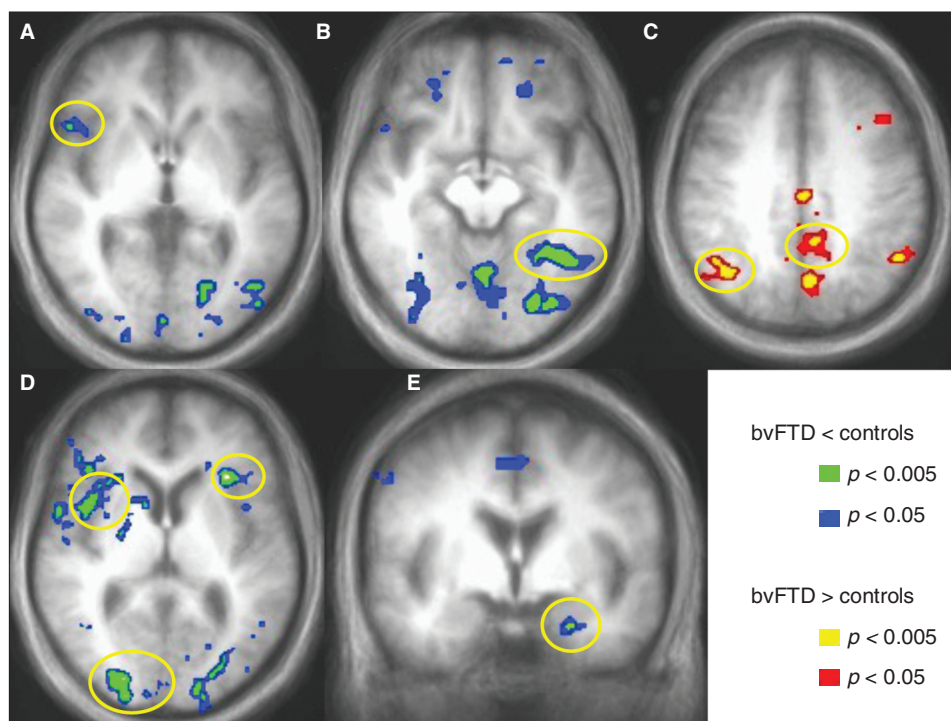


Fig. 2: Regions demonstrating significant blood oxygen level–dependent (BOLD) signal differences during emotional facial expressions in patients with behavioural variant frontotemporal dementia (bvFTD) compared with controls. During angry expression processing, patients with bvFTD demonstrate decreased BOLD signal (blue/green) compared with controls in the (A) right ventrolateral prefrontal cortex and (B) ventral visual stream, specifically the left fusiform gyrus. In contrast, patients with bvFTD showed increased BOLD signal (red/yellow) in the (C) right inferior parietal lobule and left posterior cingulate gyrus. (D) During disgusted expression processing, decreased BOLD signal in the bilateral insula and right middle occipital gyrus is observed in patients with bvFTD compared with controls. (E) During happy expression processing, decreased BOLD signal in the left amygdala is observed in patients with bvFTD compared with controls. Significant clusters are shown at $p < 0.005$ and at $p < 0.05$ to illustrate the extent of the activations. Statistical maps are corrected for voxel-wise grey matter differences. All images are displayed in radiological convention.

emotion-related brain regions.^{30,31} Accordingly, we hypothesized that increased activity in this network may reflect increased top-down efforts to compensate for reduced limbic input to the ventral visual stream in patients with bvFTD. We predicted that compared with controls, patients with bvFTD would show augmented posterior parietal and posterior cingulate cortex activation during low- compared with high-intensity emotional faces (i.e., when task demands are greatest). To test this hypothesis, we examined differences between patients with bvFTD and controls for both high- (100%) and low-intensity (40%) stimuli across all emotional expressions. During high-intensity expression processing, patients with bvFTD relative to controls showed increased activity only in the right inferior parietal lobule. Consistent with our hypothesis, during low-intensity emotional face processing, patients with bvFTD showed increased activation relative to controls in an expanded dorsal network, including both the right and left inferior parietal lobules, posterior cingulate cortex and precuneus (Fig. 3 and Table 3).

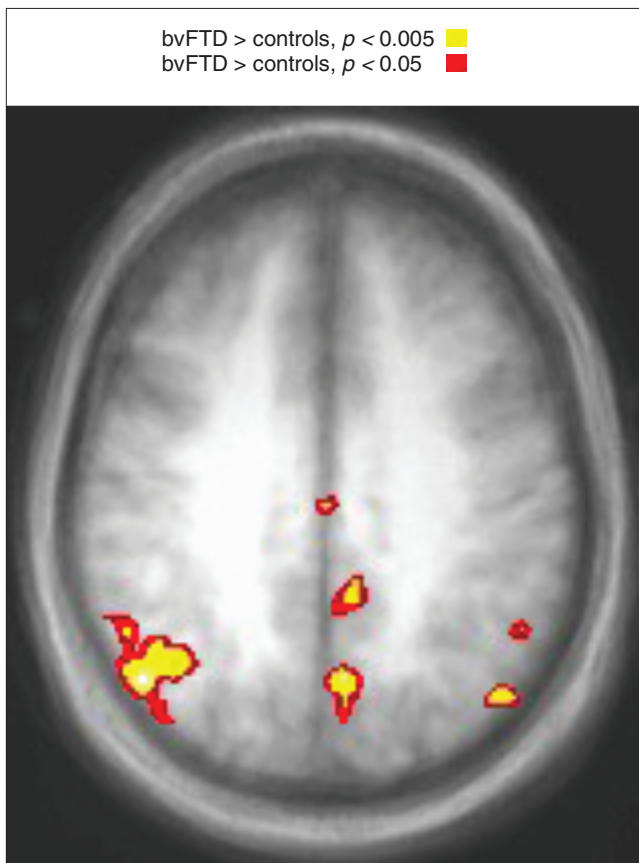


Fig. 3: Contrast of low-intensity (40%) facial expressions in patients with behavioural variant frontotemporal dementia (bvFTD) compared with controls demonstrating increased blood oxygen level-dependent signal (red/yellow) in patients with bvFTD in dorsal regions, including the bilateral inferior parietal lobule, left posterior cingulate cortex and left precuneus. Significant clusters are shown at $p < 0.005$ and also at $p < 0.05$ to illustrate the extent of activation. Statistical maps are corrected for voxel-wise grey matter differences. All images are displayed in radiological convention.

Subanalysis of only correct responses

Owing to the difference in the percentage of correct responses between the patient and control groups, we conducted a follow-up analysis on the BOLD data, including only those trials in which a correct sex discrimination response was made. For each emotional expression, the main pattern of group differences in BOLD signal observed was unchanged from the original analysis (Appendix 1, Figs. S3–S8). This included reduced BOLD activity in the fusiform gyrus/posterior occipital/temporal cortex while viewing angry, disgusted, fearful and sad faces; reduced insula BOLD signal while viewing disgusted faces; reduced amygdala activation while viewing happy faces; and increased right inferior parietal lobule and posterior cingulate cortex BOLD signal in response to angry and happy faces.

Discussion

The present study is, to our knowledge, the first study of the functional activation patterns underlying processing of a social cue in individuals with FTD. We found that fMRI was sensitive in detecting changes in BOLD signal in patients with bvFTD within frontotemporal regions previously implicated in healthy emotional processing and affected by bvFTD pathology, even after correcting for measureable grey matter loss.

The present study is also one of the first to demonstrate that task-based fMRI is feasible in patients with bvFTD despite the frequent presence of inattention and motoric restlessness. One prior study of 7 patients with FTD successfully compared fMRI activation patterns during a working memory test.³² Consideration of task length, patient comfort in the scanner and clear, simple instructions enabled us to achieve usable scans in 83% of the patients who participated. Of the 4 patients who could not complete the scan, 3 had frontal variant and 1 had temporal variant bvFTD, suggesting that patients with temporal variant FTD may be most amenable to the requirements of such imaging protocols. Future use of task-based fMRI studies in patients with bvFTD may demonstrate

Table 3: Intensity contrasts between patients with bvFTD and healthy controls

| Intensity; group contrast; brain region* | Volume, BA | Volume, mm ³ | MNI coordinate | | | t value |
|--|------------|-------------------------|----------------|-----|----|---------|
| | | | x | y | z | |
| 100% intensity | | | | | | |
| bvFTD > controls | | | | | | |
| Right inferior parietal lobule† | 39 | 189 | 38 | -62 | 32 | 3.24 |
| 40% intensity | | | | | | |
| bvFTD > controls | | | | | | |
| Right inferior parietal lobule | 39 | 729 | 47 | -65 | 35 | 3.84 |
| Left inferior parietal lobule† | 39 | 54 | 2 | 12 | 46 | 3.19 |
| Left posterior cingulate † | 31 | 108 | -5 | -59 | 26 | 3.07 |
| Left precuneus† | 7 | 81 | -5 | -65 | 35 | 3.03 |

BA = Brodmann area; bvFTD = behavioural variant frontotemporal dementia; MNI = Montreal Neurological Institute.

*All regions were corrected for voxel-wise grey matter volume differences. Functional threshold was set at $p < 0.005$; $p < 0.05$, corrected.

† $p < 0.005$; uncorrected.

the potential of this approach to reveal deficits in structures before they are apparent in anatomic scans and further illuminate the neural functional abnormalities associated with social and decision-making deficits characteristic of the disorder.

Examination of the neural correlates of emotional expression processing also provides insight into the symptomatology of bvFTD. A number of neural regions activated by emotional facial expressions are also active when the observer experiences that same emotion.^{33,34} This “mirroring” of another’s emotional expressions is thought to generate internal representations of both the motor features as well as other regions relevant to the significance of the specific emotion.³³ Supporting this model, patients with bvFTD showed decreased BOLD activation within the insular cortex in response to disgusted facial expressions, consistent with the known role of this region in normal disgust processing¹⁸ and in early bvFTD pathology.¹⁰ Insula activation in response to disgusted faces may reflect the awareness of another’s gustatory processes;³⁵ thus, the observed effects may underlie some patients’ own insensitivity toward disgusted social cues and toward environmental stimuli that normally evoke disgust (e.g., rotten or raw foods). When viewing angry faces, patients with bvFTD demonstrated decreased BOLD activation in the ventrolateral prefrontal cortex. Previous work has associated ventrolateral prefrontal cortical activation with angry expression processing¹⁷ and in modulating socially adaptive behaviour in response to social cues.^{4,29} Similarly, ventrolateral prefrontal cortex atrophy has been associated with inappropriate social behaviours in patients with FTD.³⁶

Contrary to predictions, we did not find significant group differences in amygdala activation during the presentation of fearful faces despite the frequent association of this region with fearful face processing in healthy adults. Further examination of the data indicates that there was limited amygdala activity relative to baseline in response to fearful faces in both patients and controls. Our sample of controls was older than that used in most studies examining the neural correlates of facial expression processing. Importantly, older compared with younger adults typically show less amygdala activation when viewing negative facial expressions and pictures, but show increased amygdala activation when viewing positive stimuli.³⁷ This age-related “positivity effect” has been explained as an increased allocation of cognitive resources toward processing positive emotional stimuli in older adults coupled with a negative emotional stimulus bias in younger adults.³⁸ One possibility is that, in the present study, the reduced allocation of resources to negative stimuli attenuated any existing group effects. This interpretation is supported by the fact that group differences in amygdala reactivity were only observed for happy faces (i.e., the emotion that is particularly likely to activate the amygdala in elderly populations).

Neuroimaging and lesion studies indicate that regions comprising the distributed neural face processing network communicate and influence each other, rather than functioning independently. Functional imaging studies in humans have demonstrated that ventral visual cortices, specifically the lateral fusiform areas, show more activation for emotional (angry, happy, fearful, sad or disgusted) versus neutral faces,^{13–15,30} and

for higher versus lower emotional intensities.³⁹ Research suggests that projections from limbic regions modulate activity in the ventral visual stream, augmenting activation in the fusiform cortex for emotionally salient stimuli.^{14,40–42} Whereas the amygdala responds to crude, low-resolution aspects of emotional faces, the fusiform is implicated in processing higher-resolution features.⁴³ In addition to the fusiform cortex, other visual areas modulated by anterior frontal and limbic structures in response to emotional facial stimuli include the posterior temporal cortex, occipital gyrus, cuneus and lingual gyrus.^{14,16,41} Consistent with these models, we found that patients with bvFTD demonstrated reduced activity in the fusiform cortex and other ventral visual regions while viewing negative emotional expressions (angry, fearful, disgusted and sad faces). We suggest that decreased activation in the ventral visual stream in patients with bvFTD during negative emotional face processing is most likely due to reduced afferent inputs from more anterior frontotemporal and limbic regions.

The present study provides some of the first indications that, at the neural level, patients with bvFTD may show increased activity in regions not directly affected by the disorder during task performance. The regions in which increased activity was observed in patients with bvFTD have been ascribed not only to attentional processes,^{44,45} but also to the default mode network (DMN).⁴⁶ These 2 possibilities prompted us to further examine the BOLD signal data in patients with FTD and controls in these regions (Appendix 1, Fig. S9). In the posterior cingulate cortex, the group difference was driven entirely by the apparent lack of deactivation during the task compared with baseline BOLD signal in patients with FTD. However, in the right angular gyrus and right inferior parietal lobule, patients with bvFTD showed increased BOLD signal compared with their baseline signal in response to angry or happy faces. Interestingly, increased resting state activity was recently reported in a proximal region of the left parietal cortex in patients with bvFTD compared with healthy controls and was attributed to heightened activity in the DMN.⁴⁷ If in the present study the group differences were driven entirely by failure to deactivate the DMN, then we would have expected patients with bvFTD to show activity comparable to their baseline. Instead, the increases suggest that alternate functions, perhaps attentional, of the inferior parietal cortex may be engaged in bvFTD during facial expression viewing. It has been demonstrated that emotion-related subcortical activity serves to boost stimulus representation in the ventral visual system in a bottom-up manner.^{13,30,31} Face perception tasks limiting ventral visual (bottom-up) input have detected increased activity in regions such as the inferior parietal lobule, posterior cingulate cortex, dorsolateral prefrontal cortex and precuneus.^{30,48}

Following this model, in both patients with bvFTD and controls, high-intensity expressions would be expected to generate a greater limbic response than low-intensity expressions, leading to a reduced need for attentional compensation during the viewing of high-intensity faces. Supporting this model, patients with bvFTD showed greater recruitment of the parietal cortex when viewing low- than high-intensity expressions. However, no increase was observed in the dorsolateral

prefrontal cortical regions involved in attentional and orienting responses. One possible explanation for this may be that early pathophysiologic changes in the dorsolateral prefrontal cortex in patients with bvFTD may result in reduced functional activation of this region. In summary, in addition to recent findings of increased DMN-related activity in the left inferior parietal cortex in patients with bvFTD, the present study suggests that the right inferior parietal cortex may also engage in task-driven increases relative to the baseline activity. Further fMRI studies in patients with bvFTD focusing on task performance and attentional demands are required to determine the functional nature of these observed increases.

Limitations

Autopsy confirmation of frontotemporal lobar degeneration in this cohort is still pending; therefore, unintentional inclusion of patients with Alzheimer disease or other diseases involving progressive frontal lobe dysfunction cannot be ruled out. However, as prior studies of patients with Alzheimer disease have shown increased amygdala responses during facial expression processing,⁴⁹ their inadvertent inclusion would have been expected to reduce power in the present study, and thus would be unlikely to account for these results. A second limitation is that although voxel-based morphometry has demonstrated sensitivity in measuring volume differences during varied stages in patients with bvFTD,^{9,10,50} we cannot exclude the possibility that despite the atrophy correction, subtle differences in regional volumes, rather than neuronal dysfunction, could account for the differences in BOLD signal between the groups. Thus, we carefully indicated that the functional differences exceed those of measurable atrophy using these techniques. While we cannot assume a linear relationship between atrophy and the BOLD signal, all regions reported also demonstrated significant group differences even before inclusion of atrophy as a covariate. Although the sample size of 20 patients with bvFTD may limit the generalizability of our findings, this sample size is substantially larger than those in many of the pivotal atrophy and behavioural studies of emotion processing in patients with FTD and is in line with typical sample sizes for fMRI activation studies.

Conclusion

We have demonstrated that fMRI coupled with an emotion processing task can demonstrate functional activation abnormalities in patients with bvFTD. Given the association between viewing emotional expressions and the observer's own internal emotional experiences, this approach offers an exciting means to objectively measure correlates of the internal emotional experience of patients with FTD. The demonstration of these functional differences following atrophy corrections, and comparisons to other voxel-based morphometry studies, suggests that measurable functional abnormalities exceed that of measurable atrophy. Further studies using fMRI combined with symptom-targeting tasks are needed to determine whether this technique can detect early neural dysfunction before substantial, irreversible atrophy is present.


Competing interests: None declared for K. Virani, S. Jesso and A. Kertesz. D. Mitchell has received grant funding through his institution from the National Sciences and Engineering Research Council of Canada, Social Sciences and Humanities Research Council and the Ontario Mental Health Foundation, and receives royalties from Blackwell Publishing. E. Finger received funding for this work through her institution from a Lawson Health Research Institute grant.

Contributors: K. Virani, A. Kertesz, D. Mitchell and E. Finger designed the study. K. Virani, S. Jesso and E. Finger acquired the data, which K. Virani, S. Jesso, D. Mitchell and E. Finger analyzed. K. Virani and E. Finger wrote the article, which K. Virani, S. Jesso, A. Kertesz and D. Mitchell reviewed. All authors approved its publication.

References

- Rankin KP, Kramer JH, Miller BL. Patterns of cognitive and emotional empathy in frontotemporal lobar degeneration. *Cogn Behav Neurol* 2005;18:28-36.
- Blair RJ. Facial expressions, their communicatory functions and neuro-cognitive substrates. *Philos Trans R Soc Lond B Biol Sci* 2003; 358:561-72.
- Darwin C. *The expression of the emotions in man and animals*. London: Albemarle; 1872.
- Blair RJ, Cipolotti L. Impaired social response reversal. A case of 'acquired sociopathy'. *Brain* 2000;123:1122-41.
- Marsh AA, Blair RJ. Deficits in facial affect recognition among antisocial populations: a meta-analysis. *Neurosci Biobehav Rev* 2008;32:454-65.
- Rosen HJ, Pace-Savitsky K, Perry RJ, et al. Recognition of emotion in the frontal and temporal variants of frontotemporal dementia. *Dement Geriatr Cogn Disord* 2004;17:277-81.
- Fernandez-Duque D, Black SE. Impaired recognition of negative facial emotions in patients with frontotemporal dementia. *Neuropsychologia* 2005;43:1673-87.
- Jesso S, Morlog D, Ross S, et al. The effects of oxytocin on social cognition and behaviour in frontotemporal dementia. *Brain* 2011;134: 2493-501.
- Rosen HJ, Gorno-Tempini ML, Goldman WP, et al. Patterns of brain atrophy in frontotemporal dementia and semantic dementia. *Neurology* 2002a;58:198-208.
- Seeley WW, Crawford R, Rascovsky K, et al. Frontal paralimbic network atrophy in very mild behavioral variant frontotemporal dementia. *Arch Neurol* 2008;65:249-55.
- Haxby JV, Hoffman EA, Gobbini MI. The distributed human neural system for face perception. *Trends Cogn Sci* 2000;4:223-33.
- Winston JS, Henson RN, Fine-Goulden MR, et al. fMRI-adaptation reveals dissociable neural representations of identity and expression in face perception. *J Neurophysiol* 2004;92:1830-9.
- Morris JS, Friston KJ, Buchel C, et al. A neuromodulatory role for the human amygdala in processing emotional facial expressions. *Brain* 1998;121:47-57.
- Vuilleumier P, Armony JL, Driver J, et al. Effects of attention and emotion on face processing in the human brain: an event-related fMRI study. *Neuron* 2001;30:829-41.
- Fusar-Poli P, Placentino A, Carletti F, et al. Functional atlas of emotional faces processing: a voxel-based meta-analysis of 105 functional magnetic resonance imaging studies. *J Psychiatry Neurosci* 2009;34:418-32.
- Pessoa L, McKenna M, Gutierrez E, et al. Neural processing of emotional faces requires attention. *Proc Natl Acad Sci U S A* 2002;99: 11458-63.
- Blair RJ, Morris JS, Frith CD, et al. Dissociable neural responses to facial expressions of sadness and anger. *Brain* 1999;122:883-93.
- Phillips ML, Young AW, Senior C, et al. A specific neural substrate for perceiving facial expressions of disgust. *Nature* 1997;389:495-8.
- Dickerson BC, Salat DH, Greve DN, et al. Increased hippocampal activation in mild cognitive impairment compared to normal aging and AD. *Neurology* 2005;65:404-11.

20. Neary D, Snowden JS, Gustafson L, et al. Frontotemporal lobar degeneration: a consensus on clinical diagnostic criteria. *Neurology* 1998;51:1546-54.
21. Rascovsky K, Hodges JR, Knopman D, et al. Sensitivity of revised diagnostic criteria for the behavioural variant of frontotemporal dementia. *Brain* 2001;134:2456-77.
22. Finger EC, Marsh AA, Mitchell DG, et al. Abnormal ventromedial prefrontal cortex function in children with psychopathic traits during reversal learning. *Arch Gen Psychiatry* 2008;65:586-94.
23. Lundqvist D, Flykt A, Ohman A. The Karolinska Directed Emotional Faces (KDEF) [CD-ROM]. Solna (Sweden): Department of Clinical Neuroscience, Psychology Section, Karolinska Institutet; 1998.
24. Lange K, Williams LM, Young AW, et al. Task instructions modulate neural responses to fearful facial expressions. *Biol Psychiatry* 2003;53:226-32.
25. Smith SM, Jenkinson M, Woolrich MW, et al. Advances in functional and structural MR image analysis and implementation as FSL. *Neuroimage* 2004;23(Suppl 1):S208-19.
26. Smith SM. Fast robust automated brain extraction. *Hum Brain Mapp* 2002;17:143-55.
27. Zhang Y, Brady M, Smith S. Segmentation of brain MR images through a hidden Markov random field model and the expectation-maximization algorithm. *IEEE Trans Med Imaging* 2001;20:45-57.
28. Cox RW. AFNI: software for analysis and visualization of functional magnetic resonance neuroimages. *Comput Biomed Res* 1996;29:162-73.
29. Finger EC, Marsh AA, Kamel N, et al. Caught in the act: the impact of audience on the neural response to morally and socially inappropriate behavior. *Neuroimage* 2006;33:414-21.
30. Amting JM, Greening SG, Mitchell DG. Multiple mechanisms of consciousness: the neural correlates of emotional awareness. *J Neurosci* 2010;30:10039-47.
31. Mitchell DG, Greening SG. Conscious perception of emotional stimuli: brain mechanisms. *Neuroscientist* 2012;18:386-98.
32. Rombouts SA, van Swieten JC, Pijnenburg YA, et al. Loss of frontal fMRI activation in early frontotemporal dementia compared to early AD. *Neurology* 2003;60:1904-8.
33. Carr L, Iacoboni M, Dubeau MC, et al. Neural mechanisms of empathy in humans: a relay from neural systems for imitation to limbic areas. *Proc Natl Acad Sci U S A* 2003;100:5497-502.
34. Wicker B, Keysers C, Plailly J, et al. Both of us disgusted in My insula: the common neural basis of seeing and feeling disgust. *Neuron* 2003;40:655-64.
35. Jabbi M, Swart M, Keysers C. Empathy for positive and negative emotions in the gustatory cortex. *Neuroimage* 2007;34:1744-53.
36. Massimo L, Powers C, Moore P, et al. Neuroanatomy of apathy and disinhibition in frontotemporal lobar degeneration. *Dement Geriatr Cogn Disord* 2009;27:96-104.
37. Mather M, Canli T, English T, et al. Amygdala responses to emotionally valenced stimuli in older and younger adults. *Psychol Sci* 2004;15:259-63.
38. Carstensen L, Mikels J. At the intersection of emotion and cognition: aging and the positivity effect. *Curr Dir Psychol Sci* 2005;14:117-21.
39. Surguladze SA, Brammer MJ, Young AW, et al. A preferential increase in the extrastriate response to signals of danger. *Neuroimage* 2003;19:1317-28.
40. Amaral D, Price J, Pitkanen A, et al. Anatomical organization of the primate amygdaloid complex. In: Aggleton JP, editor. *The amygdala: neurobiological aspects of emotion, memory, and mental dysfunction*. New York: Wiley-Liss; 1992. p. 1-66.
41. Vuilleumier P, Richardson MP, Armony JL, et al. Distant influences of amygdala lesion on visual cortical activation during emotional face processing. *Nat Neurosci* 2004;7:1271-8.
42. Mitchell DG, Luo Q, Mondillo K, et al. The interference of operant task performance by emotional distracters: an antagonistic relationship between the amygdala and frontoparietal cortices. *Neuroimage* 2008;40:859-68.
43. Vuilleumier P, Armony JL, Driver J, et al. Distinct spatial frequency sensitivities for processing faces and emotional expressions. *Nat Neurosci* 2003;6:624-31.
44. Cusack R, Mitchell DJ, Duncan J. Discrete object representation, attention switching, and task difficulty in the parietal lobe. *J Cogn Neurosci* 2010;22:32-47.
45. Singh-Curry V, Husain M. The functional role of the inferior parietal lobe in the dorsal and ventral stream dichotomy. *Neuropsychologia* 2009;47:1434-48.
46. Greicius MD, Krasnow B, Reiss AL, et al. Functional connectivity in the resting brain: a network analysis of the default mode hypothesis. *Proc Natl Acad Sci U S A* 2003;100:253-8.
47. Zhou J, Greicius M, Gennatas E, et al. Divergent network connectivity changes in behavioural variant frontotemporal dementia and Alzheimer's disease. *Brain* 2010;133:1352-67.
48. Li J, Liu J, Liang J, et al. A distributed neural system for top-down face processing. *Neurosci Lett* 2009;451:6-10.
49. Wright CI, Dickerson BC, Feczko E, et al. A functional magnetic resonance imaging study of amygdala responses to human faces in aging and mild Alzheimer's disease. *Biol Psychiatry* 2007;62:1388-95.
50. Whitwell JL, Przybelski SA, Weigand SD, et al. Distinct anatomical subtypes of the behavioural variant of frontotemporal dementia: a cluster analysis study. *Brain* 2009;132:2932-46.



Journal of Psychiatry & Neuroscience

**Online manuscript
submission and peer review**

AVAILABLE at
<http://mc.manuscriptcentral.com/jpn>