

# Genetics and presence of non-syndromic supernumerary teeth: A mystery case report and review of literature

NEHA KHAMBETE, RAHUL KUMAR<sup>1</sup>

## Abstract

Presence of supernumerary teeth is well-recognized clinical phenomenon. However, it is uncommon to find multiple supernumeraries in individuals with no other associated disease or syndrome. Presence of multiple supernumerary teeth is thought to have genetic component. We report a rare case where multiple supernumerary teeth were seen without presence of any other syndrome in 3 generations; father, son, and two grandsons. We also present a review of similar cases published in literature till date. The role of genetics in development of supernumerary teeth is highlighted.

**Keywords:** Genetics, heredity, non-syndromic, supernumerary teeth

## Introduction

Supernumerary teeth are defined as teeth that exceed the normal dental formula, regardless of their location and morphology. Such teeth are relatively common, as reflected by the many studies published in the literature.<sup>[1-3]</sup> According to literature, the prevalence of supernumerary teeth in permanent dentition is 1-14%. Males are affected approximately twice as frequently compared to females.<sup>[4]</sup> Around 90-98% of supernumerary teeth occur in maxilla, and 90% of these are restricted to pre-maxilla. The most common supernumerary teeth, listed in order of frequency, are the mesiodens, maxillary fourth molars, maxillary paramolars, mandibular premolars, maxillary lateral incisors, mandibular fourth molars, and maxillary premolars.<sup>[5]</sup> Supernumerary teeth are often associated with Gardner syndrome, Crouzon's disease, Fabry-Anderson syndrome, Ehler-Danlos syndrome, Hallermann-Steriff syndrome, facial fissures or cleidocranial dysplasia.<sup>[6,7]</sup>

*Department of Oral Medicine, Diagnosis and Radiology, CSMSS Dental College and Hospital, Aurangabad, <sup>1</sup>Conservative Dentistry and Endodontics, MGM Dental College and Hospital, Navi Mumbai, India*

**Correspondence:** Dr. Neha Khambete, Department of Oral Medicine, Diagnosis and Radiology, C/O Khambete Hospital, Ward No.1, Shrirampur, Maharashtra - 413 709, India.  
E-mail: khamboo1927@gmail.com

Although multiple supernumerary teeth are very common, the prevalence of 5 or more supernumerary teeth is reported to be less than 1%.<sup>[2]</sup> Exact etiology of formation of supernumerary teeth is not very well-understood. Many theories have been put forward to explain the anomaly based on developmental interference and heredity.<sup>[7]</sup>

The aim of this paper is to document a rare case of familial occurrence of multiple supernumerary teeth occurring as an isolated non-syndromic trait. We also present the importance of genetic factors as the possible cause of supernumerary teeth.

## Case Report

A 28-year-old male reported to our OPD with chief complaint of pain in mandibular left first molar. Patient also gave history of extraction of mandibular right first molar 5 years back. The medical history was non-contributory. The patient also gave familial history of presence of extra teeth in his grandfather, father, and younger brother. On clinical examination, deep proximal caries were seen with mandibular left first molar. The maxillary left canine was unerupted. Patient also showed presence of 3 supernumerary teeth; 2 in maxilla, between maxillary right canine and premolar and in place of maxillary left canine and 1 in mandible, in place of extracted right first molar [Figure 1a and b]. An intra-oral periapical radiograph with respect of mandibular left first molar revealed presence of premolar like tooth in the periapical region of mandibular left second premolar. Thus, the patient was subjected to panoramic radiograph, which revealed total of 8 supernumerary teeth along with impacted maxillary left canine [Figure 2]. Two supernumerary teeth resembling premolars were present in each of the 4 quadrants. Patient was educated about the presence of impacted supernumeraries and then referred to department of conservative dentistry for further treatment.

Access this article online	
Quick Response Code: 	Website: <a href="http://www.contempclindent.org">www.contempclindent.org</a>
	DOI: 10.4103/0976-237X.107455

On the next visit, his father and younger brother were also asked to report for clinical examination. Patient's grandfather was dead, hence we could not get any clinical records, except for the familial history of extra teeth. The father, 60-year-old male, on clinical examination, showed presence of 4 supernumerary teeth; 1 in maxilla and 3 in mandible. The OPG showed presence of total 5 supernumerary teeth. Four supernumerary teeth were present in mandible and 2 in maxilla [Figure 3].

The younger brother, who was 20-year-old, showed presence of mesiodens clinically. The intra-oral periapical radiograph showed presence of second inverted mesiodens, which was impacted [Figure 4]. However, the OPG did not show any other supernumerary teeth.

All 3 patients were investigated for presence of any other anomaly, but no significant findings were noted. Hence, a diagnosis of familial non-syndromal hyperdontia was made.

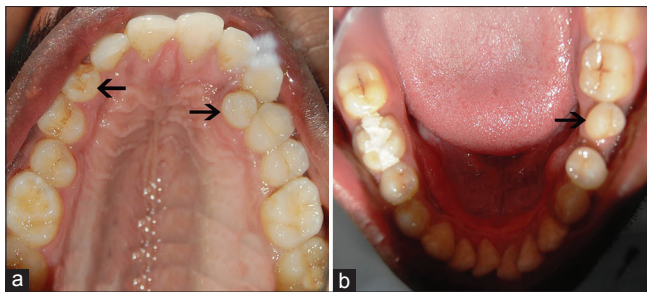
### Discussion

The etiology of supernumerary teeth still remains unclear. Two popular theories have been proposed. The dichotomy theory of tooth germs suggests that a tooth bud splits into 2 parts, resulting in 2 teeth of equal or unequal size. Another theory suggests that supernumerary teeth are formed as a result of local, independent, or conditioned hyperactivity of dental lamina.<sup>[8]</sup>

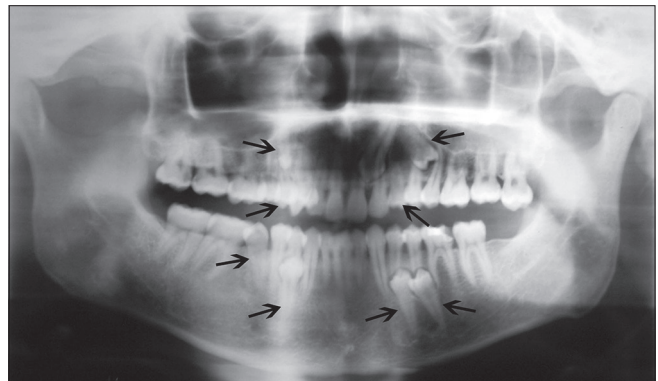
Heredity is also believed to be an important factor. A small number of supernumerary teeth may be a common developmental dental anomaly, while multiple supernumerary teeth usually have a genetic component and they are sometimes thought to represent a partial third dentition in humans.<sup>[9]</sup> Nislander and Sujaku, in 1963, proposed that this trait of supernumerary teeth may be associated with autosomal recessive gene with lesser penetrance in females. This was later supported by Gallas and Garcia in 1999.<sup>[10]</sup>

According to one theory, mutant genes give rise to supernumerary teeth and this is supported by the finding of increased supernumeraries in patients with facial and dental anomalies such as cleft lip and palate. The development of bilateral supernumeraries also suggests that they may be controlled by a mutant gene. The importance of heredity is emphasized by the increased number of supernumerary teeth found in relatives of those affected. While an autosomal-dominant inheritance with incomplete penetrance has been suggested, the increased incidence in males suggests possibility of sex-linked heredity as stated by Bruning *et al.*<sup>[6]</sup> As in our cases, this trait was seen in 3 generations of males, which indicates some role of sex-linked heredity [Figure 5].

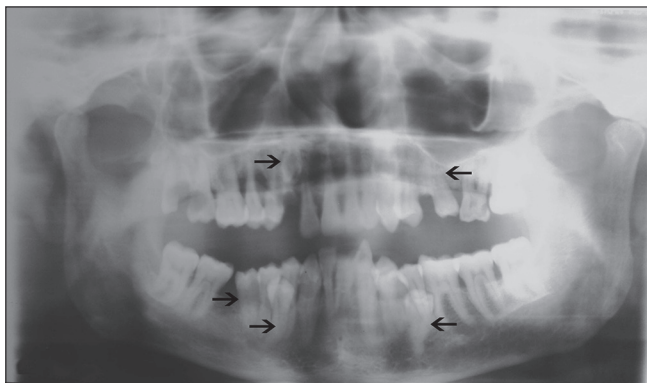
Despite advances in the knowledge of tooth morphogenesis and differentiation, relatively little is known about the etiology and molecular mechanisms underlying supernumerary tooth



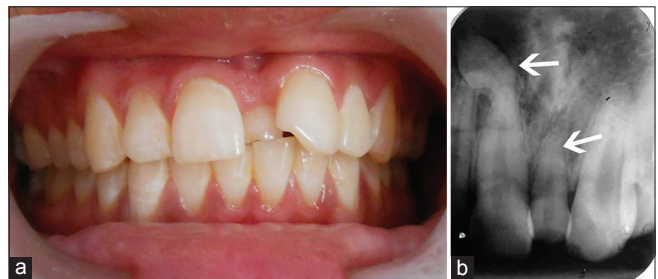**Figure 1:** Clinical photograph of (a) Maxillary; (b) Mandibular arches showing supernumerary teeth in patient



**Figure 2:** OPG of patient showing total 8 supernumerary teeth resembling premolars (arrows) and impacted maxillary left canine



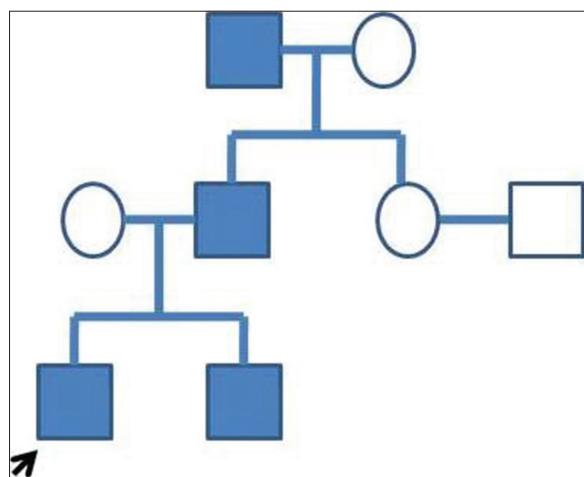
**Figure 3:** OPG of father showing 5 supernumerary teeth (arrows)



**Figure 4:** (a) Clinical photograph of brother showing mesiodens; (b) IOPA showing impacted inverted mesiodens

**Table 1: Review of literature of case reports showing familial non-syndromic hyperdontia**

Reference	Year	Family members with supernumerary teeth	Type of supernumerary teeth
Mercuri and O'Neill <sup>[12]</sup>	1980	Sisters, Father and Grandfather	Premolars
Becker <sup>[5]</sup>	1982	Cousins	Premolars
Almeida JD <sup>[13]</sup>	1995	3 siblings	Mesiodens
Seddon <i>et al.</i> <sup>[14]</sup>	1997	Twins	Mesiodens
Marya and Kumar <sup>[15]</sup>	1998	2 brothers	Mesiodens
Galas and Garcia <sup>[10]</sup>	1999	2 sisters	Mesiodens
Umveni <sup>[16]</sup>	2002	2 brothers and daughter of one of them	Mesiodens
A Sharma <sup>[17]</sup>	2003	Father and daughter	Mesiodens
Cassia A <sup>[18]</sup>	2004	5 members of same family	Lower incisors
Batra <i>et al.</i> <sup>[19]</sup>	2005	2 siblings and father	Mesiodens
		2 brothers and mother	Mesiodens
Ichingolo <i>et al.</i> <sup>[20]</sup>	2010	3 siblings	Distomolar
Verma <i>et al.</i> <sup>[21]</sup>	2010	2 siblings	Mesiodens
		Father and Son	Mesiodens



**Figure 5:** Pedigree chart showing sex-linked inheritance of non-syndromic hyperdontia

formation.<sup>[9]</sup> Genetic studies mapped cleidocranial dysplasia to chromosomal 6p21, and heterozygous mutations (haplo insufficiency) in RUNX2 (CBFA1) gene have been identified to be responsible for the development of CCD.<sup>[11]</sup> Gardner syndrome is caused by germline mutations in the APC gene. APC is located on chromosome 5q21-q22, and it can be alternatively spliced in multiple coding and non-coding regions. It has also been suggested that inactivation of APC or forced activation of Wnt/ $\beta$  (catenin signaling) results in multiple supernumerary tooth formation in both humans and in mice, but the key genes in these pathways are not very clear. Notably, adult oral tissues, especially young adult tissues, are still responsive to loss of APC or activation of Wnt/ $\beta$  (catenin signaling), and are able to form new teeth. Homozygous region on chromosome 16q12.2 is thought to be responsible for development of supernumerary incisors by El-Toum *et al.* Better understanding of the role of

Wnt/ $\beta$ -catenin, APC, 16q12.2, and RUNX2 in the formation of supernumerary teeth, together with detailed analysis of successional tooth formation in various model systems, will allow us to identify the exact genes responsible for supernumerary tooth formation.<sup>[9]</sup>

The occurrence of multiple supernumerary teeth without any associated syndrome has been reported frequently in literature; however, familial occurrence of non-syndromal multiple supernumerary teeth are very rare. A detailed review of the literature pertaining to case reports of familial non-syndromal supernumerary teeth is given in Table 1.

It is seen that most of these case reports have documented presence of non-syndromal supernumerary teeth in 2 generations of the family. However, we report a case where this condition was seen in 3 generations of the family. It is also seen that in most of the cases, the supernumeraries present were mesiodens. However, in our case, both supernumerary premolars and mesiodens were seen.

To conclude, there may be a definitive group of genes, which plays role in formation of supernumerary teeth. Research in recent years has taught us much about the molecular mechanisms underlying tooth morphogenesis and differentiation. However, relatively little is known about the initiation of tooth formation, the genetic control of successional teeth, as well as the mechanisms causing supernumerary tooth formation. Further research in stem cell biology and tissue engineering will help us to know the exact etiology of supernumerary tooth formation.

**References**

1. Scheiner MA, Sampson WJ. Supernumerary teeth: A review of the literature and four case reports. *Aust Dent J* 1997;42:160-5.

2. Açıkgöz A, Açıkgöz G, Tunga U, Otan F. Characteristics and prevalence of non-syndromic multiple supernumerary teeth: A retrospective study. *Dentomaxillofac Radiol* 2006;35:185-90.
3. Sivapathasundharam B, Einstein A. Non-syndromic multiple supernumerary teeth: Report of a case with 14 supplemental teeth. *Indian J Dent Res* 2007;18:144.
4. Brook AH. Dental anomalies of number, form and size: Their prevalence in British school children. *J Int Assoc Dent Child* 1974;5:37-53.
5. Orhan AI, Ozer L, Orhan K. Familial occurrence of nonsyndromal multiple supernumerary teeth. A rare condition. *Angle Orthod* 2006;76:891-7.
6. Scanlan PJ, Hodges SJ. Supernumerary premolar teeth in siblings. *Br J Orthod* 1997;24:297-300.
7. Yagüe-García J, Berini-Aytés L, Gay-Escoda C. Multiple supernumerary teeth not associated with complex syndromes: A retrospective study. *Med Oral Patol Oral Cir Bucal* 2009;14:E331-6.
8. Gündüz K, Muğlali M. Non-syndromic multiple supernumerary teeth: A case report. *J Contemp Dent Pract* 2007;8:81-7.
9. Wang XP, Fan J. Molecular genetics of supernumerary tooth formation. *Genesis* 2011;49:261-77.
10. Gallas MM, García A. Retention of permanent incisors by mesiodens: A family affair. *Br Dent J* 2000;188:63-4.
11. Ducey P, Zhang R, Geoffroy V, Ridall AL, Karsenty G. *Osf2/Cbfa1*: A transcriptional activator of osteoblast differentiation. *Cell* 1997;89:747-54.
12. Mercuri LG, O'Neill R. Multiple impacted and supernumerary teeth in sisters. *Oral Surg Oral Med Oral Pathol* 1980;50:293.
13. Almeida JD, Guimarães Cabral LA, Martins Gomes AP, Moraes E. Supernumerary mesiodentes with familial character: A clinical report. *Quintessence Int* 1995;26:343-5.
14. Seddon RP, Johnstone SC, Smith PB. Mesiodentes in twins: A case report and a review of the literature. *Int J Paediatr Dent* 1997;7:177-84.
15. Marya CM, Kumar BR. Familial occurrence of mesiodentes with unusual findings: Case reports. *Quintessence Int* 1998;29:49-51.
16. Umweni AA, Osunbor GE. Non-syndromic multiple supernumerary teeth in Nigerians. *Odontostomatol Trop* 2002;25:43-8.
17. Sharma A. A rare non-syndromic case of concomitant multiple supernumerary teeth and partial anodontia. *J Clin Pediatr Dent* 2001;25:167-9.
18. Cassia A, El-Toum S, Feki A, Megarbane A. Five mandibular incisors: An autosomal recessive trait? *Br Dent J* 2004;197:307-9.
19. Batra P, Duggal R, Parkash H. Non-syndromic multiple supernumerary teeth transmitted as an autosomal dominant trait. *J Oral Pathol Med* 2005;34:621-5.
20. Inchingolo F, Tatullo M, Abenavoli FM, Marrelli M, Inchingolo AD, Gentile M, *et al*. Non-syndromic multiple supernumerary teeth in a family unit with a normal karyotype: Case report. *Int J Med Sci* 2010;7:378-84.
21. Verma P, Sachdeva J, Verma K. Non-syndromic familial hyperdontia: Two case reports and review of literature. *JIAOMR* 2010;22:105-8.

**How to cite this article:** Khambete N, Kumar R. Genetics and presence of non-syndromic supernumerary teeth: A mystery case report and review of literature. *Contemp Clin Dent* 2012;3:499-502.

**Source of Support:** Nil. **Conflict of Interest:** None declared.