

The type of lymphocyte infiltration near urothelial carcinoma is diagnostic for chronic lymphocytic leukemia

Barbaros Baseskiogulu, Funda Canaz, Coskun Kaya, Turgut Dönmez

Department of Urology and Pathology, Faculty of Medicine, Osmangazi University, Eskisehir, Turkey

Abstract

T-lymphocytic infiltration near the tumor site is an expected immune response in bladder cancers. However, reports of patients with bladder cancer exhibiting small lymphocytic infiltration of the bladder tissue are very rare in the literature. Here, the patient was presented to our group with hematuria, but subsequently diagnosed as exhibiting invasive bladder cancer and chronic lymphocytic leukemia with suspicious lymphocytic infiltration in a transurethral resection specimen. This case emphasizes the importance of lymphocytic infiltration's nature near urothelial carcinoma.

Key Words: Bladder cancer, coincidence, infiltration, leukemia

Address for correspondence:

Dr. Barbaros Baseskioglu, Urology Department, ESOGU Medical Faculty, Meselik Eskişehir, Turkey. E-mail: barbaroza@gmail.com

Received: 24.02.2011, Accepted: 17.05.2011

INTRODUCTION

Patients with chronic lymphocytic leukemia (CLL) have an increased risk of developing a second type of cancer. However, coincidence of CLL and bladder cancer is very rare.^[1] Only three cases with CLL and bladder cancer were reported in the literature.^[2,3] Healthy bladder does not contain lymphoid tissue; however, T lymphocyte and monocyte infiltrations have been monitored in bladder cancers and these cells are called as tumor infiltrating lymphocytes (TILs). It is important to distinguish these lymphocytes from other pathologies. We report on a case that did not have any risks or properties of a lymphoproliferative disorder preoperatively, and was diagnosed as CLL with the suspicion in transurethral specimen of bladder cancer.

CASE REPORT

A 62 year-old man was referred to our urology unit with

a history of painless intermittent hematuria for 3 months. His occupation was long-distance driver; he had no chronic illness and a history of smoking for 45 years. In his physical examination, there were no significant findings such as hepatosplenomegaly, lymphadenopathy, fever or weight loss. Leukocytosis ($15700 \text{ } 10^3 / \text{ul}$) was determined in the blood cell count and thought to be related to the pyuria in the urinalysis. The left kidney was found at grade three hydronephrosis and a heterogeneous hypoechoic solid mass with irregular borders on the left side of the bladder wall were reported in the abdominal ultrasonography. All papillary masses in the left side of the bladder wall and in the prostatic urethra were resected transurethrally. The transurethral resection specimen was fixed in 10% buffered formaldehyde and routine hematoxylin and eosin preparation was performed for histological examination. Immunohistochemistry was performed on the formalin-fixed, paraffin-embedded tissue sections. Light microscopic examination revealed high grade urothelial carcinoma extending into the muscularis propria. The urothelium of the surrounding bladder mucosa showed carcinoma *in situ*. Diffuse small lymphocytic infiltration was found along the periphery of the tumor. Immunohistochemical studies revealed that the lymphocytes present in the region were positive for CD20, CD5 and CD43 and transitional cell carcinoma (TCC) [Figures 1 and 2]. After the pathological report the patient

Access this article online	
Quick Response Code:	Website: www.urologyannals.com
	DOI: 10.4103/0974-7796.106968

was investigated for hematological malignancies. Computer tomography scan of the abdomen, pelvic and chest regions demonstrated asymmetric wall thickening in the left side of the bladder and multiple lymphadenopathies in the pelvis and upper abdomen [Figure 3]. A peripheral blood smear and flow cytometry were performed and resulted in a diagnosis of CLL. The patient's final diagnosis was a coincidence of invasive bladder cancer and CLL. The patient received chemoradiotherapy for bladder cancer. CLL was followed conservatively. The patient died six months after diagnosis as a result of heart attack.

DISCUSSION

Bladder cancer and lymphoproliferative disorders may occur in a patient at the same time due to common etiologic factors such as benzene or dyes;^[4] due to the therapies for lymphoproliferative malignancies^[5] and bladder cancers.^[6] Furthermore, though rare, lymphoproliferative disorders can infiltrate to the urinary bladder. This is not a common occurrence because the healthy bladder does not contain lymphoid tissue.^[7] However, T lymphocyte and monocyte infiltrations have been observed in bladder cancers. Activated T cells, natural killer cells and non-T and non-B lymphocytes, collectively called tumor infiltrating lymphocytes (TILs), have cytotoxic activity and migrate to the site of the bladder tumor in order to inhibit the malignant cells.^[8] TCC with higher number of TILs is reported to have a favorable prognosis,^[9] with fewer occurrences of recurrence^[10] and metastases.^[11] But this anti-tumor response of the host immune system cannot manage the bladder tumor because mutations within tumor cells prevent tumor eradication by TILs over a prolonged period of time.^[8]

The risk of coincident malignancies in patients with CLL, which results from uncontrolled B lymphocytes in the hematopoietic organs, is higher because of the immune dysregulation^[12] and treatment with alkylating agents.^[13] Breast, skin, brain and prostate cancers have been reported as common coincident tumors of CLL,^[14] while in rare cases CLL may infiltrate other solid organs, such as skin, lung, heart and prostate.^[15] Urinary bladder involvement in CLL is also a very rare situation.^[16] Although the relation between these two tumors is unclear, one possible theory involves glutathione S-transferase M1 (GSTM1) which is important in the metabolism of environmental carcinogens, reactive oxygen species, and chemotherapeutic agents. The cigarette smoke carcinogens inactivate this GSTM1 genotype and these smokers behave as GSTM1 null genotype. Increased bladder cancer risk has been shown with GSTM1 null status and in all the cigarette smokers, even if they were positive for GSTM1, as an effect of tobacco exposure.^[17] Also GSTM1 null status and GSTM1 genotype inactivated by chemical agents was higher in patients with CLL.^[18]

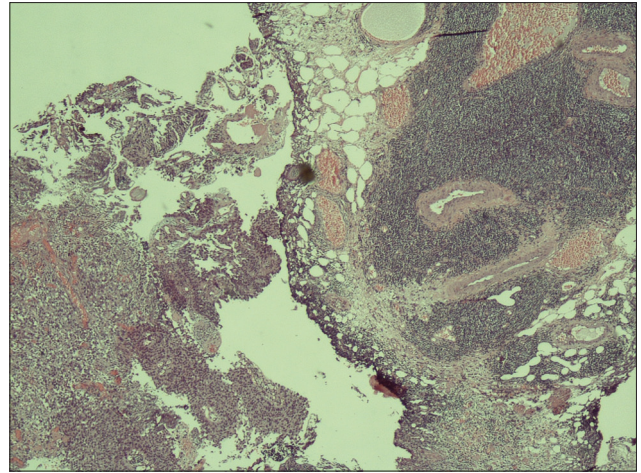


Figure 1: Transitional cell carcinoma with small lymphocytic infiltration (H and E, $\times 100$)

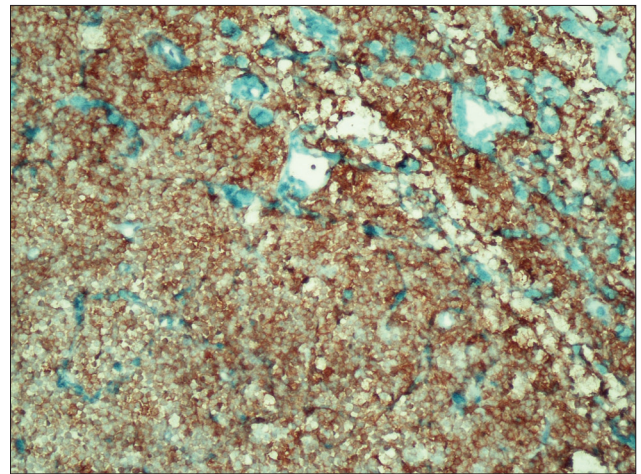


Figure 2: Small lymphoid cells were positive for CD20 ($\times 200$)

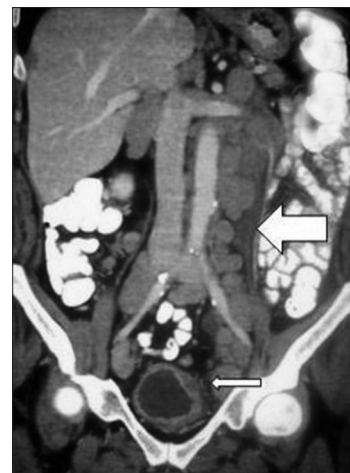

Figure 3: Computer tomography scan of the abdomen showing lymphadenopathies in abdomen of the patient

Although the patients with CLL may present with lymphoproliferative diseases and immunosuppression symptoms, pathological findings during the physical examination did

not indicate CLL in our case. He had a history of smoking, but not of exposure to chemical agents or medical therapies for other malignancies. The pathological examination of the specimen derived by transurethral resection from bladder carcinoma was identified as invasive urothelial carcinoma with lymphocytic infiltrations. These diffuse small lymphocyte infiltrates were expected to be TILs but were determined by immunohistochemistry to be CD20 positive. Further tests indicated that this patient had both invasive bladder cancer and CLL. As a result, this case indicated to us the importance of the nature of lymphocytic infiltration in bladder carcinoma.

REFERENCES

- Martín Hernández M, Alonso y Gregorio S, Cansino Alcaide R, Pérez-Utrilla M, Aguilera Bazán A, Regojo Zapata R, *et al.* Leukemic infiltration of the urinary bladder. A new case and literature review. *Actas Urol Esp* 2008;32:563-6.
- Lishner M, Prokocimer M, Ron E, Shaklai M. Primary malignant neoplasms associated with chronic lymphocytic leukaemia. *Postgrad Med J* 1987;63:253-6.
- Takács I, Berkessy S, Hártó G. Primary malignant neoplasms associated with chronic lymphocytic leukemia. *Postgrad Med J* 1992;68:595-6.
- Kelsh MA, Alexander DD, Kalmes RM, Buffler PA. Personal use of hair dyes and risk of bladder cancer: A metaanalysis of epidemiologic data. *Cancer Causes Control* 2008;19:549-58.
- Pathak AB, Advani SH, Gopal R, Nadkarni KS, Saikia TK. Urinary bladder cancer following cyclophosphamide therapy for Hodgkin's disease. *Leuk Lymphoma* 1992;8:503-4.
- Easton DJ, Poon MA. Acute nonlymphocytic leukemia following bladder instillations with thiotepa. *Can Med Assoc J* 1983;129:578-9.
- Bhansali SK, Cameron KM. Primary Malignant Lymphoma of the Bladder. *Br J Urol* 1960;32:440.
- Liakou CI, Narayanan S, Ng Tang D, Logothetis CJ, Sharma P. Focus on TILs: Prognostic significance of tumor infiltrating lymphocytes in human bladder cancer. *Cancer Immun* 2007;7:10.
- Mostofi FK, Sesterhenn I. Plenary lecture: Lymphocytic infiltration in relationship to urological tumors. *Natl Cancer Inst Monogr* 1978;49:133-41.
- Lipponen PK, Eskelinen MJ, Jauhiainen K, Harju E, Terho R. Tumour infiltrating lymphocytes as an independent prognostic factor in transitional cell bladder cancer. *Eur J Cancer* 1993;29:69-75.
- Tsujihashi H, Matsuda H, Uejima S, Akiyama T, Kurita T. Immuno-competence of tissue infiltrating lymphocytes in bladder tumors. *J Urol* 1988;140:890-4.
- Ramadan KM, Kyle A, McManus D, O'Rourke D, Cuthbert RJ. Urinary bladder infiltration with chronic B-lymphocytic leukemia: Two cases with unusual presentation. *Leuk Lymphoma* 2006;47:1184-7.
- Krause JR, Ayuyang HQ, Ellis LD. Secondary non-hematopoietic cancers arising following treatment of hematopoietic disorders. *Cancer* 1985;55:512-5.
- Takács I, Berkessy S, Hártó G. Primary malignant neoplasms associated with chronic lymphocytic leukemia. *Postgrad Med J* 1992;68:595-6.
- Hales DS, Cassidy M, Scott R, Lewi HJ. Immunocytoma of prostate. *Urology* 1983;22:438-9.
- Carver JD, Calverley D, Shen P. Chronic lymphocytic leukemia/small lymphocytic lymphoma presenting in urinary bladder without peripheral blood lymphocytosis: Case report and literature review. *Leuk Lymphoma* 2006;47:1163-5.
- Engel LS, Taioli E, Pfeiffer R, Garcia-Closas M, Marcus PM, Lan Q, *et al.* Pooled analysis and meta-analysis of glutathione S-transferase M1 and bladder cancer: A huge review. *Am J Epidemiol* 2002;156:95-109.
- Yuille M, Condie A, Hudson C. Relationship between glutathione S-transferase M1, T1 and P1 polymorphisms and chronic lymphocytic leukemia. *Blood* 2002;99:4216-8.

How to cite this article: Baseskiogulu B, Canaz F, Kaya C, Dönmez T. The type of lymphocyte infiltration near urothelial carcinoma is diagnostic for chronic lymphocytic leukemia. *Urol Ann* 2013;5:47-9.

Source of Support: Nil, **Conflict of Interest:** None.

Announcement

Android App



Download
**Android
application**

FREE

A free application to browse and search the journal's content is now available for Android based mobiles and devices. The application provides "Table of Contents" of the latest issues, which are stored on the device for future offline browsing. Internet connection is required to access the back issues and search facility. The application is compatible with all the versions of Android. The application can be downloaded from <https://market.android.com/details?id=comm.app.medknow>. For suggestions and comments do write back to us.