

# Appendicitis found in an incisional hernia

**Authors:** E L Galiñanes & A Ramaswamy

**Location:** University of Missouri, Columbia, USA

**Citation:** Galiñanes E, Ramaswamy A. Appendicitis found in an incisional hernia. JSCR. 2012 8:3

## ABSTRACT

Hernia appendicitis is a rare occurrence often described in association with groin hernias. We present a rare case of hernia appendicitis through a Pfannenstiel incision. Laparoscopy was performed with the intention to perform an appendectomy. An acutely inflamed appendix was visualized with the tip incarcerated into a 2 cm segment of the right most portion of a previous Pfannenstiel incision. Laparoscopic trans-hernial appendectomy with immediate laparoscopic suture herniorrhaphy was performed.

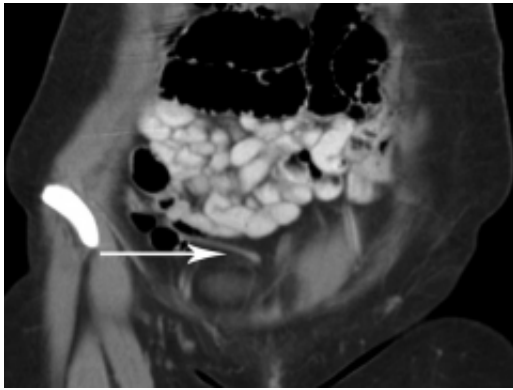
Early recognition of appendiceal hernias can be managed with appendectomy and suture herniorrhaphy omitting prosthetics. In cases with advanced pathology, approach should mimic that for emergent management of strangulated bowel and should be left to the surgeon's discretion.

## INTRODUCTION

Acute Appendicitis occurring within a hernia is rare with the overall incidence of appendicitis occurring within an inguinal, femoral, or incisional hernia estimated between 0.08-1% in the literature (1-4). The far majority of cases occur within hernia sacs in the groin secondary to anatomical proximity. We describe a rare case of hernia appendicitis through a Pfannenstiel incision.

## CASE REPORT

We report a case of a 27-year-old female with abdominal pain accompanied by nausea, vomiting, and anorexia for 24-hours. The patient denied every having experienced similar episodes and she denied any gynecological or urological symptoms. Past medical and surgical history was significant for a total abdominal hysterectomy with right-sided oophorectomy through a low transverse Pfannenstiel incision for stage III cervical cancer. On physical exam the patient had a soft abdomen with focal peritonitis in the right lower quadrant. The Pfannenstiel incision was well healed and intact with no evidence of hernias or masses on palpation. Computed tomography (CT) was performed showing an elongated 5mm appendix (Figure 1). Based on clinical examination we elected to perform a diagnostic laparoscopy suspecting acute appendicitis.



Upon entry, the appendiceal tip appeared to be incarcerated within a hernia at the right lateral aspect of the Pfannenstiel incision. The body of the appendix itself appeared to be non-inflamed. After port positioning, the appendiceal tip was dissected out of the hernia sac that appeared to extend significantly into the pre-peritoneal area and held by adhesions. A combination of blunt and sharp dissection revealed an inflamed appendiceal tip and ultimately allowed for reduction of the appendix from the hernia sac. Stapled appendectomy was performed. The bowel was examined from the ligament of Treitz to the cecum and appeared unremarkable. Exploration of the hernia sac revealed an iatrogenic injury to the bladder that had also herniated into the defect. This was primarily repaired using a 2-0 Vicryl suture in a running fashion intracorporeally. Suture herniorrhaphy with transfacial suture placement was performed to close the peritoneal defect.

Final pathology was consistent with acute appendicitis. The patient did well post operatively. She was discharged home with her Foley catheter being removed 2 weeks later.

## DISCUSSION

Appendiceal hernias have been well described in the literature, dating back to the early 1700's by DeGarengrot and Amyand. Most appendiceal hernias occur in the groin with a predilection for the right inguinal region. In a retrospective literature review of 45 cases from 1937 to 2006 by Meinke, acute appendicitis was identified within a right-sided hernia sac 95% of the time; 69% occurred in the inguinal region and 26% in the femoral region (4). The incidence of appendicitis occurring through incisional hernias is even more infrequent.

In 1991 Horgan et al described a case of a perforated appendicitis within a left-sided incarcerated hernia containing multiple loops of small bowel, appendix, caecum, and a portion of the right colon (5). Horgan postulated that arterial compromise from strangulation was the offending event. Recently, several reports have documented appendiceal hernias within kidney transplant incisions and large abdominal wall hernias (6-8). While the incidence of appendiceal hernia in an incisional hernia is rare, the overall incidence of incisional hernia has been reported to be around 11% for major abdominal surgery (9).

The Pfannenstiel incision, first described by Hermann Johannes Pfannenstiel in the late 19<sup>th</sup> century, was devised to limit the incidence of incisional hernia that was seen in midline laparotomies. Since then, it has become the incision of choice for gynecological operations. Through the years, the overall incidence of incisional hernia with a Pfannenstiel incision

remains low at 0%-0.5% ([10](#)).

The formation of a hernia at the right lateral aspect of the Pfannenstiel incision most likely preceded the appendicitis in our case. The exact mechanism by which the appendix became incarcerated into the Pfannenstiel incision is unknown but may be attributed to underlying hypermobility of the cecum or progressive inflammation leading to adhesion formation from previous surgery. Nonetheless, the appendicitis most likely occurred from external luminal compression of the appendiceal tip by chronic incarceration within the hernia sac.

Presentations of appendiceal hernias are not consistent with that of acute appendicitis. Meinke demonstrated that most appendiceal hernias presented with symptoms consistent with an incarcerated hernia, lacking the acute symptoms, such as nausea, anorexia, and periumbilical which aide in early diagnosis of appendicitis. This predisposes appendiceal hernias to a late diagnosis often in the operating room and associated perforation (41%) or gangrene (26%) ([4](#)). Most often the presenting symptom in appendiceal hernia is a tender mass that was absent in our case.

Due to the late diagnosis and complications associated with appendiceal hernias most surgeons advocate appendectomy with repair of the hernia without prosthetic mesh. A group out of Spain published their experience with Amyand's hernias in the presence of acute appendicitis. Appendectomy with hernia repair was performed in all six cases but interestingly 50% of repairs involved a plug and mesh. One case of surgical wound infection was found in one of the patients in whom the prosthetic material was used. The mesh was not removed and authors say that the infection was cleared. The limited data in their study restricts any such management to be recommended on their results.

More controversial is encountering a non-inflamed appendix in a groin hernia. Of 1,950 patients Gurer et al found a normal appendix vermiform present in eight out of the twelve cases involving a groin hernia ([3](#)). In these cases some surgeons would argue against appendectomy.

The authors advocate appendectomy whether or not a non-inflamed appendix is encountered. Early recognition of appendiceal hernias can be managed with appendectomy alone and suture herniorraphy omitting prosthetic material in a contaminated wound to prevent infection and chronic sepsis. An atypical presentation of appendicitis should raise a clinician's index of suspicion as a delay in diagnosis can be associated with advanced pathology that can contribute to a higher morbidity and mortality ([4](#)). In cases with advanced pathology, approach should mimic that for emergent management of strangulated bowel and should be left to the surgeon's discretion.

## REFERENCES

1. [Carey LC. Acute appendicitis occurring in hernias: a report of 10 cases. Surgery. 1967; 61:236-238](#)
2. [Sharma H, Gupta A, Shekhawat NS et al. Amyand's hernia: report of 18 consecutive](#)

- [patients over a 15-year period. \*Hernia\* . 2007;11:31-35](#)
3. [Gurer A, Ozdogan M, Ozlem N et al. Uncommon content hernia sac. \*Hernia\*. 2006; 10:152–158](#)
  4. [Meinke AK. Review Article: Appendicitis In Groin Hernias. \*J Gastrointest Surg\*. 2007; 11:1368-1372](#)
  5. [Horgan PG, O'Donoghue J, Courtney D \(1991\) Perforated appendicitis in an Incisional hernia. \*Ir J Med Sci\*. 1991; 160:350–351](#)
  6. [Dittmar Y, Scheuerlein H Götz M, Settmacher U. Adherent appendix vermiformis within an incisional hernia after kidney transplant mimicking acute appendicitis: report of a case. \*Hernia\*. 2010 \(Epub ahead of print\)](#)
  7. [Al-Hadithy, N, Erotocritou, P, Pourtou, MJ, Hamilton H. Appendicitis in an incisional hernia after radical nephrectomy: a case report. \*Ann R Coll Surg Engl\*. 2010 92:W23-4](#)
  8. [Arnáiz J, Ortiz A, Marco de Lucas E, Piedra T, Jordá J, Arnáiz AM, Pagola MA. Unusual perforated appendicitis within umbilical hernia: CT findings. \*Abdom Imaging\*. 2006; 3:691-3](#)
  9. [Mudge, M., Hughes, L.E. \(1985\) Incisional hernia: a 10 year prospective study of incidence and attitudes \*Br J Surg\* 72: 70-1](#)
  10. [Desouza A, Domajnko,B, Park J, Marecik S, Prasad L, Abcarian H. Incisional hernia, midline versus low transvers incision: what is the ideal incision for specimen extraction and hand assisted laparoscopy? \*Surg Endosc\*. 2011; 25:1031-6](#)