

REVIEW

Open Access

Oxygenation-sensitive cardiovascular magnetic resonance

Matthias G Friedrich^{1,2*} and Theodoros D Karamitsos³

Abstract

Oxygenation-sensitive cardiovascular magnetic resonance (CMR) is a non-contrast technique that allows the non-invasive assessment of myocardial oxygenation. It capitalizes on the fact that deoxygenated hemoglobin in blood can act as an intrinsic contrast agent, changing proton signals in a fashion that can be imaged to reflect the level of blood oxygenation. Increases in O₂ saturation increase the BOLD imaging signal (T₂ or T₂^{*}), whereas decreases diminish it. This review presents the basic concepts and limitations of the BOLD technique, and summarizes the preclinical and clinical studies in the assessment of myocardial oxygenation with a focus on recent advances. Finally, it provides future directions and a brief look at emerging techniques of this evolving CMR field.

Keywords: Cardiovascular magnetic resonance, Blood-oxygen level-dependent, Microcirculation, Ischemia, Oxygenation

Review

Contrast Generation in Oxygenation-Sensitive CMR

It was Linus Pauling who first described an effect of the oxygenation state of hemoglobin on its magnetic properties [1]. With respect to its behavior during magnetic resonance experiments, the de-oxygenation of hemoglobin causes the molecule to act as an intrinsic paramagnetic contrast agent resulting in pronounced spin-spin interaction. This accelerates the decay of transverse magnetization and thus shortens the spin-spin relaxation time. The term T₂^{*} describes the rate of loss of the transverse signal when using sequences without refocusing radiofrequency pulses. Regional iron deposition, hemoglobin degradation products in tissue hemorrhage or deoxygenated hemoglobin accelerate this process by their paramagnetic properties, a phenomenon called the BOLD (Blood-Oxygen-Level-Dependent) effect. This phenomenon can be exploited to perform “BOLD-sensitive” or, depending on the context, “oxygenation-sensitive” imaging with the aim to detect changes in tissue oxygenation.

In 1990, Ogawa et al. demonstrated that oxygenation-sensitive MR can be used to detect consequences of very small blood flow changes in the brain resulting from

external stimuli [2]. In humans, typically several averages and color-coded maps are used to visualize these changes [3], a technique which is widely known as functional brain MR. Accordingly, myocardial deoxygenation or ischemia is characterized by a net relative increase of de-oxygenated hemoglobin in the capillary blood and thus leads to T₂^{*} shortening, which can be visualized by T₂^{*} maps or by a regional signal loss in “T₂^{*}-weighted” MR images (i.e. images acquired by protocols sensitive to decreased regional field homogeneity). Conversely, a decrease of the proportion of de-oxygenated hemoglobin (for example by inducing vasodilation without a matching increase of myocardial oxygen demand) causes a relative decrease of de-oxygenated hemoglobin and leads to an increase of T₂^{*} in this territory and hence to an increased signal intensity in oxygenation-sensitive images.

It is important to keep in mind that the observed changes reflect changes in (mainly the venous compartment of the) capillary bed and therefore strictly do not represent the actual cell (i.e. cardiomyocytes). Yet the oxygenation of the capillary blood directly reflects the balance of oxygen supply and demand and therefore can be understood as a direct marker of tissue oxygenation.

Technical aspects of oxygenation-sensitive CMR

While image quality is frequently affected in echo-planar sequences [4] and other, T₂-weighted sequences [5] by motion or susceptibility artifacts (especially along the

* Correspondence: mgwfriedrich@gmail.com

¹Montreal Heart Institute, Departments of Cardiology and Radiology, Université de Montréal, Montreal, QC, Canada

²Departments of Cardiac Sciences and Radiology, University of Calgary, Calgary, Canada

Full list of author information is available at the end of the article

lung-heart interface), steady-state-free-precession sequences have shown promising results, allowing for a simultaneous acquisition of morphological, functional and oxygenation-sensitive data of the heart [6]. Of note, the oxygenation-sensitive contrast in images acquired by this sequence is directly dependent on the repetition time TR [7]. With an appropriate TR, the obtained image quality is much more consistent when compared to other BOLD-sensitive sequences, though at the expense of reduced sensitivity to the BOLD effect and thus lower “oxygenation contrast”. Further studies may have to fine-tune the balance between sensitivity to oxygenation changes and susceptibility artifacts.

Importantly, the magnitude of the BOLD effect (i.e. the measurable effect size) largely depends on the strength of the static magnetic field. While the overall susceptibility to field inhomogeneity at higher field strengths may cause artifacts, it also accounts for a higher sensitivity to changes induced by paramagnetic effects. Higher field strengths thus improve the sensitivity of MR to the BOLD effect. Data by Dharmakumar et al. indicate that the sensitivity to detect changes in myocardial oxygenation may increase by a factor of about 2.5 when moving from 1.5T to 3T [8].

With respect to a clinical application in patients with suspected myocardial ischemia, it is very important to be aware of the significant limitations of current diagnostic techniques to verify the hemodynamic relevance of coronary artery disease. Because of a lack of diagnostic targets on the (cellular) level of actual ischemia, imaging techniques use surrogate markers such as stress-inducible dysfunction (echocardiography), changes of blood inflow characteristics (echocardiography, first-pass perfusion CMR) or metabolic changes (nuclear cardiology techniques). All these are surrogates and thus cannot directly reflect an ischemic response of myocardial tissue, while oxygenation-sensitive CMR offers exactly that.

Experimental and pre-clinical studies

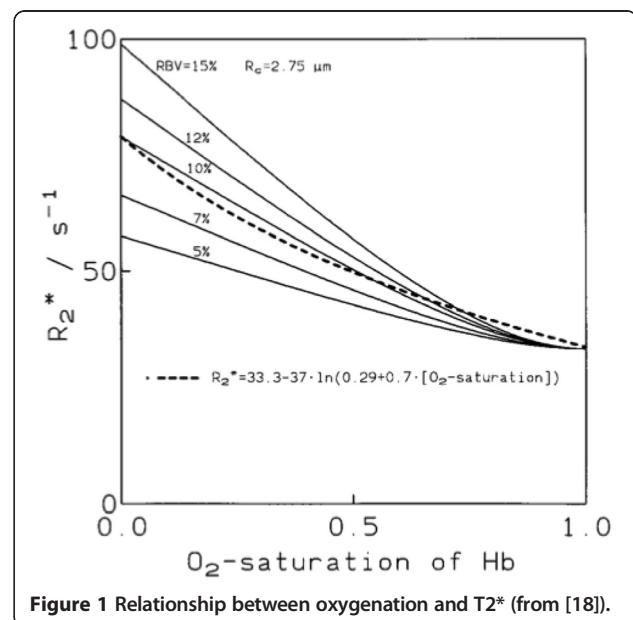
In 1993, Atalay et al. used a Langendorff heart model to show that the signal intensity in images sensitive to the BOLD effect (in that paper called “susceptibility-dependent”) is closely correlated to blood oxygenation [9]. Wendland et al. induced hypoxia in rats and demonstrated changes in the blood and the myocardium caused by the BOLD effect [10].

In July 1996, Niemi et al. observed in healthy volunteers, that the increase of myocardial blood flow as induced by the infusion of the vasodilator dipyridamole was closely correlated with a myocardial signal intensity increase in images obtained by a T2*-sensitive single-shot echo planar imaging (EPI) sequence [11]. Yet, another study, published in the same journal issue by Li et al. shed further light on the relationship of blood flow and oxygenation and thus the precise determinants of the observed signal intensity

changes. Using an oxygenation-sensitive gradient echo sequence, they could demonstrate that signal intensity changes primarily reflect changes of myocardial oxygenation and not changes of blood flow [12]: While a simultaneous, “balanced” increase of flow and demand (using dobutamine) did not significantly alter the signal, a non-balanced blood flow increase without accompanying increase of oxygen consumption (dipyridamole) lead to an increase of the myocardial signal intensity (hence oxygenation). This experiment helped to exclude relevant confounding effects of blood volume and flow on the ability of BOLD-sensitive CMR to assess changes of blood (capillary) oxygenation.

After extensive theoretical considerations on oxygenation-sensitive CMR [13] (Figure 1), Bauer et al. applied the approach of T2* mapping to visualize changes of myocardial oxygenation following dipyridamole in volunteers [14]. As an important step, signal intensity changes in the myocardium of dogs induced by vasodilation could be validated against microspheres [15]. With respect to its potential use to assess the relevance of coronary artery stenosis, an SSFP technique was used to detect a lack of signal intensity changes in the perfusion bed of experimentally (partially) occluded coronary arteries and demonstrated the ability of oxygenation-sensitive CMR to detect consequences of significantly reduced blood flow for myocardial oxygenation [16]. Tsaftaris et al found that, in severe coronary artery stenosis, the ratio of the systolic over the diastolic signal intensity in oxygenation-sensitive cine CMR images is already altered at rest, i.e. without any provocative testing [17].

While previous studies did not always distinguish between the impact of blood flow, perfusion, blood volume on the observed signal intensity in oxygenation-



sensitive images, Voehringer et al. could show in an animal model with intracoronary injection of vasoactive substances that the signal intensities observed in oxygenation-sensitive images of the myocardium indeed reflect myocardial blood oxygenation and not blood flow [19] (Figure 2), validating previous data by Li et al. [12] by blood oxygen measurements.

Oxygenation-sensitive CMR was also applied to assess endothelial function in the skeletal muscle [20], but similar studies have not been performed yet in the heart.

Expanding the scope of potential applications, Zheng et al. observed a close inverse correlation between changes of oxygenation and changes of oxygen extraction in a dog model with dipyridamole-induced hyperemia and proposed measuring the actual oxygen extraction fraction by oxygenation-sensitive CMR [21]. The change of the myocardial consumption rate has been measured in volunteers using a single breath-hold T2 mapping technique [22].

Very recent studies provide preliminary evidence that the clinical utility of oxygenation-sensitive CMR could be expanded to include vascular function. Günsch et al. used oxygenation-sensitive CMR to demonstrate the impact of breathing maneuvers on myocardial oxygenation [23]. This approach may offer a novel diagnostic approach to assess both, coronary vascular function and the hemodynamic relevance of coronary artery stenoses.

Clinical studies

Brain

BOLD imaging has been used for many years in the field of cognitive neuroscience. Both simple T2* estimates of

oxygenation and more advanced quantitative BOLD techniques have been used to detect oxygenation changes in different brain disorders (Figure 3). T2* measurements have been proposed to delineate the penumbra in acute stroke [24,25]. Furthermore, BOLD imaging has the potential to assess oxygenation status of brain tumors [26]. Many other brain disorders such as Alzheimer disease, Parkinson disease and Huntington disease have been associated with alterations in cerebral oxygen metabolism [27]. A detailed description of these studies is beyond the scope of this article.

Cardiac studies – detection of CAD

After the successful demonstration of the BOLD effect in preclinical animal studies, the next step was the evaluation of oxygenation-sensitive CMR in normal volunteers and patients with known or suspected coronary artery disease (CAD). After a small pilot study [28], Wacker and colleagues used a segmented gradient echo pulse sequence for T2* myocardial measurements at rest and during dipyridamole stress in 16 normal controls and 16 patients with single vessel CAD [29]. During dipyridamole infusion, T2* increased significantly from 35 ± 3 ms to 40 ± 4 ms in healthy volunteers (i.e., by $10 \pm 5\%$; $p = 0.01$). In contrast, myocardial segments supplied by a stenotic coronary artery showed a reduced T2* at rest and a modest response to vasodilation. Two patients with proximal stenosis of left anterior descending coronary artery were re-investigated after revascularization. Following intervention, the T2* homogeneity of the myocardium was improved. In another 1.5T study,

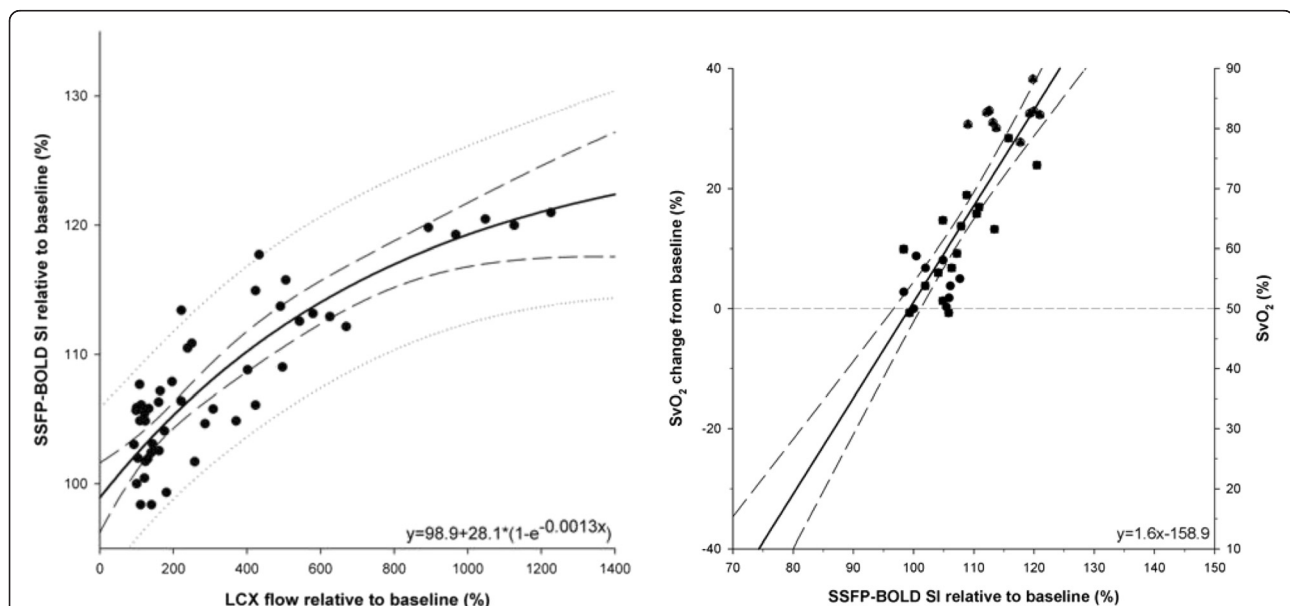


Figure 2 Correlation of changes of myocardial oxygenation during Adenosine infusion with blood flow and coronary sinus oxygenation. Note the exponential relationship between flow and signal intensity as opposed to the linear relationship with changes of coronary sinus blood oxygenation, showing that signal intensity changes reflect changes of oxygen and not blood flow (modified from [19]).

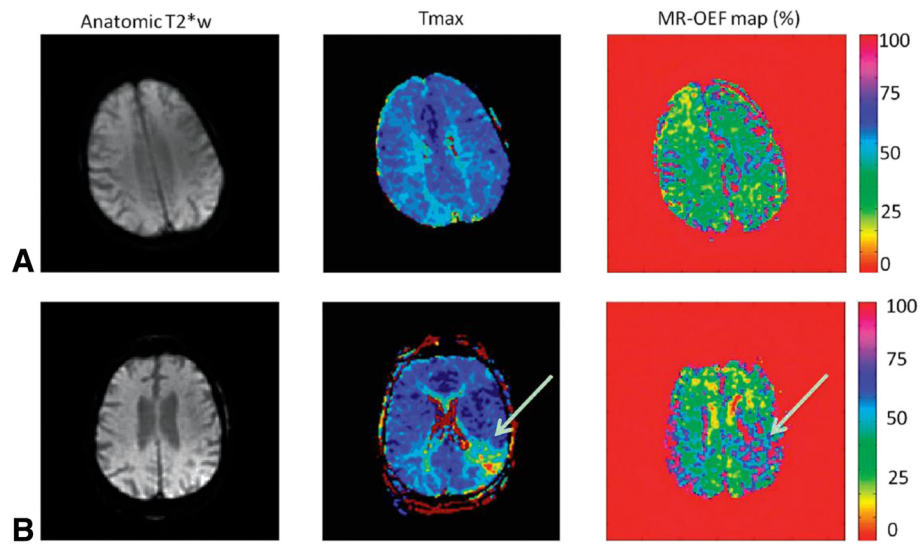
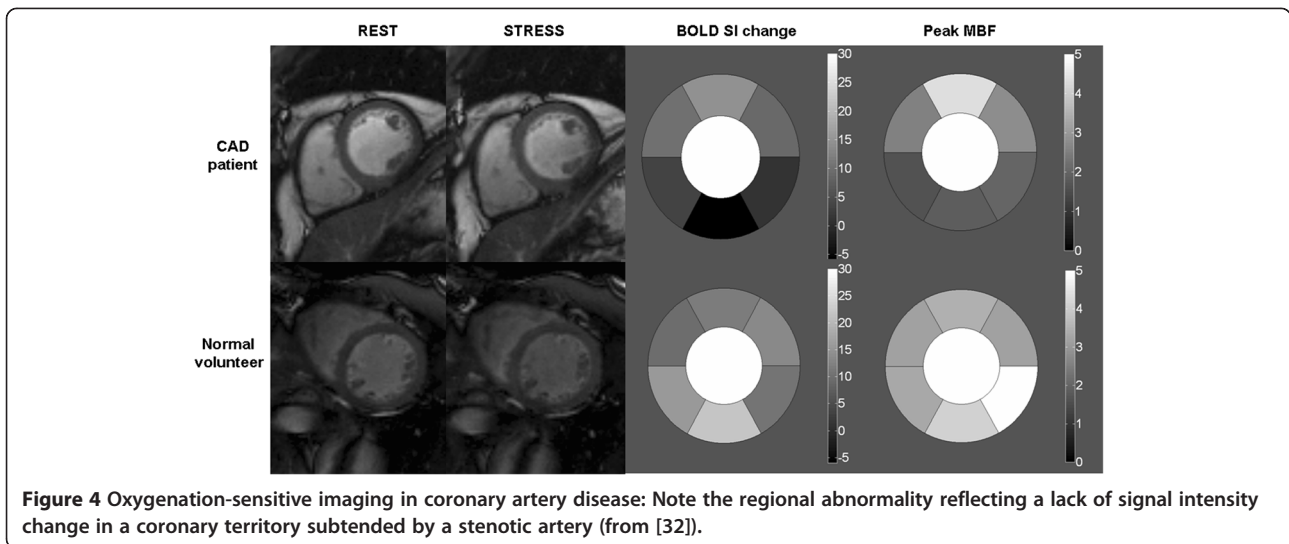


Figure 3 Parametric maps obtained with a quantitative BOLD approach by using a multiecho gradient-echo and spin-echo echo-planar imaging method in a healthy subject (A) and a patient with stroke (B). High oxygen-extraction fraction (OEF) can be observed in the affected region of the patient with stroke (white arrow). This method holds promise to evaluate the brain oxygenation status in a rapid fashion, which is critical in the acute stroke work-up (from [27]).

Friedrich and colleagues compared T2* oxygenation sensitive CMR with single-photon emission computed tomography (SPECT) [30]. This study included 25 patients with exercise-induced angina and assessed oxygenation SI changes at rest and during adenosine stress in a single mid-ventricular short axis. Myocardial segments subtended by vessels with >75% stenosis showed a significant decrease in signal intensity compared to segments with no stenosis. Receiver operator characteristics analysis of both oxygenation-sensitive CMR and thallium SPECT as related to quantitative coronary angiography revealed similar areas under the curve, 0.66 and 0.73, respectively. The investigators concluded that oxygenation-sensitive CMR is a promising technique to detect significant CAD. They also outlined the work that has to be done to improve the technique such as the need to increase spatial coverage and signal changes but also reduce artifacts. More recently, Manka and colleagues performed T2* BOLD CMR at 3T in 46 patients with known or suspected CAD [31]. Their BOLD measurements at rest revealed significantly lower T2* values for ischemic segments (27 ± 12 ms) compared to normal segments (32 ± 1 ms; $p < 0.0001$) and non-ischemic segments (31 ± 12 ms; $p = 0.0003$). During adenosine stress, T2* values demonstrated a significant increase in normal segments only (37 ± 15 ms; $p < 0.0001$ compared to rest). In contrast, T2* values of non-ischemic (33 ± 15 ms; $p = 0.19$) and ischemic segments (27 ± 12 ms; $p = 0.06$) were not significantly different from rest values. Using a cut-off value of 33.8ms, sensitivity and specificity for the detection of $\geq 50\%$ angiographic stenosis for rest and stress were 78% and 21%, and 78% and 68%, respectively. Image quality

was not consistent and was graded as moderate or poor in about 25% of patients. To overcome these problems with image quality and T2* BOLD methods, several human studies have used T2-prepared steady-state free-precession sequences for oxygenation-sensitive imaging at 1.5 and 3 Tesla [32-34]. Karamitsos and colleagues validated oxygenation-sensitive CMR against myocardial perfusion assessed by positron emission tomography (PET) [32]. They studied 22 patients with single or two-vessel CAD and 10 normal volunteers (Figure 4) and found that BOLD CMR and PET agreed on the presence or absence of ischemia in 18 of the 22 patients (82%) and in all normal subjects. However, per-segment analysis revealed that 40% of myocardial segments with stress myocardial blood flow below the prospectively defined cutoff of 2.45 mL/min/g did not show deoxygenation, whereas the majority of segments with normal perfusion also had normal oxygenation measurements. The investigators concluded that regional myocardial perfusion and oxygenation may be dissociated, indicating that in patients with CAD, reduced perfusion does not always lead to deoxygenation and ischemia. The same group compared oxygenation-sensitive CMR using a T2-prep sequence against 3T quantitative first-pass perfusion during vasodilator stress in 60 patients with suspected CAD referred for diagnostic angiography [35]. Prospective evaluation of BOLD imaging yielded an accuracy of 84%, a sensitivity of 92%, and a specificity of 72% for detecting myocardial ischemia on perfusion CMR and 86%, 92%, and 72%, respectively, for identifying significant coronary stenosis on quantitative coronary angiography. Segment-based analysis revealed evidence of



dissociation between oxygenation and perfusion ($r = -0.26$), with a weaker correlation of quantitative coronary angiography with myocardial oxygenation ($r = -0.20$) than with perfusion ($r = -0.40$; $p = 0.005$ for difference). This study confirmed that myocardial hypoperfusion is not necessarily commensurate with deoxygenation and showed that BOLD-CMR achieves favorable accuracy for identifying the anatomic and functional significance of CAD in a clinical setting. In a similar study, Jahnke and colleagues applied oxygenation-sensitive CMR at baseline and

during adenosine infusion and compared results with those acquired by a standard first-pass perfusion CMR protocol during the same session and with quantitative coronary angiography, using 50% stenosis as a cutoff to define relevant stenosis [36]. In contrast to previous studies which used breath-hold sequences, the investigators used a navigator-guided free-breathing T2-prepared segmented gradient echo sequence (Figure 5). They reported a sensitivity and specificity of 85.0% and 80.5%, respectively, compared to quantitative angiography, which is consistent

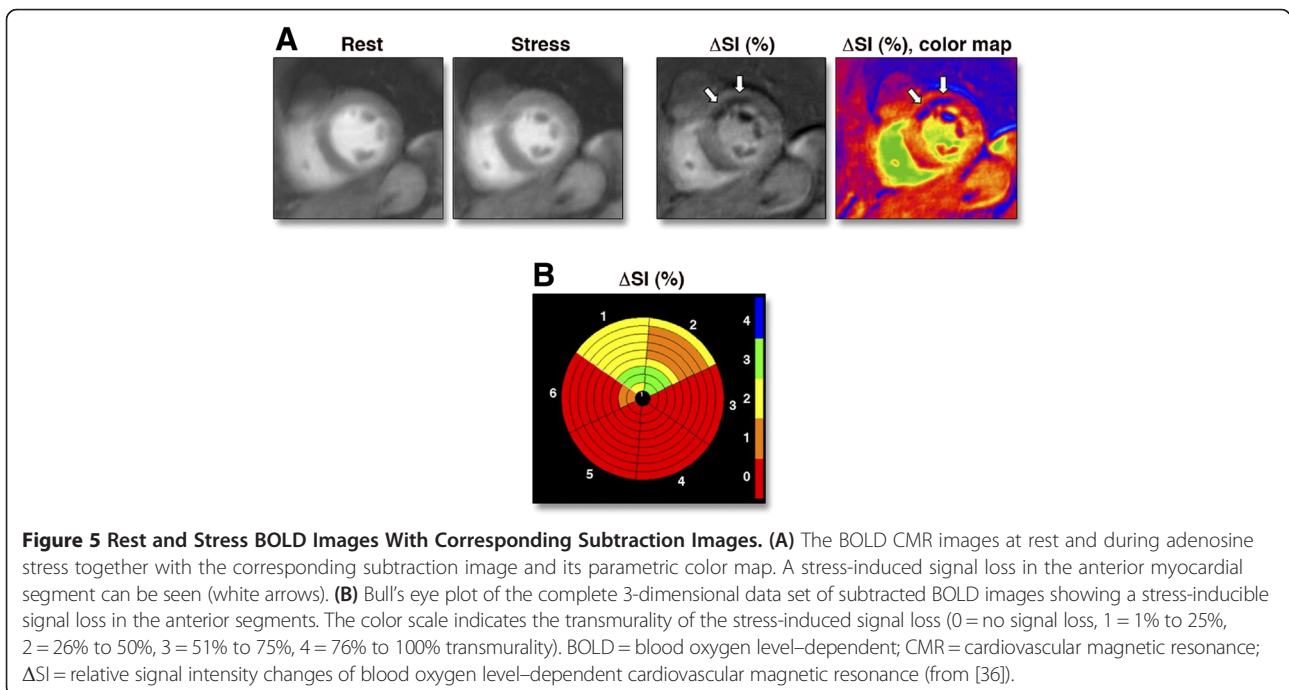


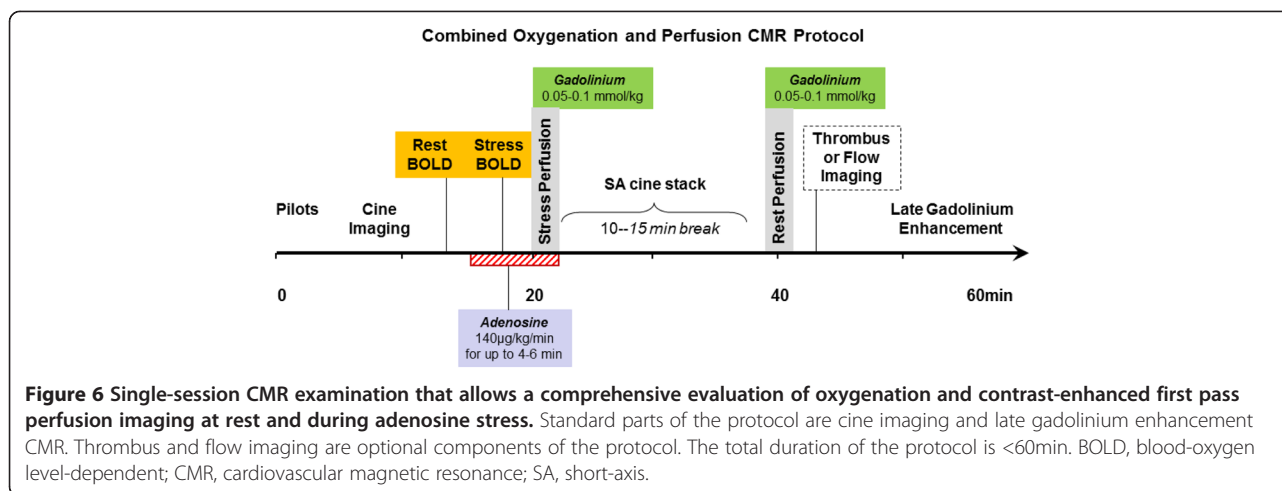
Table 1 Clinical studies using oxygenation-sensitive CMR to evaluate ischemic and non-ischemic heart diseases

| Study | Field strength | BOLD technique | Number of participants | Investigations | Main findings |
|-------------------------------|----------------|----------------|--|--|--|
| Studies in CAD cohorts | | | | | |
| Wacker et al. [29] | 1.5 T | T2* (ms) | N = 16 patients with single vessel CAD N = 16 healthy volunteers | <ul style="list-style-type: none"> • BOLD-CMR at rest and during dipyridamole stress • Coronary angiography | T2* was significantly lower in myocardial segments subtended by stenosed arteries compared to remote myocardium at rest. This difference in T2* increased during dipyridamole stress |
| Friedrich et al. [30] | 1.5 T | T2* (SI) | N = 25 patients with exertional angina | <ul style="list-style-type: none"> • BOLD-CMR at rest and during adenosine stress • Adenosine stress thallium SPECT • Coronary angiography | During adenosine, a mean signal intensity decrease was observed for myocardial segments related to coronary stenoses >75%. A non-significant increase was observed in the other segments. Using BOLD signal intensity increase cutoff value of 1.2%, BOLD-CMR had a sensitivity of 88% and a specificity of 47% to correctly classify severe stenoses. BOLD-CMR compared favorably with thallium SPECT |
| Bernhardt et al. [33] | 1.5 T | T2 (SI) | N = 46 patients with suspected CAD | <ul style="list-style-type: none"> • BOLD-CMR at rest and during adenosine stress • First-pass perfusion CMR at rest and during adenosine stress | BOLD SI change was significantly lower in segments with perfusion deficits compared to patients with visually normal perfusion |
| Manka et al. [31] | 3 T | T2* (ms) | N = 46 patients with known or suspected CAD | <ul style="list-style-type: none"> • BOLD-CMR at rest and during adenosine stress • Quantitative coronary angiography | BOLD CMR at rest revealed significantly lower T2* values for segments subtended by >50% stenosed vessels compared to segments subtended by non-stenosed vessels. Under adenosine T2* values increased only in normal segments |
| Karamitsos et al. [32] | 3 T | T2 (SI) | N = 22 patients with single or two-vessel CAD N = 10 healthy volunteers | <ul style="list-style-type: none"> • BOLD-CMR at rest and during adenosine stress • PET with oxygen-15 labeled water at rest and during adenosine stress • Quantitative coronary angiography | BOLD CMR and PET agreed on the presence or absence of ischemia in 18 of the 22 patients (82%) and in all normal subjects. On a per-segment analysis, 40% of myocardial segments with hypoperfusion on PET did not show deoxygenation, whereas the majority of segments with normal perfusion also had normal oxygenation. |
| Arnold et al. [35] | 3 T | T2 (SI) | N = 25 CAD patients and N = 20 healthy volunteers (derivation arm) N = 60 patients with suspected CAD (prospective arm) | <ul style="list-style-type: none"> • BOLD-CMR at rest and during adenosine stress • First-pass perfusion CMR at rest and during adenosine stress (absolute quantification of myocardial blood flow) • Quantitative coronary angiography | Prospective evaluation of BOLD imaging yielded an accuracy of 84%, a sensitivity of 92%, and a specificity of 72% for detecting myocardial ischemia and 86%, 92%, and 72%, respectively, for identifying significant coronary stenosis. Segment-based analysis revealed evidence of dissociation between oxygenation and perfusion ($r = -0.26$). |
| Jahnke et al. [36] | 3 T | T2 (SI) | N = 50 patients with suspected or known CAD | <ul style="list-style-type: none"> • BOLD-CMR at rest and during adenosine stress • First-pass perfusion CMR at rest and during adenosine stress (semi-quantitative assessment) • Quantitative coronary angiography | The ΔSI measurements differed significantly between normal myocardium, myocardium subtended by a stenosed coronary artery, and infarcted myocardium. A cutoff value of $\Delta SI = 2.7\%$ resulted in a sensitivity and specificity of 85.0% and 80.5%, respectively to detect coronary artery stenosis. BOLD- ΔSI correlated significantly with the degree of coronary stenosis ($r = -0.65$, $p < 0.001$). |

Table 1 Clinical studies using oxygenation-sensitive CMR to evaluate ischemic and non-ischemic heart diseases (Continued)

| | | | | | |
|-----------------------------------|-------|---------|--|--|--|
| Walcher et al. [37] | 1.5 T | T2 (SI) | N = 36 patients with suspected CAD | <ul style="list-style-type: none"> • BOLD-CMR at rest and during adenosine stress • Invasive Fractional Flow Reserve (FFR) | Relative BOLD SI increase was significantly lower in myocardial segments supplied by coronary arteries with an FFR \leq 0.8 compared with segments with an FFR > 0.8 |
| Studies in non-CAD cohorts | | | | | |
| Beache et al. [39] | 1.5 T | R2* (s) | N = 10 patients with hypertension N = 9 healthy volunteers | <ul style="list-style-type: none"> • BOLD-CMR at rest and during adenosine stress | Significantly reduced dipyridamole-induced change in the apparent transverse relaxation rate (R2*) in hypertensive patients compared to controls |
| Karamitsos et al. [34] | 3 T | T2 (SI) | N = 18 patients with Syndrome X N = 14 healthy volunteers | <ul style="list-style-type: none"> • BOLD-CMR at rest and during adenosine stress • First-pass perfusion CMR at rest and during adenosine stress (absolute quantification of myocardial blood flow) • Quantitative coronary angiography | No differences in myocardial perfusion and oxygenation between Syndrome X patients and controls |
| Karamitsos et al. [40] | 3 T | T2 (SI) | N = 27 patients with overt HCM N = 10 HCM mutation carriers without LVH N = 11 athletes N = 20 healthy volunteers | <ul style="list-style-type: none"> • BOLD-CMR at rest and during adenosine stress • First-pass perfusion CMR at rest and during adenosine stress (semi-quantitative measurement of myocardial perfusion reserve index-MPRI) | MPRI was significantly reduced in HCM compared to controls and athletes, but remained normal in HCM mutation carriers without LVH. Oxygenation response was attenuated in overt HCM compared to controls and athletes. Interestingly, HCM mutation carriers without LVH also showed an impaired oxygenation response to adenosine. |

BOLD, blood-oxygen level dependent; *CAD*, coronary artery disease; *CMR*, cardiovascular magnetic resonance; *FFR*, fractional flow reserve; *HCM*, hypertrophic cardiomyopathy; *LVH*, left ventricular hypertrophy; *MPRI*, myocardial perfusion reserve index; *PET*, positron emission tomography; *SI*, signal intensity; *SPECT*, single-photon emission computed tomography.



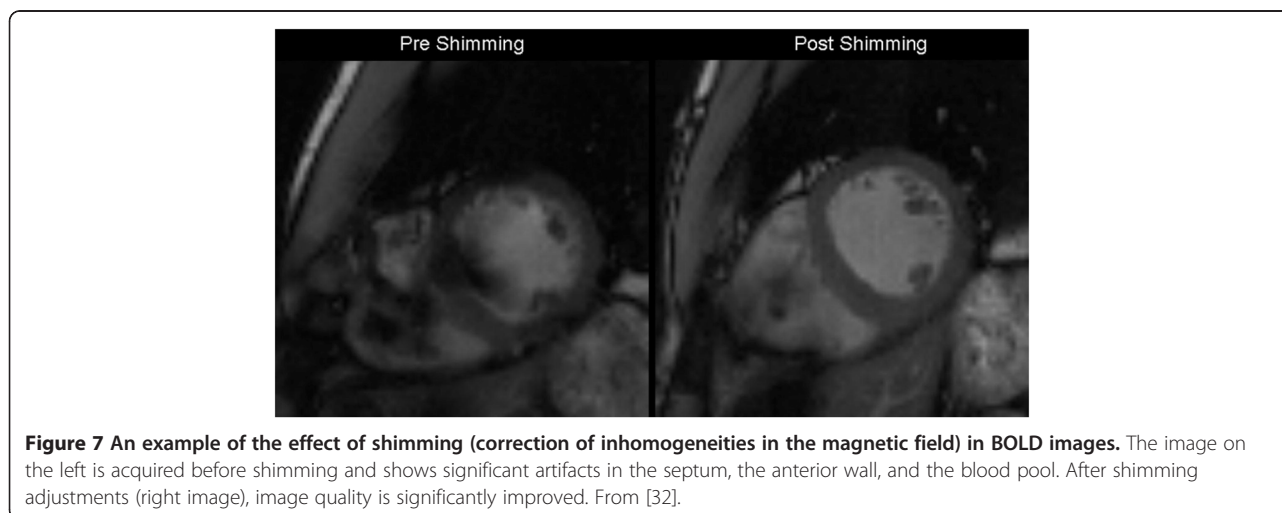
with previous BOLD studies at 3T. Recently oxygenation-sensitive CMR was validated against fractional flow reserve (FFR) in patients with CAD. Walcher et al. found that segments subtended by coronary vessels with an abnormal FFR had reduced BOLD SI change upon hyperemia compared to segments with FFR > 0.8 [37].

The clinical studies which used oxygenation-sensitive CMR to evaluate patients with ischemic and non-ischemic heart disease are summarized in Table 1.

Clinical potential

The relationship between regional myocardial blood flow and epicardial CAD is multifaceted. Oxygen supply and demand can individually vary in response to physiological stimuli, resulting in differing magnitudes of myocardial ischemia that may not be fully discernable via assessment of perfusion alone. Whilst conceptually impairment of both perfusion and oxygenation occur early in the ischemic cascade, they may not always occur simultaneously in the CAD cohort. It is therefore conceivable that, the addition

of oxygenation assessment (using oxygenation-sensitive CMR) to the non-invasive imaging armamentarium will improve our ability to detect functionally significant coronary stenoses. An additional advantage of oxygenation-sensitive CMR compared to perfusion CMR techniques is the detection of inducible ischemia without the use of exogenous contrast which is important for patients with severely impaired renal function to whom administration of gadolinium is problematic. Furthermore, oxygenation-sensitive CMR can provide interesting mechanistic insights and, thus, offer an improved pathophysiological understanding of diseases that affect the myocardial microvasculature. Recent human studies support these preclinical findings. In patients with 1 or 2-vessel CAD, oxygenation signal intensity changes during hyperemia in 'remote to ischemia' segments are intermediate compared to segments of stenosed and normal coronary arteries. This finding probably reflects the presence of diffuse microvascular dysfunction. The ability of oxygenation-sensitive CMR to detect microcirculatory changes has also



been shown in patients with hypertension [39] and in patients with hypertrophic cardiomyopathy including mutation carriers without left ventricular hypertrophy [40]. Another recent study showed that patients with Syndrome X (chest pain, abnormal stress test and normal coronary arteries on angiography) have no evidence of hypoperfusion or deoxygenation using first-pass perfusion CMR and BOLD imaging at 3T, respectively [34]. A particularly compelling aspect of oxygenation-sensitive CMR is the ability to detect deoxygenation in addition to existing CMR techniques which provide surrogates of ischemia (regional function, first-pass perfusion during vasodilator stress). BOLD imaging can be a straightforward addition on current CMR protocols in patients with known or suspected CAD undergoing vasodilator stress. A suggested CMR protocol that combines stress CMR perfusion and oxygenation assessment is shown in Figure 6.

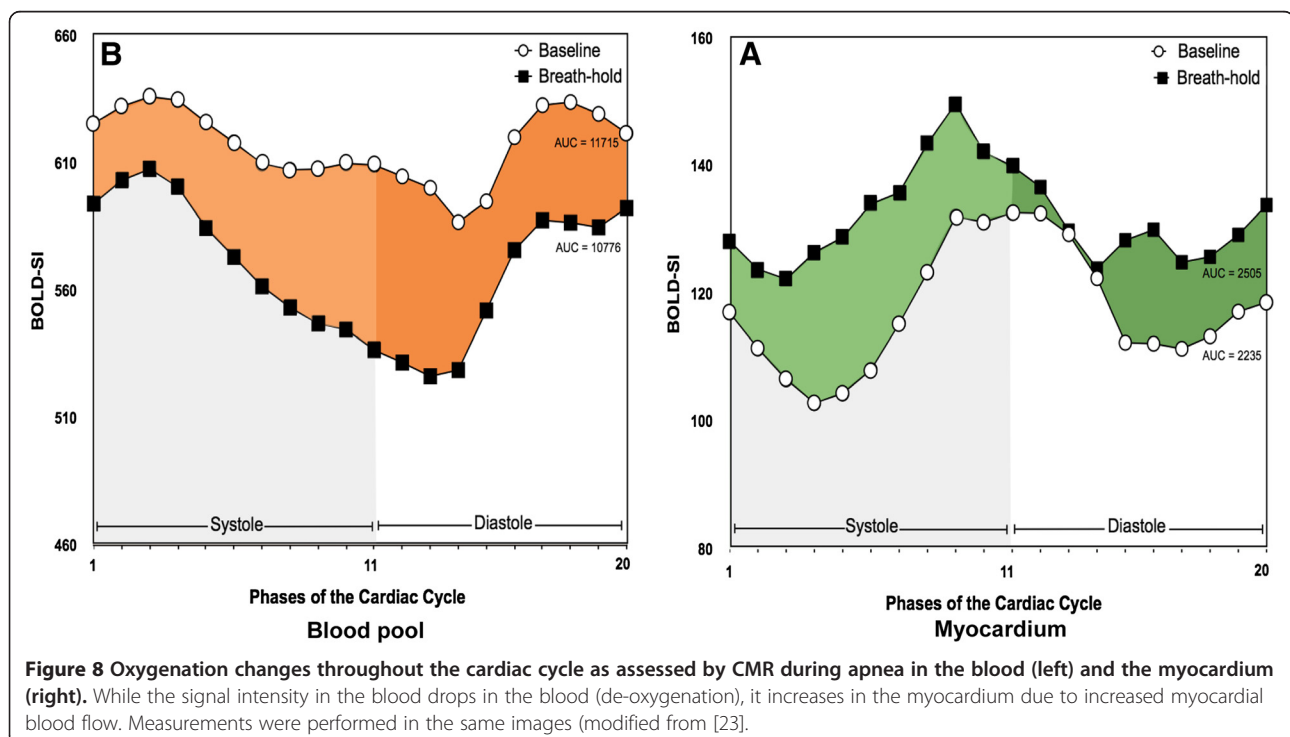
Current limitations and strategies to overcome them

While the recent advances in oxygenation-sensitive imaging in human and animal studies are promising, oxygenation-sensitive CMR is still in the steep part of a learning curve and a widespread clinical application will require fine-tuned simplified protocols and evaluation tools [41]. Although the feasibility of the technique at 1.5 T has been demonstrated, implementation of the cardiac BOLD approach at 1.5T is fundamentally limited by the relatively small difference in the signal between normal and de-oxygenated myocardial regions. At 3T, the blood and extravascular tissue T2 is much more sensitive to its

oxygenation level than at 1.5 T, consequently contrast will be increased [8,42]. This boost in contrast is accompanied by the increased signal to noise ratio at higher field strength, which makes 3 Tesla an attractive field strength for cardiac BOLD imaging. However, the increased signal comes at the expense of artifacts from inhomogeneities of the magnetic field and careful shimming is essential at 3 Tesla, particularly for SSFP sequences (Figure 7). Furthermore, artifacts may occur in the inferolateral wall due to the great cardiac vein or the heart-lung interface. Oxygenation-sensitive imaging has not been tested adequately in patients with coronary stents which are also likely to cause artifacts. There is also uncertainty as to which is the best approach for BOLD-CMR, i.e. measurement of T2* or signal intensity changes? Although T2* based methods appear to be more sensitive, they are also more susceptible to artifacts and implementation of T2* imaging at 3T may be particularly challenging.

Future directions

Current challenges of oxygenation-sensitive imaging are mainly due to its limited contrast-to-noise and thus, future developments will have to focus on improving the robustness of the CMR protocols and work on strategies to maximize detectable changes by improving stimuli and data acquisition. Such strategies include higher field strength [8], modifications of CMR sequences [43], improved methods for defining the area of interest [38] and novel ways for diagnostic changes of oxygenation [23]



(Figure 8). Furthermore, signal-intensity based methods will have to be compared with T2* mapping approaches.

In addition to refining techniques, pre-clinical and clinical research is required to reproduce published data.

Conclusion

Despite current shortcomings, oxygenation-sensitive CMR has passed the stage of an experimental attempt to become a tool which awaits serious assessment of its clinical utility in clinical scenarios. Tissue oxygenation as a true biomarker, as assessed by a very safe, non-invasive, contrast-free technique, in combination with other cardiac markers may become a major diagnostic target in patients with suspected coronary artery disease but also for primary or secondary microvascular disease.

Competing interests

Dr Karamitsos has no competing interests to report. Matthias G. Friedrich holds a pending patent on "Inducing and Measuring Myocardial Oxygenation Changes as a Marker for Heart Disease" (US Pat. Serial No. 61/680,981).

Authors' contributions

MGF and TDK drafted the manuscript and figures, read and approved the final manuscript.

Acknowledgements

MGF is supported by a Canadian Foundation for Innovation Leadership Fund Grant and by a career grant of the Fonds de la Recherche en Santé du Québec. TDK acknowledges support from British Heart Foundation and the National Institute for Health Research Oxford Biomedical Research Centre Programme.

Author details

¹Montreal Heart Institute, Departments of Cardiology and Radiology, Université de Montréal, Montreal, QC, Canada. ²Departments of Cardiac Sciences and Radiology, University of Calgary, Calgary, Canada. ³Oxford Centre for Clinical Magnetic Resonance Research, Division of Cardiovascular Medicine, Radcliffe Department of Medicine, University of Oxford, John Radcliffe Hospital, Oxford, UK.

Received: 29 April 2013 Accepted: 29 April 2013

Published: 24 May 2013

References

1. Pauling L, Coryell CD. The Magnetic Properties and Structure of Hemoglobin. Oxyhemoglobin and Carbonmonoxyhemoglobin. *Proc Natl Acad Sci USA*. 1936; **22**:210.
2. Ogawa S, Lee TM, Kay AR, Tank DW. Brain magnetic resonance imaging with contrast dependent on blood oxygenation. *Proc Natl Acad Sci USA*. 1990; **87**:9868–72.
3. Ogawa S, Tank DW, Menon R, Ellermann JM, Kim SG, Merkle H, Ugurbil K. Intrinsic signal changes accompanying sensory stimulation: functional brain mapping with magnetic resonance imaging. *Proc Natl Acad Sci USA*. 1992; **89**:5951–55.
4. Reeder SB, Faranesh AZ, Boxerman JL, McVeigh ER. In vivo measurement of T*2 and field inhomogeneity maps in the human heart at 1.5 T. *Magn Reson Med*. 1998; **39**:988–98.
5. Foltz WD, Al-Kwif O, Sussman MS, Stainsby JA, Wright GA. Optimized spiral imaging for measurement of myocardial T2 relaxation. *Magn Reson Med*. 2003; **49**:1089–97.
6. Dharmakumar R, Arumana JM, Larson AC, Chung Y, Wright GA, Li D. Cardiac phase-resolved blood oxygen-sensitive steady-state free precession MRI for evaluating the functional significance of coronary artery stenosis. *Invest Radiol*. 2007; **42**:180–88.
7. Arumana JM, Li D, Dharmakumar R. Deriving blood-oxygen-level-dependent contrast in MRI with T2*-weighted, T2-prepared and phase-cycled SSFP methods: theory and experiment. *Magn Reson Med*. 2008; **59**:561–70.
8. Dharmakumar R, Arumana JM, Tang R, Harris K, Zhang Z, Li D. Assessment of regional myocardial oxygenation changes in the presence of coronary artery stenosis with balanced SSFP imaging at 3.0 T: theory and experimental evaluation in canines. *J Magn Reson Imaging*. 2008; **27**:1037–45.
9. Atalay MK, Forder JR, Chacko VP, Kawamoto S, Zerhouni EA. Oxygenation in the rabbit myocardium: assessment with susceptibility-dependent MR imaging. *Radiology*. 1993; **189**:759–64.
10. Wendland MF, Saeed M, Lauerma K, de Crespigny A, Moseley ME, Higgins CB. Endogenous susceptibility contrast in myocardium during apnea measured using gradient recalled echo planar imaging. *Magn Reson Med*. 1993; **29**:273–76.
11. Niemi P, Poncelet BP, Kwong KK, Weisskoff RM, Rosen BR, Brady TJ, Kantor HL. Myocardial intensity changes associated with flow stimulation in blood oxygenation sensitive magnetic resonance imaging. *Magn Reson Med*. 1996; **36**:78–82.
12. Li D, Dhawale P, Rubin PJ, Haacke EM, Gropler RJ. Myocardial signal response to dipyridamole and dobutamine: demonstration of the BOLD effect using a double-echo gradient-echo sequence. *Magn Reson Med*. 1996; **36**:16–20.
13. Bauer WR, Nadler W, Bock M, Schad LR, Wacker CM, Ertl G. Theory of Coherent and Incoherent Nuclear Spin Dephasing in the Heart. *Phys Rev Lett*. 1999; **83**:4215–18.
14. Wacker CM, Bock M, Hartlep AW, Beck G, van Kaick G, Ertl G, Bauer WR, Schad LR. Changes in myocardial oxygenation and perfusion under pharmacological stress with dipyridamole: assessment using T*2 and T1 measurements. *Magn Reson Med*. 1999; **41**:686–95.
15. Fieno DS, Shea SM, Li Y, Harris KR, Finn JP, Li D. Myocardial perfusion imaging based on the blood oxygen level-dependent effect using T2-prepared steady-state free-precession magnetic resonance imaging. *Circulation*. 2004; **110**:1284–90.
16. Shea SM, Fieno DS, Schirf BE, Bi X, Huang J, Omary RA, Li D. T2-prepared steady-state free precession blood oxygen level-dependent MR imaging of myocardial perfusion in a dog stenosis model. *Radiology*. 2005; **236**:503–09.
17. Tsiftaris SA, Zhou X, Tang R, Li D, Dharmakumar R. Detecting myocardial ischemia at rest with cardiac phase-resolved blood oxygen level-dependent cardiovascular magnetic resonance. *Circ Cardiovasc Imaging*. 2013; **6**:311–19.
18. Bauer WR, Nadler W, Bock M, Schad LR, Wacker C, Hartlep A, Ertl G. Theory of the BOLD effect in the capillary region: an analytical approach for the determination of T2 in the capillary network of myocardium. *Magn Reson Med*. 1999; **41**:51–62.
19. Vohringer M, Flewitt JA, Green JD, Dharmakumar R, Wang J, Tyberg JV, Friedrich MG. Oxygenation-sensitive CMR for assessing vasodilator-induced changes of myocardial oxygenation. *J Cardiovasc Magn Reson*. 2010; **12**:20.
20. Utz W, Jordan J, Niendorf T, Stoffels M, Luft FC, Dietz R, Friedrich MG. Blood oxygen level-dependent MRI of tissue oxygenation: relation to endothelium-dependent and endothelium-independent blood flow changes. *Arterioscler Thromb Vasc Biol*. 2005; **25**:1408–13.
21. Zheng J, Wang J, Rowold FE, Gropler RJ, Woodard PK. Relationship of apparent myocardial T2 and oxygenation: towards quantification of myocardial oxygen extraction fraction. *J Magn Reson Imaging*. 2004; **20**:233–41.
22. McCommis KS, O'Connor R, Lesniak D, Lyons M, Woodard PK, Gropler RJ, Zheng J. Quantification of global myocardial oxygenation in humans: initial experience. *J Cardiovasc Magn Reson*. 2010; **12**:34.
23. Guensch DP, Fischer K, Flewitt JA, Friedrich MG. Impact of Intermittent Apnea on Myocardial Tissue Oxygenation – A Study Using Oxygenation-Sensitive Cardiovascular Magnetic Resonance. *PLoS One*. 2013; **8**:e53282.
24. Tamura H, Hatazawa J, Toyoshima H, Shimosegawa E, Okudera T. Detection of deoxygenation-related signal change in acute ischemic stroke patients by T2*-weighted magnetic resonance imaging. *Stroke*. 2002; **33**:967–71.
25. Morita N, Harada M, Uno M, Matsubara S, Matsuda T, Nagahiro S, Nishitani H. Ischemic findings of T2*-weighted 3-tesla MRI in acute stroke patients. *Cerebrovasc Dis*. 2008; **26**:367–75.
26. Brown JM, Wilson WR. Exploiting tumour hypoxia in cancer treatment. *Nat Rev Cancer*. 2004; **4**:437–47.

27. Christen T, Bolar DS, Zaharchuk G. *Imaging Brain Oxygenation with Methods, Validation, and Clinical Applications.* AJNR Am J Neuroradiol: MRI Using Blood Oxygenation Approaches; 2012.
28. Wacker CM, Bock M, Hartlep AW, Bauer WR, van Kaick G, Pflieger S, Ertl G, Schad LR. **BOLD-MRI in ten patients with coronary artery disease: evidence for imaging of capillary recruitment in myocardium supplied by the stenotic artery.** *MAGMA.* 1999; **8**:48–54.
29. Wacker CM, Hartlep AW, Pflieger S, Schad LR, Ertl G, Bauer WR. **Susceptibility-sensitive magnetic resonance imaging detects human myocardium supplied by a stenotic coronary artery without a contrast agent.** *J Am Coll Cardiol.* 2003; **41**:834–40.
30. Friedrich MG, Niendorf T, Schulz-Menger J, Gross CM, Dietz R. **Blood oxygen level-dependent magnetic resonance imaging in patients with stress-induced angina.** *Circulation.* 2003; **108**:2219–23.
31. Manka R, Paetsch I, Schnackenburg B, Gebker R, Fleck E, Jahnke C. **BOLD cardiovascular magnetic resonance at 3.0 tesla in myocardial ischemia.** *J Cardiovasc Magn Reson.* 2010; **12**:54.
32. Karamitsos TD, Leccisotti L, Arnold JR, Recio-Mayoral A, Bhamra-Ariza P, Howells RK, Searle N, Robson MD, Rimoldi OE, Camici PG, Neubauer S, Selvanayagam JB. **Relationship between regional myocardial oxygenation and perfusion in patients with coronary artery disease: insights from cardiovascular magnetic resonance and positron emission tomography.** *Circ Cardiovasc Imaging.* 2010; **3**:32–40.
33. Bernhardt P, Manzke R, Bornstedt A, Gradinger R, Spieß J, Walcher D, Rasche V, Hombach V. **Blood oxygen level-dependent magnetic resonance imaging using T2-prepared steady-state free-precession imaging in comparison to contrast-enhanced myocardial perfusion imaging.** *Int J Cardiol.* 2011; **147**:416–19.
34. Karamitsos TD, Arnold JR, Pegg TJ, Francis JM, Birks J, Jerosch-Herold M, Neubauer S, Selvanayagam JB. **Patients With Syndrome X Have Normal Transmural Myocardial Perfusion and Oxygenation: A 3-T Cardiovascular Magnetic Resonance Imaging Study.** *Circ Cardiovasc Imaging.* 2012; **5**:194–200.
35. Arnold JR, Karamitsos TD, Bhamra-Ariza P, Francis JM, Searle N, Robson MD, Howells RK, Choudhury RP, Rimoldi OE, Camici PG, Banning AP, Neubauer S, Jerosch-Herold M, Selvanayagam JB. **Myocardial oxygenation in coronary artery disease: insights from blood oxygen level-dependent magnetic resonance imaging at 3 tesla.** *J Am Coll Cardiol.* 2012; **59**:1954–64.
36. Jahnke C, Gebker R, Manka R, Schnackenburg B, Fleck E, Paetsch I. **Navigator-gated 3D blood oxygen level-dependent CMR at 3.0-T for detection of stress-induced myocardial ischemic reactions.** *JACC: Cardiovasc Img.* 2010; **3**:375–84.
37. Walcher T, Manzke R, Hombach V, Rottbauer W, Wöhrle J, Bernhardt P. **Myocardial Perfusion Reserve Assessed by T2-Prepared Steady-State Free-Precession Blood Oxygen Level-Dependent (BOLD) Magnetic Resonance Imaging in Comparison to Fractional Flow Reserve.** *Imaging: Circ Cardiovasc.* 2012, **5**:580–6.
38. Tsiftaris SA, Tang R, Zhou X, Li D, Dharmakumar R. **Ischemic extent as a biomarker for characterizing severity of coronary artery stenosis with blood oxygen-sensitive MRI.** *J Magn Reson Imaging.* 2012.
39. Beache GM, Herzka DA, Boxerman JL, Post WS, Gupta SN, Faranesh AZ, Solaiyappan M, Bottomley PA, Weiss JL, Shapiro EP, Hill MN. **Attenuated myocardial vasodilator response in patients with hypertensive hypertrophy revealed by oxygenation-dependent magnetic resonance imaging.** *Circulation.* 2001; **104**:1214–17.
40. Karamitsos TD, Dass S, Suttie J, Sever E, Birks J, Holloway CJ, Robson MD, Jerosch-Herold M, Watkins H, Neubauer S. **Blunted myocardial oxygenation response during vasodilator stress in patients with hypertrophic cardiomyopathy.** *J Am Coll Cardiol.* 2013; **61**:1169–76.
41. Friedrich MG. **Testing for myocardial ischemia: the end of surrogates?** *JACC: Cardiovasc Img.* 2010; **3**:385–87.
42. Bauer WR, Nadler W, Bock M, Schad LR, Wacker C, Hartlep A, Ertl G. **The relationship between the BOLD-induced T(2) and T(2)(*): a theoretical approach for the vasculature of myocardium.** *Magn Reson Med.* 1999; **42**:1004–10.
43. Zhou X, Tsiftaris SA, Liu Y, Tang R, Klein R, Zuehlsdorff S, Li D, Dharmakumar R. **Artifact-reduced two-dimensional cine steady state free precession for myocardial blood- oxygen-level-dependent imaging.** *J Magn Reson Imaging.* 2010; **31**:863–71.

doi:10.1186/1532-429X-15-43

Cite this article as: Friedrich and Karamitsos: Oxygenation-sensitive cardiovascular magnetic resonance. *Journal of Cardiovascular Magnetic Resonance* 2013 **15**:43.

Submit your next manuscript to BioMed Central and take full advantage of:

- **Convenient online submission**
- **Thorough peer review**
- **No space constraints or color figure charges**
- **Immediate publication on acceptance**
- **Inclusion in PubMed, CAS, Scopus and Google Scholar**
- **Research which is freely available for redistribution**

Submit your manuscript at
www.biomedcentral.com/submit

