

Nodular regenerative hyperplasia related portal hypertension in a patient with hypogammaglobulinaemia

Barun Kumar Lal, Adrian Stanley

Barun Kumar Lal, Adrian Stanley, Department of Gastroenterology, Glasgow Royal Infirmary, Glasgow G4 0SF, United Kingdom

Author contributions: Lal BK designed and wrote the case report; Stanley A chose the case and gave valuable ideas throughout the case report writing.

Correspondence to: Dr. Barun Kumar Lal, MBBS, MRCP, Clinical fellow in Gastroenterology, 2 Dorset Square, Glasgow G4 0SF, United Kingdom. docbarun@gmail.com

Telephone: +44-141-2210532 Fax: +44-141-2115131

Received: November 20, 2012 Revised: January 30, 2013

Accepted: February 5, 2013

Published online: June 14, 2013

Abstract

Nodular regenerative hyperplasia (NRH) of liver is a relatively rare liver disorder, but a frequent cause of noncirrhotic portal hypertension. We present a lady with common variable immune deficiency who presented with upper gastrointestinal bleeding and deranged liver function tests but preserved synthetic function. Upper gastrointestinal endoscope showed bleeding gastric varices and non-bleeding oesophageal varices. Although her oesophageal varices were eradicated by repeated endoscopic band ligation, the gastric varices failed to resolve after repeated endoscopic histocryl injection and she eventually needed transjugular intrahepatic portosystemic shunt placement. Liver biopsy showed NRH. We review the association of hypogammaglobulinaemia and NRH and discuss the appropriate management of portal hypertension in NRH.

© 2013 Baishideng. All rights reserved.

Key words: Nodular regenerative hyperplasia; Liver; Portal hypertension; Hypogammaglobulinaemia; Gastro-oesophageal varices

Core tip: Nodular regenerative hyperplasia (NRH) is still an evolving concept. Although a rarely identified liver

disorder, it is a frequent cause of noncirrhotic portal hypertension. Liver involvement in primary hypogammaglobulinemia mainly consists of NRH leading to chronic cholestasis and portal hypertension. Optimal management of gastric variceal bleed remains unclear. Histoacryl injection is the endoscopic method of choice for gastric variceal bleed but one should keep a lower threshold for transjugular intrahepatic portosystemic shunt procedure for recurrent gastric variceal bleed.

Lal BK, Stanley A. Nodular regenerative hyperplasia related portal hypertension in a patient with hypogammaglobulinaemia. *World J Gastroenterol* 2013; 19(22): 3502-3504 Available from: URL: <http://www.wjgnet.com/1007-9327/full/v19/i22/3502.htm> DOI: <http://dx.doi.org/10.3748/wjg.v19.i22.3502>

INTRODUCTION

Nodular regenerative hyperplasia (NRH) is the main cause of non-cirrhotic portal hypertension in the western world being responsible for 14%-27% of these cases^[1-3]. It is characterized by diffuse regenerative hepatocytic nodules without fibrosis. Common variable immune disorder (CVID) is a heterogeneous group of primary immunodeficiency conditions involving formation of antibody production and various cellular immune system defects. NRH is the main liver pathology found in patients with CVID with abnormal liver function test (LFT). It is associated with intrasinusoidal T-cell infiltration, portal vein endothelitis, autoimmune disease and peripheral lymphocytic abnormalities which suggest an autoimmune mechanism.

CASE REPORT

A 50-year-old lady presented with upper gastrointestinal bleeding. She had a history of bronchiectasis and idiopathic thrombocytopenic purpura and had previously

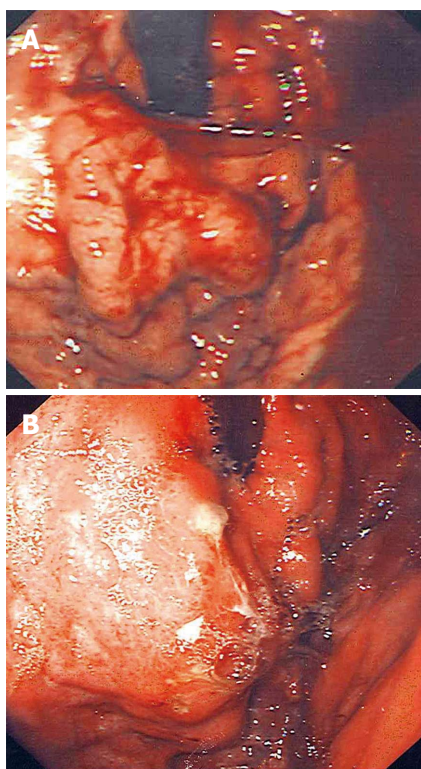


Figure 1 Gastric varices. A: Gastric varices pre glue injection; B: Gastric varices post glue.

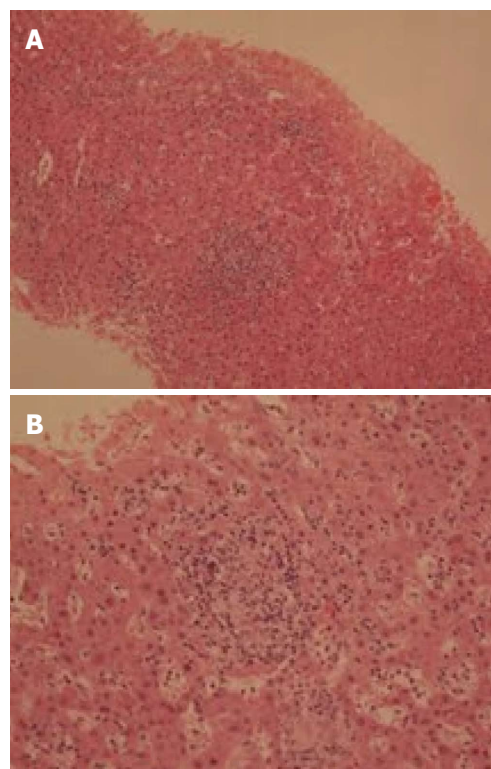


Figure 2 Nodule formation and granuloma on liver biopsy. A: Nodule; B: Granuloma.

been diagnosed with CVID. She was taking regular intravenous immunoglobulin infusion.

She was haemodynamically stable on presentation with pulse 90 per minute and blood pressure 131/65 mmHg. She had further episodes of haematemesis after admission and emergency endoscopy revealed large gastric fundal varices with evidence of active bleeding (Figure 1) and non-bleeding oesophageal varices. Haemostasis was achieved by applying glue (Histoacryl) to the gastric varices and her esophageal varices were banded. She was given five days of antibiotics and started on oral propranolol for prevention of variceal rebleeding.

She had mildly elevated liver enzymes (bilirubin 22 mmol/L, aspartate aminotransferase 55 U/L, alanine aminotransferase 35 U/L, gamma-glutamyl transpeptidase 45 U/L) with preserved synthetic function (albumin 41 g/L and prothrombin time 16 s). Ultrasonography of the abdomen revealed a coarse liver echo texture and normal flow in all hepatic veins. There was some bidirectional flow noted in the portal vein suggestive of portal hypertension but no ascites was seen.

To investigate her mildly elevated liver enzymes and portal hypertension percutaneous liver biopsy was undertaken. This showed features suggestive of NRH (Figures 2 and 3). Inflammatory cell infiltrate with granulomas were seen with a reactive appearance and immunophenotype suggestive that the NRH was related to CVID.

Subsequently, her oesophageal varices were eradicated by repeated band ligation but her gastric varices failed to resolve despite of repeated histoacryl injection (Figure 1).

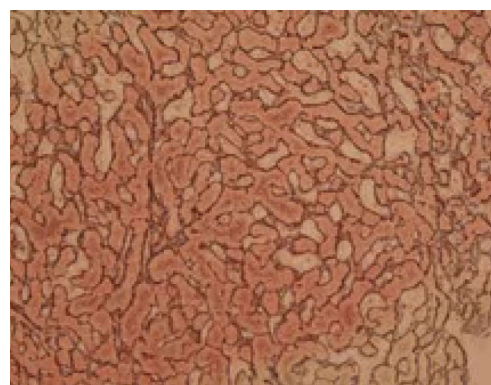


Figure 3 Thick liver cell plates on reticulin, but no fibrosis on liver biopsy.

Eventually, she had transjugular intrahepatic portosystemic shunt (TIPS) procedure with a covered graft which was placed after 6 mo of initial presentation resulting into satisfactory reduction in the portosystemic gradient with reversal of flow in the varices. She had complete resolution of her gastric varices post procedure and has remained on 6-mo TIPS checks by portography since.

She remains under regular follow up jointly in the liver, immunology, respiratory and haematology clinics. After nine years follow-up she remains well with normal LFTs.

DISCUSSION

NRH is usually associated with malignant, prothrom-

botic or rheumatologic conditions. Although liver disease and abnormal LFTs are found in approximately 10% of CVID patients^[4,5] liver lesions associated with primary hypogammaglobulinaemia has been poorly described^[6]. Two recent studies have identified NRH as the main histological correlate in patients with hypogammaglobulinemia^[2-6]. Subsequent portal hypertension was frequently observed in only one patient cohort^[6]. There has also been a case report which shows the association of hypogammaglobulinemia and major gastrointestinal bleeding from gastric varices as a result of cirrhosis of unknown cause (on biopsy)^[7].

Management of patients with NRH is aimed at the treatment of the underlying systemic disorder and any complications related to the portal hypertension. A fundamental concept is that the synthetic function of the liver is generally preserved in NRH, despite the potential for development of significant portal hypertension. Liver transplantation is therefore rarely needed for NRH^[8].

The immediate approach to variceal bleeding and ascites in patient with NRH does not differ from that of any other patients with the same condition. In the management of gastric varices or intractable or recurrent oesophageal variceal bleeding, TIPS should be considered^[9]. Gastric variceal bleeding can be particularly challenging to the clinician. Histoacryl injection is the endoscopic method of choice for gastric variceal bleeding with immediate haemostasis figures of over 90% reported^[9,10]. TIPS is used at a lower threshold for gastric compared with oesophageal variceal bleeding with uncontrolled studies demonstrating initial haemostasis obtained in over 90%, and rebleeding rates of 15%-30%^[11]. As hepatic encephalopathy is rare in NRH because of preserved hepatic synthetic function, Porto systemic shunt surgery or TIPS is more suitable to treat and prevent refractory gastric variceal bleed in patients with NRH^[11]. Balloon occluded retrograde transvenous obliteration is a technique for patients with gastric varices and gastrosplenic shunts, although it is rarely used outside Asia^[12]. Non-cardioselective beta-blockers are an alternative to TIPS for secondary prophylaxis, although the evidence is limited^[11].

In conclusion, NRH is still an evolving concept. Although a rarely identified liver disorder, it is a frequent cause of noncirrhotic portal hypertension. Liver involvement in primary hypogammaglobulinaemia mainly consists of NRH leading to chronic cholestasis and portal hypertension. Optimal management of gastric variceal bleed remains unclear. Histoacryl injection is the endoscopic method of choice for gastric variceal bleed but one should keep a lower threshold for TIPPS procedure for recurrent gastric variceal bleed.

REFERENCES

- 1 **Mahamid J**, Miselevich I, Attias D, Laor R, Zuckerman E, Shaoul R. Nodular regenerative hyperplasia associated with idiopathic thrombocytopenic purpura in a young girl: a case report and review of the literature. *J Pediatr Gastroenterol Nutr* 2005; **41**: 251-255 [PMID: 16056109]
- 2 **Nakanuma Y**. Nodular regenerative hyperplasia of the liver: retrospective survey in autopsy series. *J Clin Gastroenterol* 1990; **12**: 460-465 [PMID: 1975817 DOI: 10.1097/00004836-19008000-00023]
- 3 **Nakanuma Y**, Hosono M, Sasaki M, Terada T, Katayanagi K, Nonomura A, Kurumaya H, Harada A, Obata H. Histopathology of the liver in non-cirrhotic portal hypertension of unknown aetiology. *Histopathology* 1996; **28**: 195-204 [PMID: 8729037 DOI: 10.1046/j.1365-2559.1996.d01-412.x]
- 4 **Cunningham-Rundles C**, Bodian C. Common variable immunodeficiency: clinical and immunological features of 248 patients. *Clin Immunol* 1999; **92**: 34-48 [PMID: 10413651 DOI: 10.1006/clim.1999.4725]
- 5 **Ward C**, Lucas M, Pirus J, Collier J, Chapel H. Abnormal liver function in common variable immunodeficiency disorders due to nodular regenerative hyperplasia. *Clin Exp Immunol* 2008; **153**: 331-337 [PMID: 18647320 DOI: 10.1111/j.1365-2249.2008.03711.x]
- 6 **Malamut G**, Zioli M, Suarez F, Beaugrand M, Viallard JF, Lascaux AS, Verkarre V, Bechade D, Poynard T, Hermine O, Cellier C. Nodular regenerative hyperplasia: the main liver disease in patients with primary hypogammaglobulinemia and hepatic abnormalities. *J Hepatol* 2008; **48**: 74-82 [PMID: 17998147 DOI: 10.1016/j.jhep.2007.08.011]
- 7 **Rigaud S**, Lopez-Granados E, Sibéris S, Gloire G, Lambert N, Lenoir C, Synaeve C, Stacey M, Fugger L, Stephan JL, Fischer A, Picard C, Durandy A, Chapel H, Latour S. Human X-linked variable immunodeficiency caused by a hypomorphic mutation in XIAP in association with a rare polymorphism in CD40LG. *Blood* 2011; **118**: 252-261 [PMID: 21543760 DOI: 10.1182/blood-2011-01-328849]
- 8 **Elariny HA**, Mizrahi SS, Hayes DH, Boudreaux JP, Hussey JL, Farr GH. Nodular regenerative hyperplasia: a controversial indication for orthotopic liver transplantation. *Transpl Int* 1994; **7**: 309-313 [PMID: 7916934]
- 9 **de Franchis R**. Revising consensus in portal hypertension: report of the Baveno V consensus workshop on methodology of diagnosis and therapy in portal hypertension. *J Hepatol* 2010; **53**: 762-768 [PMID: 20638742 DOI: 10.1016/j.jhep.2010.06.004]
- 10 **Rajoriya N**, Forrest EH, Gray J, Stuart RC, Carter RC, McKay CJ, Gaya DR, Morris AJ, Stanley AJ. Long-term follow-up of endoscopic Histoacryl glue injection for the management of gastric variceal bleeding. *QJM* 2011; **104**: 41-47 [PMID: 20871126 DOI: 10.1093/qjmed/hcq161]
- 11 **Tripathi D**, Ferguson JW, Therapondos G, Plevis JN, Hayes PC. Review article: recent advances in the management of bleeding gastric varices. *Aliment Pharmacol Ther* 2006; **24**: 1-17 [PMID: 16803599 DOI: 10.1111/j.1365-2036.2006.02965.x]
- 12 **Fukuda T**, Hirota S, Sugimura K. Long-term results of balloon-occluded retrograde transvenous obliteration for the treatment of gastric varices and hepatic encephalopathy. *J Vasc Interv Radiol* 2001; **12**: 327-336 [PMID: 11287510]

P- Reviewer Bayrahtar Y S- Editor Gou SX
L- Editor A E- Editor Xiong L

