

**Background:** This paper reports a case of an 87-year-old female patient who was admitted for an emergency operation due to massive hemorrhage of an ulceration localized on a huge neck tumor. Post-interventional diagnosis indicated hidradenocarcinoma. Hidradenocarcinoma is a rare skin neoplasm. It can coincide with adenoma, may develop through its malignant transformation or develop as a malignant tumor from the beginning. It may be found in all dermal localizations. It may develop metastases or appear in the diffuse form.

**Material and methods:** Surgical excision of the tumor was performed obtaining a surgical margin, completed with excision of local lymph nodes and multiple layer suturing. Due to lack of the patient's consent, she has not been qualified for adjuvant therapy.

**Results:** Control examination 6 and 12 months later showed no signs of local recurrence or lymph node metastasis. **Conclusion:** Surgical excision of apocrine hidradenocarcinoma with a surgical margin could present a good therapeutic effect in spite of lack of adjuvant therapy.

**Key words:** hidradenocarcinoma, sweat gland tumor, neck tumor, apocrine tumor.

# Neck sweat gland cancer hemorrhage. Case study

Przemysław Ciesielski<sup>1</sup>, Barbara Górnicka<sup>2</sup>, Krzysztof Górnicki<sup>1</sup>,  
Małgorzata Kołodziejczak<sup>3</sup>, Paweł Siekierski<sup>1</sup>

<sup>1</sup>Department of General Surgery, County Hospital in Wołomin, Warsaw, Poland

<sup>2</sup>Chair and Department of Pathological Anatomy, Medical University in Warsaw, Warsaw, Poland

<sup>3</sup>Department of General Surgery, Proctology subdivision in Solec Hospital, Warsaw, Poland

## Introduction

Sweat gland tumor (hidradenocarcinoma cutis) is a rare skin neoplasm. Its incidence is estimated to ca. 0.001% [1, 2], predominating in women [3, 4]. Sweat gland tumor is mainly found within the head and neck, limbs and trunk skin, rarely in inguinal and scrotal areas [5]. Atypical localizations have been reported such as single cases of sweat gland tumor of the hand or anal region [6, 7]. Patients' age ranges from around 50 to 80 years old [4]. Sweat gland tumor was described for the first time by Stout and Cooley in 1951 [8] and the first classification of these tumors was created in 1968 by Berg and McDivitt.

The current histopathological classification of adnexal tumors (WHO Classification of Tumors, 2006) includes many types depending on the gland type and its elements dominating in the microscopic image [5]. Tumors developing from apocrine and eccrine glands are included in one group, though divided into malignant and benign tumors [5, 9]. Hidradenocarcinoma is a malignant equivalent of a benign tumor – hidradenoma – a sweat gland adenoma. Although it may coexist with an adenoma, it is rarely an effect of a malignant transformation and develops primarily rather as a malignant tumor. It can be found on the skin in any localization, slightly more often in women around the age of 50, although some pediatric cases have been reported. It grows rather slowly as an intradermal or hypodermic tumor, rarely communicating with the epidermis. The microscopic image shows a nodular growth pattern with presence of solid structures and cystically dilated ductal and tubular structures. In its tissue texture there can be seen clear cells with pale cytoplasm containing glycogen, eosinophil cells with a centrally placed nucleus similar to those of plano-epithelium, cylindrical cells cushioning tubular structures and less numerous mucus-producing cells. Differential diagnosis between adenoma and carcinoma can prove to be difficult. Morphological signs of malignancy include infiltrating growth pattern, presence of necrotic areas and atypical cells. In malignant tumors mitotic figures are generally more numerous, including atypical ones.

In clinical examinations tumors appear to be painless, giving in to pressure. They may contain cysts. It is estimated that in 20 to 40% of cases sweat gland tumor can infiltrate adjacent tissues or give rise to metastases [4, 5]. Surgical excision with a wide tumor-free margin and excision of local lymph nodes is a primary treatment. Adjuvant oncological treatment follows excision in metastatic or recurrent cases [10]. Diagnosis is based on histopathological examination, with essential histochemical, immunochemical and structural characteristics evaluation. A rare case study of a female patient with neck tumor diagnosed with sweat gland tumor post-operationally is presented below.

## Case study

The 87-year-old female patient was admitted to the Surgical Ward from the Emergency Department for the hemorrhage of an ulceration localized on a huge neck tumor.

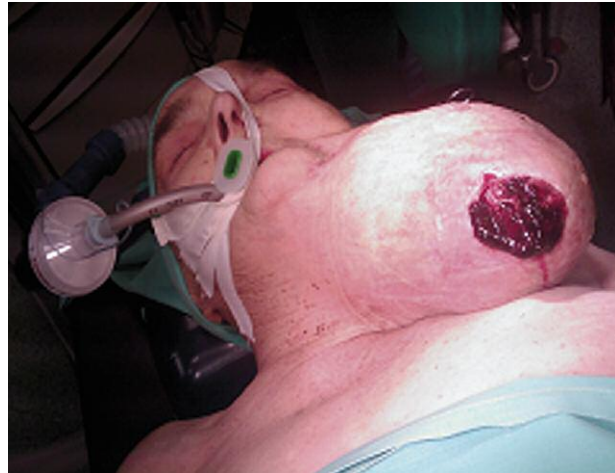Interview disclosed that the tumor had been developing for nearly 20 years. At its early stage it was of a small diameter and clearly began to expand within the last 5 years. The patient never complained for this reason to the GP. Within the last few months ulceration on the top of the tumor appeared. The first episode of bleeding occurred one month earlier and stopped spontaneously. Hypertension is the only coexisting disease.

Physical examination on admission showed poor general appearance, pale skin, BP 80/40 mmHg, HR 100/min with overall symptoms of hypovolemic shock.

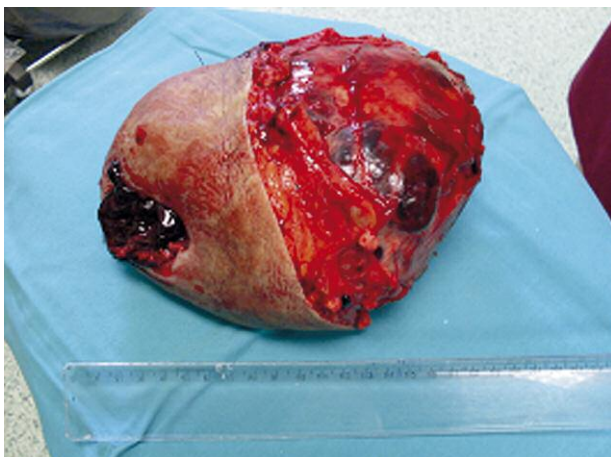
Local examination revealed a tumor measuring 180 × 135 × 122 mm localized in the left maxillary angle area. The upper pole of the tumor extended to the base of the left auricle, the lower one to the sternal insertion of the left sternocleidomastoid muscle. To the front, the tumor was covering the whole left mandibular body. The tumor appeared painless in palpation, soft, with numerous palpable cysts, presenting in its central part an ulceration with active bleeding. No local adenopathy was found.

Additional laboratory tests showed anemia (hemoglobin – 7.7 g/dl, RBC – 2.44 T/l) and leukocytosis (WBC – 17 G/l). Head and neck computed tomography showed the tumor described above (Fig. 1). Radiological interpretation of CT

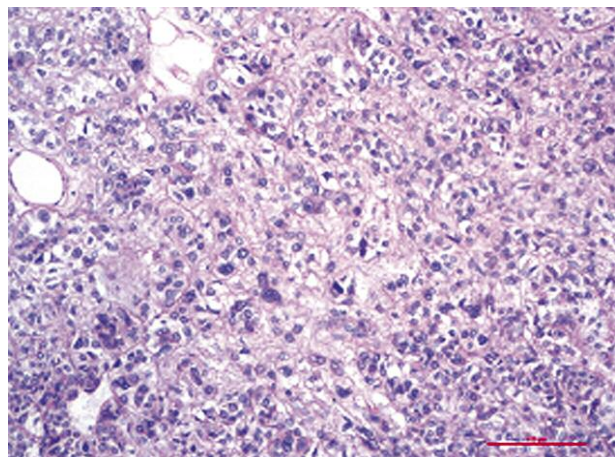
showed left parotid involvement, with oppression of neck blood vessels limiting the flow by approximately 50%, showing no signs of infiltration either of the larynx or of adjacent muscles. No adenopathy was seen in the examined region.



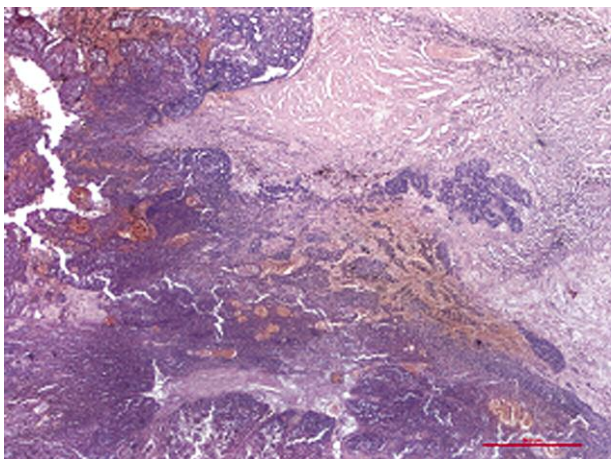
**Fig. 1.** Neck tumor. Patient prior to surgery (photograph published with patient's consent)



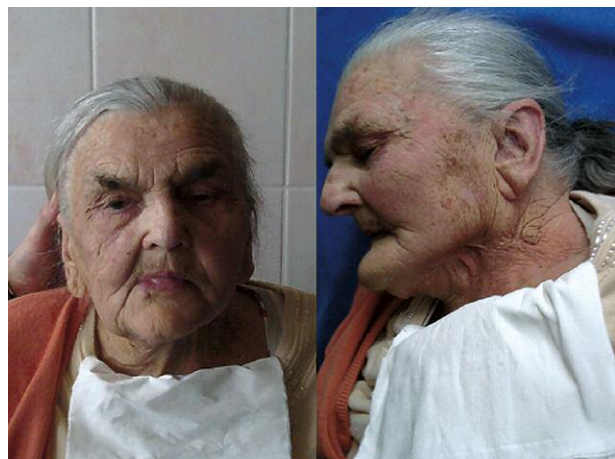**Fig. 2.** Excised neck tumor dissection



**Fig. 3.** Hidradenocarcinoma. Solid nests of clear cells and cylindrical cells showing signs of atypia. HE; magnification 20×



**Fig. 4.** Hidradenocarcinoma. Infiltrating growth pattern, necrotic areas and blood effusions can be seen; HE; magnification 4×



**Fig. 5.** The same patient 6 months after surgery (photograph published with patient's consent)

After applying a compression bandage and transfusion of 3 units of erythrocyte mass, the patient was qualified for an operation. Surgical excision of the tumor, covering skin, surrounding capsule and local lymph nodes was performed (Fig. 2). After hemostasis, the wound was closed with single interrupted sutures within all layers. The patient was discharged on the 7<sup>th</sup> day in good general condition. First intention wound healing without complications was noted. Sutures were removed on day 10.

Histopathological diagnosis: the sample sent for examination was 18 × 13 × 12 cm in diameter. The macroscopic image showed the tumor's blurred limits, soft consistency as well as blood effusions and necrotic areas. The microscopic image presented areas and nests of solid structures consisting of cylindrical and clear cells (Fig. 3).

Cells showing signs of atypia and mitotic figures were seen (about 6 on 10 large fields of view). The tumor was surrounded by a connective tissue capsule, infiltrated and exceeded by the tumor. Within the tumor blood effusions and necrosis could be seen, covering approximately 20% of its surface (Fig. 4).

Control examination conducted 6 and 12 months later showed no signs of local recurrence. The patient's general appearance was good, without complaints. Physical examination and neck ultrasound examination showed no local lymphadenopathy. The patient did not consent to undergo either a control head and neck CT or an oncologist consultation (Fig. 5).

## Discussion

The presented case is a rare case of neck cancer demonstrating the structure of hidradenocarcinoma cutis. Relatively few cases with this diagnosis have been described to date in the available literature. The atlas published by the International Agency for Research on Cancer (IARC) in 2006 describes 76 cases, among which 22 presented metastasis. For physicians sweat gland cancer represents primarily a diagnostic problem. Cancers developing from sweat glands are diagnosed mainly fortuitously, only after the excision of tumors. In most cases scheduled surgery is performed. Skin cancer surgery for acute indications is a rarity. The available literature describes no cases of patients with sweat gland cancer of similar diameter and location, or operated on for acute indications such as bleeding. Among others there was presented a case of a patient whose first symptom was an abscess within a tumor of the ano-rectal area [11]. Also in the presented case cancer was diagnosed only after surgical excision for vital indications because of hemorrhage.

Apocrine cancer (hidradenoma cutis) can take the form of a single tumor or numerous nodules. In the described case it had been growing for 20 years and showed local malignancy infiltrating adjacent tissues, including blood vessels, causing their destruction and hemorrhage threatening the patient's life. No lymph nodes or distant metastases were found. Absence of metastasis despite long disease duration correlates with other authors' observations [11, 12]. Intriguingly, it did not give rise to local lymph node metastasis, although apocrine gland cancers are relatively often metastatic to local lymph nodes [14].

Skin cancers developing from apocrine glands are treated by surgical excision with a surgical margin within healthy tissue. Adjuvant radio- and chemotherapy are also used [5, 13]. There exist single reports of tamoxifen usage [14]. The patient presented above has not been directed for further treatment due to her elderly age and lack of consent for further oncological consultation. Tumor excision with surgical margin proved to be not only a life-saving procedure (hemorrhage control) but also a radical oncologic treatment, although it is too early to draw any final conclusions due to the short patient observation period.

In conclusion, Surgical excision of apocrine gland cancer with surgical margin can have a good early therapeutic effect.

*The authors declare no conflict of interest.*

## References

1. Santa Cruz DJ. Sweet gland carcinomas a comprehensive review. *Sen Diagn Pathol* 1987; 4: 38-74.
2. Mehregan AH, Hashimoto K, Rahbari H. Eccrineadenocarcinoma: a clinicopathologic study of 35 cases. *Arch Dermatol* 1983; 119: 104-14.
3. LeBoit PE, Burg G, Weedon D, Sarasin A. Malignant tumours with apocrine and eccrine differentiation. *Pathology and genetics of skin tumours*. IARC Press 2006; 130-3.
4. Robson A, Greene J, Ansari N, Kim B, Seed PT, McKee PH, Calonje E. Eccrine porocarcinoma (malignant eccrine poroma): a clinicopathologic study of 69 cases. *Am J Surg Pathol* 2001; 25: 710-20.
5. Bronikowska-Kolasa A, Wdowiak L, Wojnowska D. Rzadko występujące złośliwe rozrosty nowotworowe skóry wywodzące się z gruczołów potowych. *Nowa Medycyna* 2005; 2: 33-4.
6. Amel T, Olfa G, Faten H, Makrem H, Slim BA, Moncef M. Metastatic hidradenocarcinomas: Surgery and chemotherapy. *N Am J Med Sci* 2009; 1: 372-4.
7. Leung TH, Lee HH, Chang SC. Perianal eccrine adenocarcinoma. *World J Surg Oncol* 2007; 5: 100.
8. Stout A, Cooley S. Carcinoma of sweat gland. *Cancer* 1951, 4: 521-36.
9. Woźniak L, Giryń I. Atlas histopatologii skóry. PZWL, Warszawa 1987; 128-32.
10. Erel E, Tarr G, Butterworth MS, Butler PE. Unusual metastatic spread of a malignant eccrine poroma. *Dermatol Online J* 2002; 8: 7.
11. Morris DM, Sanusi ID, Lanehart WH. Carcinoma of eccrine sweat gland: experience with chemotherapy, autopsy findings in a patient with metastatic eccrine carcinoma, and a review of the literature. *J Surg Oncol* 1986, 31: 26-30.
12. Cooper PH. Carcinomas of sweat glands. *Pathol Annu* 1987; 22 Pt 1: 83-124.
13. Whittington R, Browning ME, Farrell GR, Miremadi A. Radiation therapy and chemotherapy in malignant sweat gland tumors. *J Am Acad Dermatol* 1986; 15 (5 Pt 2): 1093-7.
14. Sridhar KS, Benedetto P, Otrakji CL, Charyulu KK. Response of eccrine adenocarcinoma to tamoxifen. *Cancer* 1989; 64: 366-70.

## Address for correspondence

Przemysław Ciesielski

Gdyńska 1/3

05-200 Wołomin

e-mail: przemyslaw.ciesielski@szpitalwolomin.pl

Submitted: 27.12.2011

Accepted: 19.03.2012