

LYMPH-NODE STAINING WITH ACTIVATED CARBON CH40: A NEW METHOD FOR AXILLARY LYMPH-NODE DISSECTION IN BREAST CANCER

Takashi Yokota, MD; Toshihiro Saito, MD; Yoichi Narushima, MD; Kazutsugu Iwamoto, MD; Masashi Iizuka, MD; Akeo Hagiwara, MD;*
Kiyoshi Sawai, MD;* Shu Kikuchi, MD; Yasuo Kunii, MD; Hidemi Yamauchi, MD

OBJECTIVE: To demonstrate the usefulness of activated carbon particles (CH40) as a vital staining dye for visualizing lymphatic vessels and lymph nodes in breast cancer.

DESIGN: A retrospective evaluation.

SETTING: Department of Surgery in Sendai National Hospital, Japan, a 716-bed teaching hospital.

METHODS: To identify as many lymph nodes as possible in the axillary fat, by which we might decrease the possibility of the presence of undetected metastatic nodes, an emulsion of activated carbon particles (CH40) was injected into the centre of the mammary gland, close to the tumour site, 3 days before radical surgery.

MAIN OUTCOME MEASURE: The number of lymph nodes found by the traditional method and by the CH40-injection method were recorded.

RESULTS: After injection, the CH40 was readily adsorbed into regional lymphatics and streamed along with the lymph flow to blacken regional lymph nodes. The CH40-guided method increased the mean number of nodes per case found in the axilla from 8.4, by the traditional method, to 14.0 nodes per case.

CONCLUSIONS: The use of the CH40 technique has two technical advantages; one is that it allows surgeons to locate the blackened lymph nodes at the time of surgery and the other is that it allows pathologists to look for the nodes in fatty tissue. Lymph-node dissection with the aid of activated carbon particles is inexpensive, easy to perform and enables the smallest lymph nodes to be easily recognized. CH40 is the technique of choice for the detection of axillary lymph nodes in cases where the number of lymph nodes detected by the traditional method is too small for accurate surgery. In conclusion, the present study demonstrates that CH40 could be an appropriate tool for more accurate staging of breast cancer axillary specimens.

OBJECTIF : Démontrer l'utilité des particules de carbone activé (CH40) comme colorant vital pour visualiser les vaisseaux lymphatiques et les ganglions lymphatiques dans les cas de cancer du sein.

CONCEPTION : Évaluation rétrospective.

CONTEXTE : Département de chirurgie de l'Hôpital Sendai National, Japon, hôpital d'enseignement de 716 lits.

MÉTHODES : Afin d'identifier, dans le gras axillaire, le plus grand nombre possible de ganglions lymphatiques, ce qui permettrait de réduire la possibilité qu'il y ait des métastases non détectées dans les ganglions, on a injecté une émulsion de particules de carbone activé (CH40) dans le centre de la glande mammaire, à proximité du site de la tumeur, trois jours avant une intervention chirurgicale radicale.

From the Department of Surgery, Sendai National Hospital, Sendai, 983-8520, Japan

**First Department of Surgery, Kyoto Prefectural University of Medicine, Kyoto, 602, Japan*

Accepted for publication July 4, 1999.

Correspondence to: Dr. Takashi Yokota, Department of Surgery, Sendai National Hospital, Miyagino-ku, Sendai 983-8520, Japan; fax 022-291-8114, yokoyoko@jun.ncvc.go.jp

© 2000 Canadian Medical Association

PRINCIPALE MESURE DE RÉSULTATS : On a consigné le nombre de ganglions lymphatiques découverts au moyen de la méthode classique et de la méthode à l'injection de CH40.

RÉSULTATS : Après l'injection, le CH40 a été rapidement absorbé dans le système lymphatique régional qu'il a suivi pour noircir les ganglions lymphatiques régionaux. La méthode guidée par le CH40 a augmenté le nombre moyen de ganglions par cas découverts dans la région axillaire pour porter les 8,4 ganglions découverts par la méthode traditionnelle à 14,0 ganglions par cas.

CONCLUSIONS : L'utilisation de la méthode au CH40 offre deux avantages techniques : elle permet au chirurgien de localiser les ganglions lymphatiques noircis au moment de l'intervention chirurgicale et au pathologiste de chercher des ganglions présents dans le tissu gras. L'exérèse de ganglions lymphatiques au moyen de particules de carbone activé est peu coûteuse, facile à pratiquer et permet de reconnaître facilement les ganglions lymphatiques les plus petits. La méthode au CH40 est la technique de choix pour détecter les ganglions lymphatiques axillaires lorsque le nombre de ganglions lymphatiques détectés par la méthode classique est trop limité pour permettre une intervention chirurgicale précise. En conclusion, l'étude démontre que le CH40 pourrait constituer un outil approprié qui aiderait à déterminer avec plus de précision le stade de spécimens axillaires dans les cas de cancer du sein.

Lymph-node status is a major determinant in the staging and ultimate prognosis of patients with breast carcinoma.¹⁻⁴ For accurate staging, several lymph nodes need to be resected from the axillary fat.⁵ In some cases, only a few lymph nodes can be detected by traditional methods, because it is technically difficult, in a blood-stained operative field, to identify lymph nodes and draining lymphatic vessels hidden in the adjacent fat. Some patients found to have negative lymph nodes by the standard method have metastatic breast carcinoma within a few years.⁶ It is therefore questionable whether all the metastases along the lymphatic drainage system can be detected by conventional methods.

To identify as many lymph nodes as possible in the axillary fat, in order to decrease the possibility of undetected metastatic nodes in patients with primary breast cancer, an emulsion of activated carbon particles (CH40)⁷⁻¹³ was injected into the centre of the mammary gland, close to the tumour site, 3 days before radical surgery. After injection, the CH40 was readily absorbed into regional lymphatics and streamed along with the lymph flow to blacken regional lymph nodes. Lymph-node dissection after injection of activated carbon particles is inexpensive, simple and easy to perform and will aid in the detection of small lymph nodes.

PATIENTS AND METHODS

Between July 1997 and January 1998, we studied 25 patients with operable primary breast cancer who were scheduled to undergo modified radical mastectomy at the Department of Surgery, Sendai National Hospital in Japan. We excluded the following patients: those who had previously undergone biopsy or who had received radiotherapy to the tumour, those having clinically extensive metastases and those with tumours that were histologically non-infiltrating. Thirty-four patients who underwent modified radical mastectomy with lymph-node dissection by the traditional method without injection of CH40 were included as controls. The resected neoplasms were classified according to the TNM system on the basis of data from the pathology and operative reports. Activated carbon CH40 (50 mg/mL) (Mitsubishi Chemicals Co., Ltd., Tokyo) containing very small carbon particles (21 nm in diameter) as determined by scanning electron microscopy, was combined with 20 mg/mL of polyvinylpyrrolidone (K-30; Nakarai Chemicals Co., Ltd., Kyoto, Japan) (40 000 d) mixed in saline and then kneaded with 3 rollers to make a carbon suspension.

Three days before operation, 0.5 mL of CH40 was administered subdermally, immediately adjacent to the

nipple to map the axillary lymphatic system. At modified radical mastectomy, blunt dissection was done until a black-stained node was identified. The dye-filled tract was dissected to the first black lymph node. If possible, the tract was followed distally to the soft tissue around the subclavian vein to ensure that the identified lymph node was the most distal one. All resections included levels I and II, and, at least some level III nodes; the pectoralis minor muscle was left intact. After operation, the axillary fat was dissected, and the axillary pad was examined pathologically by manual dissection, including visual examination and palpation, for both groups of patients. The nodes were excised, embedded in paraffin, sectioned and stained with hematoxylin-eosin. The numbers of lymph nodes found by the traditional method and by the CH40-injection method were recorded.

The *t*-test was used for statistical analysis of the findings. A *p* value of less than 0.05 was considered significant.

RESULTS

The women ranged in age from 20 to 77 years (mean 49 years). The tumour size and histologic axillary nodal status for each patient are shown in Table I. The 2 study groups were comparable in terms of basal clinical characteristics. Carbon-stained axillary lymph nodes were identified in all pa-

tients in the CH40-injected group (Fig. 1). The nodes stood out as blackened nodules against a background of yellow fat. The total number of lymph nodes removed from patients in the CH40-injected group was 350, with an average of 14.0 nodes per patient at the first axillary level; 1.8 at the second level, and 4.5 at the third level (Table II). By the traditional method, an average of only 8.4 nodes, 0.8 nodes and 2.8 nodes were detected in each patient at the first, second and third axillary levels, respectively. The number of nodes detected by the CH40-injection method was significantly ($p = 0.0001$) greater than those detected by the traditional method. As the techniques used by the pathologists to locate the nodes were the same for both groups (visual examination and palpation), this difference is considered to be due to the efficacy of the carbon particles in making the nodes more visible.

DISCUSSION

The treatment of breast cancer has continued to change during the past decade, with a trend toward more conservative surgical procedures, usually combined with irradiation of the breast and axilla.¹⁴⁻²² The prognosis of breast cancer is reported to be essentially the same for patients with clinically positive nodes who undergo either a radical mastectomy or a mastectomy combined with radiotherapy. These findings raise doubts about the popularly held concept that dissection of more nodes will improve the prognosis of patients with carcinoma of the breast.^{2,23}

Despite convincing evidence in support of the notion that an axillary dissection does not affect the incidence of distant disease or the survival of patients with carcinoma of the breast, there are still valid reasons for performing some type of axillary dissection. First, the true axillary nodal

status provides the best index of prognosis and helps to identify those who should be considered for systemic adjuvant therapy. More accurate staging should improve the survival of patients with breast cancer by identifying those who benefit from either the surgical procedure or the accompanying adju-

vant therapy. In addition, some patients will not be unnecessarily exposed to the toxic effects of adjuvant therapy. Second, since a proportion of patients who do not undergo axillary dissection at the time of resection subsequently have axillary involvement in the form of palpable nodes containing

Table I

Characteristics of Patients Who Had Primary Breast Cancer and Were Included in the Study*

Characteristic	Group		p value
	CH40, n = 25	Control, n = 34	
Mean (and standard error) age, yr	49.9 (3.4)	54.2 (2.1)	NS
Tumour size, no. of patients			NS
T1	12	12	
T2	10	15	
T3	3	7	
Lymph-node metastasis, no. of patients			NS
N0	11	9	
N1	11	19	
N2	3	6	

*Patients were classified according to the TNM system on the basis of data from the pathology and operative reports. NS = not significant.

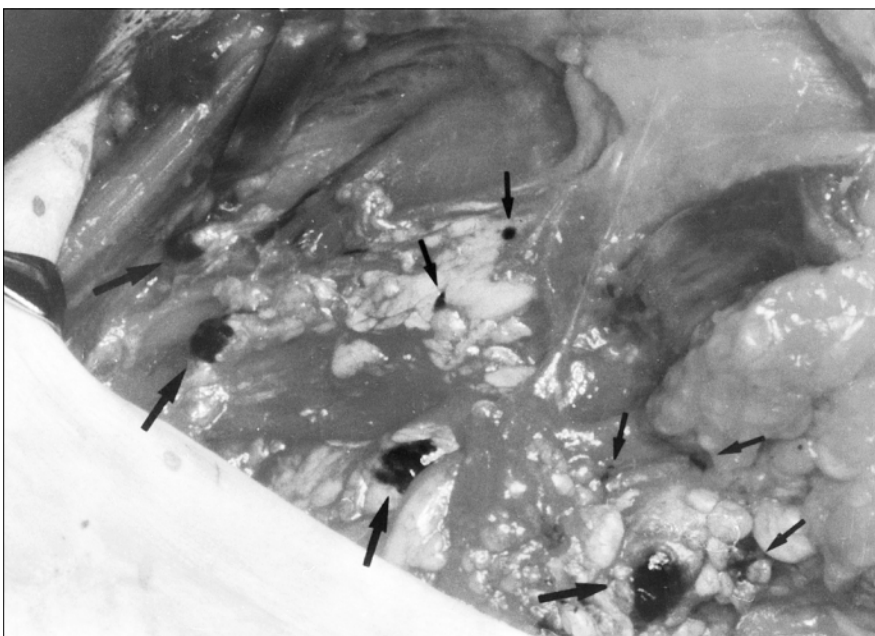


FIG. 1. Intraoperative mapping in a patient undergoing mastectomy for invasive breast cancer. Lymph nodes stained with carbon can be seen (arrows).

tumours, the use of axillary dissection with mastectomy could not only enhance the control of local regional recurrence but also reduce the need for further operative intervention. Although the finding of micrometastatic disease in a single lymph node was initially considered unimportant, more recent studies have shown a poorer survival rate for patients in whom micrometastases are detected by either serial sectioning, immunohistochemical staining or polymerase chain reaction analysis.^{24,25}

At the time of resection, all nodules suspected of being lymph nodes are removed, but small nodes are often more easily located by palpation than by visual examination. Thus, it is possible that the surgeon may not remove all the axillary nodes. This study was designed to assess whether lymph-node mapping with carbon facilitates identification and dissection of axillary lymph nodes. This technique was originally proposed by Hagiwara and associates²⁶ for gastric cancer and by Fujii and associates²⁷ and Sawai and colleagues²⁸ for breast cancer, in which lymphatic drainage from primary tumours can be mapped to regional lymph nodes. After administration, the CH40 particles are readily adsorbed into regional lymphatic vessels and blacken axillary lymph nodes. It is of note that the number of dissected axillary lymph nodes in the CH40 group was significantly larger than that in the control group. Kjaergaard and associates²⁹ demonstrated that ax-

illary recurrence in patients with breast cancer who have low-risk primary lesions decreased as the number of excised lymph nodes increased. The rate of axillary recurrence in their patients, resulting from missed lymph nodes was 12% when no lymph nodes were removed, 7% when 2 lymph nodes were removed and only 2% when more than 3 lymph nodes were removed. In a similar study by Graversen and associates,³⁰ the rate of axillary recurrence after removal of 5 to 10 axillary lymph nodes was 3%. Fisher and associates⁵ demonstrated that increasing the number of axillary nodes removed does not lead to an increase in the number of patients in whom positive nodes are diagnosed. However, increasing the number of the examined axillary lymph nodes does lead to an increase in the number of patients demonstrating 4 or more positive nodes. When 10 or less axillary nodes are removed, patients identified as having 1 to 3 positive nodes will likely actually have 4 or more positive nodes. Mathiesen and colleagues³¹ compared complete axillary dissection to simple sampling and reported that the probability of finding at least 1 metastatic node increased continuously up to about 10 removed nodes. They suggested 10 as the minimum number of dissected lymph nodes for an adequate sampling procedure. Axillary recurrence is associated with the number of metastatic nodes,³² especially when 4 or more nodes are involved or when fewer than 10 nodes have been sampled.³³ Thus, complete axillary dissection markedly decreases the incidence of axillary recurrence.³⁴ Senofsky and colleagues³⁵ demonstrated that complete axillary dissection results in recurrence rates approaching zero at 50 months and provides accurate staging. A sampling accuracy equivalent to complete node dissection can only be achieved if sampling procedures include enough lymph nodes to detect skip metastases

to any levels of the axilla and if the number of nodes is large enough to detect metastatic involvement by chance alone.

It is generally accepted that axillary lymph-node dissection provides only prognostic information and has minimal therapeutic benefit because nodal metastases in breast cancer represent systemic disease. Recently, however, several researchers have argued that the control of local disease may translate to an improvement in overall survival. Sosa and colleagues³⁶ examined the relationship between the extent of axillary lymph-node dissection in patients with stage I breast cancer and survival. They concluded that in patients with stage I breast cancer, improved survival was associated with a more complete axillary lymph-node dissection. The fact that improved locoregional control might decrease secondary systemic spread and improve survival is supported by several reports.³⁷⁻³⁹

Although the histologic status of axillary lymph nodes is one of the most important prognostic indicators in patients with breast cancer, over 80% of women who undergo axillary dissection suffer at least 1 postoperative complication in the arm, including pain, paresthesia, lymphedema, seroma, infection and limitation of shoulder motion. A potential alternative to axillary lymph-node dissection is sentinel-node resection.^{40,41} In sentinel-lymph-node mapping, a radioactive substance or a blue dye is injected into the area around the tumour. After administration, the lower axilla is explored through a small incision and the lymph node that has taken up the dye or radioactive substance is excised. If histologic examination reveals no tumour involvement, the rest of the axillary lymph nodes are likely to be tumour free. Many patients with negative nodes could be spared an axillary lymph-node dissection if the sentinel node was found to be negative. This

Table II

Mean (and Standard Error) Number of Lymph Nodes Resected by Level

Level	Group		p value
	CH40	Control	
I	14.0 (1.1)	8.4 (0.8)	0.0001
II	1.8 (0.3)	0.8 (0.5)	NS
III	4.5 (0.8)	2.8 (0.7)	NS

NS = not significant.

method is less invasive than a complete axillary dissection and lowers both morbidity and cost. Although sentinel-node biopsy has not been accepted as the standard treatment, axillary node dissection and lymph-node research for staging in breast cancer is certain to move in this direction. In this study, sentinel nodes could be identified with our carbon technique in all cases. This method, however, by waiting 3 days between injection and the harvest, stains all the nodes in the axilla. Therefore, it may be difficult to identify which node in the basin is the sentinel node. If the time interval between the injection and the harvest was shorter (1 to 3 hours), the carbon would stain only the sentinel node and not higher nodes. Sentinel-lymph-node biopsy, using dyes, radiographic contrast agents or radioactive tracers is reported to be technically challenging.⁴² Since activated carbon particles in suspension are less than 200 nm in size, the particles are absorbed smoothly into lymphatic vessels. After injection of CH40 peritumorally, the regional lymphatic capillaries turn black due to the absorption of carbon particles into the lymphatics, and the suspension also reaches the regional lymph nodes. The CH40 is retained in the sentinel node and other nodes by active phagocytosis, but some of it passes through the sentinel node to higher nodes if sufficient time is given, and some of it will pass through the axilla.

CONCLUSIONS

Dissection using the activated carbon particle technique for lymph-node dissection is inexpensive, easy to perform and enables the smallest lymph nodes to be easily recognized, even by inexperienced residents. Our study demonstrated that CH40 could be an appropriate tool for more accurate staging of breast cancer axillary lymph-node specimens.

References

1. Adair F, Berg J, Joubert L, Robbins GF. Long term follow-up of breast cancer patients: the 30-year report. *Cancer* 1974;33:1145-50
2. Fisher B, Bauer M, Wickerham DL, Redmond CK, Fisher ER, Cruz AB, et al. Relation of number of positive axillary nodes to the prognosis of patients with primary breast cancer. An NSABP update. *Cancer* 1983;52(9):1551-7.
3. Morrow M, Evans J, Rosen PP, Kinne DW. Does clearing of axillary lymph nodes contribute to accurate staging of breast carcinoma? *Cancer* 1984;53:1329-32.
4. Rosen PP, Saigo PE, Braun DW Jr, Weathers E, Kinne DW. Prognosis in stage II (T1N1M0) breast carcinoma. *Ann Surg* 1981;194:576-84.
5. Fisher B, Wolmark N, Bauer M, Redmond C, Gebhardt M. The accuracy of clinical nodal staging and of limited axillary dissection as a determinant of histologic nodal status in carcinoma of the breast. *Surg Gynecol Obstet* 1981;152:765-72.
6. Valagussa P, Bonadonna G, Veronesi U. Patterns of relapse and survival following radical mastectomy. *Cancer* 1978;41:1170-8.
7. Hagiwara A, Takahashi T, Lee R, Ueda T, Takeda M, Itoh T. Animal experiments as a model for clinical trials of a new dosage form of mitomycin C for peritoneal carcinomatosis. *In vivo* 1987;1:43-6.
8. Hagiwara A, Takahashi T. A new drug-delivery-system of anticancer agents: activated carbon particles adsorbing anticancer agents. *In vivo* 1987;1:241-52.
9. Hagiwara A, Takahashi T, Ueda T, Lee R, Takeda M, Itoh T. Intraoperative chemotherapy with carbon particles adsorbing mitomycin C for gastric cancer with peritoneal dissemination in rabbits. *Surgery* 1988;104:874-8.
10. Hagiwara A, Takahashi T, Sawai K, Iwamoto A, Shimotsuma M, Yoneyama C, et al. Lymph nodal vital staining with newer carbon particle suspensions compared with India ink: experimental and clinical observations. *Lymphology* 1992;25:84-9.
11. Hagiwara A, Takahashi T, Sawai K, Sakakura C, Hoshima M, Ohyama T, et al. Methrexate bound to carbon particles used for treating cancers with lymph node metastases in animal experiments and a clinical pilot study. *Cancer* 1996;78:2199-209.
12. Hagiwara A, Takahashi T, Sawai K, Sakakura C, Shirasu M, Ohgaki M, et al. Selective drug delivery to peritumoral region and regional lymphatics by local injection of aclarubicin adsorbed on activated carbon particles in patients with breast cancer — a pilot study. *Anti-Cancer Drug* 1997;8:666-70.
13. Hagiwara A, Takahashi T, Kitamura K, Sakakura C, Shirasu M, Ohgaki M, et al. Endoscopic local injection of a new drug delivery formulation, anticancer drug bound to carbon particles, for digestive cancers: pilot study. *J Gastroenterol* 1997;32:141-7.
14. Fisher B, Anderson S, Redmond CK, Wolmark N, Wickerham DL, Cronin WN. Reanalysis and results after 12 years of follow-up in a randomized clinical trial comparing total mastectomy with lumpectomy with or without irradiation in the treatment of breast cancer. *N Engl J Med* 1995;333:1456-61.
15. Recht A, Come SE, Henderson C, Gelman RS, Silver B, Hayes DF, et al. The sequencing of chemotherapy and radiation therapy after conservative surgery for early-stage breast cancer. *N Engl J Med* 1996;334:1356-61.
16. Early Breast Cancer Trialists' Collaborative Group. Effects of radiotherapy and surgery in early breast cancer. An overview of the randomized trials. *N Engl J Med* 1995;333(22):1444-55.
17. Jacobson JA, Danforth DN, Cowan KH, d'Angelo T, Steinberg SM, Pierce

- L, et al. Ten-year results of a comparison of conservation with mastectomy in the treatment of stage I and II breast cancer. *N Engl J Med* 1995;332:907-11.
18. Amalric R, Santamaria F, Robert F, Seigle J, Altschuler C, Kurtz JM, et al. Radiation therapy with or without primary limited surgery for operable breast cancer: a 20-year experience at the Marseilles Cancer Institute. *Cancer* 1982;49(1):30-4.
 19. Veronesi U, Saccozzi R, Del Vecchio M, Banfi A, Clemente C, De Lena M, et al. Comparing radical mastectomy with quadrantectomy, axillary dissection, and radiotherapy in patients with small cancers of the breast. *N Engl J Med* 1981;305(1):6-11.
 20. Montague ED, Gutierrez AE, Barker JL, Tapley ND, Fletcher GH. Conservation surgery and irradiation for the treatment of favorable breast cancer. *Cancer* 1979;43(3):1058-61.
 21. Calle R, Pilleron JP. Radiation therapy, with and without lumpectomy, for operable breast cancer; ten-year results. *Breast* 1979;5:2-26.
 22. Fisher B, Wolmark N, Bauer M, Redmond C, Gebhardt M. The accuracy of clinical nodal staging and of limited axillary dissection as a determinant of histologic nodal status in carcinoma of the breast. *Surg Gynecol Obstet* 1981;152:765-72.
 23. Smith JA, Gamez-Araujo J, Gallager S, White E, McBride CM. Carcinoma of the breast. *Cancer* 1977;39:527-32.
 24. Noguchi S, Aihara T, Motomura K, Inaji H, Imaoka S, Koyama H. Detection of breast cancer micrometastases in axillary lymph nodes by means of reverse transcriptase-polymerase chain reaction. *Am J Pathol* 1996;2:649-56.
 25. Schoenfeld A, Luqmani Y, Smith D, O'Reilly S, Sinnott HD, Coombs RC, et al. Detection of breast cancer micrometastases in axillary lymph nodes by using polymerase chain reaction. *Cancer Res* 1994;54:2986-90.
 26. Hagiwara A, Takahashi T, Ueda T, Iwamoto A, Torii T. Activated carbon particles as anti-cancer drug carrier into regional lymph nodes. *AntiCancer Drug Des* 1987;1(4):313-21.
 27. Fujii H, Sawai K, Shimotsuma M, Tokuda H, Hagiwara A, Takahashi T. Study of lymphatic flow of mammary gland by application of activated carbon emulsion (CH44). *J Jpn Soc Cancer Ther* 1986;21:96-102.
 28. Sawai K, Hagiwara A, Shimotsuma M, Takahashi T. Analysis of lymphatic flow using activated carbon particle CH40. *Jpn J Breast Cancer* 1995;10:445-51.
 29. Kjaergaard J, Blichert-Toft M, Andersen J, Rank F, Pedersen BV. Probability of false negative nodal staging in conjunction with partial axillary dissection in breast cancer. *Br J Surg* 1985;72(5):365-7.
 30. Graversen H, Blichert-Toft M, Andersen J, Zedeler K. Breast cancer: risk of axillary recurrence in node-negative patients following partial dissection of the axilla. *Eur J Surg Oncol* 1988;14:407-12.
 31. Mathiesen O, Bonderup O, Panduro J. Axillary sampling and the risk of erroneous staging of breast cancer: an analysis of 960 consecutive patients. *Acta Oncol* 1990;29:721-5.
 32. Smith J 3d, Gamez-Araujo JJ, Gallager HS, White EC, McBride CM. Carcinoma of the breast: analysis of total lymph node involvement versus level of metastasis. *Cancer*. 1977;39(2):527-32.
 33. Wilking N, Rutqvist L, Carstensen J, Mattsson A, Skoog L. Prognostic significance of axillary nodal status in primary breast cancer in relation to the number of resected nodes. Stockholm Breast Cancer Study. *Acta Oncol* 1992;31(1):29-35.
 34. Ball A, Waters R, Fish S, Thomas J. Radical axillary dissection in the staging and treatment of breast cancer. *Ann Roy Coll Surg* 1992;274:126-9.
 35. Senofsky GM, Moffat FL Jr, Davis K, Masri MM, Clark KC, Robinson DS, et al. Total axillary lymphadenectomy in the management of breast cancer. *Arch Surg* 1991;126(11):1336-42.
 36. Sosa JA, Diener-West M, Gusev Y, Choti MA, Lange JR, Dooley WC, et al. Association between extent of axillary lymph node dissection and survival in patients with stage I breast cancer. *Ann Surg Oncol* 1998;5:140-9.
 37. Diab SG, Hilsenbeck SG, de Moor C, Clark GM, Osborne CK, Ravdin PM, et al. Radiation therapy and survival in breast cancer patients with 10 or more positive axillary lymph nodes treated with mastectomy. *J Clin Oncol* 1998;16:1655-60.
 38. Ragaz J, Jackson SM, Le N, Plenderleith IH, Spinelli JJ, Basco VE, et al. Adjuvant radiotherapy and chemotherapy in node-positive premenopausal women with breast cancer. *N Engl J Med* 1997;337:956-62.
 39. Overgaard M, Hansen PS, Overgaard J, Rose C, Andersson M, Bach F, et al. Postoperative radiotherapy in high-risk premenopausal women with breast cancer who receive adjuvant chemotherapy. Danish Breast Cancer Cooperative Group 82b trial. *N Engl J Med* 1997;337:949-55.
 40. McMasters KM, Giuliano AE, Ross MI, Reintgen DS, Hunt KK, Byrd DR, et al. Sentinel-lymph-node biopsy for breast cancer. Not yet the standard of care. *N Engl J Med* 1998;339:990-5.
 41. Wood A. Treatment of breast cancer. *N Engl J Med* 1998;339:974-84.
 42. Krag D, Weaver D, Ashikaga T, Moffat F, Klimberg VS, Shriver C, et al. The sentinel node in breast cancer. *N Engl J Med* 1998;339:941-6.