



Published in final edited form as:

*Retina*. 2013 ; 33(7): 1328–1337. doi:10.1097/IAE.0b013e3182831293.

## Preclinical evaluation and intraoperative human retinal imaging with a high-resolution microscope-integrated spectral domain optical coherence tomography device

Paul Hahn, MD, PhD<sup>1</sup>, Justin Migacz, MS<sup>2</sup>, Rachele O'Connell, BS<sup>1</sup>, Shelley Day, MD<sup>1</sup>, Annie Lee, MD<sup>1</sup>, Phoebe Lin, MD, PhD<sup>1</sup>, Robin Vann, MD<sup>1</sup>, Anthony Kuo, MD<sup>1</sup>, Sharon Fekrat, MD, FACS<sup>1</sup>, Prithvi Mruthyunjaya, MD<sup>1</sup>, Eric A. Postel, MD<sup>1</sup>, Joseph A. Izatt, PhD<sup>2</sup>, and Cynthia A. Toth, MD<sup>1,\*</sup>

<sup>1</sup>Department of Ophthalmology, Duke University Medical Center, Durham, NC

<sup>2</sup>Department of Biomedical Engineering, Duke University, Durham, NC

### Abstract

**Purpose**—We have recently developed a high-resolution microscope-integrated spectral domain optical coherence tomography (MIOCT) device designed to enable OCT acquisition simultaneous with surgical maneuvers. The purpose of this report is to describe translation of this device from preclinical testing into human intraoperative imaging.

**Methods**—Prior to human imaging, surgical conditions were fully simulated for extensive preclinical MIOCT evaluation in a custom model eye system. MIOCT images were then acquired in normal human volunteers and during vitreoretinal surgery in patients who consented to participate in a prospective Institutional Review Board-approved study. MIOCT images were obtained before and at pauses in surgical maneuvers and were compared based on pre-determined diagnostic criteria to images obtained with a high-resolution research handheld spectral domain OCT system (HHOCT, Biotigen Inc., Research Triangle Park, NC) at the same time point. Cohorts of five consecutive patients were imaged. Successful endpoints were pre-defined, including 80% correlation in identification of pathology between MIOCT and HHOCT in 80% of patients.

**Results**—MIOCT was favorably evaluated by study surgeons and scrub nurses, all of whom responded that they would consider participating in human intraoperative imaging trials. The preclinical evaluation identified significant improvements that were made prior to MIOCT use during human surgery. The MIOCT transition into clinical human research was smooth. MIOCT imaging in normal human volunteers demonstrated high-resolution comparable to tabletop scanners. In the operating room, after an initial learning curve, surgeons successfully acquired human macular MIOCT images before and after surgical maneuvers. MIOCT imaging confirmed preoperative diagnoses, such as full-thickness macular hole and vitreomacular traction, and demonstrated post-surgical changes in retinal morphology. Two cohorts of five patients were imaged. In the second cohort, the predefined endpoints were exceeded with 80% correlation between MIOCT and HHOCT imaging in 100% of patients.

**Conclusion**—This report describes high-resolution MIOCT imaging using our prototype device in human eyes during vitreoretinal surgery, with successful achievement of pre-defined endpoints for imaging. Further refinements and investigations will be directed towards fully integrating MIOCT with vitreoretinal and other ocular surgery to image surgical maneuvers in real time.

\*Corresponding Author: Cynthia A. Toth, MD; Box 3802, DUMC, Durham, NC 27710; Phone 919-684-5631; Fax 919-681-6474; cynthia.toth@duke.edu.

## Keywords

Spectral domain optical coherence tomography; OCT; microscope-mounted; microscope-integrated; intraoperative; vitreoretinal surgery; translational; human imaging

---

## Introduction

Optical coherence tomography (OCT) is a rapid, noncontact method of cross-sectional bioimaging whose ophthalmologic diagnostic applications have been constantly expanding since its development over 20 years ago.<sup>1</sup> Until recently, OCT imaging has been limited to tabletop devices generally confined to the clinic setting. The intraoperative use of OCT was a significant application of this technology designed to view anatomic relationships in three dimensions. The development of a handheld OCT (HHOCT) scanner has enabled high-resolution spectral domain OCT (SDOCT) imaging of patients unable to position at a conventional tabletop scanner, including patients undergoing surgery in the operating room.<sup>2</sup> Intraoperative imaging with HHOCT has demonstrated relief of macular traction surrounding a macular hole after internal limiting membrane peel, removal of vitreomacular adhesions following hyaloid peel, the presence of a secondary epiretinal membrane following initial superficial membrane peel, the persistence of subclinical subretinal fluid during retinal detachment repair and macular hole repair, and a potential communication between the vitreous cavity and intraretinal fluid in optic pit-associated schisis.<sup>2-8</sup> Intraoperative retinal imaging with HHOCT, however, requires halting surgical maneuvers before imaging is initiated and is therefore fundamentally limited by the inability to image intraocular surgical maneuvers in real time.

Several groups are currently developing OCT technology capable of intrasurgical imaging of live maneuvers.<sup>9</sup> Some groups have reported integration of an OCT scanner into an intraocular probe with successful imaging of intraocular structures in model eyes.<sup>10,11</sup> Binder and coworkers reported intraoperative imaging of 25 human retinas using a Zeiss Cirrus SDOCT unit adapted to a surgical microscope.<sup>12</sup> Our group has developed a novel prototype microscope-integrated spectral domain OCT (MIOCT) device, designed to enable simultaneous surgical viewing and high-resolution SDOCT imaging.<sup>13,14</sup> In previous reports, we have described the design of the MIOCT, which is based on folding of the optical OCT path into the full beam path of the operating microscope to enable high-resolution imaging.<sup>13</sup> The optomechanical design of the MIOCT enables parfocal and coaxial OCT imaging with the surgical view while maintaining the working distance of the surgical microscope and viewing systems. Whereas our previous reports have referred to this device as a microscope-mounted OCT (MMOCT) device, we have adjusted our nomenclature to “microscope-integrated OCT,” or MIOCT, to highlight the integration of our device with the surgical microscope. With this design, we have demonstrated high-resolution SDOCT images and video during cadaveric porcine vitreoretinal surgical maneuvers simultaneously during surgical viewing, providing the first OCT characterization of vitreoretinal surgical instruments interacting with the retina.<sup>14-16</sup> In this report, we present methods of translational research to capture preclinical surgeon and nurse feedback as an integral tool for system and methods modifications. This feedback was a key precursor as we proceeded to inhuman use of high-resolution MIOCT in vitreoretinal imaging of human patients undergoing surgery.

## Methods

### MIOCT design

As we have previously described, a high-resolution MIOCT prototype device was developed to interface optically and mechanically with an ophthalmic operating microscope (Leica Microsystems, Heerbrugg, Switzerland).<sup>13</sup> The design strategically placed a dichroic mirror to allow folding of the optical path of the MIOCT into that of the surgical microscope in order to permit simultaneous imaging during surgical manipulations without altering the surgeon's view. At this insertion point, the OCT beam has room to be expanded to the ideal width for high-resolution, diffraction-limited imaging of the retina. This prototype was custom-adapted to a Bioptigen (Research Triangle Park, NC) OCT scanner with a center wavelength of 865 nm and a spectrometer equipped to acquire images at a rate of 20,000 A-scans per second. The lateral resolution was 15  $\mu\text{m}$ , and the field of view was  $10 \times 10$  mm. The axial resolution was 5  $\mu\text{m}$  and the depth range was 1.55 mm.

### Surgeon and Nurse Preference Testing

Prior to human use, testing and refinement of the MIOCT was performed under fully simulated surgical conditions in the human operating suite (Fig. 1A). Six vitreoretinal surgeons from the Duke Eye Center, including 3 attending surgeons and 3 vitreoretinal surgical fellows, participated; vitreoretinal surgeons who were actively involved in the design and development of the MIOCT device (P.H. and C.A.T.) were excluded from testing and from access to data until after analysis. Two anterior segment surgeons and two scrub nurses, also from the Duke Eye Center, participated.

Each participant was asked to don a sterile gown, cap, mask, and gloves, and each surgeon was asked to perform a complete set of predefined external and intraocular surgical maneuvers. The MIOCT device was mounted to the surgical microscope and connected to the computer workstation, which was positioned at the foot of the surgical bed and was required to drive the MIOCT. A detailed questionnaire was created to assess the impact of the MIOCT unit on each maneuver. All simulated surgical tasks were performed with the assistance of a scrub nurse, and the responses to the questionnaires were entered by a dedicated scribe during the simulations. A separate questionnaire was created for vitreoretinal surgeons, anterior segment surgeons, and scrub nurses, tailored according to the unique specificities of their intraoperative responsibilities.

Vitreoretinal surgical manipulations were performed with the Constellation Vision System (Alcon, Fort Worth, TX). A complete range of intraocular instruments, including an endoillumination probe, was provided to simulate vitreoretinal surgical maneuvers involving both the surgeons and nurses. A custom model retina was constructed by placement of a 1" diameter achromatic doublet lens with a 30 mm focal length in an adjustable lens tube with a 1:1 scale image of a human retina mounted at the front focal plane of the lens; two small holes were placed in opposite sides of the lens tube to simulate sclerotomies for insertion of surgical instruments. Anterior segment mock surgical manipulations were similarly performed with the Infiniti Vision System (Alcon) on a model eye with a complete range of instruments for both phacoemulsification and corneal manipulations.

Questionnaires were designed to assess the impact of the presence of the MIOCT device on performing surgery effectively and efficiently and not to assess the potential benefits of intrasurgical OCT imaging. Questionnaires assessed numerous parameters, including working space, ergonomics, stability, visibility through the MIOCT dichroic mirror, and aesthetic impact but specifically did not assess OCT acquisition. As a result, surgical tasks were performed with the MIOCT mounted to the surgical microscope but without concurrent OCT acquisition.

Participants were asked to rate maneuvers on a scale of 0 to 5 (0 = “An improvement”; 1 = “No impact”; 2 = “Noticeable difference, but would not adversely affect surgery”; 3 = “Noticeable difference, but may be able to work around it”; 4 = “Noticeable difference, and difficult to work around it”; 5 = “Unacceptable. Must be revised/ fixed prior to human use in an operating room”). For all assessments, participants also had the option of providing unsolicited comments, which were recorded by the scribe. During vitreoretinal simulations, intraocular maneuvers were assessed with visualization through three different viewing systems – the Oculus Binocular Indirect Ophthalmic Microscope (BIOM; Oculus Inc, Lynnwood, WA), a wide-angle contact lens system (Volk Optical Inc, Mentor, OH), and a disposable flat contact lens (Dutch Ophthalmic, Exeter, NH). All surgeons performed tasks first as the primary surgeon and then as the assistant. These tasks were assessed separately by the scrub nurses. At the conclusion of the simulation, all participants were asked to provide an overall rating of the device and asked if they would consider participating in human trials with the device.

## Human Imaging

Institutional Review Board and Data and Safety Monitoring Committee approval for a research protocol in accordance with all applicable Health Insurance Portability and Accountability Act regulations was obtained along with informed consent from all human patients undergoing MIOCT or Bioptigen HHOCT imaging. To first evaluate the quality of imaging, presurgical human retinal MIOCT imaging through the BIOM was performed on four healthy subjects lying supine on a bed in the operating room without any surgical procedure. After successful imaging of all four subjects, we proceeded to intraoperative testing.

Prior to the initiation of surgery, the MIOCT was mounted onto the Leica surgical microscope. Optical and power cables were coursed aurally to the foot of the bed, where a computer workstation was positioned to drive the MIOCT scanner and to receive the OCT image output. A dedicated member of the research team was assigned to operate the computer workstation. Apart from initial alignment, no manipulations of the mounted MIOCT device itself were required, as all controls were based from the computer workstation. Power from the OCT system was measured before and after all MIOCT imaging and verified to be within preapproved limits.

MIOCT imaging was performed through the BIOM wide-angle viewing system during macular surgery performed by a single surgeon (C.A.T., Fig. 1B). The MIOCT-mounted microscope was positioned to center the surgical view over the pupil. The reference arm and the BIOM focus were adjusted to maximize image quality. The orientation of the eye with respect to the MIOCT was adjusted by translation of the microscope, manual tilt of the BIOM lower objective lens, and/or manipulation of the orientation of the eye to obtain OCT images through the macula. MIOCT images were acquired across an 8 mm linear scan with 1000 A-scans. Twelve linear scans were registered and summed for final visualization. Bioptigen HHOCT was performed as previously described<sup>2</sup>. All imaging was performed only on the eye undergoing surgery.

Images were obtained in the operating room with the patient supine on the surgical bed using both MIOCT and HHOCT at a preincision and then intraoperative time point. Preincision imaging was performed under sterile conditions with the patient fully draped and the lid speculum placed. Intraoperative imaging, also under sterile and draped conditions, was performed immediately following vitreoretinal surgical manipulations during a normal pause in surgery; all instruments were removed from the eye, the scleral ports were plugged, and images were subsequently acquired. Total OCT imaging time, including both MIOCT and HHOCT, was limited to 30 minutes. Per protocol, surgical procedures were to be

performed as standard of care, without influence of surgical decisions based on intraoperative OCT images.

## Data Analysis

MIOCT and HHOCT images from both time points were compared by two graders masked to imaging modality and imaging timepoint. Graders examined all scans captured in the series and first recorded whether the imaging was acceptable, defined as the ability to see both the inner retinal surface and the retinal pigment epithelium (RPE) interface in at least one image. Graders then examined all scans and indicated whether they could identify the following macular pathology or morphology on any scan captured in the series: 1) macular hole, 2) epiretinal membrane, 3) retinal edema, schisis, or cystoid structures, 4) subretinal fluid or retinal detachment, and 5) central retinal thickness from inner retina to RPE. Percent correlation between MIOCT and HHOCT for the detection of macular pathology was calculated by the number of features identified on MIOCT that were also identifiable on HHOCT.

Prior to initiation of human imaging trials, endpoints for satisfactory imaging were predefined. These endpoints included 1) successful completion of surgery in all cases without interference from or serious adverse events related to the MIOCT unit, 2) acquisition of at least one acceptable image as defined above, and 3) 80% MIOCT-to-HHOCT correlation of identification of pathology in 80% of patients. Cohorts of five patients were imaged until all endpoints were achieved. All patients were monitored post-operatively for any adverse events.

## Results

### Surgeon and Nurse Preference Testing

All results from the preclinical questionnaires were tabulated, and responses addressing each comment or adverse assessment (rating of 4 or 5) were formulated. In summary, the MIOCT device was rated favorably by surgeons and scrub nurses (Fig. 2). Six vitreoretinal surgeons evaluated the device. Half of the vitreoretinal surgeons felt the presence of the MIOCT had “No impact” in surgery (an overall rating of 1), and half felt there was a “Noticeable difference, but would not adversely affect surgery” (an overall rating of 2). No vitreoretinal surgeon felt that the MIOCT overall adversely affected surgery. The majority of responses were scored as 1, “No impact.” All vitreoretinal surgeons stated that they would consider participating in human MIOCT imaging trials in their operating room.

There were three notable items identified by vitreoretinal surgeons as potentially affecting surgery. One was the additional height induced by the physical space of the MIOCT mounted on the operating microscope. Most surgeons did not feel that this ergonomic change adversely affected surgery (ratings = 3, “Noticeable difference, but may be able to work around it”), but one surgeon raised concerns regarding visibility beyond the microscope (rating of 4, “Noticeable difference, and difficult to work around it”) and the ability to pass instruments safely to the scrub nurse (another rating of 4). Another item was a peripheral clipping of the visual field with an additional central glare visible during external procedures. These changes were present only with external illumination from the microscope and disappeared with endoillumination during intraocular vitreoretinal manipulations. Similarly, these changes were generally felt not to adversely affect surgery (ratings = 3). The third notable item was the course of the cables connecting the MIOCT to the computer workstation. During initial testing, the position of these cables interfered with easy maneuvering of other surgical equipment. Following an “Unacceptable. Must be revised/fixed prior to human use in an operating room” rating of 5, the cables were modified



to course aerially at a distance away from other equipment. These changes were approved by the surgeon identifying this issue, and no further concerns were raised in subsequent evaluations. Importantly, no surgeon felt that the dichroic mirror adversely affected surgery or the surgical view (ratings = 2). While some surgeons noticed “a slightly dimmer view” with the dichroic mirror in place, this difference was only detectable upon repeated removal and reinsertion of the mirror with careful comparisons between both circumstances.

Two anterior segment surgeons evaluated MIOCT. Overall, both anterior segment surgeons felt the MIOCT had “No impact” on their ability to perform surgery (an overall rating of 1). The majority of responses were rated with a score of 1, “No impact.” Both surgeons stated that they would consider participating in human MIOCT imaging trials in their operating room.

The primary issue identified by anterior segment surgeons was the peripheral clipping of the visual field with a focal central glare, as noted by the vitreoretinal surgeons. Both anterior segment surgeons stated that these changes made a “Noticeable difference, but may be able to work around it” (rating of 3). Both surgeons also did not feel that the dichroic mirror adversely affected their surgical view (rating of 2). While both surgeons noticed a slight change in contrast with the dichroic mirror in place, this difference was only detectable upon repeated removal and reinsertion of the mirror with careful comparisons between both circumstances.

Two scrub nurses evaluated the device. One scrub nurse stated that the MIOCT made a noticeable difference, but would not adversely affect surgery (an overall rating of 2), and one scrub nurse felt the MIOCT made a noticeable difference, but she may be able to work around it (an overall rating of 3). The majority of responses were rated with a score of 1, “No impact.” Both nurses said they would consider participating in human MIOCT imaging trials in the operating room. Two notable items were identified by the scrub nurses as adversely affecting surgery. One item was the sharpness of the edges of the MIOCT, which was rated by one scrub nurse to make a “Noticeable difference, but difficult to work around it” (rating of 4). Subsequently, based on these comments, the specified MIOCT edges were machined to be rounded. The other item was the time required to install the MIOCT on the surgical microscope (approximately 15 minutes at the time of the simulation) and remove the MIOCT from the microscope (approximately 10 minutes at the time of the simulation). Both scrub nurses noted that these times exceeded the time allotted for surgical turnaround time, which was considered “Unacceptable” (rating of 5).

## Human Imaging

Following technical refinements (such as rounding of the MIOCT edges and aerial coursing of the cables) based on responses from preclinical testing, MIOCT imaging of human eyes was performed. Imaging was first performed on healthy subjects lying supine in the operating room bed without surgical procedure (Fig. 3). Post-process averaging and registration of 12 frames was performed, demonstrating a resolution comparable to that of SDOCT tabletop scanners with clear identification of all retinal layers including multiple hyperreflective bands in the outer retina.

Intraoperative OCT imaging of human eyes undergoing surgery was then performed. Images were acquired at both a preincision and intraoperative time point with instruments removed from the eye. Two sequential cohorts of five patients were imaged in this fashion. These patients were selected from those undergoing macular surgery with exclusion of eyes with corneal or media opacities. Surgeries performed included one macular translocation with 360 degree peripheral retinectomy (MT360) for neovascular age-related macular degeneration (NVAMD) and nine 25-gauge pars plana vitrectomies (PPV) with indocyanine

green (ICG)-assisted membrane peel (MP) for epiretinal membrane (ERM), full-thickness macular hole (FTMH), vitreomacular traction (VMT), and optic pit-associated macular schisis (Table 1).

The MIOCT did not impair the surgeon's subjective ability to effectively perform surgery in any surgical case, and there were no surgical complications or adverse events during any procedure or post-operatively. Acceptable imaging, defined as the ability to visualize both the inner retinal surface and the RPE complex in at least one image, was successfully obtained in all eyes. In the first cohort of five patients, 80% correlation between MIOCT and HHOCT imaging was achieved in only 20% (1 of 5) of surgical cases (Table 1). In two cases (Case 2 and Case 5), retinal morphology through the macula could not be identified with MIOCT imaging due to scanning outside the macula, resulting in zero correlation of macular morphology between MIOCT and HHOCT.

There was a learning curve to obtaining MIOCT scans of adequate resolution directed at the fovea, particularly given the limitations to visibility and adjustment of ocular alignment without surgical instruments within the eye. Specifically, because movement of the MIOCT is limited to the lateral translations possible with the microscope on which the MIOCT is mounted, alignment of the OCT beam towards a defined area was initially challenging. Proper alignment by adjusting the orientation of the eye and of the lower BIOM objective lens, along with movement of the MIOCT, was critical in obtaining scans through the fovea. Additionally, adjustment of the BIOM focus by the surgeon and of the MIOCT reference arm length (adjusted on the mobile computer workstation) by the assistant was important in improving image quality, and communication between the surgeon and assistant required precise and prompt coordination. Apart from alignment, no manipulations of the mounted MIOCT device were required.

Following failure of the first cohort to achieve its endpoint, a second cohort of five patients was imaged. The experience with the MIOCT system quickly resulted in high-resolution images centered on the fovea, and in this second cohort, 80% correlation between MIOCT and HHOCT was achieved in 100% of cases.

Successful MIOCT imaging confirmed preoperative diagnoses in preincision images and identified surgical alterations of retinal morphology in intraoperative images obtained at a pause in surgery. For example, a preoperative FTMH was demonstrated clearly on preincision MIOCT imaging (Fig. 4). Following ICG-assisted internal limiting membrane (ILM) peeling, relief of macular traction can be inferred by the relaxed, slightly corrugated appearance of the retina surrounding the hole. Additionally, the edges of the peeled ILM were visible surrounding the hole. Small intraretinal cystoid spaces and new subretinal fluid surrounding the hole were also identifiable immediately following ILM peeling. In addition, a focal preretinal hemorrhage was evident, casting a shadow through the retina but without any associated disturbance of retinal morphology. In a case of VMT (Fig. 5), vitreous adhesions to the inner surface of the fovea with updrawn inner retina were visible on preincision MIOCT imaging. Following detachment of the posterior hyaloid from the retinal surface, these vitreous adhesions were no longer present. The intraoperative image demonstrates the absence of surgically-induced macular hole, retinal edema, or inner retinal depression, and notably, there is minimal immediate change in the configuration of the inner retina despite release of the attachments.

## Discussion

In this study, we report results of preclinical surgeon preference testing of our prototype MIOCT device, which provided important information for the seamless translation of

MIOCT into the human intraoperative setting. We additionally present intraoperative human images obtained with our MIOCT device, acquired at a preincision time point and an intraoperative time point at a normal pause after macular surgical maneuvers.

Exhaustive preclinical testing was performed to optimize the MIOCT system prior to initiating human imaging. The MIOCT unit was designed based on close collaboration between bioengineers and ophthalmic surgeons, and non-surgical human imaging was performed prior to intraoperative use.<sup>13,14</sup> Significant experience with imaging in cadaveric porcine eyes during actual vitreoretinal surgery was obtained to develop protocols for efficient human imaging.<sup>15,16</sup> As a final step before intraoperative human imaging, we additionally obtained feedback from multiple surgeons and scrub nurses, as described in this report, to evaluate the interface between the system and the work area and to minimize the impact of the MIOCT unit on efficient and reliable execution of surgical procedures. We fully simulated surgical conditions, enforcing pseudo-sterile conditions, and using a full complement of surgical equipment and instruments with a scrub nurse to assist. We also developed a custom model eye that allowed for visualization and simulation of vitreoretinal manipulations. Based on feedback from an extensive questionnaire directed to surgeons and scrub nurses, important modifications were completed, including aerial mounting of all cables and rounding of the MIOCT unit edges.

Some suggested modifications, however, could not be performed. For example, the additional height added to the microscope by the MIOCT cannot be removed in the current portable prototype design. Mild peripheral clipping of the field of view and the presence of glare with external ocular viewing is a result of the location of the MIOCT unit relative to the built in lights for external field operating. While we subsequently streamlined the installation and removal process of the MIOCT to minimize the impact on turnaround time in the operating room, the additional time required would not be completely eliminated unless the device is fully integrated into the microscope housing.

Overall preclinical feedback for the MIOCT, however, was favorable. Despite the above suggestions, no surgeon or scrub nurse felt overall that the MIOCT unit adversely affected the ability to perform surgery. The MIOCT was designed towards parfocal and coaxial OCT imaging with the surgical view and does not alter the working distance or magnification of the surgical microscope and/or BIOM or contact lens viewing modalities. As a result, MIOCT imaging is acquired without the need to adjust the microscope focus, magnification, or position. All surgeons and scrub nurses felt they would consider participating in human MIOCT imaging trials.

Based on this favorable feedback, MIOCT experienced a smooth transition into the human operating room environment. Imaging of healthy human subjects demonstrated high-resolution imaging of our MIOCT system with full visualization of retinal layers. We designed three stages of intraoperative MIOCT imaging, with predefined endpoints for successfully completing each stage. We present results from the first stage, in which MIOCT imaging was acquired at a preincision time point and then intraoperatively at a pause in surgery following removal of instruments from the eye. Successful completion of this first stage was required before proceeding to the second stage, with instruments held in a static fashion in the vitreous cavity, and the third stage, with imaging obtained during actual surgical maneuvers. We have recently begun our second stage of imaging, whose results will be reported separately.

In this report, we present successful completion of the first stage of imaging. All surgical procedures were successfully performed without complication or adverse events, and in all cases, the surgeon did not feel that the MIOCT unit interfered with surgery. Acceptable



images were obtained in all cases. There was an initial rapid learning curve to familiarize the imaging team with the nuances of human intraoperative imaging, particularly the alignment and coordination required. Horizontal translations of the microscope along with external manipulations of the orientation of the eye were necessary to obtain images through the fovea of adequate resolution and intensity. The need for these manipulations will likely be improved as imaging is acquired with instruments in the eye, including the endoillumination probe, thereby facilitating alignment by direct surgical visualization and simplifying ocular orientation. In this first stage of imaging, due to this learning curve, MIOCT imaging in the first cohort of five patients did not meet satisfactory correlation with HHOCT imaging. In the second cohort of patients, however, 80% correlation was achieved in all patients imaged, achieving our endpoints for this first stage of human imaging. High-resolution images obtained with MIOCT were able to confirm preoperative pathology and identify post-surgical changes in retinal morphology, as we have previously demonstrated with images from HHOCT.<sup>2</sup>

These images highlight potential benefits of intraoperative OCT imaging. Retinal imaging following surgical manipulations can effectively confirm successful completion of surgical goals. For example, edges of peeled ILM can be visualized following repair of a FTMH (Fig. 4), and elimination of vitreous strands, without iatrogenic macular hole formation or increase in retinal thickening, can be seen following surgery for VMT (Fig. 5). Importantly, these images also may provide information about surgical recovery. These images suggest that FTMH closure or resolution of retinal morphology in VMT does not occur immediately, and careful post-operative OCT imaging will likely be helpful in better outlining temporal patterns of recovery. These images also demonstrate surprising intraoperative findings, such as the presence of increased subclinical subretinal fluid following macular hole repair, as recently described.<sup>5</sup> Our current protocol precluded changes in surgical decision making based on intraoperative OCT findings, and further studies will be important to better define the prognostic significance for final visual and/or anatomic outcomes.

The MIOCT imaging protocol described in this report has been identical to that previously described with HHOCT<sup>2</sup>, and future stages of imaging will test the expanded capabilities of MIOCT beyond those of HHOCT. Unlike HHOCT, which requires halting of surgical manipulations to acquire images, the shared optical path of the MIOCT and surgical microscope is designed to enable OCT imaging simultaneous with surgical manipulations. As a result, we predict that MIOCT imaging may prove to be more efficient than HHOCT imaging, although this first in-human study was not designed to assess efficiency, and we did not formally compare acquisition time with individual imaging modalities. Future protocols will be directed at obtaining high-resolution images with instruments in the eye, first to document the instrument in a static position over the retina and then to video-image live manipulations, as we have demonstrated in animal eyes.<sup>13-16</sup> Further modifications to the MIOCT device, including sterile controls, incorporation of tracking options, an integrated display, and ultimately true microscope integration, will be important.

In this report, we present intraoperative images acquired with our MIOCT device in human patients undergoing surgery. These images are comparable to those obtained with HHOCT, but we predict the ability of MIOCT to obtain real-time, high-resolution video imaging, during both vitreoretinal and anterior segment surgical manipulations, in the near future.

## Acknowledgments

**Funding:** Supported by the Heed Ophthalmic Foundation (PH); 1R21 EY019411

Dr. Toth receives research support through equipment loan from Bioptigen Inc and has potential for royalties for OCT-related technology licensed by Duke to Bioptigen Inc. Dr. Toth also receives royalties for surgical technology licensed by Duke to Alcon Laboratories. Duke University has an equity interest in Bioptigen Inc.

Dr. Izatt is a co-founder of Bioptigen Inc and has corporate, intellectual property, and equity interests in this company.

The authors would like to acknowledge the assistance and input of Annette Taylor-Sneed, RN and Gail Harris RN, BA, CNOR along with technical support from Eric Yuan and Tomas Moreno.

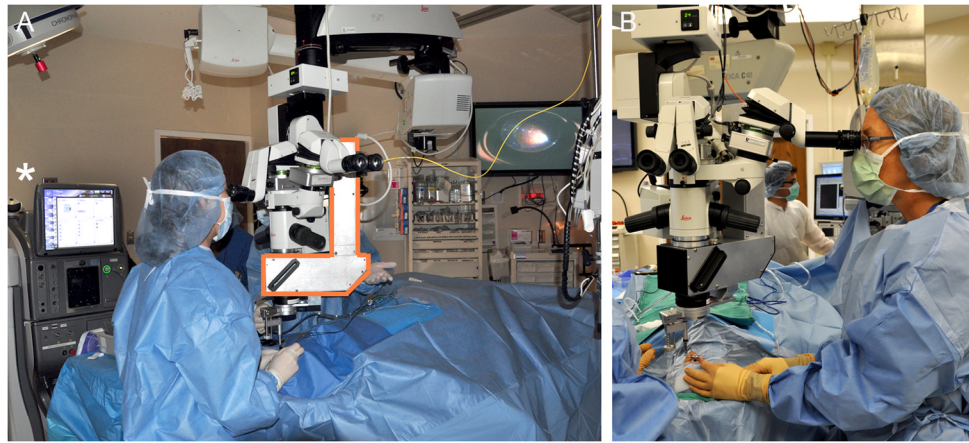
## References

1. Huang D, Swanson EA, Lin CP, et al. Optical coherence tomography. *Science*. Nov 22; 1991 254(5035):1178–1181. [PubMed: 1957169]
2. Dayani PN, Maldonado R, Farsiu S, Toth CA. Intraoperative use of handheld spectral domain optical coherence tomography imaging in macular surgery. *Retina*. Nov-Dec;2009 29(10):1457–1468. [PubMed: 19823107]
3. Baranano DE, Fortun JA, Ray R, et al. Intraoperative Spectral-Domain Optical Coherence Tomography for Macular Pucker Surgery. *ARVO Meeting Abstracts*. Apr 11.2010 51(5):269.
4. Lee LB, Srivastava SK. Intraoperative spectral-domain optical coherence tomography during complex retinal detachment repair. *Ophthalmic Surg Lasers Imaging*. 2011; 42:e71–74. Online. [PubMed: 21830748]
5. Ray R, Baranano DE, Fortun JA, et al. Intraoperative microscope-mounted spectral domain optical coherence tomography for evaluation of retinal anatomy during macular surgery. *Ophthalmology*. Nov; 2011 118(11):2212–2217. [PubMed: 21906815]
6. Wykoff CC, Berrocal AM, Scheffler AC, Uhlhorn SR, Ruggieri M, Hess D. Intraoperative OCT of a full-thickness macular hole before and after internal limiting membrane peeling. *Ophthalmic Surg Lasers Imaging*. Jan-Feb;2010 41(1):7–11. [PubMed: 20128563]
7. Scott AW, Farsiu S, Enyedi LB, Wallace DK, Toth CA. Imaging the infant retina with a hand-held spectral-domain optical coherence tomography device. *Am J Ophthalmol*. Feb; 2009 147(2):364–373. e362. [PubMed: 18848317]
8. Ehlers JP, Kernstine K, Farsiu S, Sarin N, Maldonado R, Toth CA. Analysis of pars plana vitrectomy for optic pit-related maculopathy with intraoperative optical coherence tomography: a possible connection with the vitreous cavity. *Arch Ophthalmol*. Nov; 2011 129(11):1483–1486. [PubMed: 22084218]
9. Hahn P, Migacz J, O'Connell R, Maldonado R, Izatt JA, Toth CA. The use of optical coherence tomography in intraoperative ophthalmic imaging. *Ophthalmic Surg Lasers Imaging*. 2011; 42(4 Suppl):S85–S94. [PubMed: 21790116]
10. Han S, Sarunic MV, Wu J, Humayun M, Yang C. Handheld forward-imaging needle endoscope for ophthalmic optical coherence tomography inspection. *J Biomed Opt*. Mar-Apr;2008 13(2):020505. [PubMed: 18465947]
11. Balicki M, Han JH, Iordachita I, et al. Single fiber optical coherence tomography microsurgical instruments for computer and robot-assisted retinal surgery. *Med Image Comput Comput Assist Interv*. 2009; 12(Pt 1):108–115. [PubMed: 20425977]
12. Binder S, Falkner-Radler CI, Hauger C, Phd HM, Glittenberg C. Feasibility of Intrasurgical Spectral-Domain Optical Coherence Tomography. *Retina*. Jan 26.2011
13. Tao YK, Ehlers JP, Toth CA, Izatt JA. Intraoperative spectral domain optical coherence tomography for vitreoretinal surgery. *Opt Lett*. Oct 15; 2010 35(20):3315–3317. [PubMed: 20967051]
14. Ehlers JP, Tao YK, Farsiu S, Maldonado R, Izatt JA, Toth CA. Integration of a spectral domain optical coherence tomography system into a surgical microscope for intraoperative imaging. *Invest Ophthalmol Vis Sci*. May; 2011 52(6):3153–3159. [PubMed: 21282565]
15. Tao YK, Ehlers JP, Toth CA, Izatt JA. Visualization of vitreoretinal surgical manipulations using intraoperative spectral domain optical coherence tomography. *Proc SPIE*. 2011; 7889:78890F.

16. Hahn P, Migacz J, O'Connell R, Izatt JA, Toth CA. Unprocessed real-time imaging of vitreoretinal surgical maneuvers using a microscope-integrated spectral-domain optical coherence tomography system. *Graefes Arch Clin Exp Ophthalmol*. May 16.2012

### Summary Statement

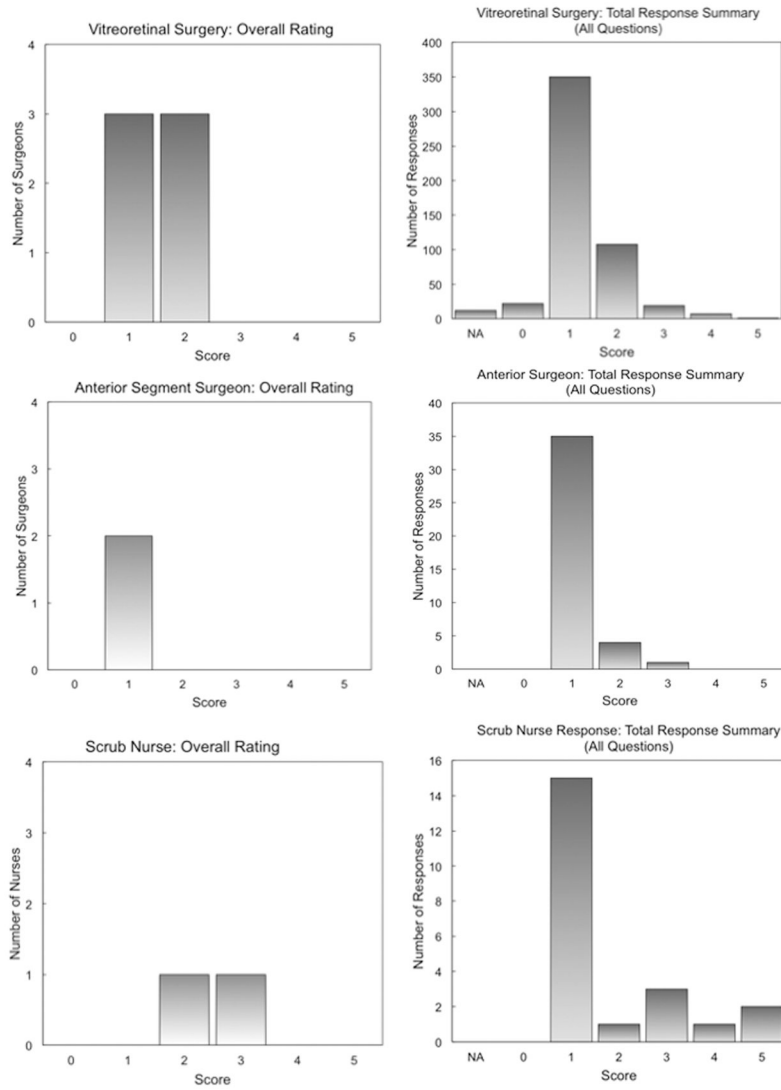
This report describes the translation of a prototype microscope-integrated spectral domain OCT (MIOCT) system from preclinical evaluation to retinal imaging of human patients in the operating room during surgery. Future MIOCT imaging will focus on intrasurgical real-time imaging of intraocular surgical manipulations.



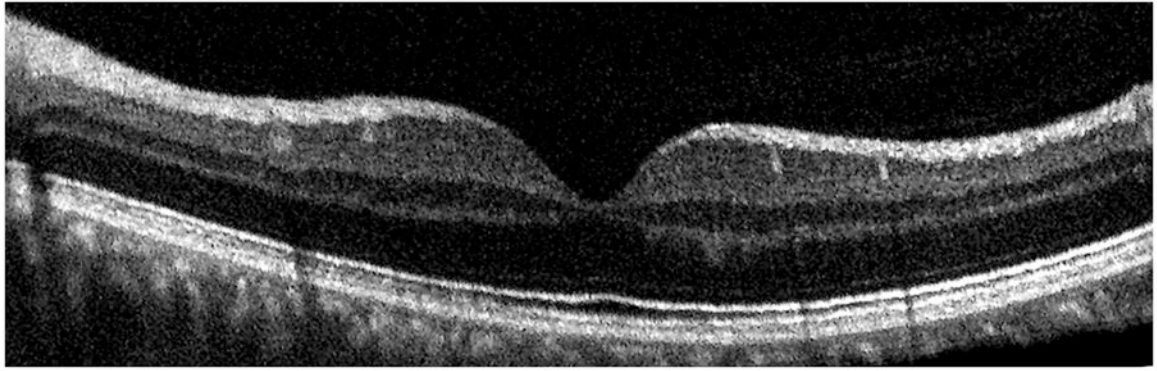
**Figure 1.**

**A)** Under fully simulated surgical conditions, a vitreoretinal surgeon is performing surgical tasks with the Alcon Constellation Vision system (\*, left) and the assistance of a scrub nurse whose hand is visible to the right of the microscope. The surgeon is performing vitreoretinal manipulations under the MIOCT (orange outline) mounted to the Leica surgical microscope with visualization through the BIOM wide-angle viewing system. The aerially-coursing yellow cables connect the MIOCT to a computer workstation (not visible) at the foot of the bed. A display monitor (right) mounted on the wall provides the surgeon's view of the model retina. **B)** Human intraoperative MIOCT retinal imaging of a live patient undergoing surgery was performed under similar conditions. The surgeon is adjusting the lower BIOM objective lens with her finger to optimize MIOCT image quality. An assistant is operating the computer workstation at the foot of the surgical bed.

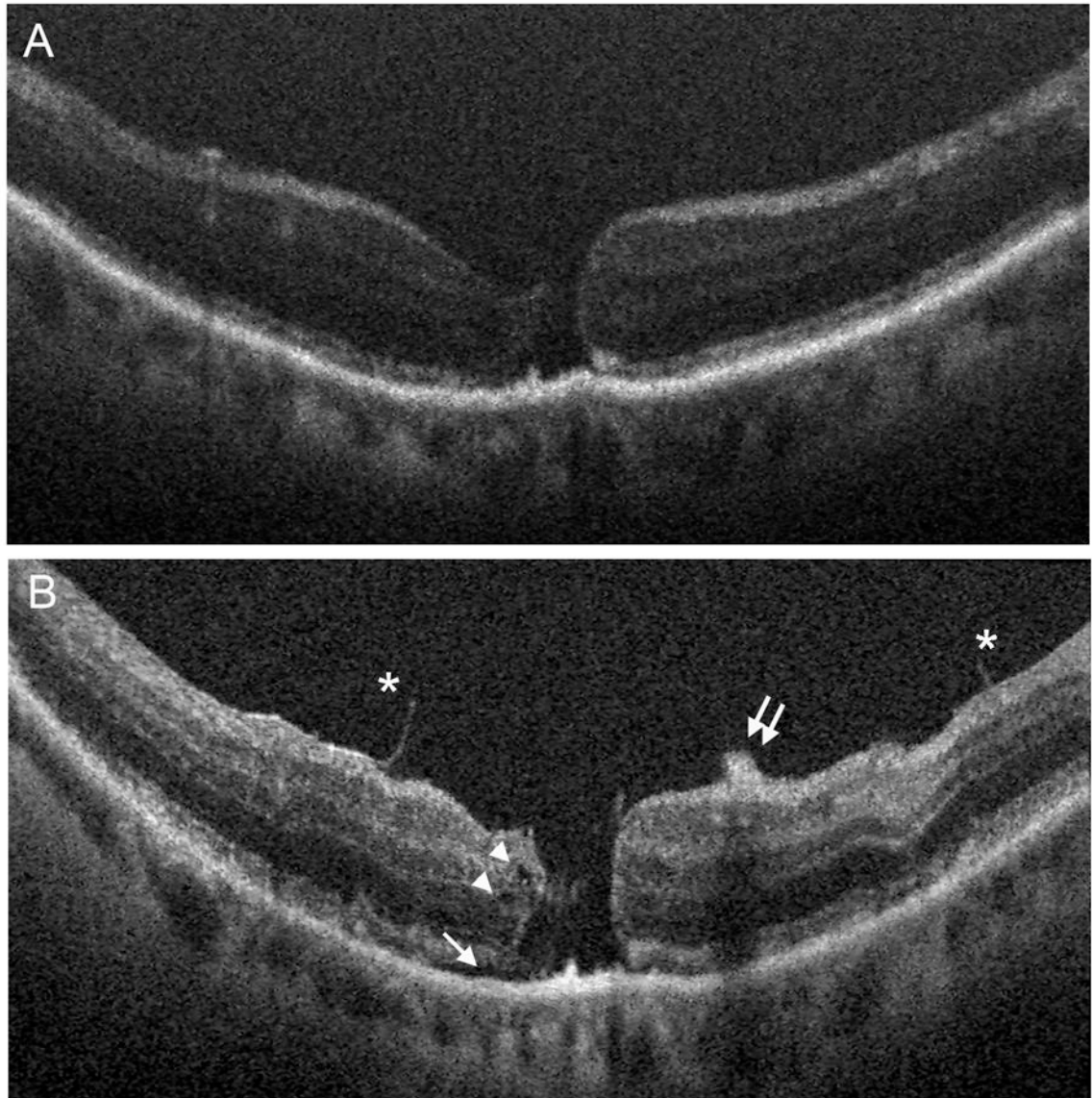




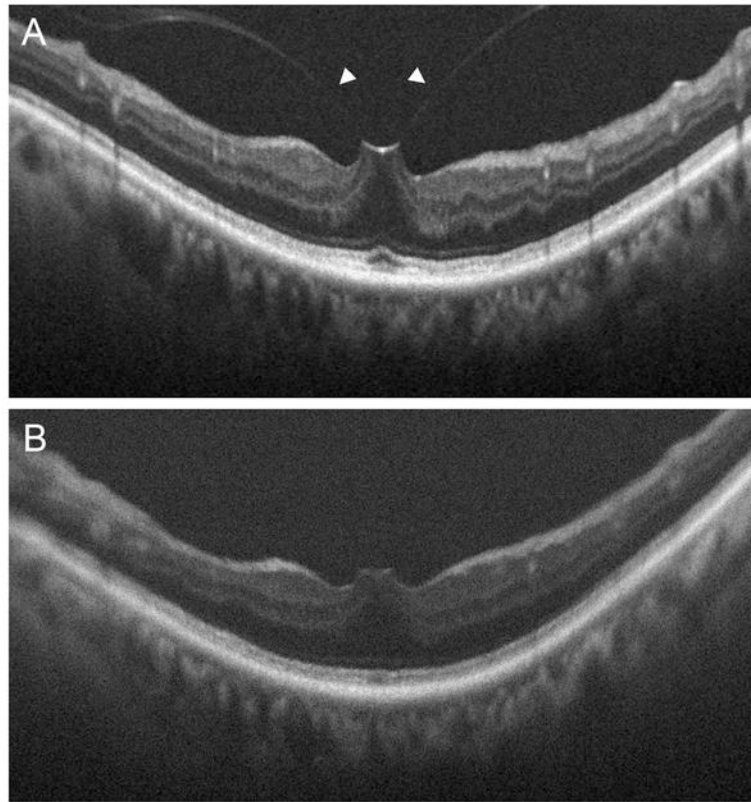
**Figure 2.** Graphs representing feedback based on evaluation of MIOCT during simulated surgical conditions. Overall rating and a distribution summary of total responses are presented based on responses by vitreoretinal surgeons (top row), anterior segment surgeons (middle row), and scrub nurses (bottom row). 0 = “An improvement”; 1 = “No impact”; 2 = “Noticeable difference, but would not adversely affect surgery”; 3 = “Noticeable difference, but may be able to work around it”; 4 = “Noticeable difference, and difficult to work around it”; 5 = “Unacceptable. Must be revised/fixed prior to human OR use.”



**Figure 3.** MIOCT image acquired in a healthy human volunteer demonstrates resolution of individual retinal layers. Multiple outer retinal bands can be resolved, corresponding to the external limiting membrane (ELM), inner segment-outer segment junction (IS-OS), retinal pigment epithelium-outer segment junction (RPE-OS), and retinal pigment epithelium (RPE).



**Figure 4.** MIOCT images acquired in a human patient undergoing vitreoretinal surgery for repair of a full-thickness macular hole. Preincision images (A) confirm the preoperative diagnosis. Intraoperative images following membrane peel (B) suggest a more relaxed retinal morphology based on a corrugated retinal appearance, demonstrate the edges of the peeled internal limiting membrane (asterisks), and reveal an iatrogenic intraretinal hemorrhage (double arrow), small intraretinal cystoid spaces (arrowheads), and mild subretinal fluid (arrow).



**Figure 5.** MIOCT images acquired in a human patient undergoing vitreoretinal surgery for relief of vitreomacular traction. Preincision images (**A**) confirm the preoperative diagnosis with visible vitreous adhesions (arrowheads) to the fovea. Intraoperative images (**B**) following hyaloid membrane peel demonstrate removal of the vitreous adhesions, and the decreased retinal elevation suggests relief of foveal traction.

Table 1

Surgical cases and intraoperative MIOCT imaging results

Case	Preoperative pathology	Surgical procedure	Surgery uncomplicated?	Acceptable imaging?*	% correlation MIOCT-to-HHOCT**
1	ERM	25G PPV/MP (ICG)	Yes	Yes	100
2	ERM	25G PPV/MP (ICG)	Yes	Yes	0
3	NVAMD	20G MT360	Yes	Yes	60
4	FTMH	25G PPV/MP (ICG)	Yes	Yes	60
5	FTMH/ERM	25G PPV/MP (ICG)	Yes	Yes	0
6	ERM	25G PPV/MP (ICG)	Yes	Yes	80
7	VMT	25G PPV/MP (ICG)	Yes	Yes	80
8	Optic pit with schisis	25G PPV/MP (ICG)	Yes	Yes	80
9	FTMH	25G PPV/MP (ICG)	Yes	Yes	100
10	FTMH	25G PPV/MP (ICG)	Yes	Yes	100

\* defined as ability to visualize inner retinal surface and RPE interface in at least one MIOCT image.

\*\* defined as number of identifiable elements, (1) macular hole, 2) epiretinal membrane, 3) retinal edema, schisis or cystoid structures, 4) subretinal fluid or retinal detachment, and 5) central retinal thickness from inner retina to RPE, in MIOCT compared to HHOCT images.