

# CASE REPORT

## Pulmonary tumor thrombotic microangiopathy from metastatic epithelioid angiosarcoma

Funda Demirag<sup>1</sup>, Ebru Cakir<sup>1</sup>, Ulku Yazıcı<sup>2</sup>, Irfan Tastepe<sup>2</sup>

<sup>1</sup>Atatürk Chest Diseases and Chest Surgery Education and Research Hospital, Department of Pathology, Ankara, Turkey; <sup>2</sup>Atatürk Chest Diseases and Chest Surgery Education and Research Hospital, Department of Chest Surgery, Ankara, Turkey

### ABSTRACT

The lung is most common site for metastatic disease via hematogenous route. Tumor emboli of the vessels of the lung induces fibrocellular and fibromuscular intimal proliferation. These histopathological changes may cause pulmonary tumor thrombotic microangiopathy. Few cases are diagnosed antemortem. We report a 60 year old woman with by metastatic epithelioid angiosarcoma involving the lung. Tumor cells were positive for VEGF and topoisomerase II. VEGF may be involved in the pathogenesis pulmonary tumor thrombotic microangiopathy and topoisomerase II positivity showed sensitivity against catalytic topoisomerase II inhibitors.

### KEY WORDS

Pulmonary tumor thrombotic microangiopathy; Angiosarcoma; Vascular endothelial growth factor; Topoisomerase II

*J Thorac Dis 2013;5(3):E107-E111. doi: 10.3978/j.issn.2072-1439.2012.10.08*

### Introduction

The lungs are frequently the site of metastatic tumors because of vast capillary network and position in the circulation. Secondary tumors of the lung may present form of discrete nodules, diffuse lymphatic permeation, diffuse consolidation, endobronchial growth or massive tumor embolism (1). Pulmonary tumor embolism (PTE) is not an uncommon cause of respiratory failure in patients with cancer. It is observed in up to 26% all cancer autopsies (2). Tumor cell emboli may not only occlude the vessels but also activate both local and systemic coagulation system, leading to thrombosis, fibrocellular and fibromuscular intimal proliferation, luminal stenosis and finally occlusion. These caused pulmonary tumor thrombotic microangiopathy (PTTM) with malign tumors patients (3). Few cases are diagnosed antemortem. PTTM and PTE may cause dyspne, pulmonary hypertension, and right-side heart failure. The most common neoplasm associated with PTTM is adenocarcinoma and the most frequent primary site is the stomach (4). We described the case of a patient with PTE and PTTM due to

metastatic epithelioid angiosarcoma, not previously reported with this association. The pathogenesis of this rare metastatic pattern was discussed.

### Case report

A 60 year old woman was admitted with two month history dyspne, haemoptysis, weight lost, nausea and night sweats. A chest X-ray demonstrated bilateral nodular shadows (Figure 1). A computed tomographic scan showed a solid mass, 6.5 cm in diameter in right lower lobe and ill defined parenchymal nodules in both lungs (Figure 2). PET scan from vertex to knee was performed 1.5 hours after intravenous injection of F-18 labelled flurodeoxyglucose (FDG). PET scan showed hypermetabolic lesion in the bilaterally hiler lymphadenopathy (SUVmax: 8.0) and in the liver (SUVmax: 3.6). Multifocal abnormal FDG uptake were observed in bilaterally lung nodules and 6 cm diameter mass in the right lower lobe (SUVmax: 4.6) (Figure 3). In right ramus mandibula, left frontal bone, head of left humerus, C2T8 corpus vertabrae, T9 cervical transvers proces, T10 right transvers and spinous proces and corpus vertebrae, T10-12, I1-S vertebra, sacrum, bilaterally ischium, symphysis were observed hypermetabolic (SUVmax: 14.5) with PET scan (Figure4).

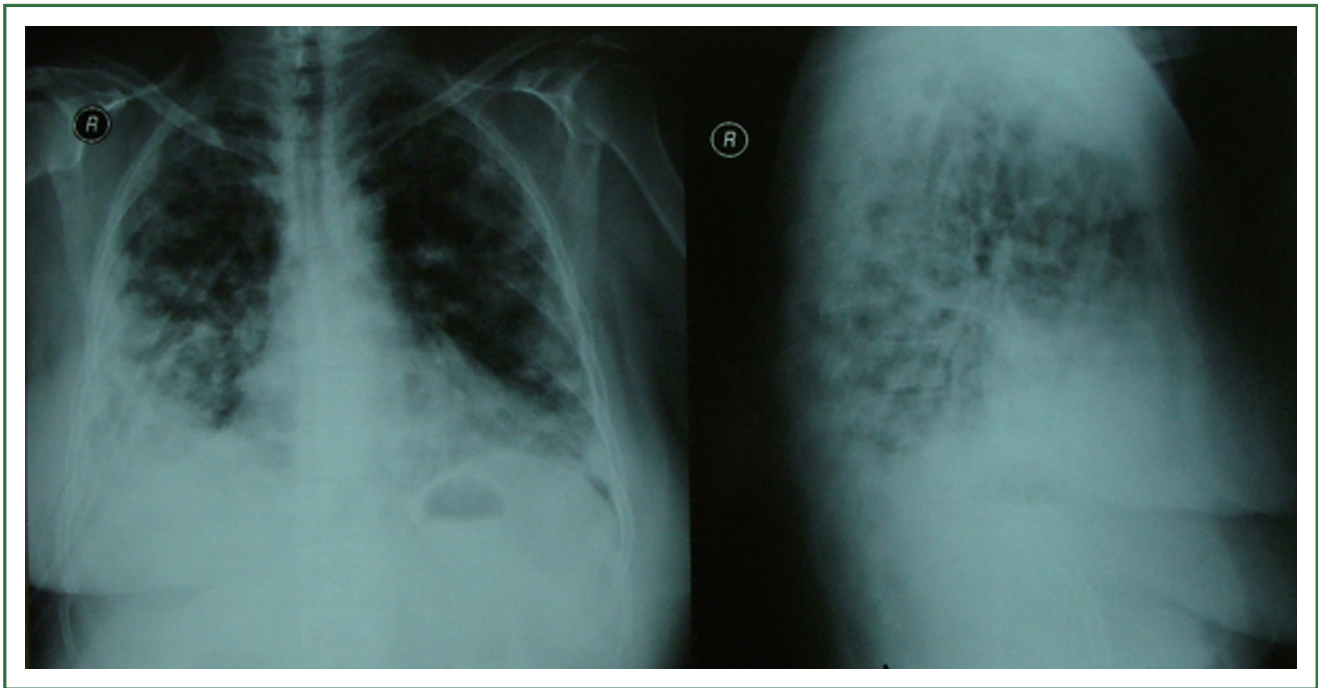
Bronchoscopy was performed. Endobronchial lesion was not observed. Patient was not accepted transthoracic byopsi. Hypermetabolic lesions in PET suggested metastatic malignancy. Cranium BT and abdominal USG, bilateral breast and thyroid USG were normal. Meedle lobe wedge resection and 5. rib exicion were performed with right thoracotomy.

Corresponding to: Funda Demirag, MD. Atatürk Chest Diseases and Chest Surgery Education and Research Hospital, Department of Pathology, Ankara, Turkey. Email: fundademirag@yahoo.com.tr.

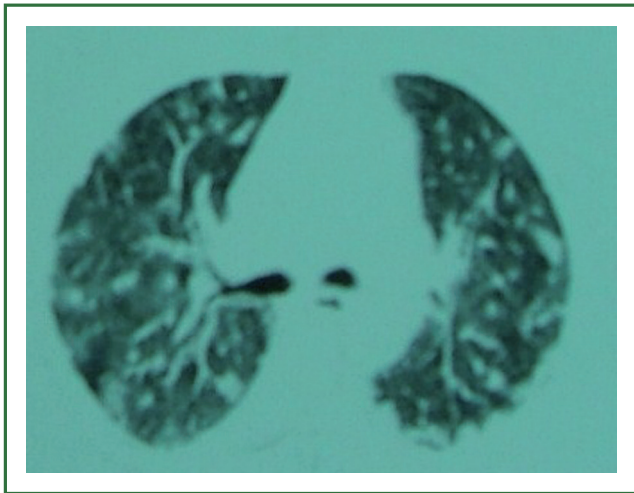
Submitted Aug 13, 2012. Accepted for publication Oct 10, 2012.  
Available at www.jthoracdis.com

ISSN: 2072-1439

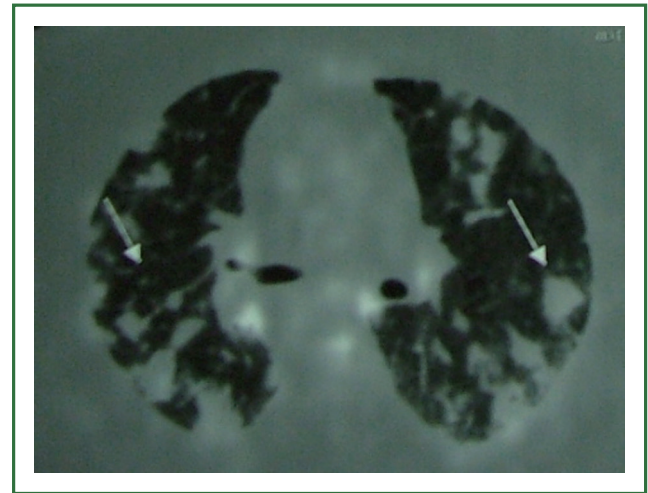
© Pioneer Bioscience Publishing Company. All rights reserved.



**Figure 1.** A chest X-ray revealed bilateral nodules.



**Figure 2.** Chest computed tomography showed thickened interlobular septa and vascular structure.

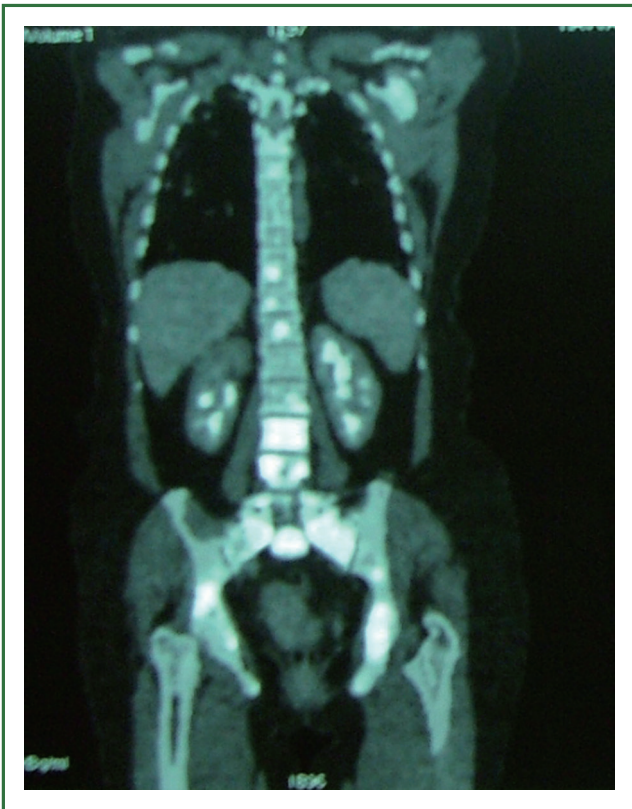

**Figure 3.** Fluorine-18 fluorodeoxyglucose positron emission tomography showed increased glucose metabolism of multiple lung nodules and pathologic mediastinal lymph nodes.

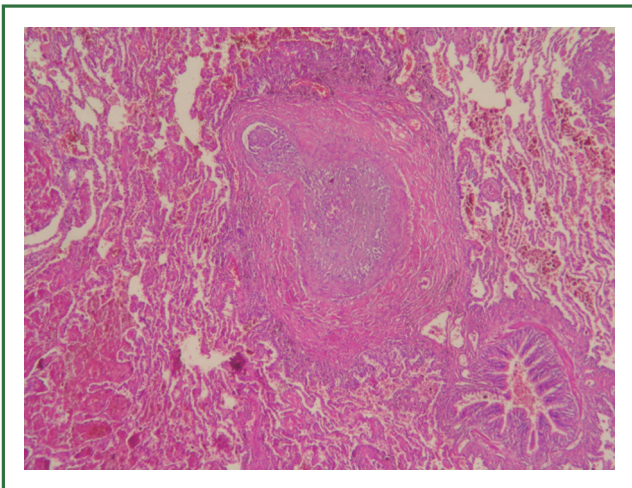
On the macroscopic examination diffuse haemorrhage and ill defined two nodules were observed. Nodules were constituted from ischemic necrosis. Around necrosis showed extensive haemorrhage and malignant neoplasm. Exhibiting distinctive patterns of neoplasm were intraarterial (embolic), lymphatic, interstitial spread, focal neoplastic arteriopathy and tumoral pneumonia (Figures 5,6,7). Tumor cells were mildly pleomorphic, medium to large with pale eosinophilic and large vesicular nuclei with distinct nucleoli. They arranged loosely

solid, scattered mitosis. Tumoral pneumonia composed of intraalveolar accumulation of the tumor cells admixed with fibrin and focal organisation of the fibrinous neoplastic exudate.

Cytoplasmic features and vasotropic pattern was considered poorly differentiated carcinoma and melanoma. Intravascular B cell lymphoma and sarcoma with epithelioid features (rhabdomyosarcoma, angiosarcoma and synovial sarcoma) were on our list of possible primary malignancies. A panel of immunohistochemical stains were performed, including CD45,

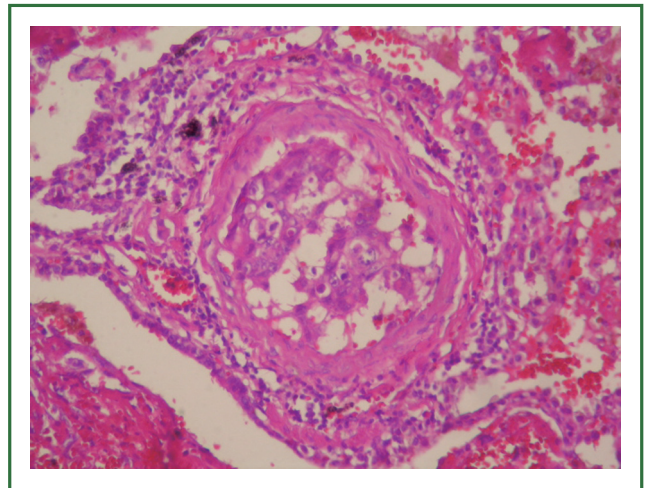


**Figure 4.** Fluorine-18 fluorodeoxyglucose positron emission tomography showing increased glucose metabolism of the spine.

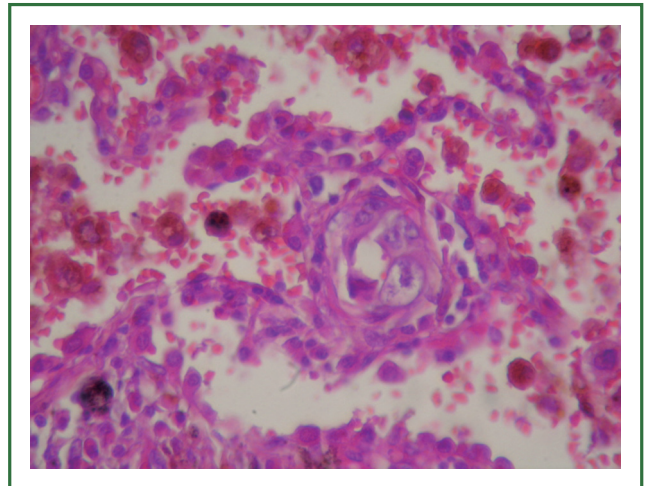


**Figure 5.** Tumor emboli showing admixed fibrin thrombi and tumor cells (HE ×400).

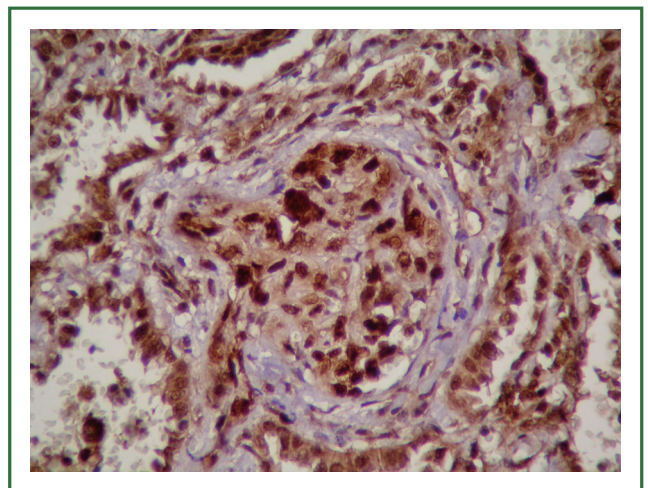
CD31, CD34, TTF-1, CEA, pancytokeratin, Keratin20, bcl-2, actin, s-100, VEGF, Ki67 and topoisomeraseII $\alpha$  (Figure 8). CD31 and VEGF were positive. Ki67 proliferation index is high (>%90). CD45, CD34, TTF-1, CEA, pancytokeratin, Keratin20, bcl-2, actin, s100 were negative. Topoisomerase II alpha was



**Figure 6.** Intimal fibrocellular proliferation with tumor cells, causing marked luminal stenosis (HE×100).



**Figure 7.** Interstitial infiltration (HE ×400).



**Figure 8.** Angiosarcoma cells showed positive reactivity for topoisomerase II $\alpha$  (topoisomeraseII $\alpha$  ×400).

**Table 1.** Rare causes of pulmonary thrombotic microangiopathy.

Type of tumor	Number of cases	The time of diagnosis	References
Low grade ovarian serous carcinoma	2	postmortem	(10)
Ovarian clear cell carcinoma	1	postmortem	(4)
Desmoplastic small round cell tumor	1	postmortem	(11)
Esophageal squamous cell carcinoma	1	Antemortem thranbronchial lung biopsy	(9)
Cervix carcinoma	1	Antemortem thranbronchial lung biopsy	(12)
Salivary duct carcinoma ex pleomorphic adenoma	1	postmortem	(13)
Gallbladder carcinoma	1	postmortem	(14)
Lung adenocarcinoma	5	2-antemortem 3- postmortem	(15)
Epithelioid angiosarcoma	1	Antemortem Wedge resection	Current case

intracellular positive. 5.rib contained microscopic tumor focus. We reported with these finding as metastatic epithelioid angiosarcoma. Patient was not accepted therapy. She died later 5 week.

## Discussion

The epithelioid form of angiosarcoma has been fully characterized only in the past decade. The tumor cells are typically large, amphophilic and have a large vesicular nucleus with a prominent nucleolus. It may contain intracytoplasmic lumen and erythrocytes. Mitosis, necrosis and hemorrhage are frequent. These features mimic malignant melanoma and carcinoma (5).

CD31 is most sensitive marker for angiosarcoma. Epithelioid angiosarcoma may be positive cytokeratin (6). But cytokeratin was negative in our case. In view of histopathologic appearance, immunohistochemical phenotype, the metastatic tumor in our case is consistent with epithelioid angiosarcoma.

Pulmonary angiosarcomas are usually metastatic malignancies. There are only 20 primary pulmonary angiosarcomas in English literature (7). Heart is one of the most common primary sites for lung metastasis in noncutaneous angiosarcomas (6). There was no evidence of primary cardiac tumour as cardiomegaly, tachycardia, low blood pressure, reduced intensity of the heart tones in our case. Clinical features of our case was most consistent with metastatic disease. Hypermetabolic areas in bone appeared to be most possible source of metastatic disease. In literature one case with epithelioid angiosarcoma involving the lungs, soft tissue masses in the leg is possible primary foccus (8).

PTTM is a rare complication due to tumor dissemination. The tumor thrombi within small arteries and arterioles and associated fibrocellular and fibromuscular intimal proliferation

are histological features of PTTM. The most common tumor associated with PTTM is gastric adenocarcinomas. Nongastric tumors are very rare. Esophageal squamous cell carcinoma, ovarian tumors, desmoplastic small cell tumor, salivary duct carcinoma ex pleomorphic adenoma and pulmonary adenocarcinoma with PTTM were reported in literature (9-15). We have summarized their features nongastric tumors with PTTM in Table 1.

Very few cases in the literature have been diagnosed antemortem (9,12). The conventional radiologic findings are often minimal or nonspecific. Franquet *et al.* reported tree-in-bud pattern on high resolution CT of a patient with PTTM (16). But we didn't detect tree-in-bud pattern in our case. PET/CT imaging with F-18 FDG helped for detection in metastatic angiosarcoma (17-19). SUV max were 4,6 and 8.0 in the bilaterally pulmonary and hiler lymphadenopathy, respectively in our case. Our findings supported that FDG-PET can help the diagnosis of PTTM as the intensity FDG accumulation. But in our case metastatic tumor in 5. rib was not hypermetabolic in PET/CT. Because the resolution of a PET/CT system is about 5-7 mm.

The nuclear enzyme DNA topoisomerase II $\alpha$  is a major target for antineoplastic agents used in the treatment of breast, lung, and prostate cancer, sarcomas and hematological malignancies (10,20). Topoisomerase II $\alpha$  positivity in our case showed sensitivity against catalytic topoisomerase II $\alpha$  inhibitors.

Molecular mechanisms of PTTM is unclear, but some studies have suggested that tissue factor, osteopontin and vascular endothelial growth factor (VEGF) expressed by tumor cells (4,21). In addition to activated alveolar macrophages in the PTTM lesion has a critical role in te onset and progression of PTTM via expression of Platelet-Derived Growth Factor (22). Immunohistochemical expression of VEGF and their receptors in angiosarcomas were showed by Itakura *et al.* (23). We

observed VEGF positivity in our case. This finding supported that VEGF may be involved in the pathogenesis of PTTM and new therapeutic approaches including anti-angiogenic agents.

In conclusion, epithelioid appearance sarcomas as epithelioid angiosarcoma may cause pulmonary tumor thrombotic microangiopathy. PET may not detect microscopic epithelioid angiosarcoma. Topoisomerase II $\alpha$  and VEGF positivity showed sensitivity against catalytic topoisomerase II $\alpha$  inhibitors and antiangiogenic agents.

### Acknowledgements

*Disclosure:* The authors declare no conflict of interest.

### References

- Corrin B, Nicholson AG. Pathology of the Lungs, pp682, third ed, Elsevier, China, 2011.
- Chatkin JM, Fritscher LG, Fiterman J, et al. Microscopic pulmonary neoplastic emboli: report of a case with respiratory failure but normal imaging. *Primary Care Respiratory Journal* 2007;16:115-7.
- Yao DX, Flieder DB, Hoda SA. Pulmonary tumor thrombotic microangiopathy. An often missed antemortem diagnosis. *Arch Pathol Lab Med* 2001;125:304-5.
- Chinen K, Fujino T, Horita A, et al. Pulmonary tumor thrombotic microangiopathy caused by an ovarian cancer expressing tissue factor and vascular endothelial growth factor. *Pathol Res Pract* 2009;205:63-8.
- Fletcher CD, Beham A, Bekir S, et al. Epithelioid angiosarcoma of deep soft tissue: a distinctive tumor readily mistaken for an epithelial neoplasm. *Am J Surg Pathol* 1991;15:915-24.
- Bocklage T, Leslie K, Yousem S, et al. Extracutaneous angiosarcomas metastatic to the lungs: Clinical and pathologic features of twenty-one cases. *Mod Pathol* 2001;14:1216-25.
- Yang CF, Chen TW, Tseng GC, et al. Primary pulmonary epithelioid angiosarcoma presenting as a solitary pulmonary nodule on image. *Pathology International* 2012;62:424-8.
- Lund L, Amre R. Epithelioid angiosarcoma involving the lungs. *Arch Pathol Lab Med* 2005;129:e7-10.
- Ueda A, Fuse N, Fujii S, et al. Pulmonary tumor thrombotic microangiopathy associated with esophageal squamous cell carcinoma. *Inter Med* 2011;50:2807-10.
- Gru AA, Pai RK, Roma AA. Pulmonary tumor thrombotic microangiopathy in patients with low grade ovarian serous neoplasm: a clinicopathologic review of 2 cases a previously unknown association. *Int J Gynecol Pathol* 2012;31:438-42.
- Sadimin ET, Collier AG, Gaffney JW, et al. Pulmonary tumor thrombotic microangiopathy with cor pulmonale due to desmoplastic small round cell tumor. *J Pediatr* 2012;160:697-9.
- Sekiyama T, Mizamura K, Kobayashi T, et al. A pulmonary tumor embolism which mimicked pulmonary tumor thrombotic microangiopathy caused by cervical cancer. *Nihon Kokyuki Gakkai Zasshi* 2010;48:595-9.
- Uruga H, Fujii T, Kurosaki A, et al. A case of pulmonary tumor thrombotic caused by carcinoma (salivary duct carcinoma) ex pleomorphic adenoma. *Nihon Kokyuki Gakkai Zasshi* 2010;48:463-8.
- Malani AK, Gupta C, Kuttu AV, et al. Pulmonary tumor thrombotic microangiopathy from metastatic gallbladder carcinoma: an unusual cause of severe pulmonary hypertension. *Dig Dis Sci* 2007;52:555-7.
- Hotta M, Ishida M, Kojima F, et al. Pulmonary tumor thrombotic caused by lung adenocarcinoma: case report and with review of the literature. *Oncol Lett* 2011;2:435-7.
- Franquet T, Giménez A, Prats R, et al. Thrombotic microangiopathy of pulmonary tumors: A vascular cause of tree-in-bud pattern on CT. *AJR Am J Roentgenol* 2002;179:897-9.
- Vasanawala MS, Wang Y, Quon A, et al. F-18 fluorodeoxyglucose PET/CT as an imaging tool for staging and restaging cutaneous angiosarcoma of the scalp. *Clin Nucl Med* 2006;31:534-7.
- Cicone F, Del Forno M, Papa A, et al. Fatal pulmonary tumour thrombotic microangiopathy: Do typical FDG-PET findings exist? *Nuklearmedizin* 2012;51:N6-9.
- Tashima Y, Abe K, Matsuo Y, et al. Pulmonary tumor thrombotic microangiopathy: PET/CT findings. *Clin Nucl Med* 2009;34:175-7.
- Larsen AK, Escargueil AE, Skladanowski A. Catalytic topoisomerase II inhibitors in cancer therapy. *Pharmacology&Therapeutics* 2003;99:167-81.
- Okubo Y, Nakayama M, Kitahara K, et al. Pulmonary tumor thrombotic microangiopathy induced by gastric carcinoma: Morphometric and immunohistochemical analysis of six autopsy cases. *Diagnostic Pathology* 2011;6:27.
- Yokomine T, Hirakawa H, Ozawa E, et al. Pulmonary thrombotic microangiopathy caused by gastric carcinoma. *J Clin Pathol* 2010;63:367-9.
- Itakura E, Yamamoto H, Oda Y, et al. Detection and characterization of Vascular Endothelial Growth Factors and their receptors in a series of angiosarcomas. *J Surg Oncol* 2008;97:74-81.



Cite this article as: Demirag F, Cakir E, Yazıcı U, Tastepe I. Pulmonary tumor thrombotic microangiopathy from metastatic epithelioid angiosarcoma. *J Thorac Dis* 2013;5(3):E107-E111. doi: 10.3978/j.issn.2072-1439.2012.10.08