

# Role of Complement and Polymorphonuclear Cells in Demethylchlortetracycline-induced Phototoxicity in Guinea Pigs

## INHIBITION BY DECOMPLEMENTATION IN VIVO

HENRY W. LIM, HOWARD NOVOTNY, and IRMA GIGLI, *Division of Dermatology, University of California, San Diego, California 92103; Department of Dermatology and the Irvington House, New York University Medical Center, New York 10016*

**ABSTRACT** In this study, demethylchlortetracycline was used as a prototype of exogenous phototoxic substances. In vitro, exposure of serum containing demethylchlortetracycline to ultraviolet-A irradiation resulted in the diminution of total complement hemolytic activity and C4, C2, C3, and C5 activities. In addition, chemotactic activity for human polymorphonuclear cells was generated, which was thermostable and antigenically related to human C5 but not human C3. In vivo, phototoxic lesions were induced in guinea pigs upon intradermal injections of demethylchlortetracycline solution, followed by ultraviolet-A irradiation. On a scale of 0-3+, the animals developed a maximal response of 2.5 at 20 h. This clinical response was associated with cellular infiltrate in the dermis, consisting of  $29 \pm 2\%$  of neutrophils at 24 h. The participation of the polymorphonuclear cells was evaluated in guinea pigs rendered neutropenic by treatment with cyclophosphamide. In these guinea pigs, demethylchlortetracycline and ultraviolet-A induced a maximal response of  $0.75 \pm 0.6$ , which was associated histologically with  $1.2 \pm 0.5\%$  neutrophils in the dermis. The role of complement in this process was studied in guinea pigs congenitally deficient in C4, and

in guinea pigs de complemented by treatment with cobra venom factor. In contrast to normal guinea pigs, C4-deficient animals exhibited a maximal reaction of  $0.83 \pm 0.16$  at 6 h, which subsided within 24 h. Cobra venom factor-treated guinea pigs developed a maximal response of 0.5 at 0.5 and at 6 h. These clinical changes were associated with the development of an increased vascular permeability, as demonstrated by studies using guinea pigs injected intravenously with Evans blue solution. In animals with a normal complement system, there was intense localized bluing at the sites of phototoxic lesion. In contrast, only minimal bluing was observed in de complemented guinea pigs. These data indicate that a normal number of polymorphonuclear cells and an intact complement system are required for the full development of demethylchlortetracycline-induced phototoxic lesions.

## INTRODUCTION

In previous studies (1, 2), we have demonstrated that irradiation of normal human serum containing exogenously added uroporphyrin or protoporphyrin with light of 400-410 nm wavelengths resulted in activation of the complement system and the generation of chemotactic activity for human polymorphonuclear leukocytes (PMN). Similar observations were noted when sera from patients with erythropoietic protoporphyria or porphyria cutanea tarda were irradiated in vitro (3). Furthermore, in vivo activation of the complement system was noted after irradiation of the forearms of these patients (4). These observations suggest that complement activation may participate in the development of phototoxic lesions; indirect evidence reported

---

This work was presented, in part, at the Annual Meeting of the American Association of Physicians, Washington DC, 1982, and published in abstract form: 1982. *Clin. Res.* 20:552a. (Abstr.)

Address reprint requests to Dr. Lim, Division of Dermatology, University of California Medical Center, San Diego, CA 92103.

Received for publication 19 August 1982 and in revised form 7 June 1983.

by others also support this concept. Deposition of C3 and immunoglobulins around blood vessels and at the dermal-epidermal junction had been observed in light-exposed skin of patients with various types of porphyria (5). Histologically, exposure of nonlesional skin of patients with erythropoietic protoporphyria to long-wave ultraviolet light resulted in lysis of capillary endothelial cells, mast cell degranulation, and the appearance of PMN in the dermis (6). In animals, administration of an exogenous phototoxic substance, such as chlorpromazine, followed by ultraviolet irradiation, resulted in dermal edema, vasodilation, and PMN infiltrate (7). Similar changes were observed both in guinea pigs that received protoporphyrin intraperitoneally (2) and in mice rendered protoporphyric by griseofulvin administration (8). These histologic changes are consistent with those mediated by products of complement activation.

To evaluate whether our previous observation of photoactivation of the complement system by uroporphyrin or protoporphyrin could also occur with other phototoxic substances, studies were performed using demethylchlortetracycline (DMCT),<sup>1</sup> an exogenous phototoxic agent. In the following experiments, we investigated the effect of DMCT and ultraviolet irradiation on the complement system of human serum. Furthermore, the participation of the complement system and PMN in the development of phototoxic lesions induced by DMCT and ultraviolet light was studied.

## METHODS

**Light source.** Four General Electric F40BL tubes (General Electric Co., Medical Systems Div., Milwaukee, WI) were used as the source of ultraviolet-A (UVA) (320–400 nm) light. Photons emitted over a wavelength range of 320–450 nm represent 94% of the total energy output of the lamps. With an IL 700 research radiometer (International Light, Inc., Newburyport, MA) and a 3-mm window-glass as a filter, the output of the lamps at 15 cm was as follows: 275–303 nm, 2.13  $\mu\text{W}/\text{cm}^2$  (SEE 240 sensor, UVB 63 filter, International Light, Inc.); 308–318 nm, 13.4  $\mu\text{W}/\text{cm}^2$  (PT 171C sensor, NB 313 filter); 330–390 nm, 1, 310  $\mu\text{W}/\text{cm}^2$  (PT171C sensor; WB 365 filter); and 400–410 nm, 200  $\mu\text{W}/\text{cm}^2$  (PT171 C sensor; NB 405 filter). The ultraviolet-B (UVB) (270–320 nm) light source was a barrel of four Westinghouse FS40 tubes (Westinghouse Electric Corp., Bloomfield, NJ), which emit photons over the wavelength range of 275–375 nm. The output of the lamps at 15 cm was as follows: 275–303 nm, 307  $\mu\text{W}/\text{cm}^2$  (SEE 240 sensor, UVB 63 filter); 308–318 nm, 495  $\mu\text{W}/\text{cm}^2$  (PT171C sensor, NB 313 filter); 330–390 nm, 680  $\mu\text{W}/\text{cm}^2$  (PT171C sensor, WB 365 filter); and 400–410 nm, 44  $\mu\text{W}/\text{cm}^2$  (PT171C sensor, NB 405 filter).

<sup>1</sup> *Abbreviations used in this paper:* CH50, total complement hemolytic activity; DMCT, demethylchlortetracycline; EA, erythrocytes coated with antibody; GVB, veronal-buffered saline with 0.1% gelatin; UVA, ultraviolet-A; UVB, ultraviolet-B.

**In vitro irradiation of serum.** Pure DMCT powder (Led-erle Laboratories, Pearl River, NY) was dissolved in phosphate-buffered saline (PBS), pH 7.4, at a concentration of 1.0 mg/ml. 0.1 ml of this stock solution, or serial dilutions from it, was then added to 0.9 ml of normal human serum to yield the final desired concentrations. The ratio of DMCT/serum of 1:9 was used for all the in vitro experiments, unless it is specifically stated otherwise. To eliminate the effect of ambient ultraviolet irradiation, all procedures involving DMCT were carried out under subdued room light. The mixtures were transferred to petri dishes, and placed on ice 15 cm away from the light source. Irradiation with UVA light was then performed, using a 3-mm window-glass to eliminate wavelengths of <320 nm. To evaluate the effect of UVB radiation, sera containing DMCT were irradiated in a similar manner with a UVB light source (40  $\text{mJ}/\text{cm}^2$  at 308–318 nm).

**Hemolytic titration of total complement activity and individual complement components.** Veronal-buffered saline, 0.15 M, pH 7.5, containing 0.1% gelatin (GVB); GVB containing 0.15 mM  $\text{CaCl}_2$ , and 0.5 mM  $\text{MgCl}_2$  (GVB++); equal volumes of 5% dextrose in water and GVB++ (DGVB++) and 40 mM EDTA buffer in GVB (EDTA-GVB) were prepared as previously described (9). Sheep erythrocytes were sensitized with rabbit anti-sheep hemolysin (erythrocytes coated with antibody, EA). EACI were prepared by mixing EA with human CI, diluted to provide 200 effective hemolytic sites/cell. After incubation at 30°C for 30 min and at 4°C for 15 min, the cells were washed in DGVB++ (10). EACI4b were prepared by incubating EACI,  $1 \times 10^9$  ml, with human C4 to provide 400 effective molecules/cell. The mixture was then incubated at 4°C for 30 min (11), the cells were then washed and resuspended in DGVB++ and stored in the same buffer with penicillin and streptomycin. EAC4b cells were prepared by incubating EACI4b cells in 0.04 M EDTA-GVB. These cellular intermediates were used to measure total complement hemolytic activity (CH50) and C1, C4, C2, C3, and C5 titers (1).

**Crossed immunoelectrophoresis.** Two-dimensional (crossed) immunoelectrophoresis was performed with minor modifications of the method of Laurell (12). Goat antisera to human C3 were obtained from Atlantic Antibodies, Westbrook, ME.

**PMN chemotaxis.** PMN were obtained from venous blood of healthy adult donors by a previously described method (13). Briefly, PMN were isolated by dextran-sedimentation technique, and suspended in PBS, pH 7.4, supplemented with 0.6 mM  $\text{CaCl}_2$ , 1.0 mM  $\text{MgCl}_2$ , and 2.0% of bovine serum albumin (wt/vol). Cell suspensions contained ~85% PMN. Random motility and directed migration (chemotaxis) of these cells were assessed by a modification of the leading front method of Zigmond and Hirsch, as previously described (1, 13, 14). 2% dilutions of treated and untreated sera, or buffer, were placed in the lower compartments of modified Boyden chambers (Nucleopore Corp., Pleasanton, CA); aliquots (0.8 ml) of leukocyte suspensions, containing  $2.5 \times 10^6$  PMN/ml, were added to the upper compartments. The upper compartments were separated from the lower ones by 3- $\mu\text{m}$  (pore diameter) nitrate cellulose micropore filters (Sartorius Filters, Inc., San Francisco, CA). The chambers containing cells and chemoattractants were incubated at 37°C for 30 min. The filters were then removed, fixed in methanol, stained with hematoxylin, dehydrated in ethanol, and cleared in xylene. The response of PMN, either to buffer alone (random motility) or to chemotactic stimuli is measured as the distance that the leading front of cells migrated into the filters (in micrometers per

30 min). This was performed by microscopic examination  $\times 45$  objective, measuring the distance from the top of the filter to the furthest plane of focus that contained at least two cells in focus. For each experiment, duplicate chambers were used and 10 fields were examined per filter. Goat antisera to human C5 used in some of the chemotactic experiments were obtained from Meloy Laboratories, Inc., Springfield, VA.

*In vivo induction of localized phototoxic lesions in guinea pigs.* Albino guinea pigs, 600–800 g, were purchased from Camm Research Lab Animals (Wayne, NJ). Guinea pigs congenitally deficient in C4 were obtained from our own colony at New York University Medical Center. The depilated backs of albino guinea pigs were injected intradermally at multiple sites either with 0.1 ml of DMCT in PBS (1.0 mg/ml) or with PBS alone. Only areas below the scapulae were used. 20 min later, the left side of the backs of different groups of guinea pigs were exposed either to UVA (14.4–19.2 J/cm<sup>2</sup>) or to UVB (40 mJ/cm<sup>2</sup>), while the right side was covered with a lead shield to serve as a nonirradiated control side. Doses of UVA and UVB chosen were in the range of the known minimal erythema dose in man for UVA and UVB, respectively. Clinical changes were evaluated serially up to 72 h after the completion of the irradiation. These changes were graded visually by two independent observers on the following scale: 0: no erythema, no induration; 0.25+: minimally perceptible erythema, no induration; 0.5+: minimal erythema, minimally palpable induration; 1.0+: pink erythema, minimal induration; 1.5+: pink erythema, moderately palpable induration; 2.0+: red erythema, moderate induration; 2.5+: red erythema, marked induration; and 3.0+: red erythema with erosion. For each experiment, the results are expressed as the mean of clinical response score  $\pm$  SEM.

At each time of clinical examination, skin biopsies were performed. The tissues obtained were fixed in 10% formalin, embedded in paraffin, cut with a microtome into 6- $\mu$ m-thick sections, and stained with hematoxylin and eosin (15). The specimens were examined under light microscope, and the epidermal and dermal changes were noted. The appearance of neutrophils in the dermis in these specimens were quantified by modification of a previously described method (16, 17). Briefly, differential cell counts on all infiltrating cells in the dermis encountered in two randomly selected vertical swaths were performed, using a calibrated optical grid. As measured from the dermal-epidermal junction, each swath was 156  $\mu$ m in width and 474  $\mu$ m in height. The size of the vertical swath was selected as the dermal changes in these specimens were observed within 450  $\mu$ m of the dermal-epidermal junction. The differential cell counts for each specimen were performed on two separate histologic sections; hence, infiltrating cells in a total of four vertical swaths were counted. The total number of cells counted in the four swaths ranged from 300 to 400. Results are expressed as the mean percentage of neutrophils  $\pm$  SEM. On the basis of the morphology and staining characteristics, the following cells were distinguishable: mononuclear cells, eosinophils, basophils, and neutrophils. Evaluation for the increase in vascular permeability associated with the development of phototoxic lesions was performed by assessing the degree of bluing induced by 1% Evans blue (Fisher Scientific Co., Fairlawn, NJ) in normal saline. The dye was injected intravenously into the guinea pigs 30 min before the completion of the irradiation, and the degree of bluing was evaluated 30 min later.

Similar experiments were performed in guinea pigs rendered neutropenic or decompartmented, or both neutropenic and decompartmented. Neutropenia was achieved in these

animals by two intraperitoneal injections of cyclophosphamide (Mead Johnson & Co., Evansville, IN) at 5 and 1 d before the study (200 and 50 mg/kg, respectively), a previously described method (18). In pilot studies, we confirmed that this treatment resulted in a complete depletion of peripheral PMN without any alteration of the complement profile. Decompartmentation was performed by intraperitoneal injection of 300 U/kg of cobra venom factor (Cordis Laboratories, Inc., Miami, FL) 16 h before the administration of DMCT and UVA irradiation (18). Our pilot studies demonstrated that such treatment resulted in a decrease in the hemolytic titers of C3 and C5 of 90–95 and 55–60%, respectively. Guinea pigs were decompartmented and rendered neutropenic by injections of both cobra venom factor and cyclophosphamide.

## RESULTS

*In vitro effect of DMCT, UVA, or UVB irradiation on human complement system.* UVA irradiation (2.4 J/cm<sup>2</sup>) of human serum containing varying concentrations of DMCT (25–100  $\mu$ g/ml) resulted in a dose-dependent decrease of CH50, reflecting the decrease in the titers of the components tested: C4, C2, C3, and C5 (Fig. 1). In samples that contained DMCT and were kept in darkness, no alteration of these hemolytic activities were noted. Exposure of normal human serum to UVA, in the absence of DMCT, did not alter the complement profile (Fig. 1, ordinate). Furthermore, the alteration of the complement profile was dependent upon the irradiance energy (Fig. 2). To investigate whether the decrease in complement hemolytic activities was due to the nonspecific inhibitory effect of the DMCT molecules on the complement proteins or whether it was due to the activation of the complement system associated with the generation of biologically active cleavage products, serum samples were subjected to two-dimensional immunoelectrophoresis. The result of a representative experiment is shown in Fig. 3. In sample containing DMCT, exposure to UVA resulted in the appearance of an extraanodal precipitant peak, representing the cleavage products of C3. Such a treatment also resulted in the generation of potent chemotactic activity for human PMN (Table I). The chemotactic activity generated was thermostable and was inhibitable by antiserum to C5, but not by antiserum to C3, indicating that it was C5 derived. No chemotactic activity was detected when DMCT-containing sera were kept in the dark. In contrast to the effect of UVA irradiation, exposure of sera containing DMCT (50  $\mu$ g/ml) to 40 mJ/cm<sup>2</sup> of UVB light did not result in alteration of the complement activity (data not shown).

Clinical relevance of the above observations was studied in sera containing 5  $\mu$ g/ml of DMCT, a concentration comparable to that observed in serum of individuals taking this medication (19). UVA (16 J/

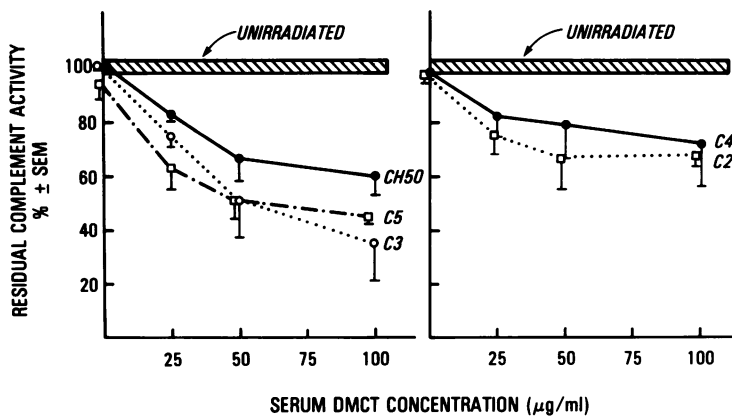


FIGURE 1 Effect of UVA ( $2.4 \text{ J/cm}^2$ ) and varying serum concentration of DMCT on CH50, C4, C2, C3, and C5 titers. At 25, 50, and  $100 \mu\text{g/ml}$  DMCT, irradiation resulted in statistically significant decrease of titers of CH50, C2, C3, and C5 ( $P < 0.05$ , vs. titers of samples that received PBS and kept unirradiated).

$\text{cm}^2$ ) irradiation of these sera resulted in a decrease of CH50, C1, C4, C2, and C3-9 titers (Table II).

The possibility of the generation of a stable photo-product of DMCT and its role in the decrease in hemolytic activity of complement were studied in the following experiment. A solution of DMCT,  $50 \mu\text{g/ml}$ , was exposed to UVA irradiation ( $24.0 \text{ J/cm}^2$ ) before its addition to serum (DMCT/serum, 1:1). As shown in Table III, the CH50 titer was not altered in serum containing preirradiated DMCT; furthermore, subsequent irradiation of this mixture did not result in any significant decrease of the titer. In the same experiment, serum containing DMCT that was not preirradiated had a significant decrease of its hemolytic activity upon subsequent irradiation. These data indicate

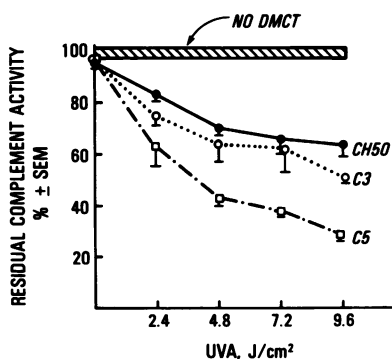


FIGURE 2 Dose-response effect of UVA irradiation on CH50, C3, and C5 titers of serum samples containing  $25 \mu\text{g/ml}$  DMCT. Irradiation with 2.4, 4.8, 7.2, and  $9.6 \text{ J/cm}^2$  of UVA resulted in statistically significant decrease of CH50, C3, and C5 titers ( $P < 0.05$ , vs. titers of samples that received PBS and kept unirradiated).

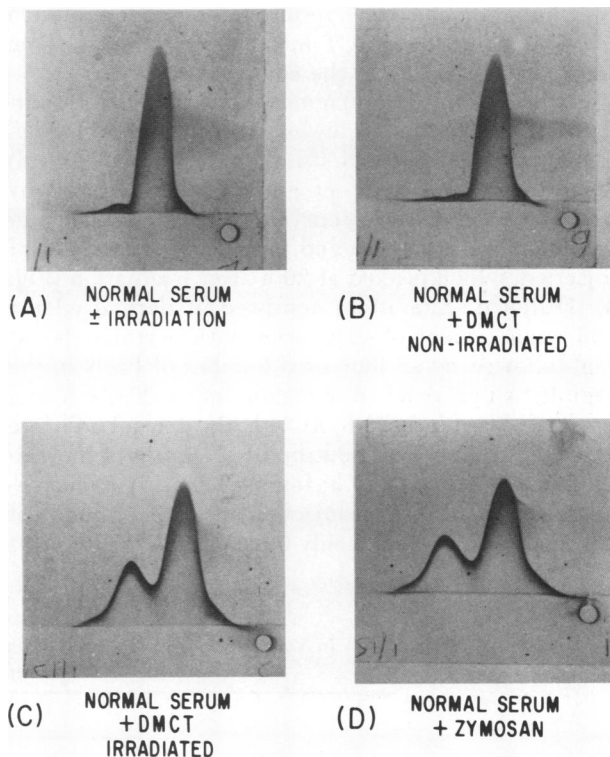


FIGURE 3 Effect of UVA irradiation on electrophoretic mobility of C3, as detected by two-dimensional immunoelectrophoresis technique. Normal serum, with or without irradiation, (A), or DMCT-containing serum, kept unirradiated (B), both demonstrate a single precipitant peak, representing that of native C3. Panel C shows that irradiation of DMCT-containing serum resulted in the appearance of an extra-anodal precipitant peak, similar to that observed when zymosan-activated serum was used (D). This anodal peak represents cleavage products of C3.

TABLE I  
Generation of Chemotactic Activity in Sera Containing DMCT and Exposed to UVA

Stimulus	PMN migration*
	$\mu\text{M}/30 \text{ min}$
DMCT (100 $\mu\text{g}/\text{ml}$ ) + UVA (2.4 $\text{J}/\text{cm}^2$ )	117.2 $\pm$ 3.6†
DMCT (100 $\mu\text{g}/\text{ml}$ ) + dark	99.8 $\pm$ 2.7
DMCT + UVA $\rightarrow$ 56°C	115.9 $\pm$ 2.3†
DMCT + UVA $\rightarrow$ A-C3	113.1 $\pm$ 2.2†
DMCT + UVA $\rightarrow$ A-C5	98.6 $\pm$ 3.1
Buffer	96.6 $\pm$ 2.7

\* Results represent the mean of two experiments  $\pm$  SEM. Duplicate chambers were used in each experiment and 10 fields were examined in each filter.

†  $P$ , vs. buffer,  $< 0.05$  (Student's  $t$  test).

that a stable photoproduct of DMCT was not involved in this reaction. In addition, they also suggest that preirradiation of DMCT resulted in photodegradation of the majority of DMCT molecules, rendering them incapable of activating the complement system.

*Participation of complement and PMN on the induction of phototoxic lesions in an animal model.* Intradermal injection of 0.1 ml DMCT (1.0 mg/ml) on the depilated backs of guinea pigs, followed by exposure to 14.4–19.2  $\text{J}/\text{cm}^2$  UVA, resulted in the development of erythema and induration at the sites of injection, which peaked at 20 h after irradiation (Fig. 4). Histologic alterations consisted of dermal edema and engorgement of capillaries with erythrocytes at 1 h, followed by an increased number of PMN in the dermis, which reached a maximum at 20–24 h and persisted for at least 72 h. At 24 h, the dermal infiltrate consisted of 29 $\pm$ 2% of neutrophils. Necrosis of the epidermis was noted at 20 h, followed by its gradual regeneration. Guinea pigs injected with DMCT and kept unirradiated developed only 0.5 clinical changes at 24

h, which subsided by 72 h (Fig. 4). Histologic changes at these sites were limited to a sparse neutrophilic infiltrate in the dermis (2.9 $\pm$ 0.4% neutrophils at 24 h). At 24 h, the difference between the percentage of neutrophils at sites injected with DMCT and exposed to UVA and that at sites injected with DMCT and kept in the dark was statistically significant ( $P < 0.01$ ). At sites injected with buffer and subsequently irradiated or at sites exposed to irradiation alone, no clinical changes were noted at 24 h. Histologically, there was some dermal edema at 1 h, which subsided by 24 h. The dermal cellular infiltrate in these specimens consisted of  $< 0.5\%$  of neutrophils (range: 0–0.4 $\pm$ 0.35%), which was similar to that observed in tissues obtained from untreated sites.

In contrast to the clinical and histologic changes observed in DMCT-treated guinea pigs exposed to UVA, irradiation with UVB (40  $\text{mJ}/\text{cm}^2$ ) induced only 0.5 $\pm$ 0.25 clinical changes. Histologic findings were limited to dermal edema at 2 h, followed by the appearance of necrotic keratinocytes at 24 h.

The role of PMN in the development of DMCT-induced phototoxic lesions was studied in guinea pigs rendered neutropenic by cyclophosphamide injections. In these guinea pigs, a maximal clinical response of 0.75 $\pm$ 0.6 at 24 h was elicited (Fig. 5). This was associated histologically with the appearance of few intact and fragmented neutrophils in the dermis (1.2 $\pm$ 0.5% neutrophils at 24 h). The degree of neutrophilic infiltrate was not statistically significantly different from that observed at sites injected with DMCT alone.

The participation of the complement system in this reaction was studied in guinea pigs congenitally deficient of C4, which had normal C3 and C5 levels. Only the white areas were used in these tricolored guinea pigs. There was a marked suppression of clinical response induced by DMCT and UVA (Fig. 5). Histologically, marked dermal edema, and dilated capillaries engorged with erythrocytes were observed

TABLE II  
In Vitro Effect of UVA Irradiation (16  $\text{J}/\text{cm}^2$ ) on Complement Activities of Serum Containing 5  $\mu\text{g}/\text{ml}$  of DMCT\*

DMCT concentration	Residual complement activity†				
	CH50	C1	C4	C2	C3-9
$\mu\text{g}/\text{ml}$					
			%		
5.0	78 $\pm$ 2§	59 $\pm$ 15	84 $\pm$ 3§	70 $\pm$ 1§	85 $\pm$ 11
0	98 $\pm$ 2	98 $\pm$ 2	100 $\pm$ 1	100 $\pm$ 2	100 $\pm$ 1

\* DMCT/normal human serum, 1:9.

† Calculated based on titers of samples that received PBS and were kept unirradiated. Values are means  $\pm$  SEM.

§  $P < 0.05$ , vs. titers of samples that received PBS and were kept unirradiated.

TABLE III  
In Vitro Effect of Preirradiated DMCT on CH50

Reagent	UVA	Final concentration in sera*	Residual CH50 activity†	
			Dark	2.4 J UVA/cm <sup>2</sup>
	J/cm <sup>2</sup>	µg/ml	%	
DMCT, 50 µg/ml	24.0	25	99±1	97±2
DMCT, 50 µg/ml	0	25	100±0.5	70±3‡

\* DMCT/normal human sera, 1:1.

† Calculated based on titers of the samples that received PBS and were kept unirradiated. Values are means±SEM.

‡  $P < 0.05$ , vs. titers of samples that received PBS and were kept unirradiated.

at 6 h; at 24 h, only a slight engorgement of capillaries was noted. The dermal infiltrate consisted of  $2.9 \pm 0.1\%$  of neutrophils at 24 h, which was similar to that observed at sites injected with DMCT alone.

The involvement of the complement system was further studied in normal guinea pigs depleted of C3 and C5 by intraperitoneal injections of cobra venom factor. In contrast to guinea pigs with a normal complement system, DMCT and UVA induced a minimal phototoxic response, which subsided by 24 h (Fig. 5). These clinical changes were associated histologically with the presence of  $6.5 \pm 0.8\%$  of neutrophils in the dermis at 6 h. The neutrophilic infiltrate was not statistically different from that noted at sites injected with DMCT.

In guinea pigs injected with both cobra venom factor and cyclophosphamide (hence, C3-C5-depleted as well as neutropenic), the clinical and histologic changes induced by DMCT and UVA were essentially abolished.

Since edema was one of the early findings in the development of phototoxic lesions, the alteration in vascular permeability was assessed in studies using

guinea pigs injected intravenously with Evans blue solution. In animals with a normal complement system, intense bluing was noted at sites injected with DMCT and exposed to UVA, reflecting a localized increase in vascular permeability (Fig. 6). In contrast, in guinea pigs depleted of both C3 and C5, only minimal bluing was observed. The specificity of both this inhibition was demonstrated by the reaction to a topically applied primary irritant (croton oil). The response observed in decompensated guinea pigs was comparable to that noted in those with a normal complement system.

## DISCUSSION

The interactions of phototoxic substances and their biologic substrates have been shown to be mediated by several types of photochemical reactions (20). The first one involves the absorbance of photons by the phototoxic substances, resulting in the formation of the excited state molecules, which may interact directly with their biologic substrates to form photoproducts. An example of such a photochemical reaction is the

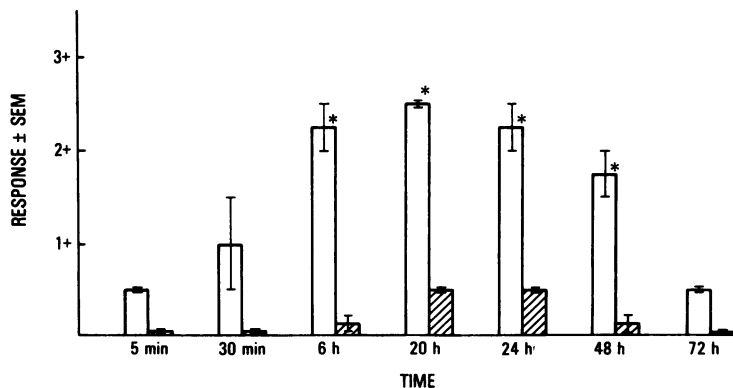


FIGURE 4 Phototoxic response induced by DMCT (1.0 mg/ml) and UVA ( $19.2 \text{ J/cm}^2$ ) in normal guinea pigs. (□), UVA; (▨), dark. \*  $P$  vs. dark  $< 0.05$ .

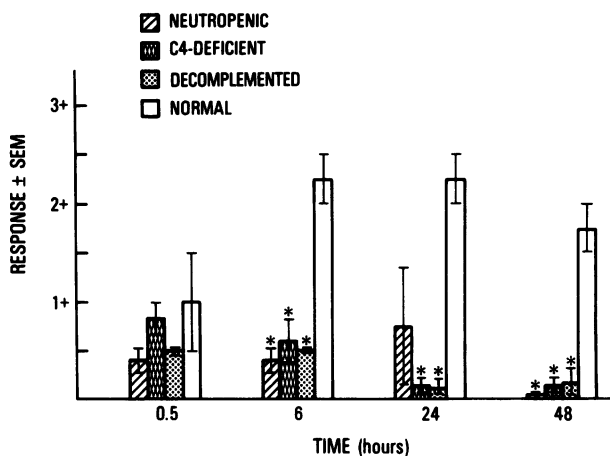


FIGURE 5 Phototoxic response induced by DMCT and UVA in guinea pigs that were neutropenic, or deficient in C4, or decomplemented. Response observed in normal guinea pigs is shown for comparison. At least three guinea pigs were used for each experiment.  $P$  vs. normal  $< 0.05$ .

light-induced formation of a photoadduct of 8-methoxypsoralen and a pyrimidine base in the DNA molecule (21). In the second type of reaction, the molecules absorb photons to form stable photoproducts, which are toxic to the biological substrates. Both chlorpromazine and protriptyline had been shown to form such toxic photoproducts, which caused lysis of erythrocytes *in vitro* (22). A third type of reaction involves the generation of toxic oxygen species, such as singlet oxygen, superoxide anions, and hydroxyl radicals. In this reaction, the molecules that initially absorb the photons transfer the energy to oxygen molecules, resulting in the formation of an excited state of oxygen. Examples of this type of reaction are the toxic oxygen species produced by irradiation of protoporphyrin (23), xanthene dyes (24), and thiazine dyes (24).

The elucidation of the above photochemical reactions contributes toward the basic understanding of the pathogenesis of cutaneous phototoxic lesions; however, these studies were performed in a serum-free environment. The role of proteins in the serum, either as the primary mediator or as the amplifying system, in the development of phototoxic tissue damage *in vivo*, has not been investigated. We have demonstrated previously that *in vitro*, as well as *in vivo*, photoactivation of the complement system occurred in the presence of uroporphyrin or protoporphyrin, two endogenous phototoxic substances (1-3). This was associated with the generation of chemotactic activity for human PMN. These findings suggest that the complement system participates in the development of cutaneous lesions in phototoxicity. Such a concept is consistent with the observations that complement proteins and im-

munoglobulins were deposited in the exposed skin of patients with porphyrias (5). In addition, in patients with erythropoietic protoporphyria, an acute photosensitivity flare is associated clinically with burning sensation, edema, erythema, and histologically with the appearance of PMN in the dermis (6). Furthermore, irradiation of forearms of patients with erythropoietic protoporphyria or porphyria cutanea tarda resulted in the activation of the complement system (4).

To investigate whether other phototoxic substances are also capable of inducing photoactivation of complement, *in vitro* and *in vivo* studies were performed with DMCT, an exogenous phototoxic agent, with an excitation spectra in the UVA range (25). The doses of UVA used in these studies were between 2.4 and 19.2 J/cm<sup>2</sup>. Solar irradiance for the wavelength range of 330 to 390 nm at sea level on a midsummer day is 4,150  $\mu$ W/cm<sup>2</sup>, which is more than three times greater than the output of the light source used (1,310  $\mu$ W/cm<sup>2</sup>) (26). Therefore, during the course of daily activities, exposure to equivalent or higher doses of radiation energy as those used in these experiments could be achieved.

*In vitro*, irradiation of DMCT-containing sera resulted in diminution of CH50 and decrease in C4, C2, C3, and C5 titers (Fig. 1). These changes were dependent on the concentration of DMCT, as well as on the irradiance energy administered (Figs. 1 and 2). As shown in Fig. 3, the diminution of complement hemolytic activity was associated with the alteration in the electrophoretic mobility of C3, presumably owing to the appearance of cleavage products. Furthermore, C5-derived chemotactic activity for human PMN was generated (Table I). In contrast to UVA, UVB irradiation of such sera did not result in complement activation. This is consistent with the known excitation fluorescence spectra of DMCT, as well as its clinical action spectra, which are both in the range of UVA (25).

The clinical relevance of the above observations was demonstrated in experiments using sera containing DMCT at a concentration achieved clinically (5  $\mu$ g/ml) (19). As shown in Table II, irradiation of serum containing 5  $\mu$ g/ml of DMCT also resulted in photoactivation of the complement system.

The possible role of stable photoproduct(s) of DMCT that might induce the activation of the complement system was investigated in experiments summarized in Table III. Exposure of DMCT to UVA light before its addition to normal human serum did not cause any alterations of the complement profile, indicating that a stable photoproduct was not involved in this reaction. Furthermore, such preirradiation of DMCT resulted in the loss of its efficacy to activate the complement

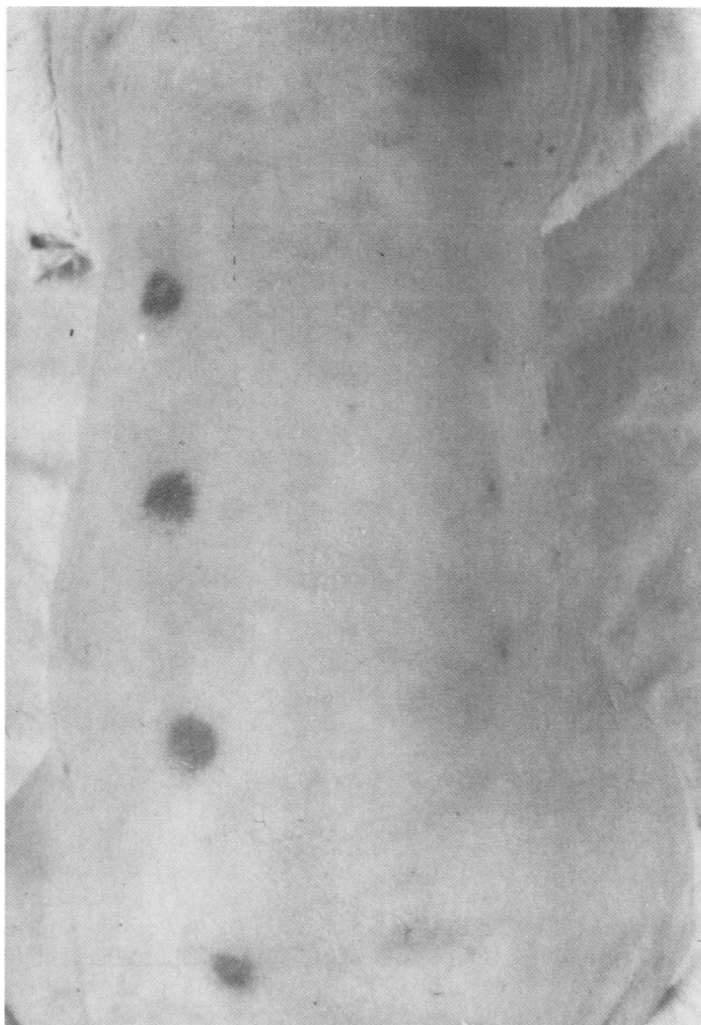


FIGURE 6 Clinical appearance of a representative guinea pig 30 min after intravenous injection of Evans blue solution. The back of this animal was injected with DMCT at multiple sites; the left side of the back was then exposed to UVA, while the right side was protected from the irradiation. Intense bluing is observed only at sites injected with DMCT and exposed to UVA.

system upon subsequent irradiation, presumably owing to photodegradation of the molecules.

Having demonstrated that *in vitro* irradiation of DMCT-containing serum with UVA resulted in the activation of the complement system and in the generation of chemotactic activity for PMN, we investigated the role of complement and neutrophils in the development of phototoxic lesions *in vivo*, using guinea pigs as an animal model. Intradermal injection of DMCT, 100  $\mu\text{g}/\text{site}$ , followed by UVA irradiation, consistently resulted in the development of phototoxic lesions, as manifested by cutaneous erythema and edema, whereas only minimal erythema and edema was noted at the DMCT injected, nonirradiated sites (Fig. 4). The

quantity of DMCT injected was chosen on the basis of a study of tetracycline-induced phototoxicity in which the concentration of the drug in the involved skin was found to be 10-fold higher than that in the serum (27). Clinical evaluation of the evolution of the phototoxic response showed that it reached its peak 20 h after the completion of the irradiation and then subsided gradually. Histologically, there was dermal edema at 1 h, followed by PMN infiltrate, which peaked at 20–24 h. At 24 h, the dermal infiltrate consisted of  $29 \pm 2\%$  of neutrophils. These clinical and histologic changes are similar to those of phototoxic lesions induced by intraperitoneal administration of DMCT (7) or protoporphyrin (2, 28). These results also



confirm and extend the previously reported observation that intradermal injection of DMCT into backs of mice, followed by "black light" irradiation, resulted in the development of cutaneous erythema (25).

The presence of PMN at the sites of phototoxic lesions suggested that these cells may contribute to the development of tissue damage. This was investigated in guinea pigs rendered neutropenic by intraperitoneal injections of cyclophosphamide (18). Such injections resulted in complete depletion of circulating PMN without altering the complement profile. In these guinea pigs, the maximal intensity of the reaction was diminished; whereas a response of  $2.25 \pm 0.25$  was observed in normal guinea pigs, only  $0.75 \pm 0.6$  response was noted in cyclophosphamide-treated animals at 24 h (Fig. 5). Histologically, few intact and fragmented neutrophils ( $2.9 \pm 0.4\%$  at 24 h) were observed in the dermis. As compared with response observed in normal guinea pigs, the suppression of clinical response in neutropenic guinea pigs was statistically significant at 6 h and at 48 h; however, it was not statistically significant at 24 h. These data indicate that although a normal number of neutrophils is apparently required for the full development of phototoxic lesions, a mechanism independent of neutrophils is also operative.

Since dermal edema is the feature of the early histologic lesions, the participation of the complement system in the development of phototoxic lesions was studied in experiments performed in guinea pigs congenitally deficient in C4 and in decomplicated animals. Clinically, a maximal response of only  $0.83 \pm 0.16$  was observed in C4-deficient guinea pigs (Fig. 5). Histologically, there was marked dermal edema, accompanied by the appearance of PMN ( $2.9 \pm 0.1\%$  neutrophils at 24 h). In guinea pigs depleted of C3 and partially of C5, a minimal response (0.5) was observed (Fig. 5). These observations were corroborated by studies using intravenously injected Evans blue solution. In guinea pigs with normal complement system, intense localized bluing occurred at sites injected with DMCT and exposed to UVA (Fig. 6), whereas the same treatment induced only minimal bluing in cobra venom factor-treated animals.

There are other mediators of inflammation that have been shown to be responsible, at least in part, for the development of UV-induced erythema. Degranulation of mast cells has been observed after UVB (290–320 nm) irradiation of normal skin (29), as well as in tissue obtained from patient with erythropoietic protoporphyria after exposure to long-wave ultraviolet light (6). Cutaneous erythema induced by UVB, but not that induced by UVA (320–400 nm), was inhibitable by indomethacin, an inhibitor of cyclooxygenase pathway of arachidonic acid metabolism (30, 31). In vitro, fi-

broblasts have been reported to generate chemoattractants for PMN and monocytes (32); however, the in vivo significance of this observation in UV-induced erythema is not clear. Although results of the studies with cobra venom factor-treated, decomplicated animals suggest that the complement system plays a significant role in the development of DMCT-induced phototoxic lesions, the participation of other mediators remains to be elucidated.

The mechanism of complement activation induced by DMCT and UVA is not clear. A stable photoproduct of DMCT probably was not involved in this process (Table III). Another mechanism that may produce photoactivation of the complement system by DMCT involves the absorption of photons by the molecules, converting them into an excited state. The latter may interact directly with complement proteins, or with other serum proteins (e.g., C-reactive protein, plasminogen, Hageman factor, etc.), which in turn activates the complement system. Alternatively, photoactivation of complement may also involve the generation of toxic oxygen species. Experiments are in progress attempting to elucidate this interesting phenomenon.

The complement system is one of the principal effector systems of inflammation (33). It had been shown previously that porphyrins, upon exposure to 400–410 nm light, activated this system in vitro, as well as in vivo (1–4). In this report, we demonstrated that the complement system is also activated by DMCT in the presence of UVA irradiation. Therefore, these data suggest that the previously described photochemical reactions, which produced cellular damage in a serum-free environment, may also result in the activation of the complement system in the presence of serum. Whether the complement system serves as the primary mediator of phototoxic tissue injury in vivo or as an amplifying mechanism remains to be elucidated.

#### ACKNOWLEDGMENTS

The authors wish to acknowledge Mr. Bruce Weintraub for technical assistance; Dr. Anna Ragaz for reviewing the histologic sections; Dr. Maureen Poh-Fitzpatrick, and Dr. Donald V. Belsito for their review of the manuscript; and Ms. Elizabeth Drahman for secretarial assistance.

This work was supported by grants from the National Institutes of Health (AI 17365, AI 13809, and AM 01165) and by the Irma T. Hirsch Trust.

#### REFERENCES

1. Lim, H. W., H. D. Perez, I. M. Goldstein, and I. Gigli. 1981. Complement-derived chemotactic activity is generated in human serum containing uroporphyrin after irradiation with 405 nm light. *J. Clin. Invest.* 67:1072–1077.
2. Lim, H. W., and I. Gigli. 1981. Role of complement in

- porphyrin-induced photosensitivity. *J. Invest. Dermatol.* 76:4-9.
3. Lim, H. W., H. D. Perez, M. B. Poh-Fitzpatrick, I. M. Goldstein, and I. Gigli. 1981. Generation of chemotactic activity in serum from patients with erythropoietic protoporphyria and porphyria cutanea tarda. *N. Engl. J. Med.* 304:212-216.
  4. Lim, H. W., M. B. Poh-Fitzpatrick, and I. Gigli. 1982. Activation of the complement system and generation of chemotactic activity *in vivo* in patients with porphyrias. *Clin. Res.* 30:488a. (Abstr.)
  5. Epstein, J. H., D. L. Tuffanelli, and W. L. Epstein. 1973. Cutaneous changes in the porphyrias. A microscopic study. *Arch. Dermatol.* 107:689-698.
  6. Schnait, F. G., K. Wolff, and K. Konrad. 1975. Erythropoietic protoporphyria—submicroscopic events during the acute photosensitivity flare. *Br. J. Dermatol.* 92:545-557.
  7. Sams, W. M., Jr., and J. H. Epstein. 1967. The experimental production of drug phototoxicity in guinea pigs. I. Using sunlight. *J. Invest. Dermatol.* 48:89-94.
  8. Konrad, K., H. Honigsmann, F. Gschnait, and K. Wolff. 1975. Mouse model for protoporphyria. II. Cellular and subcellular events in the photosensitivity flare of the skin. *J. Invest. Dermatol.* 65:300-310.
  9. Nelson, R. A., J. Jenson, I. Gigli, and N. Tamura. 1966. Methods for the separation, purification, and measurement of nine components of hemolytic complement in guinea pig serum. *Immunochemistry.* 3:111-135.
  10. Ruddy, S., and K. F. Austen. 1967. A stoichiometric assay for the fourth component of complement in whole serum using EAC1<sup>8p</sup> and functionally pure component. *J. Immunol.* 99:1162-1172.
  11. Ferreira, A., V. Nussenzweig, and I. Gigli. 1978. Structural and functional differences between the H-2 controlled Ss and Slp proteins. *J. Exp. Med.* 148:1186-1197.
  12. Laurell, C. B. 1965. Antigen-antibody crossed immunophoresis. *Anal. Biochem.* 10:358-361.
  13. Perez, H. D., M. Lipton, and I. M. Goldstein. 1978. A specific inhibitor of complement (C5)-derived chemotactic activity in serum from patients with systemic lupus erythematosus. *J. Clin. Invest.* 62:29-38.
  14. Zigmond, S. H., and J. G. Hirsch. 1973. Leukocyte locomotion and chemotaxis. New Methods for evaluation and demonstration of a cell-derived chemotactic factor. *J. Exp. Med.* 137:387-410.
  15. Lever, W. F., and G. Schaumburg-Lever. 1975. *Histopathology of the Skin.* J. B. Lippincott Company, Philadelphia. Fifth Ed. 46-49.
  16. Dvorak, H. F., A. M. Dvorak, B. A. Simpson, H. B. Richerson, S. Leskowitz, and M. J. Karnovsky. 1970. Cutaneous basophil hypersensitivity. II. A light and electron microscopic description. *J. Exp. Med.* 132:558-582.
  17. Dvorak, H. F., and M. C. Mihm, Jr. 1972. Basophilic leukocytes in allergic contact dermatitis. *J. Exp. Med.* 135:235-254.
  18. Hosea, S., E. Brown, C. Hammer, and M. Frank. 1980. Role of complement activation in a model of adult respiratory distress syndrome. *J. Clin. Invest.* 66:375-382.
  19. Frost, P., G. Weinstein, and E. Gomez. 1971. Methacycline and demeclocycline in relation to sunlight. *JAMA (J. Am. Med. Assoc.).* 216:326-329.
  20. Kochevar, I. E. 1981. Phototoxicity mechanisms: chlorpromazine photosensitized damage to DNA and cell membranes. *J. Invest. Dermatol.* 76:59-64.
  21. Song, P.-S., and K. J. Tapley, Jr. 1978. Photochemistry and photobiology of psoralens. *Photochem. Photobiol.* 29:1177-1197.
  22. Kochevar, I. E., and A. A. Lamola. 1979. Chlorpromazine and protriptyline phototoxicity: photosensitized, oxygen-independent red cell hemolysis. *Photochem. Photobiol.* 29:791-795.
  23. Lamola, A. A., and F. H. Doleiden. 1980. Cross-linking of membrane proteins and protoporphyrin-sensitized photohemolysis. *Photochem. Photobiol.* 31:597-601.
  24. Ito, T., and K. Kobayashi. 1977. A survey of *in vivo* photodynamic activity of xanthenes, thiazines, and acridines in yeast cells. *Photochem. Photobiol.* 26:581-587.
  25. Stratigos, J. D., and I. A. Magnus. 1968. Photosensitivity by demethylchlortetracycline and sulphanilamide. *Br. J. Dermatol.* 80:391-405.
  26. Stair, R. 1969. Measurement and natural ultraviolet radiation. Historical and general introduction. *In The Biological Effects of Ultraviolet Radiation (With Emphasis on Skin).* F. Urbach, editor. Pergamon Press, Ltd., Oxford. 377-390.
  27. Cullen, S. I., P. M. Catalano and R. J. Helfman. 1966. Tetracycline sunsensitivity. *Arch. Dermatol.* 93:77.
  28. Baer, R. L., W. J. Miles, H. Rosman, and L. Harber, 1967. Erythropoietic protoporphyria: photosensitivity patterns in man and laboratory animals. *Dermatologica (Basel).* 135:5-10.
  29. Gilchrest, B. A., N. A. Soter, J. S. Stoff, and M. C. Mihm, Jr. 1981. The human sunburn reaction: histologic and biochemical studies. *J. Am. Acad. Dermatol.* 5:411-422.
  30. Snyder, D. S. 1975. Cutaneous effects of topical indomethacin, an inhibitor of prostaglandin synthesis, on UV-damaged skin. *J. Invest. Dermatol.* 64:322-325.
  31. Morison, W. L., B. S. Paul, and J. A. Parrish. 1977. The effects of indomethacin on long-wave ultraviolet-induced delayed erythema. *J. Invest. Dermatol.* 68:120-133.
  32. Sobel, J. D., and J. S. Gallin. 1979. Polymorphonuclear leukocyte and monocyte chemoattractants produced by human fibroblasts. *J. Clin. Invest.* 63:609-618.
  33. Gigli, I. 1979. The complement system in inflammation and host defense. The Presser White oration. *Clin. Exp. Dermatol.* 4:271-289.