

## Case Report

# Traumatic rupture of an intracranial dermoid cyst: Case report and literature review

Yoshua Esquenazi, Keith Kerr, Meenakshi B. Bhattacharjee<sup>1</sup>, Nitin Tandon

Vivian L Smith Department of Neurosurgery, and <sup>1</sup>Department of Pathology, University of Texas Medical School at Houston, Houston TX, USA

E-mail: Yoshua Esquenazi - [yoshua.esquenazilevy@uth.tmc.edu](mailto:yoshua.esquenazilevy@uth.tmc.edu); Keith Kerr - [keith.a.kerr@uth.tmc.edu](mailto:keith.a.kerr@uth.tmc.edu);  
Meenakshi B. Bhattacharjee - [meenakshi.b.bhattacharjee@uth.tmc.edu](mailto:meenakshi.b.bhattacharjee@uth.tmc.edu); \*Nitin Tandon - [nitin.tandon@uth.tmc.edu](mailto:nitin.tandon@uth.tmc.edu)  
\*Corresponding author

Received: 05 March 13 Accepted: 13 May 13 Published: 12 June 13

### This article may be cited as:

Esquenazi Y, Kerr K, Bhattacharjee MB, Tandon N. Traumatic rupture of an intracranial dermoid cyst: Case report and literature review. *Surg Neurol Int* 2013;4:80.  
Available FREE in open access from: <http://www.surgicalneurologyint.com/text.asp?2013/4/1/80/113357>

Copyright: © 2013 Esquenazi Y. This is an open-access article distributed under the terms of the Creative Commons Attribution License, which permits unrestricted use, distribution, and reproduction in any medium, provided the original author and source are credited.

## Abstract

**Background:** Dermoid tumors are benign congenital cystic lesions that usually present with local mass effect. Very rarely, they present as spontaneous ruptures. Traumatic rupture of these dermoid cysts is an extremely rare event and only a handful of such cases have been ever reported.

**Case Description:** A 47-year-old female presented to our hospital with a ruptured intracranial dermoid cyst following a mild head injury. The ruptured cyst contents were disseminated into the subarachnoid and intraventricular compartments, resulting in an obstructive hydrocephalus. After medical stabilization, she underwent gross total resection of the cyst using combined transsylvian, transcortical-transventricular, and sub-frontal approaches. A ventriculo-peritoneal shunt was eventually also needed.

**Conclusion:** Traumatic rupture of an intracranial dermoid cyst is an extremely rare event and this is only the fourth such case reported in the literature. We presume that this rupture occurs due to sudden shifts in the cyst sac, which is adherent to some partially mobile intracranial contents. Although computed tomography (CT) is often adequate in making a diagnosis of this entity, magnetic resonance imaging (MRI) provides complete characterization of the extent of lipid dissemination, and is essential for operative planning. Intravenous steroids at presentation are helpful in managing the aseptic meningitis associated with rupture. Complete surgical resection is the goal, but must be weighed against the risk for injury to nearby vital structures. Hydrocephalus should be managed promptly, and patients should be monitored for it closely in the perioperative period. Even though the recurrence rate with subtotal resection is extremely rare, follow up should be done routinely.

**Key Words:** Aseptic meningitis, communicating hydrocephalus, dermoid cyst, intracranial rupture

### Access this article online

**Website:**

[www.surgicalneurologyint.com](http://www.surgicalneurologyint.com)

**DOI:**

10.4103/2152-7806.113357

**Quick Response Code:**

## INTRODUCTION

Dermoid cysts, also known as dermoid tumors, are rare benign congenital cystic masses of embryological origin that represent 0.04-0.6% of all intracranial tumors.<sup>[1]</sup>

Dermoid and epidermoid cysts are both thought to arise from defects in the separation of the neuroectoderm during the formation of the neural tube, leading to sequestration of ectodermal remnants. Intracranial dermoid cysts occur at either end of the neuraxis and

mostly near the midline. Intracranial dermoids are found in the posterior fossa, supra, and parasellar regions. Dermoids enlarge slowly and accumulate viscous or semi-solid inspissated yellow material that comprises desquamated epithelium, sebaceous gland secretions, fat, oil, and hair. The presence of skin adnexa (hair follicles, sebaceous, and sweat glands) in the cyst wall and contents distinguishes dermoids from epidermoid cysts. The rupture of an intracranial dermoid cyst causes dissemination of the cyst contents into the ventricular and subarachnoid space. Most ruptures occur spontaneously. Very rarely, the rupture of cysts has been reported after head trauma.<sup>[8,12,13]</sup> The present paper reports a case of a 47-year-old female with a traumatic intracranial dermoid cyst rupture after minor head trauma that was managed surgically with a gross total resection. To our knowledge, only three prior cases of traumatic rupture have been reported in the literature, only two of which have been treated surgically.

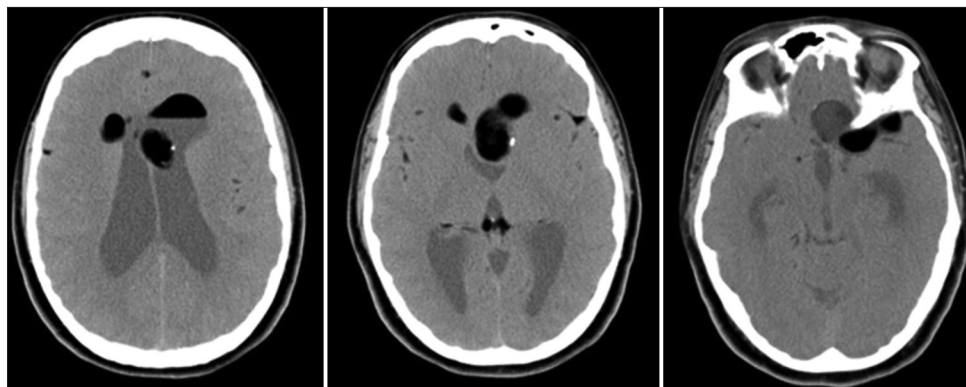
## CASE DESCRIPTION

A 47-year-old healthy female struck the back of her head on a shelf in a closet at her home and suffered a transient loss of consciousness. She had a headache immediately thereafter and this progressively worsened over the next 2 days. She also developed nausea and vomiting and photophobia over this time interval. On physical examination at initial presentation to our hospital, she was found to have nuchal rigidity, but otherwise her neurological examination was unremarkable. A noncontrast computer tomography (CT) scan revealed a heterogeneous very low attenuation lesion extending from the floor of the anterior cranial fossa superiorly along the falx, with diffuse scattered areas of low-attenuation throughout the subarachnoid space and lateral ventricles. These areas of low attenuation resembled the appearance of pneumocephalus. Magnetic resonance imaging (MRI) scans revealed a large multi-lobulated lesion extending along the floor of the left anterior and middle cranial fossae that was hyperintense on T1 weighted sequences

at all locations except at the skull base attachment at the planum sphenoidale, where it was hypointense. Droplets of T1 hyperintense material were present throughout the subarachnoid space, including the sylvian fissures bilaterally, the quadrigeminal cistern, the ambient cisterns, and sulci over the frontal convexity. Fat-fluid levels were present throughout the ventricular system, with evidence of obstructive hydrocephalus [Figures 1 and 2].

The patient was immediately started on high dose intravenous (IV) steroids and monitored in the intensive care unit. Two days after admission, her symptoms of headaches and nausea had resolved. The patient was taken to the operating room on hospital day three. The tumor was removed via a left fronto-temporal craniotomy and orbital osteotomy with combined transsylvian, sub-frontal, and transcortical-transventricular approaches. The sylvian fissure was opened widely, and large amounts of fat globules as well as some hair fragments were found within the fissure. The ventricular contents of the ruptured cyst were approached through a small corticectomy in the middle frontal gyrus. The frontal horn of the lateral ventricle was entered, where a large amount of fatty material expressed itself under pressure. Sebaceous material and hair were removed from a contained cyst that was dissected away from the surrounding ependyma. The sub-frontal exposure allowed access to the remainder of the cyst at the skull base, where it was dissected away from the optic nerve and the carotid artery in a piecemeal fashion and away from the dura of the skull base. During the dissection, and at the conclusion of the case, the ventricular system and subarachnoid space were thoroughly irrigated with saline solution.

Once a gross total removal of the cyst was achieved, communication between the basal-frontal and the intraventricular approaches was accomplished and a septostomy was performed. A ventricular catheter was placed and externalized to allow residual fat droplets and sebaceous material in the ventricular system a



**Figure 1:** Noncontrast CT scan of the head shows a heterogeneous low attenuation lesion extending from the floor of the anterior cranial fossa superiorly along the falx, with diffuse scattered areas of low-attenuation throughout the subarachnoid space and lateral ventricles

path to exit the cranium [Figure 3]. The postoperative course was uneventful; the ventriculostomy catheter was removed successfully 3 days after surgical intervention, and the patient was discharged home on postoperative day 4 on a tapering dosage of steroids. Histo-pathologic examination of the surgical specimens showed the wall of a ruptured dermoid cyst, with the typical squamous epithelial lining, and dispersed pilosebaceous units (hair follicles and associated sebaceous glands) with some focal calcification [Figure 4].

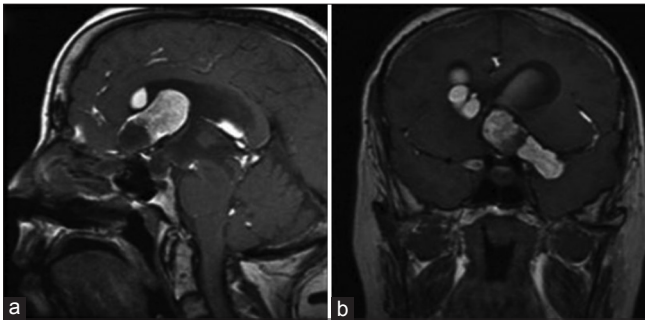
Two weeks after discharge the patient was seen in clinic with worsening headaches and a subgaleal fluid accumulation. Repeat head CT showed evidence of dilatation of the ventricular system consistent with communicating hydrocephalus. The patient underwent placement of a right frontal ventriculo-peritoneal shunt.

## DISCUSSION

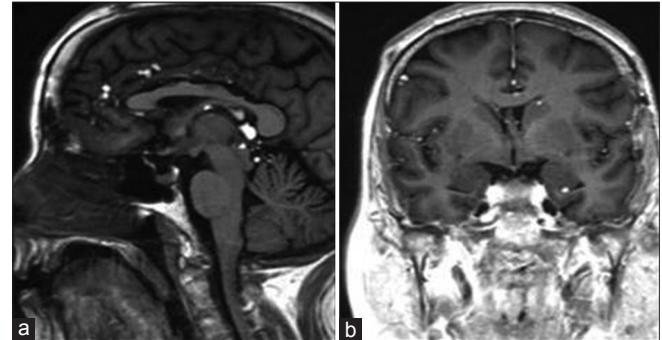
Dermoid cysts comprise 0.04-0.6% of all intracranial tumors<sup>[6,10]</sup> and develop when dermal components become trapped intracranially along the lines of

embryonic closure, during fetal development. Rupture of these benign lesions occurs in only a small percentage of patients, and usually occurs spontaneously.<sup>[5,15]</sup> Traumatic rupture of an intracranial dermoid cyst is an exceedingly rare event, with only three cases reported in the literature to date.<sup>[8,12,13]</sup> Our case of traumatic rupture represents the fourth such case, and only the third case to be managed surgically.

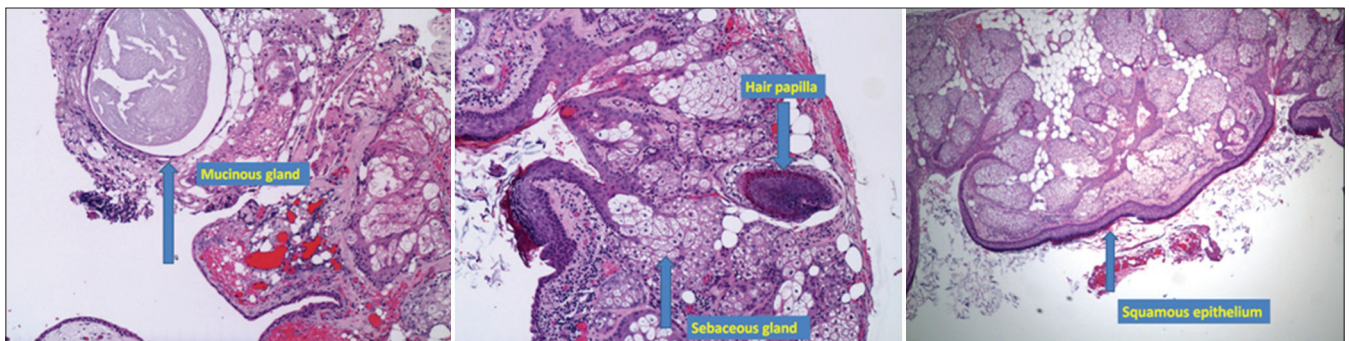
Patients with spontaneous ruptured intracranial dermoid cysts present with a variety of neurologic symptoms such as headaches, seizures, nausea, visual loss, facial numbness, neck pain, meningeal signs, and altered consciousness. Some of these patients will report progressive neurologic symptoms prior to the acute rupture due to the mass effect of the growing cyst. These symptoms depend on the location of the cyst, but can include worsening headache due to hydrocephalus, and progressive visual loss from optic chiasm compression.<sup>[9,10]</sup> Hydrocephalus may be present due to obstruction of the cerebrospinal fluid pathway due to mass effect of the cyst, or alternatively through occlusion of ventricular outlets by disseminated fat particles after rupture.<sup>[3,4,10]</sup> The symptoms of patients with traumatic rupture of a dermoid cyst may be present shortly after trauma,<sup>[8,12,13]</sup> or as in the case of our patient, days later. It has previously been proposed that the presence of lipid droplets within the subarachnoid space



**Figure 2:** Preoperative sagittal and coronal T1 MRI of the brain (a and b) shows a large T1 hyperintense multilobulated lesion extending along the floor of the left anterior and middle cranial fossa, with areas of T1 hypointense signal around the component in the left anterior cranial fossa. Locules of T1 hyperintense material are present throughout the subarachnoid spaces along the sylvian fissures bilaterally, extending into the frontal sulci, parasagittal frontal lobes, tectum, and into the posterior fossa. Fat-fluid levels are present within the ventricular system, with evidence of obstructive hydrocephalus



**Figure 3:** Postoperative sagittal and coronal MRI of the brain (a and b) with evidence of gross total resection of the dermoid cyst along the anterior cranial fossa floor, with residual intraventricular and subarachnoid fat droplets



**Figure 4:** Histopathologic examination. Hematoxylin and eosin (H and E) stained sections  $\times 40$ ,  $\times 100$ , and  $\times 40$ , respectively, showing the typical histologic components of the dermoid cyst



causes aseptic meningitis with these associated symptoms by irritating the adjacent neurovascular structures shortly after rupture. Our patient, and previously reported patients with traumatic rupture of dermoid cysts, reported no other previous neurologic deficits or symptoms of mass effect prior to the traumatic event.<sup>[8,12,13]</sup>

CT scans of patients with dermoid cysts reveal well-circumscribed, homogeneously hypodense lesions due to the predominant lipid content of the tumor. Heterogeneous appearing dermoid tumors (like in this case) occur when there is a greater admixture of hair, calcification and epidermal debris. Hypodense areas found in the subarachnoid space and ventricles represent lipid droplets that have disseminated after initial rupture. Dermoid cysts do not enhance with the administration of contrast, and no edema is seen.<sup>[9,11,14]</sup> T1-weighted MRI shows a mass of high signal intensity due to the high lipid content, with the possibility of heterogeneous appearance due to hair, calcifications, and epithelial debris. The presence of high-intensity signal distributed throughout the subarachnoid and ventricular space is diagnostic of ruptured dermoid cysts.<sup>[9,11,14]</sup> Fat-fluid levels may also be seen within the ventricles.<sup>[9]</sup> In the setting of possible traumatic rupture, MRI is useful to distinguish fat droplet dissemination from the possibility of pneumocephalus. The lipid portion of these dermoid tumors lose their T1 intensity with fat suppression MRI, whereas intracranial air does not change its intensity.<sup>[8,12,13]</sup> MRI is also of greater utility than CT in determining the extent of spread of fat droplets after rupture, as well as the precise relationship of the tumor to adjacent neurovascular structures needed for adequate surgical planning.<sup>[13,14]</sup> Our patient tumor was characterized as a multiloculated hyperintense lesion with some areas of hypointensity, as well as fat-fluid levels and obstructive hydrocephalus [Figure 2].

In patients with large dermoid cysts with previously reported neurologic symptoms, surgical resection is recommended.<sup>[9,12]</sup> In the setting of traumatic rupture, two of the three previously reported cases opted for surgical management while one was managed conservatively with observation.<sup>[1,7,9,12]</sup> The patient who did not require surgical intervention had resolution of her symptoms (nausea, vomiting, mild headache) shortly after admission and physical examination was unremarkable.<sup>[13]</sup> Two other cases had a similar clinical picture, but the authors opted for surgical management.<sup>[8,12]</sup> In our case, the extensive amount of dispersed intracranial cyst contents associated with obstructive hydrocephalus, influenced our decision to treat the patient surgically. In all cases, complete surgical resection is preferable to minimize the risk for recurrence. However, the risk of injury to nearby neurovascular structures must be weighed against complete removal, as dermoid tumors may strongly adhere to the surrounding structures, which makes a good plane of dissection more

difficult to achieve, and the risk of damage to vital structures higher.<sup>[2,3,12,16]</sup>

In our case, as in others,<sup>[8]</sup> IV steroids were administered at presentation in order to alleviate the symptoms of chemical meningitis, with significant and prompt improvement of these symptoms. Steroids were continued postoperatively and eventually tapered. Some authors have proposed irrigation of the operative field with hydrocortisone to provide protection against aseptic meningitis; however, many point out that postoperative aseptic meningitis is often transient, and responds to systemic dexamethasone therapy.<sup>[3,10,16]</sup> The presence of extensive lipid droplet propagation does not warrant reoperation, as these patients do not experience new neurologic symptoms or clinical consequences when followed long-term.<sup>[3,11]</sup> Despite these measures, most patients with preoperative hydrocephalus (as in this case) eventually require shunting.<sup>[4,9]</sup>

Although recurrence after subtotal resection is extremely rare, close follow up is recommended. In the four reported cases of recurrence in the literature, times to presentation after initial resection were 5, 12, 13, and 66 months.<sup>[1,7,9,12]</sup> In the largest case series in the literature (8 patients), the authors followed several patients between 2 and 134 months postoperatively, without evidence of recurrence.<sup>[9]</sup> Imaging is a useful modality to monitor the status of these patients postoperatively. In most cases the disseminated fat lesions accumulated from rupture will remain stable in position without consequences.<sup>[3,11,12]</sup>

## CONCLUSION

Traumatic rupture of an intracranial dermoid cyst is an extremely rare event. We report the fourth such case in the literature, and outline a course of effective evaluation and management. Although CT is often adequate in making a diagnosis of this entity, MRI is superior for complete characterization of the extent of lipid dissemination, and for operative planning. IV steroids at the time of presentation decrease the symptoms of aseptic meningitis associated with rupture. Complete surgical resection is optimal, but must be weighed against the risk for injury to nearby vital structures. Hydrocephalus should be managed promptly, and monitored for closely in the perioperative period. The recurrence rate even following a subtotal resection is extremely low, but incompletely resected cysts should be followed routinely.

## REFERENCES

1. Arseni C, Danaila L, Constantinescu AI, Carp N, Decu P. Cerebral dermoid tumours. *Neurochirurgia (Stuttg)* 1976;19:104-14.
2. Berger MS, Wilson CB. Epidermoid cysts of the posterior fossa. *J Neurosurg* 1985;62:214-9.
3. Carvalho GA, Cervio A, Matthies C, Samii M. Subarachnoid fat dissemination after resection of a cerebellopontine angle dysontogenic cyst: Case report and review of the literature. *Neurosurgery* 2000;47:760-3.

4. Cavazzani P, Ruelle A, Michelozzi G, Andrioli G. Spinal dermoid cysts originating intracranial fat drops causing obstructive hydrocephalus: Case reports. *Surg Neurol* 1995;43:466-9.
5. El-Bahy K, Kotb A, Galal A, El-Hakim A. Ruptured intracranial dermoid cysts. *Acta Neurochir (Wien)* 2006;148:457-62.
6. Guidetti B, Gagliardi FM. Epidermoid and dermoid cysts. Clinical evaluation and late surgical results. *J Neurosurg* 1977;47:12-8.
7. Jamjoom AB, Cummins BH. The diagnosis of ruptured intracranial dermoid cysts. *Br J Neurosurg* 1989;3:609-12.
8. Kim IY, Jung S, Jung TY, Kang SS, Kim TS. Traumatic rupture of an intracranial dermoid cyst. *J Clin Neurosci* 2008;15:469-71.
9. Liu JK, Gottfried ON, Salzman KL, Schmidt RH, Couldwell WT. Ruptured intracranial dermoid cysts: Clinical, radiographic, and surgical features. *Neurosurgery* 2008;62:377-84.
10. Lunardi P, Missori P. Supratentorial dermoid cysts. *J Neurosurg* 1991;75:262-6.
11. Messori A, Polonara G, Serio A, Gambelli E, Salvolini U. Expanding experience with spontaneous dermoid rupture in the MRI era: Diagnosis and follow-up. *Eur J Radiol* 2002;43:19-27.
12. Park SK, Cho KG. Recurrent intracranial dermoid cyst after subtotal removal of traumatic rupture. *Clin Neurol Neurosurg* 2012;114:421-4.
13. Phillips WE 2<sup>nd</sup>, Martinez CR, Cahill DW. Ruptured intracranial dermoid tumor secondary to closed head trauma. Computed tomography and magnetic resonance imaging. *J Neuroimaging* 1994;4:169-70.
14. Smith AS, Benson JE, Blaser SI, Mizushima A, Tarr RW, Bellon EM. Diagnosis of ruptured intracranial dermoid cyst: Value MR over CT. *AJNR Am J Neuroradiol* 1991;12:175-80.
15. Stendel R, Pietila TA, Lehmann K, Kurth R, Suess O, Brock M. Ruptured intracranial dermoid cysts. *Surg Neurol* 2002;57:391-8.
16. Yasargil MG, Abernathy CD, Sarioglu AC. Microneurosurgical treatment of intracranial dermoid and epidermoid tumors. *Neurosurgery* 1989;24:561-7.

**Disclaimer:** The authors of this article have no conflicts of interest to disclose, and have adhered to *SN*'s policies regarding human/animal rights, and informed consent. Advertisers in *SN* did not ask for, nor did they receive access to this article prior to publication.