

# Influence of Surgically Induced Varicocele on Testicular Blood Flow, Temperature, and Histology in Adult Rats and Dogs

DAVID C. SAYPOL, STUART S. HOWARDS, TERRY T. TURNER, and EDWARD D. MILLER, JR., *Departments of Urology, Physiology, and Anesthesiology, University of Virginia School of Medicine, Charlottesville, Virginia 22908*

**ABSTRACT** Varicocele has been repeatedly implicated as a cause of infertility in selected men, although neither a causal relationship nor a mechanism has been documented. The purpose of this investigation was to create a varicocele model in animals and to study the subsequent alterations in testicular physiology. Secondary dilatation of the left internal spermatic vein was achieved either by partial ligation of the left renal vein in rats and dogs or by surgical destruction of the valve of the left testicular vein in a second group of dogs. 1 mo after partial ligation in the rats and 3 mo after partial ligation or valve destruction in the dogs, testicular blood flow was measured using Strontium 85 (SR-85)-labeled microspheres ( $15 \pm 1.1 \mu\text{m}$ ). Intratesticular temperature was measured with a Bailey needle probe thermometer and biopsies were obtained for histologic sections. Mean testicular blood flow in milliliters per minute per 100 g was significantly greater in the partially ligated rats; right testis control  $26 \pm 2$ , left testis control  $24 \pm 2$  compared to right testis experimental  $35 \pm 3$ , left testis experimental  $35 \pm 4$  ( $P < 0.02$ ). Dogs undergoing either partial vein ligation or valve destruction showed similar increases in mean testicular blood flow; right testis control  $8 \pm 1$ , left testis control  $8 \pm 1$  vs. right testis experimental  $16 \pm 3$ , left testis experimental  $18 \pm 4$  ( $P < 0.01$ ). The mean difference between intratesticular and intraperitoneal temperature in control rats was significantly higher ( $4.02 \pm 0.25^\circ\text{C}$  right testis,  $3.77 \pm 0.14^\circ\text{C}$  left testis), than rats who underwent partial vein ligation (right testis  $2.14 \pm 0.09^\circ\text{C}$ , left testis  $2.34 \pm 0.12^\circ\text{C}$ ) ( $P < 0.001$ ). Control dogs also had a significantly higher mean difference between intratesticular and rectal temperatures; (right testis control  $3.61 \pm 0.42^\circ\text{C}$ , left

testis control  $3.60 \pm 0.40^\circ\text{C}$ ) than the partially ligated or valve destruction dogs (right testis  $2.31 \pm 0.17^\circ\text{C}$ , left testis  $2.67 \pm 0.32^\circ\text{C}$ ) ( $P < 0.05$ ). In addition, histologic evaluation revealed abnormalities in spermatogenesis in some of the animals. Thus, venous dilatation secondary to partial vein ligation or testicular vein valve obliteration is followed by large bilateral increases in testicular blood flow in these two species. A consequence of this increased flow is an elevation in bilateral testicular temperature, which it is postulated, leads to impaired spermatogenesis in some of the animals. In selected men varicocele may impair spermatogenesis by a similar physiologic mechanism.

## INTRODUCTION

A varicocele is diagnosed in 39% of males evaluated at infertility clinics and is the most common identifiable cause of infertility in men (1). Each year ~20,000 men undergo varicocelectomy in hopes of eliminating a lesion about which little is known. The bilateral, deleterious effects of the unilateral lesion on testicular histology and semen are well described (2, 3). Elevated testicular temperature, reflux of adrenal or renal metabolites, hypoxia secondary to venous stasis, and hormonal imbalance have been proposed as mechanisms through which spermatogenesis is impaired. Data to support and refute each of these mechanisms is available and, consequently, the pathophysiology of varicocele remains obscure (4–12).

Two reports in the recent literature have shown significant elevations in venous pressure in the left testicular vein of patients with varicocele (13, 14). The cause of the increased venous tension is unknown, but has been ascribed to the absence or incompetence of valves, and/or arterial compression of the renal vein (14, 15). Recently, several investigators have surgically

*Received for publication 2 September 1980 and in revised form 12 March 1981.*

achieved varicoceles in monkeys and dogs using partial ligation of the left renal vein distal to the testicular vein (16, 17). Kay et al. (18) found sloughing of germinal epithelium, decreased sperm counts, and bilateral elevation of testicular temperature in monkeys 3 mo after unilateral partial ligation.

To date, there has been no well-controlled study examining the effects of unilateral increased testicular venous pressure on the physiology and morphology of the testes. In the present study, partial ligation of the left renal vein or obliteration of the left testicular vein valve was used to induce varicoceles in two animal species. After these manipulations, testicular blood flow, temperature, and histology were determined.

## METHODS

### Rats

Mature Sprague Dawley rats (weighing 350–500 g) were obtained from institutional vivarium sources and acclimated for 1 wk prior to experimental use. Control and experimental animals were age- and weight-matched.

*Group I rats, control.* Seven consecutive animals were weighed and anesthetized with 1.2% inspired halothane delivered via face cone. Using pressure monitoring, PE50 polyethylene tubing was passed through the right carotid artery into the left ventricle. A second piece of PE 50 tubing was passed into the right femoral artery in odd-numbered animals and into the left femoral artery in even-numbered animals. The site was alternated to eliminate localizing effects. Blood pressure was monitored continuously via the femoral artery catheter using a Statham P23 Db pressure transducer (Gould-Statham Instruments, Inc., Hato Rey, Puerto Rico) and Brush Mark 260 (Gould Inc., Cleveland, Ohio) recorder. Rectal temperature was maintained at 37°C using a heating lamp.

Tissue blood flow and cardiac output were determined using Strontium 85 (SR-85)-labeled microspheres ( $15 \pm 1.1 \mu\text{m}$ ) with a specific activity of 9.0 mCi/g suspended in 10% Dextran containing 0.05% Tween 80. After 5 min of agitation, 0.15 ml of microsphere suspension (40,000–60,000 microspheres) was drawn into a plastic syringe designed for placement in a gamma radiation counting vial, and analyzed in a Beckman Biogamma counter (Beckman Instruments, Inc., Fullerton, Calif.) (at the energy spectrum for the isotope). This suspension was injected into the left ventricular catheter over 20 s and flushed with 1.0 ml saline (0.9%). Blood was withdrawn from the femoral artery catheter using a constant withdrawal sage pump (Orion Research Inc., Cambridge, Mass.) for 10 s before the injection of microspheres, during the injection, and thereafter for a total withdrawal time of 70 s (~0.8 ml). The blood sample was placed in a preweighed counting vial and the withdrawal rate was determined. The animals were killed using a potassium chloride injection into the left ventricle.

The right and left testicles, kidneys, epididymides, prostate, and a section of the liver were removed, weighed, and analyzed for radioactivity in the gamma counter along with the blood sample and empty injection syringe. Cardiac output was determined using the formula:

$$\text{CO} = \frac{\text{R} \times \text{I}}{\text{B}},$$

where CO represents cardiac output ml/min; R, rate of withdrawal of blood ml/min; I, number of counts injected; B, number of counts blood sample. Blood flow to the tissue was calculated using the formula:

$$\text{BF} = \frac{\text{R} \times \text{T}}{\text{B}},$$

where BF, blood flow in milliliters per minute; R, rate of withdrawal of blood in milliliters per minute; B, number of counts blood sample; T, number of counts in tissue sample. Blood flow to each organ was divided by the weight of that organ to determine flow per gram of tissue.

*Group II rats, partial vein ligation.* Six animals were anesthetized using sodium pentobarbital 50 mg/kg i.p. Through a midline incision, the left renal vein was partially ligated distal to the left adrenal and testicular veins, to an external diameter of 1 mm. The abdomen was closed, the animals were returned to the vivarium, and 1 mo later they underwent the same protocol as group I rats (control). Dilatation of the left internal spermatic vein was graded by inspection during autopsy as no dilatation, moderate dilatation, or marked dilatation.

*Group III rats, sham.* Three animals were anesthetized as in group II rats (partial ligation). Following laparotomy, the left renal vein was isolated but no ligation was placed. 1 mo later the animals underwent the same protocol as group I rats (control).

*Group IV rats, temperature and histology controls.* Nine rats were anesthetized with sodium pentobarbital 50 mg/kg i.p. 15 min later, the ambient, right intratesticular, left intratesticular, and intraperitoneal temperatures were measured with a 23-gauge needle probe thermometer (Bailey Instruments Inc., Saddle Brook, N. J.) The difference between intraperitoneal and intratesticular temperature was recorded for each testicle. Biopsies of each testicle were fixed in Bouin's solution for 24 h, washed in 70% ethyl alcohol, embedded in paraffin, and stained with hematoxylin and eosin. The prepared slides were coded and examined by an independent histologist in a single-blind scoring procedure. After subjective observation, all testes were noted as being normal or abnormal (epithelial disorganization). In each histologic section of the right and left testis, 10 tubules were randomly selected and the presence of late spermatids or spermatozoa within the tubule was noted. The percentage of tubules having either cell type within the lumen was recorded for both testes in experimental and control animals. This data was subjected to the arc-sine transformation prior to statistical evaluation by Student's *t* test.

*Group V rats, temperature and histology after partial vein ligation.* 12 rats underwent left renal vein partial ligation as in group II rats (partial ligation). 1 mo later temperatures were measured and histologic sections were obtained as in group IV rats (control). A laparotomy incision was made in each animal and dilatation of the left testicular vein was graded.

### Dogs

Adult male mongrel dogs were obtained from the university vivarium. Dogs whose testicles appeared atrophic when palpated were not used.

*Group I dogs, control.* Eight dogs were anesthetized with sodium pentobarbital 30 mg/kg i.v. An 8 Fr. polyurethane catheter was passed through the right internal carotid artery into the left ventricle using pressure monitoring. A second 8 Fr. polyurethane catheter was inserted into the right

femoral artery in odd-numbered dogs and into the left femoral artery in even-numbered dogs. Blood pressure and temperature were monitored as in group I rats (control).

Blood flow to both testicles and a cortical portion of each kidney was determined using Strontium 85 microspheres in a manner similar to group I rats (control). 2 ml of SR-85 (500,000–800,000 microspheres) were drawn into a 3-ml plastic syringe after 5 min agitation. This suspension was injected over 5 s into the left ventricular catheter. Blood was withdrawn from the femoral artery catheter using a Harvard pump (Harvard Apparatus Co., Inc., S. Natick, Mass.) at the rate of 9.89 ml/min beginning 10 s before the injection of microspheres, during the injection, and thereafter for a total withdrawal time of 80 s.

10 min after injection of the microspheres, the ambient, right intratesticular, left intratesticular, and rectal temperatures were measured and recorded using the Bailey needle-probe thermometer.

The dogs were killed using intraventricular potassium chloride and the right and left testes and cortical sections of the right and left kidneys were weighed and analyzed for radioactivity.

**Group II dogs, left testicular vein valve obliteration.** Seven dogs were anesthetized as in group I dogs (control). After sterile preparation, a wedge biopsy was taken from the right and left testes and processed as in group IV rats (control). Through a midline incision, vascular control of the proximal and distal left renal vein, left renal artery, left testicular vein, and left adrenal vein was obtained. Using 3× loupes for visual magnification, the renal vein was opened and the valve overlying the left testicular vein was obliterated by sharp dissection. The left renal vein was closed, the peritoneum was approximated over the renal pedicle and the abdomen was closed in two layers. The animals were returned to the vivarium.

3 mo later, testicular blood flow and temperature were measured as in group I dogs (control) and histologic sections of both testes were obtained and processed as in group IV rats (control). Left testicular vein dilatation was graded as in group II rats (partial ligation).

**Group III dogs, partial vein ligation.** Four dogs were anesthetized as in group I dogs (control) and bilateral testicular biopsies were taken. Through a midline incision, the left renal vein was partially ligated distal to the left adrenal and testicular veins, to an external diameter of 3 mm.

3 mo later, these dogs underwent the same protocol for determination of blood flow, temperature, histology, and degree of dilatation as in group II dogs (valve obliteration).

Data were analyzed statistically using Student's *t* test.

## RESULTS

### Rats

The change in testicular blood flow in group II rats (partial ligation) compared with group I rats (control) is shown in Table I. This 38% increase in testicular blood flow per gram of tissue to both testicles was significant ( $P < 0.02$ ) and not associated with changes in epididymal, prostatic, renal, or hepatic blood flow. All animals in group II rats (partial ligation) had moderate or marked dilatation of the left internal spermatic vein (Fig. 1).

Mean body weight, testicular weight, cardiac output, and blood pressure were the same in group I rats (control) and group II rats (partial ligation) (Table II). Absolute blood flow to each testicle as a percentage of cardiac output was significantly higher ( $P < 0.05$ ) in group II rats (Table II). Testicular blood flow in group III rats (sham) was the same as group I rats (control).

Of 12 animals in group V rats (partial ligation), 9 demonstrated mild or moderate left testicular vein dilatation. The mean difference between intraperitoneal and intratesticular temperature in these rats was significantly lower ( $P < 0.001$ ) than the mean difference for each testis in group IV rats (control) (Table III). The mean temperature difference in the three rats who demonstrated no left testicular vein dilatation was the same as group IV rats (control).

All of group IV rats (control) and the three animals from group V rats (partial ligation) with no left testicular vein dilatation had normal testicular histology. Of the nine animals in group V rats (partial ligation) with left testicular vein dilatation, three showed minimal bilateral disorganization of germinal epithelium with no decrease in numbers of mature spermatozoa. The remainder had normal histology.

### Dogs

Four of seven dogs in group II dogs (valve obliteration) and three of four dogs in group III dogs (partial

TABLE I  
Rats: Organ Blood Flow\*

	R Testis	L Testis	R Epididymis	L Epididymis	R Kidney	L Kidney	Prostate	Liver
Group I rats <i>n</i> = 7 (Control)	26±2	24±2	13±2	12±2	584±45	541±35	33±6	31±6
Group II rats <i>n</i> = 6 (Partial ligation)	35±3	35±4	14±1	13±3	601±61	557±62	37±7	35±5
Level of significant difference	$P < 0.02$	$P < 0.02$	NS†	NS	NS	NS	NS	NS

\* Values expressed as mean±SEM in milliliters per minute per 100 grams of tissue.

† Not significantly different.

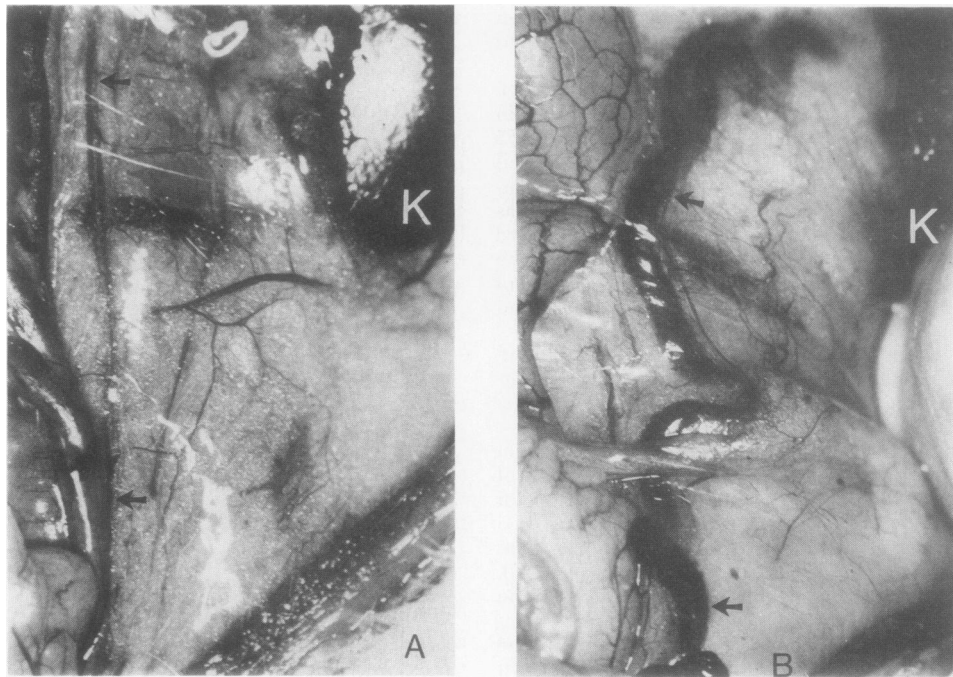


FIGURE 1 (a) Left testicular vein in rat prior to partial ligation of the left renal vein (10×). K: Kidney; arrows indicate left spermatic vein. (b) Left testicular vein in rat 1 mo after partial ligation of the left renal vein (10×). K: kidney; arrows indicate left spermatic vein.

ligation) demonstrated mild or moderate left testicular vein dilatation 3 mo after surgery. Mean testicular blood flow in these animals was significantly higher ( $P < 0.01$ ) than group I dogs (control) for each testis (Table IV). The four animals that showed no left testicular vein dilatation had a mean testicular blood flow that did not differ from group I dogs (control). All animals in group I, II, and III dogs (control, valve obliteration, and partial ligation, respectively) had similar mean renal cortical blood flow (Table IV).

Mean testicular weight in groups II and III dogs with left testicular vein dilatation was significantly lower ( $P < 0.05$ ) for each testis than mean testicular weight in group I dogs (control). This occurred despite no significant difference in mean body weight in groups II and III dogs with dilatation compared to group I dogs (control) (Table V).

The mean difference between rectal temperature and testicular temperature was significantly lower ( $P < 0.01$ ) in groups II and III dogs with left testicular

TABLE II  
Rats: Animal Weight, Testicular Weight, Cardiac Output, Blood Pressure, and Flow as Percentage of Cardiac Output\*

	Rat weight	R Testicular weight	L Testicular weight	Cardiac output	Blood pressure	Percent cardiac output to	
						R Testis	L Testis
	g	g	g	ml/min	mm Hg		
Group I rats $n = 7$ (Control)	419±9	1.78±0.06	1.78±0.05	111±7	100±2	0.42±0.04	0.39±0.04
Group II rats $n = 6$ (Partial ligation)	437±12	1.90±0.04	1.86±0.06	120±14	98±5	0.58±0.08	0.57±0.07
Level of significant difference	NS‡	NS	NS	NS	NS	$P < 0.05$	$P < 0.05$

\* Values expressed as mean±SEM.

‡ Not significantly different.

TABLE III

Rats: Difference between Intratesticular and Intraperitoneal Temperature (Ambient Temp. 26.4°C)\*

	Right testis	Left testis
Group IV (Control) <i>n</i> = 9		
Mean intraperitoneal temp.		
37.4±0.2	4.02±0.25	3.77±0.14
Group V (Partial ligation) <i>n</i> = 9‡		
Mean intraperitoneal temp.		
37.2±0.1	2.14±0.09	2.34±0.12
Level of significant difference	<i>P</i> < 0.001	<i>P</i> < 0.001

\* Values expressed as mean±SEM.

‡ Includes only animals with left testicular vein dilatation.

vein dilatation than group I dogs (control dogs) (Table VI). Those dogs in groups II and III in whom there was no venous dilatation had a mean temperature difference that was the same as group I dogs (control).

All of the animals in groups II and III dogs had normal testicular histology prior to partial left renal vein ligation or left testicular vein valvular obliteration. Of the seven animals in groups II and III dogs who had left testicular vein dilatation, three animals from group II dogs and two animals from group III dogs showed bilateral disorganization of germinal epithelium and a decrease in percentage of seminiferous tubules with mature spermatozoa in their lumina. In control animals 59.6±2.5 and 56.2±4.0% of seminiferous tubules in the right and left testis, respectively, contained late spermatids or spermatozoa in their lumina. In the affected animals of groups II and III these mean percentages were 42.5±7.6 and 29.5±9.2, respectively. These values were significantly different (*P* < 0.05) from their respective controls. The remaining dogs with left testicular vein dilatation had normal histology bilaterally. Of the four dogs from groups II and III dogs who had no left testicular vein dilatation, two animals demonstrated bilateral disorganization of germinal epithelium and a slight reduction in number of mature spermatozoa. The remaining two animals had normal bilateral testicular histology.

## DISCUSSION

Following Tulloch's report (19) in 1952 of improved fertility in a patient following varicocelectomy, clinicians have become increasingly aware of an association between male subfertility and varicocele. Although impaired bilateral seminiferous tubular morphology is well documented in unilateral varicocele, it is unclear whether there is a causal relationship between the venous abnormality and the testicular dysfunction. The literature is replete with poorly documented speculations implying that varicocele may interfere with spermatogenesis by various mechanisms. This study provides the first systematic, well-documented investigation of this phenomenon and strongly supports the hypothesis that a unilateral varicocele has a deleterious bilateral impact on spermatogenesis. Furthermore, the data suggest that this effect may be mediated by increases in testicular blood flow and temperature.

The values for testicular blood flow in our control rats (26±2 ml/min per 100 g) are identical to previous measurements in our lab (20) and are similar to that reported by Jaffe and Free (21) using a friction flowmeter (22.6±3.8 cm<sup>3</sup>/min per 100 g) (21). The use of radioactively labeled microspheres for measurements of cardiac output and organ blood flow was first described by Rudolph and Heymann (22) and has proved to be an accurate method that does not alter hemodynamics. Damber and Janson (23) have used labeled microspheres and Xe-133 clearance for determination of testicular flow in rats and obtained results similar to our control values using both methods. Using direct venous cannulation in dogs, several authors have obtained values for flow within the range of our findings in dogs (24). No reports of blood flow determinations using a friction flowmeter or microspheres in dogs have been found.

The bilateral increase in testicular blood flow using partial ligation in the rat and partial ligation or valve obliteration in the dog was unexpected and intriguing. In the rat, both the flow per gram of tissue and the absolute flow as a percentage of cardiac output were elevated. This was associated with no change in testic-

TABLE IV  
Dogs: Organ Blood Flow\*

	R Testis	L Testis	R	L
			Renal cortex	Renal cortex
Group I dogs (Control) <i>n</i> = 8	8±1	8±1	808±102	714±59
Groups II and III dogs (Partial ligation and valve obliteration) <i>n</i> = 7‡	16±3	18±4	712±151	757±114
Level of significant difference	<i>P</i> < 0.01	<i>P</i> < 0.01	NS§	NS

\* Values expressed as mean±SEM in milliliters per minute per 100 grams of tissue.

‡ Includes only animals with left testicular vein dilatation.

§ Not significantly different.

TABLE V  
Dogs: Animal Weight and Testicular Weight\*

	Dog weight	R testicular weight	L testicular weight
	kg	g	g
Group I dogs (Control) <i>n</i> = 8	16.8±0.8	14.5±1.2	15.6±1.4
Groups II and III dogs (Partial ligation and valve obliteration) <i>n</i> = 7†	20.4±2.1	9.6±1.9	9.5±1.9
Level of significant difference	NS‡	<i>P</i> < 0.05	<i>P</i> < 0.05

\* Values expressed as mean±SEM.

† Includes only animals with left testicular vein dilatation.

‡ Not significantly different.

ular weight. Testicular blood flow in the dog was also increased, but was associated with some degree of testicular atrophy implying a decrease in tubular size. (Cardiac output was not measured so absolute flow could not be assessed.) Presumably, the 3-mo lesion in the dog compared to a 1-mo lesion in the rat allowed for prolonged damage and atrophy and, indeed, histologic sections showed more pathologic changes in the dogs.

Since this is the first report of this finding, the mechanism and how it might affect testicular function is speculative. Although evidence has been presented for reflux of vasoactive substances from adrenal or renal tissue into the testicular vein in human varicocele (4, 25), much of it is not convincing because controls were not used or poorly selected. Additionally, other studies have found that the transfer of substances from the testicular vein to the testicular artery is minimal (26).

The concomitant increase in bilateral testicular temperature in both animal models might implicate temperature as the initial event leading to vasodilatation and increased blood flow. Perhaps the venous

TABLE VI  
Dogs: Difference between Intratesticular and Rectal Temperature (Ambient Temp. 22.2–22.6°C)\*

	Right testis	Left testis
Group I dogs (Control) <i>n</i> = 8 Mean rectal temp. 38.4±0.2	3.61±0.42	3.60±0.40
Groups II and III dogs (Partial ligation and valve obliteration) <i>n</i> = 7† Mean rectal temp. 38.5±0.2	2.31±0.17	2.67±0.32
Level of significant difference	<i>P</i> < 0.01	<i>P</i> < 0.05

\* Values expressed as mean±SEM.

† Includes only animals with left testicular vein dilatation.

lesion interferes with the vascular countercurrent heat exchange; the testes become warmer and blood flow increases. Previous studies have shown that heating of the testes 8–10°C above normal scrotal temperature caused a marked increase in testicular blood flow (27). However, when the testes are artificially warmed to temperatures equal to abdominal temperature (3–4°C above normal scrotal temperature) there is no increase in blood flow (28). This leads us to hypothesize that increased flow is the initial response to the venous lesion in our model, and is followed by chronic temperature elevation.

The existence of arterio-venous shunting in the testis has not been proven, as no anatomic basis has yet been identified. There is evidence however, that total blood flow to the testis is greater than nutrient or capillary blood flow. Godinho and Setchell (29) found that capillary blood flow accounted for only 66% of total testicular flow. Further data in support of arterio-venous shunting comes from Nguyen (30) who noted testicular blood flow was 30% higher in rabbits using 50-μm radioactive microspheres as opposed to 10-μm microspheres.

It is possible that in our model, increased testicular flow may in part be spurious. If there were arterio-venous shunting in the control animals, a percentage of the 15-μm spheres might be shunted out of the testes and control flow would represent capillary flow rather than total testicular flow. After partial venous ligation or valve destruction, venous hemodynamics, possibly from elevated venous pressure, might be affected in a way that prevents arterio-venous shunting, thus trapping an increased number of microspheres, and perhaps increasing total capillary blood flow. The elimination of shunting and the increased flow would be followed by chronic temperature elevation and its well-documented, unfavorable effects on the seminiferous tubules. Recent evidence by Nakamura and Hall (31) suggests that this minimal temperature elevation above that of the normal scrotal environment slows the *in vitro* incorporation of amino acids by spermatids, thus interfering with normal protein synthesis.

What remains enigmatic is an adequate explanation for the bilateral effects of the unilateral venous lesion. The demonstration of collateral venous circulation to the right testis in humans has heretofore been the accepted, but unproven explanation. Although it is possible that there is venous hypertension in the right testicular vein secondary to crossover between the left testicular venous system, most venographic studies in patients with varicocele have shown venous crossover that is limited to superficial veins of the pubis and upper scrotum.

Although our data and the proposed mechanism await documentation in the human, several conclusions can be made. Partial ligation of the left renal vein distal

to the left testicular vein leads to hemodynamic changes that result in an increase in measured testicular blood flow and a decrease in bilateral abdominal testicular temperature differences. Associated with this temperature elevation are histologic changes manifest in both testes in some of the animals. In addition, surgical elimination of the valvular mechanism in the left testicular vein produces changes identical to partial renal vein ligation. Although hemodynamics in man (upright posture) are perhaps different, an effective animal model for the study of varicocele exists and presumably the subfertility in human males is a consequence of venous abnormalities similar to those induced in our models. The possibility that increased testicular capillary flow and elevation of testis temperature is involved in idiopathic infertility warrants further investigation.

#### ACKNOWLEDGMENT

This work was supported in part by National Institutes of Health Career Development Award 1-K04-HD00108-01 and grant R23GM24313.

#### REFERENCES

- Dubin, L., and R. D. Amelar. 1971. Etiologic factors in 1294 consecutive cases of male infertility. *Fertil. Steril.* **22**: 469-474.
- Agger, P., and S. G. Johnsen. 1978. Quantitative evaluation of testicular biopsies in varicocele. *Fertil. Steril.* **29**: 52-57.
- MacLeod, J. 1965. Seminal cytology in the presence of varicocele. *Fertil. Steril.* **16**: 735-757.
- Comhaire, F., and A. Vermeulen. 1974. Varicocele sterility: cortisol and catecholamines. *Fertil. Steril.* **25**: 88-95.
- Charny, C. W., and S. Baum. 1968. Varicocele and infertility. *J. Am. Med. Assoc. (JAMA)*. **204**: 1165-1168.
- Mobley, D. F. 1974. Left spermatic vein cortisol in subfertile men with varicocele. *Urology*. **3**: 461-464.
- Comhaire, F., and A. Vermeulen. 1975. Plasma testosterone in patients with varicocele and sexual inadequacy. *J. Clin. Endocrinol. Metab.* **40**: 824-829.
- Swerdloff, R. S., and P. C. Walsh. 1975. Pituitary and gonadal hormones in patients with varicocele. *Fertil. Steril.* **26**: 1006-1012.
- Donohue, R. E., and J. S. Brown. 1969. Blood gases and pH determinations in the internal spermatic veins of subfertile men with varicocele. *Fertil. Steril.* **20**: 365-369.
- Netto, N. R., Jr., G. C. Lemos, and G. M. DeGoes. 1977. Varicocele: relation between anoxia and hypospermatogenesis. *Int. J. Fertil.* **22**: 174-178.
- Zorgniotti, A. W., and J. MacLeod. 1973. Studies in temperature, human semen quality, and varicocele. *Fertil. Steril.* **24**: 854-863.
- Tessler, A. N., and H. P. Krahn. 1966. Varicocele and testicular temperature. *Fertil. Steril.* **17**: 201-203.
- Shafik, A., and G. A. M. Bedeir. 1980. Venous tension patterns in cord veins. I. In normal and varicocele individuals. *J. Urol.* **123**: 383-385.
- Zerhouni, E. A., S. S. Siegelman, P. C. Walsh, and R. I. White. 1980. Elevated pressure in the left renal vein in patients with varicocele: preliminary observations. *J. Urol.* **123**: 512-513.
- Ahlberg, N. E., O. Bartley, N. Chidekel, and A. Fritjofsson. 1966. Phlebography in varicocele scroti. *Acta Radiol.* **4**: 517-528.
- Al-Juburi, A., K. Pranikoff, K. A. Dougherty, R. L. Urry, and A. T. K. Cockett. 1979. Alteration of semen quality in dogs after creation of varicocele. *Urology*. **13**: 535-539.
- Harrison, R. M., R. W. Lewis, and J. A. Dollar. 1980. Early changes following surgically induced varicocele in monkeys. *J. Androl.* **1**: 79.
- Kay, R., N. J. Alexander, and W. L. Baugham. 1979. Induced varicoceles in Rhesus monkeys. *Fertil. Steril.* **31**: 195-199.
- Tulloch, W. S. 1952. A consideration of sterility factors in the light of subsequent pregnancies: subfertility in the male. *Trans. Edinburgh. Obstet. Soc.* **59**: 29-34.
- Saypol, D. C., T. T. Turner, and S. S. Howards. 1980. The effect of surgically induced cryptorchidism on testicular blood flow. *Surgical Forum.* **31**: 569-572.
- Jaffe, R. A., and M. J. Free. 1972. A miniature friction flowmeter for use in rat testicular artery and other small vessels. *J. Appl. Physiol.* **32**: 571-573.
- Rudolph, A. M., and M. A. Heymann. 1967. The circulation of the fetus in utero. *Circ. Res.* **21**: 163-184.
- Damber, J-E., and P. O. Janson. 1977. Methodological aspects of testicular blood flow measurements in rats. *Acta Physiol. Scand.* **101**: 278-285.
- Setchell, B. P. 1970. Testicular fluids. In *The Testis*. A. D. Johnson, W. R. Gomes, and N. L. Vandemark, editors. Academic Press, Inc., New York. Vol. 1. 140.
- Caldamone, A. A., A. Al-Juburi, and A. T. K. Cockett. 1980. The varicocele: elevated serotonin and infertility. *J. Urol.* **123**: 683-685.
- Jacks, F., and B. P. Setchell. 1973. A technique for studying the transfer of substances from venous to arterial blood in the spermatic cord of wallabies and rams. *J. Physiol. (Lond.)*. **233**: 17P-18P.
- Glover, T. D. 1966. The influence of temperature on flow of blood in the testis and scrotum of rats. *Proc. Roy. Soc. Med.* **59**: 765-766.
- Waites, G. M. H., B. P. Setchell, and D. Quinlan. 1973. Effect of local heating of the scrotum, testes, and epididymides of rats on cardiac output and regional blood flow. *J. Reprod. Fertil.* **34**: 41-49.
- Godinho, H. P., and B. P. Setchell. 1975. Total and capillary blood flow through the testis of anesthetized rams. *J. Physiol. (Lond.)*. **251**: 19P-20P.
- Nguyen-Duc-Kien. 1975. Testicular blood flow and testosterone secretion rates in rabbit and rat. Ph.D. Dissertation, Ohio State University, Columbus.
- Nakamura, M., and P. F. Hall. 1980. The mechanism by which body temperature inhibits protein biosynthesis in spermatids of rat testes. *J. Biol. Chem.* **255**: 2907-2913.