

Diamine Oxidase (Histaminase)

A CIRCULATING MARKER FOR RAT INTESTINAL MUCOSAL MATURATION AND INTEGRITY

GORDON D. LUK, THEODORE M. BAYLESS, and STEPHEN B. BAYLIN, *Departments of Medicine and Oncology, Johns Hopkins University School of Medicine, Johns Hopkins Hospital, Baltimore, Maryland 21205*

ABSTRACT Diamine oxidase (histaminase) is an enzyme found in high concentrations in the intestinal mucosa of humans and other mammalian species. We investigated whether plasma and mucosal levels of diamine oxidase activity reflect both the maturational status of the mucosa during its development in the newborn rat and the degree of mucosal damage during its injury in the adult rat. Litter mates were reared under identical conditions and killed at different ages from day 0 to day 40 after birth. Diamine oxidase in the small intestine was low at birth, increased gradually with age, reached a peak at 22 d, and then remained at normal adult levels, similar to the developmental patterns of maltase and sucrase. Plasma diamine oxidase rose in parallel with intestinal levels ($n = 500$, $r = 0.84$, $P < 0.001$), reached a peak at 24 d, and then remained at normal adult levels. Diamine oxidase activity in 15 nonintestinal tissues was $<5\%$ of ileal mucosal activity, and no nonintestinal activities showed increase with age. Adult rat intestinal loops were perfused with hyperosmolar sodium sulfate solutions to produce selective damage to villus mucosa. With increasing mucosal damage, there was a progressive decrease in the enzyme activities studied; first, lactase levels fell, then maltase and sucrase, and finally mucosal and plasma diamine oxidase activity levels fell. The decrease in plasma diamine oxidase reflected the degree of mucosal damage ($n = 29$, $P < 0.04$). Diamine oxidase activity is thus unique among intestinal mucosal enzymes studied to date in that circulating levels can serve as a marker of mucosal maturation and integrity.

Part of this work was presented in abstract form (1979. *Gastroenterology*. 76: 1189.) before the American Gastroenterological Association, New Orleans, May 1979.

Received for publication 7 December 1979 and in revised form 8 February 1980.

INTRODUCTION

The study of diseases of the intestinal epithelium (mucosa) has always been limited by the need for mucosal biopsies to examine the histology and the enzymes characteristic of an intact, mature mucosa. We now report that the activity of diamine oxidase (DAO),¹ an enzyme found in high concentrations in the intestinal mucosa of humans and other mammalian species, may be the first known circulating marker for monitoring mucosal maturation. DAO activity is measurable in plasma, and the values obtained uniquely reflect the maturational status of the mucosa during its development in the newborn rat and the degree of mucosal damage during its injury in the adult rat.

At birth, the rat small intestine contains proliferating crypts but only short villi; the activities of most digestive enzymes, including the disaccharidases sucrase and maltase, are present only at low levels. In the first 3 postnatal wk the crypts elongate, cell proliferation increases, the villi lengthen, and mature mucosal cells bearing sucrase, maltase, and other brush border enzymes appear (1-3). These enzyme activities have been used to follow mucosal development and function, but can be measured only in the intestinal tissue and not in plasma, and therefore require mucosal biopsies to determine their levels (4-6).

Plasma DAO (EC 1.4.3.6) activity, known also as histaminase activity, appears to come primarily from the small intestine in many mammalian species (7). In the nonpregnant rat, the small intestine is the tissue containing the highest DAO activity, and the increase in circulating DAO that occurs following heparin administration appears to come primarily from the small intestine (8, 9). In man, a similar rise in plasma DAO

¹ Abbreviation used in this paper: DAO, diamine oxidase.

is seen after heparin infusion, and the small intestine is again the tissue containing the highest DAO activity (10, 11). However, the potential value of DAO as an index of intestinal function has not been investigated.

Our laboratory previously established (12, 13) that the mucosa is the site of highest DAO activity in the rat small intestine. This mucosal activity is associated with the mature villus-tip absorptive cells rather than the proliferating crypt cells, but unlike other villus-tip cell biochemical markers, DAO activity is not confined to the brush border region of these cells (12). Subcellular fractionation studies have localized rat mucosal DAO in the soluble fraction (14). Immunohistochemical studies in our laboratory have revealed a similar distribution in human small intestinal mucosa (15). Having found this relation of DAO to mature mucosal cells in the adult rat, we wondered whether the appearance of DAO might reflect the characteristic postnatal developmental changes of small intestinal mucosa in the newborn rat (1-3), whether plasma DAO might serve as a marker of mucosal maturity during this development, and whether plasma DAO might also monitor the degree of damage to mature mucosa from exposure to hyperosmolar sodium sulfate solutions (16).

METHODS

Newborn rat mucosal maturation studies. Timed-pregnant Wistar-Lewis rats were purchased from Charles River Breeding Laboratories, Wilmington, Mass. The animals were observed at 2-h intervals and the time of birth of pups was recorded; litters were culled to 10 pups and the day of birth termed day 0. Animals were housed with 12/12-h light/dark (0800/2000) cycles; the dams were given regular Purina laboratory rat chow (Ralston Purina Co., St. Louis, Mo.) and water ad lib., and the pups were weaned on day 21. Pups were sacrificed daily in groups of three at 0800 from day 0 to day 40. Pups were anesthetized with methoxyflurane. Blood was withdrawn by cardiac puncture and plasma separated in a refrigerated centrifuge. The small intestine was stripped of its mesentery from the ligament of Treitz to the ileocecal junction and removed. Other tissues were then removed and the animals killed by cervical dislocation. The small intestine was divided into thirds; the distal third was designated ileum. Whole intestinal homogenate was used for pups 10 d or younger and intestinal mucosal scrapings used for older pups. Both whole intestinal homogenate and mucosal scrapings were used in animals aged 10-14 d, and the results obtained with the two different preparative methods were similar. Plasma and mucosa from 12 normal, 3-mo-old female Wistar-Lewis rats were also obtained for measurement of normal adult levels of DAO and disaccharidases. DAO was assayed by the method of Beaven and Jacobsen as described in our previous studies (13), measuring tritiated water formed upon deamination of β [3 H]histamine; results are reported as 1 U = 1 pmol histamine deaminated per hour at 37°C. Disaccharidases were assayed by the method of Dahlqvist (17), measuring glucose formed upon hydrolysis of the appropriate substrates of sucrose, maltose, and lactose; results are reported as 1 U = 1 μ mol substrate hydrolyzed per

minute at 37°C. Protein determination was done by the method of Lowry et al. (18). Linear regression analysis was used to evaluate the correlation between plasma and mucosal DAO activities.

Adult rat mucosal injury studies. Adult 200-g Wistar-Lewis rats were purchased from Charles River Breeding Laboratories. Animals were anesthetized with intraperitoneal pentobarbital. Pretreatment blood was obtained from the tail vein. Intestinal loops (35-40 cm) consisting of the entire small intestine except for 5 cm of proximal jejunum, with their blood supply intact, were prepared and left in the peritoneal cavity. The 5-cm proximal jejunal segments were used as controls, as were proximal jejunal segments in untreated sham-operated rats. Loops were perfused with sodium sulfate solutions of 700-, 1,400-, or 2,100-mosM concentrations for 30 or 60 min, at a pressure of 5 cm of water. At the end of the perfusion period, the loops were flushed with normal saline and the animals kept anesthetized for another 6 h. Then blood was removed by cardiac puncture, the intestinal loops were also removed, and the animals were sacrificed. 5-mm sections of the control segments and the proximal segments of the loops were fixed in formalin and Hollande's fixative for histologic studies, and the adjacent sections used for enzyme assays. Disaccharidases and DAO were then assayed exactly as described in the previous section. Student's *t* test (unpaired) was used to analyze the difference in enzyme activities associated with varying degrees of mucosal damage; and linear regression analysis was used to evaluate the correlation between plasma and mucosal DAO activities.

RESULTS

Mucosal maturation studies. Fig. 1 shows the postnatal development pattern of maltase activity in the ileal (distal third of small intestine) mucosa. Activity was low at birth, increased gradually with age, and reached adult levels at 3 wk. Maltase activity in the middle third was similar and that in the proximal third was about 50% higher; activities in all segments increased with age in a similar manner. Sucrase activity reached adult levels and lactase fell to postweaning levels at 3 wk also. These findings are similar to those previously described by other investigators (1-3).

Fig. 2 shows the postnatal development patterns of DAO in the ileum, plasma, and 15 other nonintestinal tissues. DAO in the ileum was low at birth, increased gradually with age, reached a peak at 22 d, and then re-

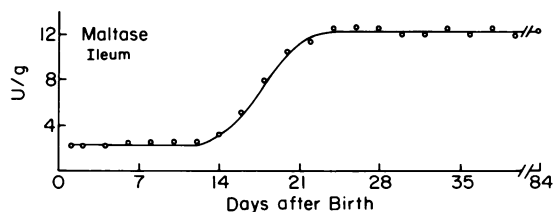


FIGURE 1 Developmental pattern of maltase in the newborn rat ileum. Each point represents the mean of data from at least eight animals. 1 U = 1 μ mol maltose hydrolyzed per minute at 37°C. (Normal levels in the adult rat are 10-34 U/g wet wt.)

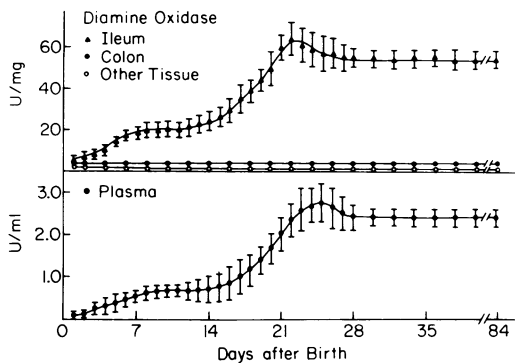


FIGURE 2 Postnatal developmental patterns of DAO in the ileum, colon, and 15 other tissues (top), and in the plasma (bottom) of the newborn rat in the first 40 d of life. Each point represents the mean of data from 20 animals. The bars indicate \pm SE. 1 U = 1 pmol histamine deaminated per hour at 37°C. Normal levels in the adult rat are 1.4–2.8 U/ml for plasma, and 32–63 U/mg protein for ileum.

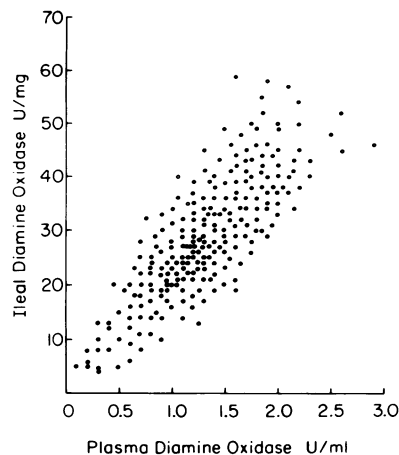


FIGURE 3 Correlation of plasma DAO with intestinal DAO in the same animal. Each point represents the results from one to three animals ($n = 500$, $r = 0.84$, $P < 0.001$).

mained at normal adult levels (32–63 U/mg protein). DAO activity in the proximal and middle third of the small intestine was about 20 and 10% lower, respectively, but increased in a similar fashion. Thus, the pattern of increasing levels of intestinal DAO, like the characteristic developmental patterns of the mucosal disaccharidases, closely reflects the maturational process of the mucosa.

DAO was essentially undetectable in liver, pancreas, spleen, kidney, lung, heart, brain, muscle, skin, bone marrow, ovary, and testis; colon DAO was <5% of ileal DAO; and thymus, adrenal, and stomach DAO

were <2%. DAO from all tissues measured, other than the intestine, showed no increase with age (Fig. 2).

Plasma DAO rose in parallel with intestinal DAO ($n = 500$, $r = 0.84$, $P < 0.001$), reached a peak at 24 d, and then remained at normal adult levels (1.4–2.8 U/ml) (Fig. 2 and 3). If the plasma DAO curve is superimposed on the intestinal DAO curve, the curves are identical except for a 3-d lag before the plasma DAO reaches peak levels. These data thus document that the prime source of the increasing plasma DAO in the newborn rat is the small intestine.

Mucosal injury studies. Table I shows that per-

TABLE I
Decreases in Mucosal Enzyme Activities and Plasma DAO after Selective Villus Mucosal Damage by Hypertonic Sodium Sulfate Solution

Perfusion	Histologic injury	Decrease in enzyme activity					Number of rats
		Lactase	Maltase	Sucrase	Mucosal DAO	Plasma DAO	
					%		
1,400 × 30	Minimal	0	0	0	0	0	4
1,400 × 60	Minimal	10*	0	0	0	0	5
2,100 × 30	Moderate	73†	62‡	60‡	22*	12*	8
2,100 × 60	Severe	75	65	62	44§	42§	12

Histological injury is graded as follows: Minimal, normal-appearing columnar epithelial cells, with a few pyknotic nuclei; moderate, slight loss of contour of epithelial cells, with moderate numbers of pyknotic nuclei, and lymphatic dilation; severe, epithelial cells shortened and cuboidal, with dense-staining cytoplasm, many with pyknotic nuclei. Changes were most marked over villus tips and did not extend into crypts. Decreases in enzyme activities are the mean of the percentage change of activities as compared with those measured simultaneously in untreated controls.

Statistical significance of difference as compared to one less degree of injury:

* $P < 0.04$.

† $P < 0.01$.

§ $P < 0.02$.

fusion with hyperosmolar sodium sulfate solutions produces different degrees of selective damage to the mature villus cells while sparing the proliferative crypt cells, as previously shown (16). Increasing concentrations and times of exposure produced progressively more severe damage to the villus mucosa. With this increasing damage, there were progressive and statistically significant decreases first in lactase, then maltase and sucrase, and finally in mucosal and plasma DAO activities. The magnitude of the decrease in plasma DAO correlated well with the decrease in mucosal DAO ($n = 29$, $r = 0.69$, $P < 0.005$).

DISCUSSION

The measurement of mucosal enzymes such as disaccharidases and alkaline phosphatase (intestinal isoenzyme) has been used to follow mucosal development and function (4–6). However, such measurements require intestinal mucosal specimens because the disaccharidases are usually not measureable in plasma; and, in the case of alkaline phosphatase, the intestinal isoenzyme measurement requires electrophoretic separation after neuraminidase digestion, and the isoenzyme is only a minor fraction of the total serum enzyme activity. Thus the identification of a plasma enzyme activity that can both be easily measured and serve to monitor the maturity and integrity of intestinal mucosa should be of interest.

Our results show that DAO activity is unique in this regard, and may serve as a useful plasma marker of mucosal maturation and also of mucosal integrity in the rat. Its measurement can be accomplished rapidly and easily by using a liquid scintillation counter to measure the amount of tritiated water released after a 2-h incubation of 0.1 ml of plasma with the tritiated substrate (13). Plasma levels of this enzyme activity closely reflect the maturity and integrity of the mucosa; plasma enzyme activity increases as the rat intestinal mucosa differentiates and contains increasing amounts of the enzyme, and decreases as the adult rat mucosa is progressively damaged. Although decreasing activities of lactase, maltase, and sucrase are sensitive tissue indicators of mucosal damage, DAO is the only enzyme that provides a plasma marker of progressive mucosal injury (Table I).

In humans, as in rats, the small intestinal mucosa is the tissue containing the highest DAO activity, and the rise in plasma DAO seen after heparin infusion is also similar to that seen in rats (10, 11). It is thus quite possible that plasma DAO might also reflect intestinal mucosal maturity and integrity in humans, and further studies should be done to establish this.

The number of mature, differentiated villus-tip cells that appear to contain the highest levels of intestinal mucosal DAO (13) is decreased in certain disorders of

the mucosa, such as celiac diseases, tropical sprue, and ischemia (5). In such diseases, this loss of integrity of the mature mucosa may be reflected by a decrease in DAO activity. The goal of treatment for such disorders is restoration of a normal population of mature mucosal cells. At present, repeated peroral biopsies of the mucosa are required to monitor precisely the status of the mucosa in these situations. Our data suggest that the monitoring of plasma DAO activity during therapeutic efforts warrants investigation as a noninvasive means for evaluating the integrity of the small intestinal mucosa in humans.

In summary, our data confirm that the intestinal mucosa is the prime source of plasma DAO and that plasma DAO can be used as an index of mature enterocyte mass, and suggest that further studies on the potential biological role of DAO in the intestinal mucosa may be fruitful. Previous studies have suggested that DAO may play a protective role in intestinal ischemia by metabolizing increased levels of histamine (19, 20). In addition to histamine, the polyamine precursor putrescine is also a preferred *in vitro* substrate for DAO. Since only small amounts of histamine are metabolized *in vivo* by DAO (21), it has been suggested that DAO may be more important in polyamine metabolism (22). Recent studies in our laboratory show that increases in activity of polyamine-synthesizing enzymes and in tissue levels of putrescine precede the increases in DAO that occur during intestinal mucosal maturation and recovery after injury (23, 24). Thus, DAO may be important in polyamine metabolism, and play a role in the regulation of mucosal growth and differentiation.

ACKNOWLEDGMENTS

We thank Dr. Thomas R. Hendrix for advice, encouragement, and review of the manuscript. We thank MarLou Maestri, Jennifer Messersmith, Mimi Thomas, and Kathy Wieman for technical assistance.

This work was supported in part by National Institutes of Health grants 5-R01-CA-18404, 1-P50-HL-19157-01, and RR-5378 and National Institutes of Health training grant 5 T32 AM07192-05. S.B.B. is also supported by National Institutes of Health Research Career Development Award 5-K04-CA-000-27.

REFERENCES

1. Koldovsky, O. 1969. Development of the Functions of the Small Intestine in Mammals and Man. S. Karger, New York.
2. Henning, S. J., and N. Kretchmer. 1973. Development of intestinal function in mammals. *Enzyme (Basel)*. **15**: 3–23.
3. Eastwood, G. L. 1977. Gastrointestinal epithelial renewal. *Gastroenterology*. **72**: 962–975.
4. Crane, R. K. 1968. A concept of the digestive-absorptive surface of the small intestine. *Handb. Physiol.* **5**: 2535–2542.
5. Alpers, D. H., and B. Seetharam. 1977. Pathophysiology

- of diseases involving intestinal brush-border proteins. *N. Engl. J. Med.* **296**: 1047–1050.
6. McCarthy, D. M., and Y. S. Kim. 1973. Changes in sucrase, enterokinase, and peptide hydrolase after intestinal resection. The association of cellular hyperplasia and adaptation. *J. Clin. Invest.* **52**: 942–951.
 7. Buffoni, F. 1966. Histaminase and related amine oxidases. *Pharmacol. Rev.* **18**: 1163–1199.
 8. Shaff, R. E., and M. A. Beaven. 1976. Turnover and synthesis of diamine oxidase (DAO) in rat tissues. Studies with heparin and cycloheximide. *Biochem. Pharmacol.* **25**: 1057–1062.
 9. Kobayashi, Y., J. Kupelian, and D. V. Maudsley. 1969. Release of diamine oxidase by heparin in the rat. *Biochem. Pharmacol.* **18**: 1585–1591.
 10. Baylin, S. B., M. A. Beaven, R. M. Krauss, and H. R. Keiser. 1973. Response of plasma histaminase to small doses of heparin in normal subjects and patients with hyperlipoproteinemia. *J. Clin. Invest.* **52**: 1985–1993.
 11. Baylin, S. B., M. A. Beaven, L. M. Buja, and H. R. Keiser. 1972. Histaminase activity: a biochemical marker for medullary carcinoma of the thyroid. *Am. J. Med.* **53**: 723–733.
 12. Shakir, K. M. M., S. Margolis, and S. B. Baylin. 1977. Localization of histaminase (diamine oxidase) in rat small intestinal mucosa: site of release by heparin. *Biochem. Pharmacol.* **26**: 2343–2347.
 13. Baylin, S. B., S. A. Stevens, and K. M. M. Shakir. 1978. Association of diamine oxidase and ornithine decarboxylase with maturing cells in rapidly proliferating epithelium. *Biochim. Biophys. Acta.* **541**: 415–419.
 14. Taylor, S. L., and E. R. Lieber. 1979. Subcellular distribution and properties of intestinal histamine-metabolizing enzymes from rats, guinea pigs and rhesus monkeys. *C. Comp. Biochem. Physiol.* **63**: 21–26.
 15. Baylin, S. B., and G. D. Luk. 1980. Diamine oxidase (histaminase) activity in human disease. In *Perspectives in Polyamine Research*. L. Marton and D. R. Morris, editors. Raven Press, New York. In press.
 16. Roggin, G. M., J. G. Banwell, J. H. Yardley, and T. R. Hendrix. 1972. Unimpaired response of rabbit jejunum to cholera toxin after selective damage to villus epithelium. *Gastroenterology.* **63**: 981–989.
 17. Dahlqvist, A. 1964. Method of assay of intestinal disaccharidases. *Anal. Biochem.* **7**: 18–25.
 18. Lowry, O. H., N. J. Rosebrough, A. L. Farr, and R. J. Randall. 1951. Protein measurement with the Folin phenol reagent. *J. Biol. Chem.* **193**: 265–275.
 19. Kusche, J., H. Richter, J. Schmidt, R. Hesterberg, A. Friedrich, and W. Lorenz. 1975. Diamine oxidase in rabbit small intestine: separation from a soluble monoamine oxidase, properties and pathophysiological significance in intestinal ischemia. *Agents Actions.* **5**: 431–439.
 20. Kusche, J., C. D. Stahlknecht, W. Lorenz, G. Reichert, and H. Richter. 1977. Diamine oxidase activity and histamine release in dogs following acute mesenteric artery occlusion. *Agents Actions.* **7**: 81–84.
 21. Schayer, R. W. 1959. Catabolism of physiological quantities of histamine in vivo. *Physiol. Rev.* **39**: 116–126.
 22. Zeller, E. A. 1965. Identity of histaminase and diamine oxidase. *Fed. Proc.* **24**: 766–768.
 23. Luk, G. D., and S. B. Baylin. 1980. Inhibition of ornithine decarboxylase (ODC) with α -difluoromethyl ornithine suggests an essential role for ODC in intestinal maturation. *Clin. Res.* **28**: 280A. (Abstr.)
 24. Luk, G. D., and S. B. Baylin. 1980. Essential role of ornithine decarboxylase (ODC) in intestinal mucosal growth and recovery shown by inhibition with α -difluoromethylornithine (DFMO). *Gastroenterology.* **78**: 1212. (Abstr.)