

An Unusual Etiology of Spontaneous Pyometra Perforation; A Case Report

Rachna Agarwal *, Amita Suneja, Abha Sharma, Neelam Bala Vaid

- Department of Obstetrics and Gynecology, University College of Medical Sciences and Guru Teg Bahadur Hospital, Shahdara, Delhi, India

* Corresponding Author:
Rachna Agarwal,
Department of Obstetrics
and Gynecology,
University College of
Medical Sciences and
Guru Teg Bahadur
Hospital, Shahdara, Delhi,
India
E-mail:
Rachna_anila@yahoo.
co.in

Received: May 8, 2011

Accepted: Jun. 29, 2011

Abstract

Introduction: By presenting this case we aimed to describe an uncommon complication of generalized peritonitis following spontaneous pyometra perforation in untreated cervical carcinoma.

Case Presentation: This report describes a 60-year-old postmenopausal woman presenting with clinical features mimicking intestinal perforation who was later diagnosed as cervical carcinoma with pyometra perforation at exploratory laparotomy. The patient had good post-operative recovery following drainage and peritoneal lavage.

Conclusion: Spontaneous pyometra perforation in a case of untreated carcinoma of cervix is a rare condition, yet it should be suspected and kept in the differential diagnosis of acute abdomen in elderly women.

Keywords: Acute abdomen, Cervical cancer, Perforation, Pyometra.

To cite this article: Agarwal R, Suneja A, Sharma A, Vaid NB. An Unusual Etiology of Spontaneous Pyometra Perforation; A Case Report. *J Reprod Infertil.* 2011;12(3):235-238.

Introduction

Generalized peritonitis in elderly women is a serious condition and finding an etiology is usually a challenge for surgeons. Spontaneous perforation of pyometra is a rare cause of acute abdomen with only 28 cases reported and indexed in the English literature (1 - 6). Furthermore, only six cases (including the present one) have been due to cervical cancer (1). In the case illustrated here the presentation clinically mimicked an intestinal perforation. The etiology was diagnosed only intraoperatively. A high index of suspicion is required to make a correct preoperative diagnosis to allow early intervention, thereby reducing morbidity and mortality.

Case Presentation

A 60-year-old postmenopausal, para 2 woman presented with acute central abdominal pain for

the past 12 hours along with abdominal distension. The pain was intermittent, non-radiating and non-colicky. She also gave a history of mild fever for 3 days associated with chills but no rigors. There was no history of prolonged illness, medication use or intervention in the past. On examination, vitals were stable. There was mild abdominal distension with tenderness and guarding on per-abdomen examination. Bowel sounds were present with no obvious palpable organomegaly. Abdominal x-rays showed free air under diaphragm with no distended bowel loops or air fluid levels. Being an endemic region, a provisional clinical diagnosis of enteric perforation with subsequent peritonitis was made and the patient was planned for urgent exploratory laparotomy by surgeons.

Preoperatively, there was about 100 ml of pus

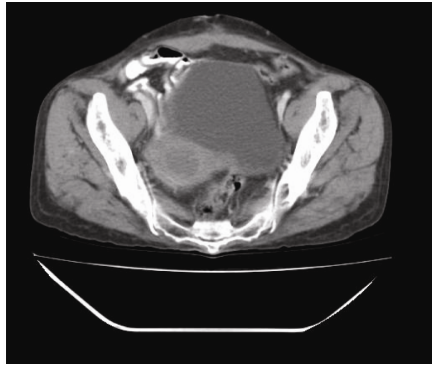


Figure 1. Post-operative contrast enhanced computerized tomography showing advanced carcinoma cervix

with soft bulky uterus perforated at fundus which had sealed. Extensive lavage of abdominal cavity was done. Bilateral thickened uterosacral and a short pelvic wall raised strong suspicion of cervical cancer and accompanying pyometra. On per speculum examination, the cervix was found flushed with vagina. A cervical biopsy was taken and pyometra was drained vaginally.

Post-operatively, the patient's cervical biopsy was confirmatory of carcinoma cervix. Patient had good post-operative recovery. Contrast enhanced computerized tomography was done post operatively to assess tumor extent (Figure 1) in consultation with a gynecologic oncologist to plan further treatment according to its staging. The patient received radiotherapy in view of advanced stage of cervical cancer and was placed under follow up.

Discussion

Pyometra is the accumulation of purulent material in the uterine cavity. Pyometra is an uncommon condition, but the incidence of associated malignancies is considerable, and the risk of spontaneous perforation is relatively high (2). Pyometra represented 0.038% of gynecologic admissions in a retrospective study between 1993 and 1999 in two regional hospitals in a developing country (2). Of these, 22.2% of the cases were associated with malignancy, 3.7% with genital tract abnormality and 74.1% were idiopathic (2). Spontaneous perforation of pyometra was noted in 18.5% of the cases. A preoperative diagnosis was correctly made in 77.3% of the patients without spontaneous perforation in their series. Thus, preoperative diagnosis of malignancy can be often missed in cases presenting perforation later in the course of

the disease as in our case.

The common causes of pyometra in postmenopausal women are malignancies of genital tract and the consequence of their treatment (radiotherapy). Pyometra was associated in 0.89% of cervical cancer patients in a large study of 3041 patients (7). Other postmenopausal causes are benign tumor-like leiomyomas, endometrial polyps, senile cervicitis, cervical occlusion after surgery or idiopathic conditions (3). Spontaneous rupture of carcinoma cervix associated pyometra resulting in peritonitis is an extremely rare complication with only 5 cases reported till date (8).

The classic triad of symptoms in patients with pyometra consists of purulent vaginal discharge, postmenopausal bleeding and lower abdominal pain. Symptoms being nonspecific, the diagnosis of pyometra is difficult unless suspected and specifically looked for. Once diagnosed, a careful history and a detailed pelvic examination should be performed to rule out associated malignancies. Our case illustrated one of the truly rare and unsuspected complications of carcinoma cervix associated pyometra: a presentation of a spontaneous perforation and subsequent peritonitis. Most of the times, surgeons perform an exploratory laparotomy with provisional diagnosis other than pyometra perforation.

On reviewing the indexed English literature, there were 28 reported cases of spontaneous pyometra rupture (1- 6). Table 1 describes these cases grouped according to the etiology along with presenting symptoms and their outcomes. All cases were postmenopausal elderly females, mostly in the sixth to tenth decades of life. The most common universally present symptom was abdominal pain. Moreover, some cases had fever at the time of presentation. An analysis of preoperative diagnosis in the above cases hardly shows spontaneous perforation of pyometra in carcinoma cervix. The common preoperative diagnosis kept were generalized peritonitis (50%), perforation of gastrointestinal tract (40%) and pneumoperitoneum (30%). Laparotomy was performed in all cases. Only 5 out of 28 cases including our case had untreated carcinoma cervix as the cause leading to spontaneous pyometra perforation. All the 5 described cases did not have a preoperative diagnosis of malignancy and were missed cases of carcinoma cervix as in our case (8).

Table 1. Review of literature: The etiology of 28 cases of pyometra perforation along with their provisional diagnosis and outcome (1 - 6)

Etiology	Patient's age (yrs)	Presentation	Treatment	Outcome
Malignancy: cervical carcinoma (post-surgical diagnosis): 6 cases				
	66	GP	Repair uterus	Survival
	67	GP, PP	Subtotal hyst	Survival
	34	GP	Drain & irrigation	Survival
	72	Nm**	Drain & irrigation	Mortality
	80	GP	Panhyst	Survival
	60*	GP,PP, PPU	Drainage & irrigation	Survival
Malignancy: 3 cases (Endom CA, rectal CA, sigmoid CA)				
	77	GP	Panhyst	Mortality
	86	GP, PP	Subtotal hyst + sigmoidostomy	Survival
	77	Acute appendicitis	Subtotal hyst + sigmoidectomy	Survival
Benign: leiomyoma+ adenomyosis: 2+1 cases				
	41	PIT, PP	TAH	Survival
	85	PIT , PP	Panhyst	Mortality
	86	GP, PP	Subtotal hyst	Survival
Benign: fundal necrosis + uterine infarction + gangrene: 1+1+1 cases				
	88	PP	Drain & irrigation	Survival
	66	Nm**	Panhyst	Mortality
	60	GP + PIT	Panhyst	Survival
Benign: endometritis/ infection uterus: 7 cases				
	80	PIT, PP	Panhyst	Survival
	67	PIT + PP	Panhyst	Nm**
	65	GP	Panhyst	Survival
	72	GP	Panhyst	Survival
	76	Acute diverticulitis	Drain & irrigation	Survival
	92	PIT, PP	Panhyst	Survival
	63	GP+ PIT		Mortality
Unclear: patent cervical canal: 3 cases				
	78	Nm**	Panhyst	Nm**
	82	PPU (PIT)	Panhyst	Mortality
	86	PIT	TAH	Survival
Not mentioned: 4 cases				
	86	GP	Subtotal hyst	Mortality
	73	PIT	TAH	Survival
	69	GP	TAH	Mortality
	89	GP	Panhyst	Mortality

Abbreviations: yrs: Years; GP: Generalized peritonitis; PIT: Perforated gastrointestinal tract; PPU: Perforated peptic ulcer; PP: Pneumo-peritoneum; Drain& irrigation: Drainage & Irrigation; Subtotal hyst: Subtotal hysterectomy; TAH: Total abdominal hysterectomy; Panhyst: Total abdominal hysterectomy & Bilateral salpingo-opherectomy, *: Our case, Nm**: Not mentioned

The diagnosis of pyometra perforation is usually one of exclusion. Abdominal x-ray may show gas under diaphragm. Confirmation is aided by ultrasonography of the abdomen with fluid collection in the uterine cavity. Urgent laparotomy should be performed. Total hysterectomy along with bilateral salpingo-oophorectomy and thorough drainage and irrigation of abdominal cavity remain the preferred immediate treatment in emergency. Postoperatively, broad spectrum antibiotics and intensive care can help in good recovery followed by definitive management according to the etiology. Cervical cancer is managed according to the cancer stage in consultation with gynec oncologists. Radiation in combination with cisplatin-based chemotherapy has become the standard of care for patients with locally advanced cervical cancer (9).

Conclusion

Pyometra is a serious medical condition, because of both its association with malignant diseases and the danger of spontaneous perforation. Although rare, ruptured pyometra should be considered in the differential diagnosis of acute abdomen in elderly women, especially those with malignant disorders of the genital tract. The treatment of pyometra rupture is immediate peritoneal lavage and drainage, or simple hysterectomy.

References

1. Yildizhan B, Uyar E, Şişmanoğlu A, Güllüoğlu G, Kavak ZN. Spontaneous perforation of pyometra. *Infect Dis Obstet Gynecol.* 2006;2006:26786.
2. Chan LY, Lau TK, Wong SF, Yuen PM. Pyometra. What is its clinical significance? *J Reprod Med.* 2001;46(11):952-6.
3. Iwase F, Shimizu H, Koike H, Yasutomi T. Spontaneously perforated pyometra presenting as diffuse peritonitis in older females at nursing homes. *J Am Geriatr Soc.* 2001;49(1):95-6.
4. Shahid N, Khan H, Onon TS. Perforation of pyometra leading to diffuse peritonitis is not necessarily iatrogenic. *J Obstet Gynaecol.* 2006;26(1):76-7.
5. Saha PK, Gupta P, Mehra R, Goel P, Huria A. Spontaneous perforation of pyometra presented as an acute abdomen: a case report. *Medscape J Med.* 2008;10(1):15.
6. Geranpayeh L, Fadaei-Araghi M, Shakiba B. Spontaneous uterine perforation due to pyometra presenting as acute abdomen. *Infect Dis Obstet Gynecol.* 2006;2006:60276.
7. Babarinsa IA, Campbell OB, Adewole IF. Pyometra complicating cancer of the cervix. *Int J Gynaecol Obstet.* 1999;64(1):75-6.
8. Vyas S, Kumar A, Prakash M, Kapoor R, Kumar P, Khandelwal N. Spontaneous perforation of pyometra in a cervical cancer patient: a case report and literature review. *Cancer Imaging.* 2009;9:12-4.
9. National Comprehensive Cancer Network: your best resource in fight of cancer [Internet]. Washington PA: National Comprehensive Cancer Network; 2011. NCCN Clinical Practice Guidelines in Oncology: Cervical Cancer vol.1; 2011 [cited 2011 Jul 20]. Available from: http://www.nccn.org/professionals/physician_gls/PDF/cervical.pdf