

ARTICLE

# Phenotypic variant of Brachydactyly-mental retardation syndrome in a family with an inherited interstitial 2q37.3 microdeletion including *HDAC4*

Pablo Villavicencio-Lorini<sup>1</sup>, Eva Klopocki<sup>2,3</sup>, Marc Trimborn<sup>2</sup>, Randi Koll<sup>2</sup>, Stefan Mundlos<sup>2,3</sup> and Denise Horn<sup>\*,2</sup>

Deletions of the chromosomal region 2q37 cause brachydactyly-mental retardation syndrome (BDMR), also known as Albright hereditary osteodystrophy-like syndrome. Recently, histone deacetylase 4 (*HDAC4*) haploinsufficiency has been postulated to be the critical genetic mechanism responsible for the main clinical characteristics of the BDMR syndrome like developmental delay and behavioural abnormalities in combination with brachydactyly type E (BDE). We report here on the first three generation familial case of BDMR syndrome with inheritance of an interstitial microdeletion of chromosome 2q37.3. The deletion was detected by array comparative genomic hybridization and comprises the *HDAC4* gene and two other genes. The patients of this pedigree show a variable severity of psychomotor and behavioural abnormalities in combination with a specific facial dysmorphism but without BDE. Given that only about half of the patients with 2q37 deletions have BDE; we compared our patients with other patients carrying 2q37.3 deletions or *HDAC4* mutations known from the literature to discuss the diagnostic relevance of the facial dysmorphism pattern in 2q37.3 deletion cases involving the *HDAC4* gene. We conclude that *HDAC4* haploinsufficiency is responsible for psychomotor and behavioural abnormalities in combination with the BDMR syndrome-specific facial dysmorphism pattern and that these clinical features have a central diagnostic relevance.

*European Journal of Human Genetics* (2013) 21, 743–748; doi:10.1038/ejhg.2012.240; published online 28 November 2012

**Keywords:** 2q37; *HDAC4*; BDMR; Albright hereditary osteodystrophy-like syndrome; brachydactyly

## INTRODUCTION

Brachydactyly-mental retardation syndrome (BDMR, MIM 600430), synonymous with Albright hereditary osteodystrophy-like syndrome, is caused by chromosomal 2q37 deletions ranging from small submicroscopic interstitial deletions to large terminal deletions that are detectable by routine cytogenetics.<sup>1</sup> Major features of BDMR are mild to moderate developmental delay/intellectual disability, and behaviour disorders.

Brachydactyly type E (BDE) is a variable clinical sign and only documented in about half of the patients with 2q37 deletions. Further clinical findings in these patients include obesity, short stature, seizures, hypotonia, and structural anomalies of the CNS, heart, trachea and the gastrointestinal/genitourinary tract. In rare cases, Wilms tumours have been observed.<sup>1,2</sup> By array comparative genomic hybridization (array CGH), the minimal deletion interval responsible for the phenotypical features of BDMR has been refined.<sup>3,4</sup> Recently, histone deacetylase 4 (*HDAC4*, MIM 605314) haploinsufficiency has been identified to be the critical genetic mechanism responsible for the major BDMR features in patients with 2q37 deletions or intragenic *HDAC4* mutations.<sup>5</sup> *HDAC4* acts as a transcription repressor by altering chromatin structure and influences a broad transcriptional network that is essential for brain, muscle and bone development, as well as function.<sup>6–8</sup> In the present study, we show that a heterozygous 2q37.3 microdeletion involving the genes *HDAC4*,

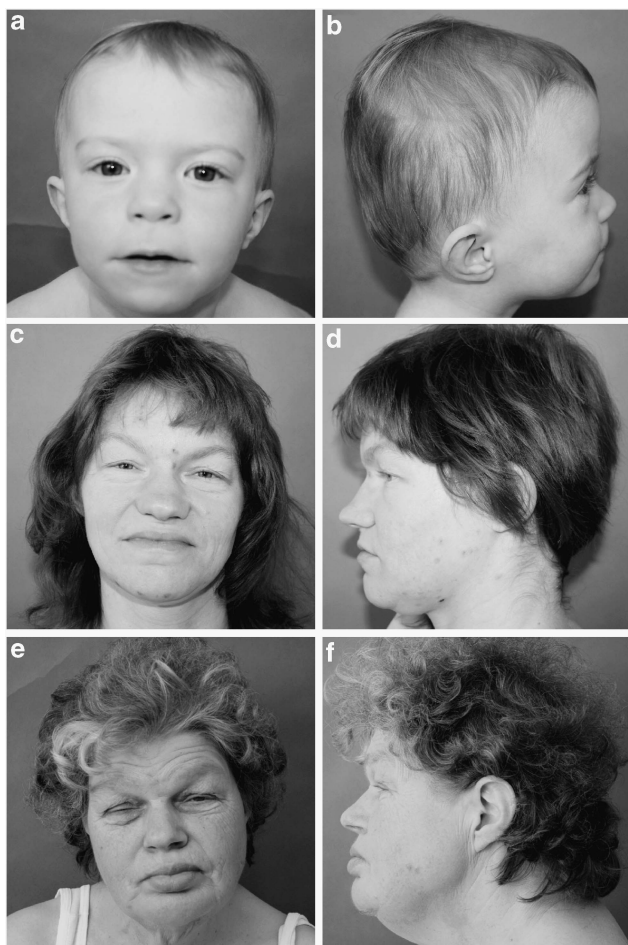*TWIST2* and *FLJ43879* is inherited in an autosomal-dominant manner and is associated with psychomotor and behavioural abnormalities in combination with the BDMR-specific facial dysmorphism pattern.

## CLINICAL DESCRIPTION

### Patient 1

This is the female index patient who is the only child of non-consanguineous parents (Figure 1a and b). She was born at 38-weeks' gestation by spontaneous delivery after an uncomplicated pregnancy. During her first weeks of life, constipation and a diminished motor activity were noticed. At age of 6 months the girl was referred to our clinical genetics unit because of motor developmental and growth delays. Upon clinical examination, the patient showed a borderline short stature with a height of 62 cm (–2 SD), while her occipitofrontal head circumference (41.8 cm; –0.9 SD) and weight (6.4 kg; –1.3 SD) were in the normal range. At this age, she was not able to grasp nor to roll from back to ventral position. The patient presented a short neck, widely placed hypoplastic nipples, a four finger crease on the left hand and clinodactyly of both fifth fingers. In the follow-up examination at the age of 11 months unattended sitting was not possible. Her height was in the lower normal range and primary dentition had started meanwhile at the age of 10 months. At the age of 2 years and 8 months, physical examination revealed midface hypoplasia, mild

<sup>1</sup>Centre for Pediatrics and Adolescent Medicine, University Hospital of Freiburg, Freiburg, Germany; <sup>2</sup>Institute for Medical and Human Genetics, Campus Virchow Klinikum, Charité-Universitätsmedizin Berlin, Berlin, Germany; <sup>3</sup>Max-Planck-Institute for Molecular Genetics, Research Group Development & Disease, Berlin, Germany  
\*Correspondence: Dr D Horn, Institute for Medical and Human Genetics, Campus Virchow Klinikum, Charité-Universitätsmedizin Berlin, Augustenburger Platz 1, Berlin 13353, Germany, Tel: +49 30 450 569 118, Fax: +49 30 450 569 914, E-mail: denise.horn@charite.de  
Received 26 January 2012; revised 2 October 2012; accepted 11 October 2012; published online 28 November 2012



**Figure 1** Facial features of patients with 2q37.3 deletion including *HDAC4*. Patient 1 (a, b), a female at age of 2 years and 8 months, shows features like midface hypoplasia, and mild ptosis. Note in patient 2 (c, d) highly arched eyebrows, narrow palpebral fissures, deep set eyes and broad nasal bridge, as well as tip that are more pronounced in her mother (e, f).

ptosis, deeply set eyes, posteriorly rotated and low-set ears, thin upper lip and pointed chin (Table 1). Motor skills now were according for age and her speech development was unremarkable being able to communicate with short sentences of three to four words. Behavioural problems in the form of aggressive tantrum-like behaviour and sleep abnormalities became progressively disturbing. Clinically and radiologically, BDE was not present and was also excluded by a metacarpophalangeal pattern profile (Supplementary figure 1). The middle finger length was at 4.6 cm (3rd–25th centile) and the total hand length was at 10.9 cm (3rd–25th centile).

#### Patient 2

The 45-year-old mother of the index patient had a history of general developmental and growth delays during childhood (Figure 1c,d). However, later the patient was able to attend normal school. In adulthood she noticed a reduced spatial orientation and memory deficits. On clinical examination, a coarse facial appearance with a broad and depressed nasal bridge, highly arched eyebrows, deep set eyes and narrow palpebral fissures were observed (Table 1). Her growth parameters were all in the normal range: height of 158 cm (–1.4 SD), weight of 61 kg (BMI 24.4), and OFC of 54.5 cm (+0.6 SD). Clinically her hands and feet appeared to be normal, BDE was

excluded radiologically and by a metacarpophalangeal pattern profile (Supplementary figure 1). The middle finger length was at 8 cm (50th centile) and the total hand length was at 17.6 cm (25th centile).

#### Patient 3

The 68-year-old grandmother of the index patient is the mother of patient 2 (Figure 1e and f), her only child. Her sister's daughter had suffered from intellectual disability in combination with hydrocephalus and paraplegia of unknown cause and died at the age of 28 years.

The past medical history of patient 3 is positive for severe osteoarthritis, most accentuated in both knee joints. She underwent multiple surgeries and an extensive orthopaedic treatment. On examination, she presented a dysmorphic facial aspect similar to that of her daughter with highly arched eyebrows, markedly narrow palpebral fissures and everted as well as full lips (Table 1). Her growth parameters were all in the normal range: height –157.5 cm (–1.4 SD), weight –75 kg (BMI 30.0), and OFC –54.5 cm (+0.6 SD). She was able to communicate in simple sentences and her intellectual skills appeared to be lower than normal. Clinically her hands were normal.

## METHODS

### Informed consent

Written informed consent was given by the patients or the legal guardian for genetic testing and publication of images.

### Conventional cytogenetics

Standard cytogenetic analysis with a high resolution 550 GTG-banding was performed according to standard procedures using a lithium-heparin peripheral blood sample from patient 1.

### Array CGH

Genomic DNA samples from patients 1 and 2 were extracted from EDTA peripheral blood samples. The DNA sample from patient 1 was analysed by whole genome 244 K oligonucleotide array according to the manufacturer's protocol (Agilent Technologies, Santa Clara, CA, USA). Image data were analysed using Feature Extraction 9.5.3.1 and CGH Analytics 3.4.40 software (Agilent Technologies) with the following analysis settings: aberration algorithm ADM-2; threshold: 6.0; window size: 0.2 Mb; filter: five probes,  $\log_2\text{ratio} = 0.29$ . Genome coordinates are shown according to the human genome build hg18 (NCBI 36.1). The Array-Format BlueGenome CytoChip ISCA 4 × 180K v1.0 (Bluegenome, Cambridge, UK) was used to compare deletion sizes between patients 1 and 2.

### Fluorescence *in situ* hybridization

To confirm the array CGH result of patient 1, a fluorescence *in situ* hybridization (FISH) analysis was performed on metaphase chromosomes from peripheral blood lymphocytes using the BAC clone RP11-546M8 (2q37.3) labelled in red. BAC clone RP11-27O22 probe (2p16.1) labelled in green served as control probe. The same procedure was performed for patients 2 and 3.

### Real-time quantitative PCR

To clarify whether *TWIST2* is also affected by the microdeletion 2q37.3 we performed real-time quantitative PCR (qPCR) for patients 1 and 2 measuring four amplicons covering the *TWIST2* gene. Genomic DNA samples from the patients were extracted from EDTA peripheral blood samples. For comparison the qPCR analysis included quantification of *HDAC4* exon 12 and *FVIII* exon 8. The primer sequences are annotated in the Supplementary table 1. The qPCR analysis was performed on ABI Prism 7900HT Sequence Detection System (Applied Biosystems, Foster City, CA, USA) as described previously.<sup>9</sup>

**Table 1 Comparison of genotypes and clinical features in patients of the current study and patients known from literature**

Patients	Genotype	Gender	Age (years)	OFC	Height	Weight	Motor delay	Speech delay	Behaviour disturbance	Brachy-cephaly	Round/broad face*	Frontal bossing*	Highly arched eyebrows*	Deeply set eyes*	Narrow palpebral fissure	Upslanted palpebral fissures*	Epicanthal folds*	Midface hypoplasia	Hypoplastic alacnasiprom.colum <sup>2</sup>	Low-set ears/ Ear anomaly*	Thin upper lip*	Everted lower lip	Brache-dactyly E
Patient 1	del(2)(q37.3) 0.8 Mb inherited	♀	2.6	47 cm (-1.8 SD)	86 cm (-1.7 SD)	13 kg (-0.3 SD)		-	+	+	+	-	-	+	(+)	-	+	+	+	+	+	-	-
Patient 2	del(2)(q37.3) 0.8 Mb inherited	♀	44	54.5 cm (+0.6 SD)	158 cm (-1.4 SD)	61 kg (BMI 24.4)		+	-	-	+	-	+	+	+	-	-	+	-	-	-	+	-
Patient 3	del(2)(q37.3) 0.8 Mb	♀	68	54.5 cm (+0.6 SD)	157.5 cm (-1.4 SD)	75 kg (BMI 30.0)																	
SMS117 <sup>5</sup>	<i>HDAC4</i> c.2399_2400insC <i>de novo</i>	♀	25		157 cm (-1.5 SD)	96 kg (BMI 38.9)																	
SMS245 <sup>6</sup>	<i>HDAC4</i> c.490+56_121del65 <i>de novo</i>	♀	16		159.8 cm (+0.8 SD)	152.3 kg (+7 SD)																	
SMS277 <sup>15</sup>	del(2)(q37.3) 1.17 Mb N/A	♀	15		no short stature																		
SMS320 <sup>16</sup>	del(2)(q37.3) 3.02 Mb N/A	♀	3		no short stature																		
Patient 122 <sup>3</sup>	del(2)(q37.3qter) ~3.0 Mb <i>de novo</i>	♀	6	52 cm (50-75th centile)	9th centile	50th centile																	
Patient 10780 <sup>17</sup>	del(2)(q37.3qter) ~3.1 Mb <i>de novo</i>	♀	12	50 cm (< 3rd centile)	126 cm (< 3rd centile)	36.4 kg (25th centile)																	
Patient 8491 <sup>3</sup>	del(2)(q37.3qter) ~6 Mb N/A	♀	16		50th centile	>95th centile																	
Patient (W) <sup>20</sup>	del(2)(q37.3) 0.3-6 Mb N/A	♂	~4		normal	normal																	
Patient (S) <sup>21</sup>	del(2)(q37.3qter) 5.6 Mb <i>de novo</i>	♀	adult		10th centile	< 3rd centile																	
Patient (RA) <sup>17</sup>	del(2)(q37.3) 4.6 Mb <i>de novo</i>	♀	15	55.2 cm (10th centile)	~136cm (<3rd centile)	~35kg (<3rd centile)																	
Patient V.10 <sup>22</sup>	del(2)(q37.3)(q2:8)(q37.3;q24.3)	♀	9		30th centile	25th centile																	
Patient V.3 <sup>22</sup>	del(2)(q37.3)(q2:8)(q37.3;q24.3)	♀	18		10th centile	90th centile																	
Patient V.7 <sup>22</sup>	del(2)(q37.3)(q2:8)(q37.3;q24.3)	♂	17		50th centile																		
Patient V.19 <sup>22</sup>	del(2)(q37.3)(q2:8)(q37.3;q24.3)	♀	33		< 3rd centile	50th centile																	
Patient IV.6 <sup>22</sup>	del(2)(q37.3)(q2:8)(q37.3;q24.3)	♂	41		30th centile	90th centile																	
Patient IV.17 <sup>22</sup>	del(2)(q37.3)(q2:8)(q37.3;q24.3)	♂	37		< 3rd centile	90th centile																	
Patient V.20 <sup>22</sup>	del(2)(q37.3)(q2:8)(q37.3;q24.3)	♀	14		50th centile																		
Patient V.21 <sup>22</sup>	del(2)(q37.3)(q2:8)(q37.3;q24.3)	♀	39		< 3rd centile	> 90th centile																	
Patient (R) <sup>23</sup>	del(2)(q37.3) N/A	♀	9	52.5 cm (normal)	117cm (<5th centile)	48kg (>98th centile)																	
Patient (R) <sup>23</sup>	del(2)(q37.3) N/A	♂	44	normal																			
Patient (G) <sup>24</sup>	del(2)(q37.1) 7.8 Mb <i>de novo</i>	♀	8	5years: 51cm (75th centile)	114cm (90th centile)	24kg (97th centile)																	
Patient (M) <sup>25</sup>	del(2)(q37.1)(q2:10)(q37.1;q26.1)	♂	15		143.3cm (<3SD)	58kg (BMI 28.2)																	
Total 26 patients	variable deletion sizes	♀/♂= 20/6		4/18 microcephalic	8/24 short stature	7/20 overweight	23/25	24/25	16/17	4/10	20/23	7/18	7/18	20/23	19/21	9/18	1/16	15/23	9/21	7/12	14/23	5/16	19/24

+ present, — not present, (+) mild presentation, [—/+] evaluated from pictures, empty slots: neither applicable from descriptions nor from photographs. Additional information: SMS117: first sentences with 6 years, hyperactive, stereotypes, self-injurious, sleep disturbance, cerebral atrophy, aortic stenosis, hearing loss, hirsutism, SMS245: intellectually disabled, first sentences with 7 years, self-injurious, temper tantrums, sleep disturbance, hypermobility, dental anomalies, constipation, reduced sensitivity to pain, SMS272: aggression, stereotypes, hand wringing, sinus arrhythmia, myopia, SMS320: hyperactive, stereotypes, self-injurious, sleep disturbance, Patient 122: social communication disorder, generalized joint laxity, reduced muscle tone, Patient 10780: craniosynostosis, seizures, amblyopia left, dental crowding, Patient 8491: sociable, not aggressive, hydrocephalus, hip dislocation, perthes disease, febrile seizures, Patient 6: ritualistic behaviour and autism, unusual dentition, multiple skin rashes, Patient (Wolff et al.<sup>26</sup>), autistic disorder, moderate mental retardation, hyperkinetic, impulsive and aggressive behaviour, temporarily sleep disturbance, Patient (Smith et al.<sup>27</sup>): walking at 39 months, first single words at 48 months, acquisition of bowel and bladder control at 60 months, little response to social or verbal gestures from others, school testing indicated mental retardation, rapid catch-up cognitive progress, graduation from regular high school classes, lastly student at a 4-year college, severely impaired fine motor skills for writing and most daily living tasks, Patient (RA): congenital hip dislocation, dislocated radial heads, bowing of the radius and ulna, mild lumbar scoliosis, eczema, myopia, strabismus, Patient 6: autistic and ritualistic behaviour, unusual dentition, multiple skin rashes, increased appetite in early childhood, advanced bone age, Patient V.10: convulsions without fever, hyperkinesias, aggressive behaviour, self-mutilations, strabismus, hypoplastic ulna, inguinal hernia, Patient V.7: hyperactive, seizures, strabismus, contractures, scoliosis, hiatus hernia, Patient V.19: aggressive, hyperactive, strabismus, hypoplastic ulna, hydrothyroidism, Patient IV.6: psychiatric disorder, hypoplastic ulna, Patient IV.17: seizures, kyphoscoliosis, alopecia, pale fundus, hearing loss, Patient V.20: aggressive, hyperactive, strabismus, contractures, scoliosis, Patient (Reddy et al.<sup>28</sup>) 9 years: seizures, situs inversus, dextrocardia, duodenal/jejunal atresia, abdominal hernia, small hands and feet, obesity, Patient (Reddy et al.<sup>29</sup>) 44 years: psychosis, abnormal wide-based gait with spastic paraparesis, high-arched palate, pectus excavatum, low-set nipples, malrotation of large and small bowels, hypoplastic diaphragm, Patient (Galasso et al.<sup>24</sup>): hyperactivity, repetitive and self-injury behaviour, autism, high palate, microretrognathia, asymmetrical ears, gastroesophageal reflux disease, chronic colitis, hypotonia, joint hyperlaxity, abnormal EEG, Patient (Morris et al.<sup>15</sup>) 15 years: mandibular hypoplasia, plagiocephaly, hypertonia at age 4 months, eczema, abnormal gyration of the frontal lobes on cranial MRI, sparse hair, downslanting palpebral fissures, high palate.

<sup>26</sup>Characteristic facial features in 2q37 deletion syndrome according to GeneReviews.<sup>1</sup>

## RESULTS

While the standard cytogenetic analysis showed a normal female karyotype in patient 1, we identified by array CGH a heterozygous interstitial microdeletion 2q37.3 of about 800 kb, according to ISCN 2009 arr 2q37.3q37.3(239,395,957-240,154,599)x1 (Figure 2a). The following FISH analysis confirmed this chromosomal aberration and revealed that the deletion was maternally inherited from the grandmother via the mother to the index patient (Figure 2b). To clarify that the deletion is of the same size in patient 1 and at least her mother (patient 2), we performed a second array CGH analysis hybridizing the DNA samples from patient 1 and 2 against each other. The array CGH shows now a balanced profile on chromosome 2 indicating that both patients (1 and 2) carry exactly the same deletion. (Supplementary figure 2).

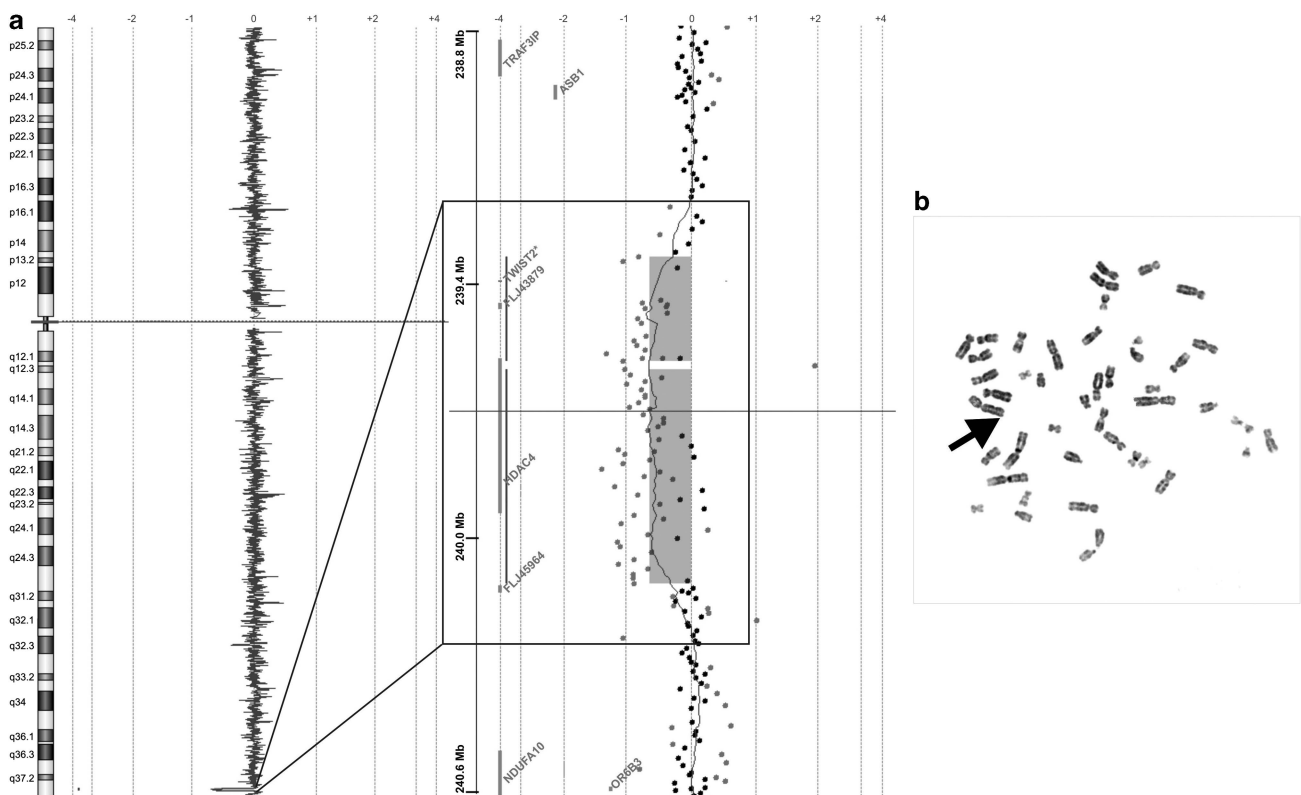
The genome coordinates chr2:239,395,957-240,154,599 in the UCSC human genome build 18 (NCBI36/ Version Mar 2006) indicated that the deletion included *HDAC4* and two additional genes *FLJ43879* and *TWIST2* (MIM 607556) (Figure 3). For confirmation we used target-specific qPCR analysis and confirmed that both genes with known function *HDAC4* and *TWIST2* are affected by the microdeletion 2q37.3 in patients 1 and 2, and, therefore, most probably also in patient 3 (Supplementary figure 3). The coordinates for the minimum and maximum deletion intervals are chr2:239,395,957-240,154,599 and chr2:239,385,056-240,165,585, respectively.

## DISCUSSION


Currently, about 100 patients with 2q37 deletions have been reported in the literature and 10 reports of patients with 2q37.3 microdeletions of different sizes are annotated in the DECIPHER database. Most of them have emerged *de novo*. Studies on parent-of-origin of *de novo* deletions revealed no preferential maternal or paternal transmission. Only a minority of 2q37.3 deletions recur in families with structural chromosomal abnormalities.<sup>3</sup> Most of these are derivatives from a balanced parental chromosomal translocation. The current study is to our knowledge the first report on a three generation familial case with an inherited interstitial 2q37.3 microdeletion comprising *HDAC4*, *TWIST2* and *FLJ43879*. There is so far only one report on parent to child transmission of an apparently pure terminal 2q37.3 deletion from an unaffected parent which is distally to the *HDAC4* gene and does not overlap with the interstitial 2q37.3 deletion reported here.<sup>9</sup>

Recently, *HDAC4* haploinsufficiency has been identified as the critical genetic mechanism responsible for developmental delay, behavioural abnormalities, and BDE in BDMR patients with 2q37 deletion.<sup>5</sup> This was supported by the detection of intragenic *de novo* *HDAC4* mutations in two patients with core findings of BDMR syndrome.

Here, we show that a heterozygous 2q37.3 microdeletion involving *HDAC4* is associated with psychomotor and behavioural abnormalities in combination with the BDMR-specific facial dysmorphism pattern (Figure 1). The missing BDE in the patients reported here



**Figure 2** (a) Array CGH profile of chromosome 2 indicating a heterozygous interstitial deletion in 2q37.3 (hg18 position chr2:239,395,957-240,154,599 bp) as shown by CGH Analytics 3.4.40 software. Note the magnification box, the deleted region (blue bars) encompasses *HDAC4*, *FLJ43879* and *TWIST2* (\*gene symbol added according to UCSC hg18 NCBI36/Version Mar 2006). (b) FISH analysis confirming the 2q37.3 deletion in lymphocytic chromosomes of the index patient's grandmother. Note, there is only one hybridization signal of the 2q37.3 locus-specific RP11-546M8 probe (red) on one of the chromosomes 2 (control probe RP11-27022 labelled in green). The aberrant chromosome 2 is marked by an arrow.



**Figure 3** Schematic representation of the 2q37.3 deletions in the family of the current study relative to recently reported *HDAC4* mutations (SMS117, SMS245) or 2q37.3 deletions involving *HDAC4*. The 2q37.3 deletions of SMS272 (hg18, chr2:239,764,593-240,938,545), SMS320 (hg18, chr2:237,920,956-240,938,547) and the patient described by Morris *et al.*<sup>19</sup> were detected by array CGH, while the deletions of the other patients were located by break point mapping using microsatellite analysis or by cytogenetic analysis with G-banding. RefSeq Gene positions are according to UCSC hg18 (NCBI36/ Version Mar 2006).

matches to observations that BDE is a variable clinical feature in BDMR patients. Despite the positive history of growth delay in infancy of patients 1 and 2, upon examination, all the patients of the current study presented a height in the lower normal range (Table 1). Interestingly, *HDAC4* exerts its inhibitory activity on key players of skeletogenesis like *RUNX2* and *MEF2C* by binding them with its N-terminal part. Therefore, a loss of the N-terminal function of *HDAC4* leads to a premature ossification resulting in shortness of bones in mice. In contrast the loss of the enzymatic activity in the C-terminus of *HDAC4* allows normal bone development in mice.<sup>8,10</sup> Thus, other *RUNX2* or *MEF2C*-binding factors compensating the effect of the *HDAC4* N-terminal part might have taken effect in the patients reported here and led to a normal metacarpal bone development. For instance, *TWIST2* which is also heterozygously deleted in these subjects is known to be involved in skeletogenesis.<sup>11,12</sup> However, as *TWIST2* maintains cells in a preosteoblast phenotype its deletion should have forced the manifestation of bone shortness. On the other hand, neither mutations in *TWIST2* nor in *FLJ43879* are described in patients with skeletal abnormalities. Instead, homozygous nonsense mutations in *TWIST2* are reported to segregate in families with Setleis syndrome (MIM 227260), which is

characterized by thin skin and sparse hair with a bi-temporal forceps marks-like pattern.<sup>13,14</sup> No function of the *FLJ43879* gene is known yet.

A comparison of the spectrum of the clinical findings of previously reported patients with 2q37.1, 2q37.2 and 2q37.3 terminal deletions has been performed by Galasso *et al.*<sup>24</sup> The distribution of malformations or anomalies of the central nervous system, gastrointestinal, cardiac, oral, tracheal, bony and genitourinary systems was different between these subgroups, however, more frequent in patients with break points in 2q37.1. To evaluate further diagnostic criteria for the 2q37 deletion syndrome, we compared the clinical findings of our patients and a representative cohort of other published patients carrying *HDAC4* mutations or overlapping interstitial or terminal 2q37 deletions (Figure 3, Table 1).<sup>3,5,15-24</sup> The female to male ratio was 21/6. Regarding the body measurements, 4/18 of the patients were microcephalic, 8/24 revealed a short stature and 7/20 an overweight. Twenty-three out of 24 patients had a history of motor delay. Except for patient 1, all patients for whom data were available showed speech delay. Altogether, the developmental delay/intellectual disability of the presented individuals (patients 1-3) was of only mild degree

compared with the other here discussed patients. Behavioural problems were reported in 16/17 affected individuals. The reported behavioural abnormalities include hyperactivity, sleep disturbance, auto-/aggression or temper tantrums and stereotypic/ritualistic or autistic behaviour. Only patient 8491 is described as sociable and not aggressive.<sup>3</sup> As only the child (patient 1) of the current study reveals behavioural problems, and no obvious behavioural abnormalities are present in the adult patients, it is supposable that these behavioural problems though progressively disturbing during childhood will disappear with age. Overall, these behavioural problems remind that of Smith–Magenis syndrome (SMS; MIM 182290). Accordingly, a regulatory connexion between *HDAC4* and *RAI1* the major gene for the phenotypic features of SMS has been proven.<sup>5</sup> Interestingly, with regard to the memory deficits claimed by the index patients mother, *HDACs* seem to be related to memory functions of the brain as shown in an Alzheimer's disease mouse model.<sup>18</sup>

With regard to the BDMR-associated facial dysmorphism we compared the facial characteristics of our patients and the other patients reported in the literature with the features previously described in GeneReviews (see features marked with an asterisk in Table 1).<sup>1</sup> Sorted by frequency, joint facial signs were narrow palpebral fissures in 91% (19/21), round or broad face in 87% (20/23), deeply set eyes in 87% (20/23), midface hypoplasia in 65% (15/23), thin upper lip in 61% (14/23), upslanted palpebral fissures in 50% (9/18), hypoplastic alae nasi with prominent columnella in 43% (9/21), frontal bossing in 39% (7/18), highly arched eyebrows in 39% (7/18), low-set ears or ear anomalies in 33% (7/21), everted lower lip in 31% (5/16) and epicanthal folds in 6% (1/16) of the patients. From the listed features, particularly our patients did not show frontal bossing, upslanted palpebral fissures nor hypoplastic alae nasi with prominent columnella. Additional remarkable facial features not described by GeneReviews are the markedly narrow palpebral fissures and the everted lower lip, which seems to aggravate with age, as this could be observed especially in the adult patients of our current study and was described for the patients harbouring *HDAC4* mutations. Comparing the photograph of patient 2 to that of patient SMS117 (see Williams *et al.*, 2010<sup>5</sup>) the facial gestalt of both patients is of striking similarity. As shown recently, different levels of *HDAC4* gene expression levels from the remaining intact *HDAC4* alleles could be one explanation for the differing phenotypic severity in BDMR syndrome.<sup>19</sup>

In summary, our study shows that a heterozygous 2q37.3 microdeletion involving the genes *HDAC4*, *TWIST2* and *FLJ43879* is inherited in an autosomal-dominant manner in a three generation familial case and is associated with psychomotor and behavioural abnormalities in combination with the BDMR-specific facial dysmorphism pattern. We provide another example that *HDAC4* haploinsufficiency is not fully penetrant with regard to the BDE phenotype.<sup>3,16</sup> Furthermore, we assume that it is also the critical genetic mechanism for the BDMR-specific facial pattern besides the BDMR-associated moderate developmental delay and behavioural problems. As patients with 2q37.3 microdeletions including *HDAC4* show similar behavioural problems as the ones known for SMS *HDAC4* deletions and mutations should be considered in patients with BDMR-specific facial dysmorphism pattern, and a phenotypic spectrum of SMS who are negative for 17p11.2 deletions and mutations of *RAI1*.

## CONFLICT OF INTEREST

The authors declare no conflict of interest.

## ACKNOWLEDGEMENTS

We would like to thank the family for their collaboration and contribution to this project. We acknowledge F Trotier for excellent technical assistance.

- Doherty ES, Solomon BD, Lacbawan F: 2q37 Deletion Syndrome; in Pagon RA, Bird TD, Dolan CR, Stephens K (eds) *GeneReviews*. Seattle WA, 1993–2011.
- Falk RE, Casas KA: Chromosome 2q37 deletion: clinical and molecular aspects. *Am J Med Genet C Semin Med Genet* 2007; **145C**: 357–371.
- Aldred MA, Sanford RO, Thomas NS *et al*: Molecular analysis of 20 patients with 2q37.3 monosomy: definition of minimum deletion intervals for key phenotypes. *J Med Genet* 2004; **41**: 433–439.
- Chaabouni M, Le Merrer M, Raoul O *et al*: Molecular cytogenetic analysis of five 2q37 deletions: refining the brachydactyly candidate region. *Eur J Med Genet* 2006; **49**: 255–263.
- Williams SR, Aldred MA, Der Kaloustian VM *et al*: Haploinsufficiency of *HDAC4* causes brachydactyly mental retardation syndrome, with brachydactyly type E, developmental delays, and behavioral problems. *Am J Hum Genet* 2010; **87**: 219–228.
- Majdzadeh N, Wang L, Morrison BE, Bassel-Duby R, Olson EN, D'Mello SR: *HDAC4* inhibits cell-cycle progression and protects neurons from cell death. *Dev Neurobiol* 2008; **68**: 1076–1092.
- Miska EA, Langley E, Wolf D, Karlsson C, Pines J, Kouzarides T: Differential localization of *HDAC4* orchestrates muscle differentiation. *Nucleic Acids Res* 2001; **29**: 3439–3447.
- Vega RB, Matsuda K, Oh J *et al*: Histone deacetylase 4 controls chondrocyte hypertrophy during skeletogenesis. *Cell* 2004; **119**: 555–566.
- van Karnebeek CDM, Koevoets C, Sluijter S *et al*: Prospective screening for subtelomeric rearrangements in children with mental retardation of unknown aetiology: the Amsterdam experience. *J Med Genet* 2002; **39**: 546–553.
- Rajan I, Savelieva KV, Ye GL *et al*: Loss of the putative catalytic domain of *HDAC4* leads to reduced thermal nociception and seizures while allowing normal bone development. *PLoS One* 2009; **4**: e6612.
- Bialek P, Kern B, Yang X *et al*: A twist code determines the onset of osteoblast differentiation. *Dev Cell* 2004; **6**: 423–435.
- Nakamura T, Toita H, Yoshimoto A *et al*: Potential involvement of *Twist2* and *Erk* in the regulation of osteoblastogenesis by HB-EGF-EGFR signaling. *Cell Struct Funct* 2010; **35**: 53–61.
- Tukel T, Susic D, Al-Gazali LI *et al*: Homozygous nonsense mutations in *TWIST2* cause Setleis syndrome. *Am J Hum Genet* 2010; **87**: 289–296.
- Cervantes-Barragan DE, Villarreal CE, Medrano-Hernandez A *et al*: Setleis syndrome in Mexican-Nahua sibs due to a homozygous *TWIST2* frameshift mutation and partial expression in heterozygotes: review of the focal facial dermal dysplasias and subtype reclassification. *J Med Genet* 2010; **48**: 716–720.
- Williams SR, Girirajan S, Tegay D, Nowak N, Hatchwell E, Elsea SH *et al*: Array comparative genomic hybridisation of 52 subjects with a Smith–Magenis-like phenotype: identification of dosage sensitive loci also associated with schizophrenia, autism, and developmental delay. *J Med Genet* 2009; **47**: 223–229.
- Casas KA, Mononen TK, Mikail CN *et al*: Chromosome 2q terminal deletion: report of 6 new patients and review of phenotype-breakpoint correlations in 66 individuals. *Am J Med Genet A* 2004; **130A**: 331–339.
- Wilson LC, Leverton K, Oude Luttikhuis MEM *et al*: Brachydactyly and mental retardation: an albright hereditary osteodystrophy-like syndrome localized to 2q37. *Am J Hum Genet* 1995; **56**: 400–407.
- Kilgore M, Miller CA, Fass DM *et al*: Inhibitors of class 1 histone deacetylases reverse contextual memory deficits in a mouse model of Alzheimer's disease. *Neuropsychopharmacology* 2010; **35**: 870–880.
- Morris B, Etoubleau C, Bourthoumieu S *et al*: Dose dependent expression of *HDAC4* causes variable expressivity in a novel inherited case of brachydactyly mental retardation syndrome. *Am J Med Genet Part A* 2012; **158A**: 2015–2020.
- Wolff DJ, Clifton K, Karr C, Charles J: Pilot assessment of the subtelomeric regions of children with autism: detection of a 2q deletion. *Genet Med* 2002; **4**: 10–14.
- Smith M, Escamilla JR, Filipek P *et al*: Molecular genetic delineation of 2q37.3 deletion in autism and osteodystrophy: report of a case and of new markers for deletion screening by PCR. *Cytogenet Cell Genet* 2001; **94**: 15–22.
- Bijlsma EK, Aalfs CM, Sluijter S *et al*: Familial cryptic translocation between chromosomes 2qter and 8qter: further delineation of the Albright hereditary osteodystrophy-like phenotype. *J Med Genet* 1999; **36**: 604–609.
- Reddy KS, Flannery D, Farrer RJ: Microdeletion of chromosome sub-band 2q37.3 in two patients with abnormal situs viscerum. *Am J Med Genet* 1999; **84**: 460–468.
- Galasso C, Lo-Castro A, Lalli C, Nardone AM, Gullotta F, Curatolo P: Deletion 2q37: an identifiable clinical syndrome with mental retardation and autism. *J Child Neurol* 2008; **23**: 802–806.

Supplementary Information accompanies the paper on European Journal of Human Genetics website (<http://www.nature.com/ejhg>)