

RESEARCH

Detection of cavitated approximal surfaces using cone beam CT and intraoral receptors

A Wenzel^{*1}, E Hirsch², J Christensen¹, LH Matzen¹, G Scaf³ and M Frydenberg⁴

¹Oral Radiology, Department of Dentistry, Aarhus University, Aarhus, Denmark; ²Department of Dentomaxillofacial Radiology, School of Dentistry, Leipzig University, Leipzig, Germany; ³Department of Oral Diagnosis and Surgery, Araraquara Dental School, State of São Paulo University, Araraquara, Brazil; ⁴Biostatistics, Department of Biomedicine, Aarhus University, Aarhus, Denmark

Objectives: The aim of this study was to compare cone beam CT (CBCT) in a small field of view (FOV) with a solid-state sensor and a photostimulable phosphor plate system for detection of cavitated approximal surfaces.

Methods: 257 non-filled approximal surfaces from human permanent premolars and molars were recorded by two intraoral digital receptors, a storage phosphor plate (Digora Optime, Soredex) and a solid-state CMOS sensor (Digora Toto, Soredex), and scanned in a cone beam CT unit (3D Accuitomo FPD80, Morita) with a FOV of 4 cm and a voxel size of 0.08 mm. Image sections were carried out in the axial and mesiodistal tooth planes. Six observers recorded surface cavitation in all images. Validation of the true absence or presence of surface cavitation was performed by inspecting the surfaces under strong light with the naked eye. Differences in sensitivity, specificity and agreement were estimated by analysing the binary data in a generalized linear model using an identity link function.

Results: A significantly higher sensitivity was obtained by all observers with CBCT ($p < 0.001$), which was not compromised by a lower specificity. Therefore, a significantly higher overall agreement was obtained with CBCT ($p < 0.001$). There were no significant differences between the Digora Optime phosphor plate system and the Digora Toto CMOS sensor for any parameter.

Conclusions: CBCT was much more accurate in the detection of surface cavitation in approximal surfaces than intraoral receptors. The differences are interpreted as clinically significant. A CBCT examination performed for other reasons should also be assessed for approximal surface cavities in teeth without restorations.

Dentomaxillofacial Radiology (2013) **42**, 39458105. doi: 10.1259/dmfr/39458105

Cite this article as: Wenzel A, Hirsch E, Christensen J, Matzen LH, Scaf G, Frydenberg M. Detection of cavitated approximal surfaces using cone beam CT and intraoral receptors. *Dentomaxillofac Radiol* 2013; **42**: 39458105.

Keywords: radiography; digital; computed tomography; diagnosis; dental caries

Introduction

A bitewing radiograph is the most common adjunct to a clinical examination for the diagnosis of carious lesions; however, a shortcoming of the radiograph is that it shows only a surface demineralization and not whether the caries disease is active or whether the lesion is merely scar tissue from previous activity. Moreover, the

bitewing radiograph is inaccurate in distinguishing between lesions with and without a cavity in the surface since the outer enamel surface may remain intact even when the lesion is observed well into the dentine.¹

It is crucial for the clinician to decide whether the surface is intact or cavitated since this determines the treatment plan. When the surface breaks down the biofilm is protected within the cavity, impeding cleaning, particularly in approximal surfaces. At this stage of the carious process restorative treatment is indicated, but not before. At a consensus workshop on

*Correspondence to: Ann Wenzel, Professor and Head, Oral Radiology, Department of Dentistry, Aarhus University, Vennelyst Blvd, 8000 Aarhus C, Denmark. E-mail: awenzel@odont.au.dk

Received 11 January 2012; revised 5 March 2012; accepted 8 March 2012

caries clinical trials one final statement was that “it is time to change strategy”, *i.e.* since a lesion in an intact surface may be arrested, only cavitated lesions should be treated operatively.²

There is a relationship between the depth of the lesion observed in the radiograph and the probability of cavitation of the surface; in ten studies from different parts of the world, the percentage of outer dentine lesions found to be cavitated has been shown to vary between 40% and 100%, as demonstrated in a review by Ratledge *et al*¹ In most of the studies from Western countries concerning permanent teeth in children and adolescents the fraction was 50–60%,^{3–5} meaning that the probability of cavitation when an outer dentine lesion is seen in a bitewing may be like tossing a coin. In primary teeth the fraction of cavitation observed in surfaces with demineralization into dentine in the radiograph was much higher.⁶

Previous *in vitro* studies have assessed the validity of cone beam CT (CBCT) scanning for detection of caries lesions. The majority found that CBCT was no more accurate than intraoral film, charge-coupled device (CCD) sensors or photostimulable storage phosphor systems for overall detection of lesions in approximal surfaces.^{7–12} One study found that CBCT was more accurate in estimating lesion depth than a film and a photostimulable storage phosphor system,¹³ and another found that CBCT had higher sensitivity for detecting dentinal lesions than CCD sensors.⁸ One study showed that neither the CBCT system nor the field of view (FOV) had an influence on diagnostic accuracy,¹¹ whereas another found lower accuracies with larger FOVs.⁹ On the basis of these findings, it may be agreed that little is gained by using CBCT for caries lesion detection compared with the traditional bitewing radiograph, particularly when also considering dose and resources. No study has, however, been conducted to assess the diagnostic validity of CBCT to distinguish between lesions that are cavitated and lesions that are only demineralized, leaving the surface intact.

The aim of this study was to compare a CBCT examination in a small FOV with a solid-state sensor and a photostimulable phosphor plate system for detection of cavitated lesions in approximal surfaces.

Material and methods

The study included 257 non-filled approximal surfaces in human permanent premolars and molars. The teeth were mounted in plaster in rows with four teeth in each (except for two which had five teeth). The teeth were placed in anatomical position from the apex to the cemento-enamel junction with approximal surfaces in contact and with the buccal surfaces facing the same direction.

The tooth blocks were positioned in a jig to provide a central beam orientation and recorded by two intraoral digital receptors, a storage phosphor plate (Digora

Optime, Soredex, Tuusula, Finland) and a solid-state CMOS (complementary metal oxide semiconductor) sensor (Digora Toto, Soredex), which were placed behind the blocks in close contact. All teeth were radiographed separately (one image per tooth) under standardized conditions (Gendex 1000 DC X-ray unit, Gendex, Des Plaines, IL): 65 kVp, 10 mA, 32 mm tooth–receptor distance, rectangular collimation, paralleling technique and the same target-to-receptor distance. A rubber glove filled with approximately 1 cm of water was placed between the tube extension and the teeth to simulate soft tissues. In the case of overlapping approximal surfaces the exposure was repeated until images with no overlaps were obtained, meaning that sometimes two images of the same tooth were recorded and saved. The images from both intraoral systems were exported to a general program developed for recording categorical data in digital images (Erik Gottfredsen, Department of Dentistry, Aarhus University, Denmark).

The tooth blocks were then scanned in a CBCT scanner (3D Accuitomo FPD80, Morita Corporation Ltd, Tokyo, Japan) with a FOV of 4 cm and a voxel size of 0.08 mm. The same soft-tissue simulation was used. The volumetric data were reconstructed and sections performed in the axial and mesiodistal (sagittal) tooth planes with a section thickness of 0.1 mm. The mean number of sections from one tooth in the axial plane was 19 (range 16–22) and in the sagittal plane 27 (range 20–34).

The intraoral images were displayed in random order and full size (1:1) on a 17 inch monitor. The same program kept track of the CBCT images and stated which image files should be opened next. One file contained all image sections in both planes, which were all viewed before scoring the tooth surface.

The tooth surfaces were scored in one of the following categories: 0, sound; 1, lesion in enamel without cavitation; 2, lesion in enamel with cavitation; 3, lesion one-third or less into the dentine without cavitation; 4, lesion one-third or less into the dentine with cavitation; 5, lesion more than one-third into the dentine without cavitation; 6, lesion more than one-third into the dentine with cavitation; 7, surface not recordable.

Six observers (two oral radiologists, two dental students and two postgraduate oral radiology trainees) independently recorded the surfaces with each of the three radiographic methods. The observers had varying experience with CBCT. Before the study, a rehearsal session was held, in which the observers became familiar with the scoring program and how to view the CBCT sections. Moreover, the literature on the relationship between radiographic lesion depth in bitewing radiographs and cavitation of the surface was recapitulated and discussed among the observers before scoring the images. When viewing the images, the room light was turned off.

Validation of the true absence or presence of a cavitated surface was performed by five observers, who

Table 1 Mean percentage (range) of sensitivity, specificity and overall agreement for each imaging method: Accuitomo, Digora Optime and Digora Toto

| Accuracy | Accuitomo | Digora Optime | Digora Toto |
|-------------|-------------|---------------|-------------|
| Sensitivity | 40 (26–58) | 17 (6–31) | 19 (3–24) |
| Specificity | 99 (98–100) | 100 (98–100) | 99 (99–100) |
| Agreement | 85 (83–88) | 80 (77–83) | 80 (76–82) |

were different from those scoring the radiographs. The observers inspected the cleaned surfaces under strong light with the naked eye, and a surface with a substance loss and a distinct rim was scored as cavitated. In cases of disagreement, a consensus between the observers was calculated: the score (cavity/non-cavity) reached by the majority (three or more) of the observers was the consensus score. 62 surfaces (24%) were cavitated. The majority of the cavities were between 0.5 mm and 1 mm in diameter. This registration served as the validation or so-called gold standard for the surface.

Data analysis

The outcome was cavity/no cavity on the surface; therefore, radiographic scores 2, 4 and 6 were combined (cavity) and so were scores 0, 1, 3 and 5 (no cavity). Thus, lesion depth was not taken into account in the present analysis of the data. For each observer and each radiographic modality, the sensitivity, specificity and overall agreement (true positives + true negatives/all scores) were computed by comparing the radiographic scores with the validation. The difference in sensitivity, specificity and agreement was estimated by analysing the binary data assuming additive effects of observer and modality in a generalized linear model using an identity link function. The correlation within surfaces was adjusted for by applying robust standard errors. Pairwise comparisons between modalities were performed by Wald tests. The level of statistical significance was $p < 0.05$.

Results

Table 1 presents mean sensitivities, specificities and agreement for each radiographic method for the total sample. Table 2 presents the differences with confidence intervals among the imaging methods. Figure 1 shows a tooth with two approximal surfaces scored as cavitated by CBCT and as non-cavitated by the intraoral systems. According to the validation method, these

lesions had cavities in both surfaces; thus with CBCT a true-positive score and with the phosphor plate a false-negative score was obtained.

A significantly higher sensitivity (Figure 2a) was obtained by all observers with the Accuitomo CBCT ($p < 0.001$), which was not compromised by a significantly lower specificity (Figure 2b). Therefore, a significantly higher overall agreement was also obtained with CBCT ($p < 0.001$; Figure 2c). There were no significant differences between the Digora Optime storage phosphor plate system and the Digora Toto CMOS sensor for any parameter ($p > 0.05$).

Discussion

Like all previous studies on caries lesion detection with CBCT, this study was *ex vivo* in a mixed-tooth sample, and more noise and artefacts may be expected in CBCT sections after examination of patients. It is well known that artefacts of various origin may occur in CBCT images¹⁴ and that beam hardening is a common feature in images of teeth with metal restorations.¹⁵ It has also been shown that detection of demineralization in tooth surfaces using CBCT was much more accurate in approximal than in occlusal surfaces,⁸ probably also because of artefacts from the thicker and denser occlusal enamel; this means that the present results are limited to approximal surfaces in non-filled teeth.

There has been a steady decline in caries prevalence throughout the world during the last decades,^{16–20} and a larger fraction of children and adolescents have few or no tooth restorations. Our study included only teeth with natural carious lesions, of which 24% had a naturally developed cavity in the surface at a site susceptible to caries. We believe therefore that the results are likely to simulate the clinical situation. Owing to the differences between *in vitro* and *in vivo* studies, a clinical trial of the relationship between cavitation observed with CBCT and the clinical appearance of the surface should be conducted.

Cavitated carious lesions in occlusal surfaces should be detected by visual and tactile clinical examination, although cavitated approximal surfaces may not be accessible clinically. Therefore, a radiographic examination has traditionally been an adjunct to clinical examination for diagnosing caries lesions in approximal surfaces. However, the two-dimensional bitewing examination has the limitation that it only displays demineralization on the surface. Not only is the lesion seen in the radiograph merely a historic reflection of

Table 2 Difference (95% confidence interval) in sensitivity, specificity and overall agreement among the imaging methods Accuitomo, Digora Optime and Digora Toto

| Accuracy | Optime vs Accuitomo | Toto vs Accuitomo | Optime vs Toto |
|-------------|-----------------------------------|-----------------------------------|------------------|
| Sensitivity | –22.5 (–30.4; –14.6) ^a | –22.0 (–30.7; –13.4) ^a | 0.4 (–3.3; 4.2) |
| Specificity | 0.4 (–0.6; 1.5) | 0.2 (–0.6; 1.0) | –0.2 (–0.9; 0.5) |
| Agreement | –5.4 (–7.8; –3.1) ^a | –5.2 (–7.6; –2.7) ^a | 0.3 (–1.0; 1.5) |

^a $p < 0.001$.

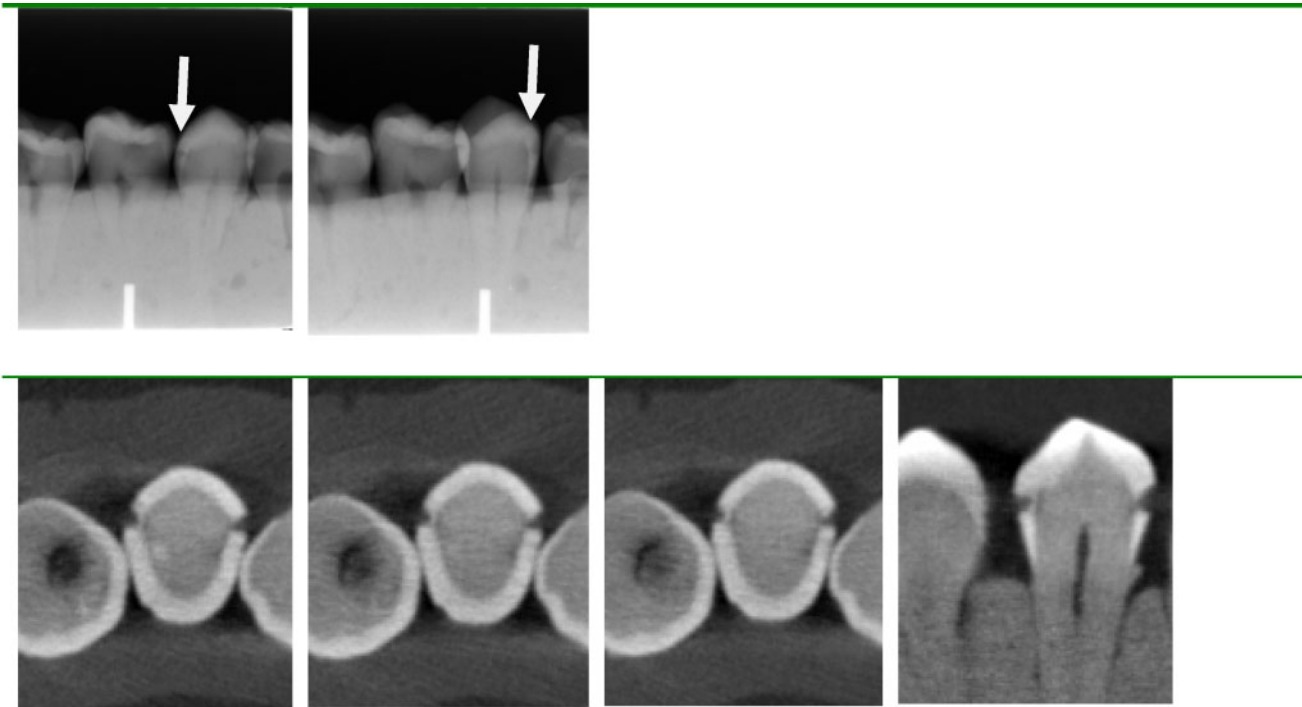


Figure 1 Demineralization just into dentine in both approximal surfaces (arrows) of a premolar scored as non-cavitated in the images from the phosphor plate system (upper row) and scored as cavitated by cone beam CT (lower row)

former bacterial activity, but, more importantly, in a summation image it is not possible to distinguish between lesions where loss of tooth substance has occurred on the surface and lesions where the surface is intact. This distinction is, however, crucial to the clinician for planning treatment since a surface may stay intact without breakdown even in cases of demineralization in the dentine. In digital radiographs it has been assessed whether objectively measured shades of grey constituting demineralization in approximal surfaces could predict surface cavitation, but no relationship was found.²¹ It may therefore be concluded that radiographic dentinal demineralization should not *per se* result in operative treatment of the surface. The observers in our study were well aware of this

relationship, and knowing that a diagnosis of cavitation would lead to operative treatment they were cautious in stating “cavitation” if they were not very sure. Therefore, few false-positive scores were made, which was connected to a rather low sensitivity in the intraoral images of less than 20%. This diagnostic strategy seems acceptable if the purpose is to avoid fillings in non-cavitated surfaces.

It may be logical that when thin tooth sections in more planes are available, as is the case in volumetric imaging, this will facilitate diagnosis of surface cavities. In our study we sectioned the teeth in the axial and the mesiodistal (which in the patient situation would be the sagittal) planes to view the surfaces in all directions, and usually a cavity, when observed, was seen in

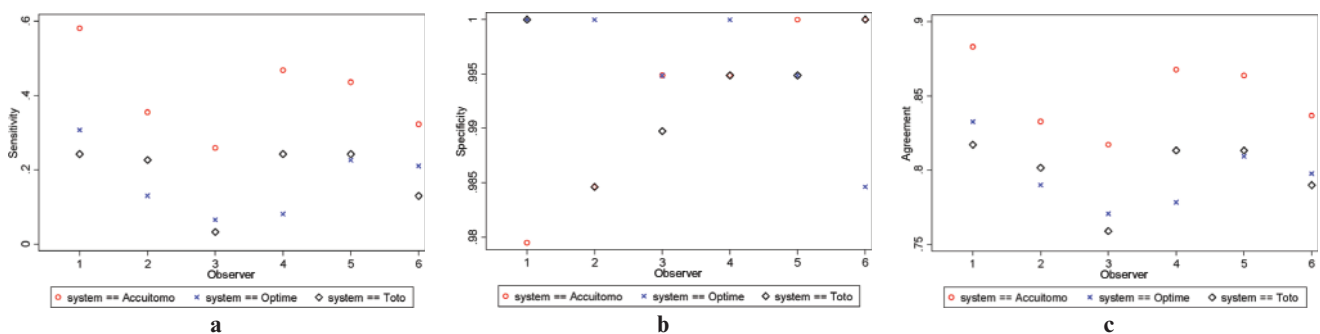


Figure 2 (a) Sensitivities for detection of cavitated approximal surfaces by six observers with three radiographic systems. (b) Specificities for detection of cavitated approximal surfaces by six observers with three radiographic systems. (c) Overall agreement for detection of cavitated approximal surfaces by six observers with three radiographic systems

both planes. The observers had varying experience with CBCT image sections, and the most experienced ones obtained higher sensitivities than those not well acquainted with the method. The most experienced radiologist (observer 1) had a sensitivity of almost 60% without compromising specificity (98%). This fact suggests that diagnostic accuracy increases with experience when examining CBCT images. The accuracy for detecting cavitation was quite high for CBCT images in this study, and it is noteworthy that the high sensitivity was not followed by a lower specificity, meaning that no more false-positive scores in surfaces that were in fact intact were scored with CBCT than with the intraoral systems.

Several studies have compared CBCT and intraoral receptors for detection of caries lesions, but none has evaluated surface cavitation. A recent study assessed defects drilled in trabecular bone adjacent to the apex in order to simulate apical periodontitis and found

that CBCT was more accurate than intraoral systems.²² The cavities in our study were, however, the result of progression of the caries disease to a stage where the surface breaks down, and we believe it is the first study to validate natural lesion cavitation.

In conclusion, CBCT was much more valid in the detection of surface cavitation in approximal surfaces than intraoral radiographic receptors. The differences are interpreted as clinically relevant. A CBCT examination performed for other reasons should also be assessed for approximal surface cavities in teeth without restorations.

Acknowledgments

The authors wish to thank Camilla Petri Petersen, Kathrine Mathiasen, Marjun Vang and Camilla Holm for acting as visual scoring of surface cavitation observers and Maria Vad Brændgaard and Malene Ledet for acting as radiograph observers.

References

1. Ratledge DK, Kidd EAM, Beighton D. A clinical and microbiological study of approximal carious lesions. Part 1: The relationship between cavitation, radiographic lesion depth, the site-specific gingival index and the level of infection of the dentine. *Caries Res* 2001; **35**: 3–7.
2. Kidd EAM, Fejerskov O. What constitutes dental caries? Histopathology of carious enamel and dentine related to the action of cariogenic biofilms. *J Dent Res* 2004; **83** (Special issue C): C35–C38.
3. Thylstrup A, Bille J, Quist V. Radiographic and observed tissue changes in approximal carious lesions at the time of operative treatment. *Caries Res* 1986; **20**: 75–84.
4. Pitts NB, Rimmer PA. An in vivo comparison of radiographic and directly assessed clinical caries status of posterior approximal surfaces in primary and permanent teeth. *Caries Res* 1992; **26**: 146–152.
5. Lunder N, von der Fehr FR. Approximal cavitation related to bite-wing image and caries activity in adolescents. *Caries Res* 1996; **30**: 143–147.
6. Nielsen LL, Hoernoe M, Wenzel A. Radiographic detection of cavitation in approximal surfaces of primary teeth with digital storage phosphor system and conventional film, and the relationship between cavitation and radiographic lesion depth: an in vitro study. *Int J Paediatr Dent* 1996; **6**: 167–172.
7. Tsuchida R, Araki K, Okano T. Evaluation of a limited cone-beam volumetric imaging system comparison with film radiography in detecting incipient proximal caries. *Oral Surg Oral Med Oral Pathol Oral Radiol Endod* 2007; **104**: 412–416.
8. Young SM, Lee JT, Hodges RJ, Chang TL, Elashoff DA, White SC. A comparative study of high-resolution cone beam computed tomography and charge-coupled device sensors for detecting caries. *Dentomaxillofac Radiol* 2009; **38**: 445–451.
9. Haiter-Neto F, Wenzel A, Gotfredsen E. Diagnostic accuracy of cone beam computed tomography scans compared with intraoral image modalities for detection of caries lesions. *Dentomaxillofac Radiol* 2008; **37**: 18–22.
10. Senel B, Kanburoglu K, Uçok O, Yüksel SP, Ozen T, Avsever H. Diagnostic accuracy of different imaging modalities in detection of proximal caries. *Dentomaxillofac Radiol* 2010; **39**: 501–511.
11. Qu X, Li G, Zhang Z, Ma X. Detection accuracy of in vitro approximal caries by cone beam computed tomography images. *Eur J Radiol* 2011; **79**: e24–27.
12. Kayipmaz S, Sezgin OS, Saricaoğlu ST, Can G. An in vitro comparison of diagnostic abilities of conventional radiography, storage phosphor, and cone beam computed tomography to determine occlusal and approximal caries. *Eur J Radiol* 2011; **80**: 478–482.
13. Akdeniz BG, Gröndahl HG, Magnusson B. Accuracy of proximal caries depth measurements: comparison between limited cone beam computed tomography, storage phosphor and film radiography. *Caries Res* 2006; **40**: 202–207.
14. Schulze RK, Heil U, Groß D, Bruellmann DD, Dranischnikow E, Schwanecke U, et al. Artefacts in CBCT: a review. *Dentomaxillofac Radiol* 2011; **40**: 265–273.
15. Schulze RK, Berndt D, d'Hoedt B. On cone-beam computed tomography artifacts induced by titanium implants. *Clin Oral Implants Res* 2010; **21**: 100–107.
16. Sqaan-Cohen HD, Amram-Liani D, Livny A. Changing dental caries levels in the 1980's, 1990's and 2005 among children in Jerusalem region. *Community Dent Health* 2009; **26**: 62–64.
17. Menghini G, Steiner M, Thomet E, Rath C, Marthaler T, Imfeld T. Further caries decline in Swiss recruits from 1996 to 2006. *Schweiz Monatsschr Zahnmed* 2010; **120**: 590–600.
18. Han DH, Kim JB, Park DY. The decline in dental caries among children of different ages in Korea, 2000–2006. *Int Dent J* 2010; **60**: 329–335.
19. Steiner M, Menghini G, Marthaler T, Imfeld T. Changes in dental caries in Zurich school-children over a period of 45 years. *Schweiz Monatsschr Zahnmed* 2010; **120**: 1084–1104.
20. Jacobsson B, Koch G, Magnusson T, Hugoson A. Oral health in young individuals with foreign and Swedish backgrounds – a ten-year perspective. *Eur Arch Paediatr Dent* 2011; **12**: 152–159.
21. Mariath AAS, Casagrande L, de Araujo FB. Grey levels and radiolucent lesion depth as cavity predictors for approximal dentin caries lesions in primary teeth. *Caries Res* 2007; **36**: 377–381.
22. Stavropoulos A, Wenzel A. Accuracy of cone beam dental CT, intraoral digital and conventional film radiography for the detection of periapical lesions. An ex vivo study in pig jaws. *Clin Oral Invest* 2007; **11**: 101–106.