

Case Report

Cerebral Aspergillosis with Multiple Enhancing Nodules in the Right Cerebral Hemisphere in the Immune-Competent Patient

Gwang-Jun Lee, M.D.,¹ Tae-Young Jung, M.D., Ph.D.,¹ Seong-Min Choi, M.D.,² Min-Young Jung, M.D.³

Departments of Neurosurgery,¹ Neurology,² Radiology,³ Chonnam National University Research Institute of Medical Sciences, Chonnam National University Hwasun Hospital & Medical School, Gwangju, Korea

Aspergillosis in the central nervous system (CNS) is a very rare disease in immune-competent patients. There was a case of a healthy man without a history of immune-compromised disease who had invasive aspergillosis with unusual radiologic findings. A 48-year-old healthy man with diabetes mellitus, presented with complaints of blurred vision that persisted for one month. Brain magnetic resonance imaging (MRI) showed multiple nodular enhancing lesions on the right cerebral hemisphere. The diffusion image appeared in a high-signal intensity in these areas. Cerebrospinal fluid examination did not show any infection signs. An open biopsy was done and intraoperative findings showed grayish inflammatory and necrotic tissue without a definitive mass lesion. The pathologic result was a brain abscess caused by fungal infection, morphologically aspergillus. Antifungal agents (Amphotericin B, Ambisome and Voriconazole) were used for treatment for 3 months. The visual symptoms improved. There was no recurrence or abscess pocket, but the remaining focal enhanced lesions were visible in the right temporal and occipital area at a one year follow-up MRI. This immune-competent patient showed multiple enhancing CNS aspergillosis in the cerebral hemisphere, which had a good outcome with antifungal agents.

Key Words : Aspergillosis · Cerebral · Enhancement · Immune-competent · Multiple.

INTRODUCTION

Aspergillosis of the central nervous system (CNS) is a very rare disease in immune-competent patients¹¹. Aspergillosis of the CNS could cause an altered mental status, seizures, and focal neurologic symptoms^{7,23}. It can present as aseptic meningitis, solitary or multiple CNS abscess and cerebral infarction^{1,5,6}. The main route of infection is the inhalation of spores into the lungs which is the primary site of infection leading to the hematogenous spread to other organs^{6,22}. The mortality rate of this infection is very high, and early diagnosis and rapid treatment are crucial^{25,26}.

We report the case of a healthy man without a history of immune-compromised disease who presented with multiple nodular enhancing aspergillosis in the right cerebral hemisphere and had the good clinical outcome after adequate conservative treatment after biopsy.

CASE REPORT

A 48-year-old man with diabetes mellitus, presented to the department of ophthalmology with the complaints of blurred vision that persisted for one month. There was defected visual accuracy in the left eye about 18 years ago. In ophthalmologic examination, there was no new lesion in the both eyes. The laboratory examinations were within normal range. The random blood glucose was 164 mmol/L and the glycosylated hemoglobin was 8.1%. Upon further evaluation, magnetic resonance imaging (MRI) of the brain showed a low-signal intensity on T1-weighted images and a high-signal intensity on T2-weighted images (Fig. 1A, B). After gadolinium enhancement, multiple nodular enhancing lesions with or without a focal necrotic area were shown in the right frontotemporoparietal cortex and white matter (Fig. 1C, D). The diffusion image appeared with high-signal intensity in these areas (Fig. 1E). The magnetic resonance spectroscopy

• Received : October 30, 2012 • Revised : February 17, 2013 • Accepted : May 13, 2013

• Address for reprints : Tae-Young Jung, M.D., Ph.D.

Department of Neurosurgery, Chonnam National University Hwasun Hospital, 322 Seoyang-ro, Hwasun-eup, Hwasun 519-763, Korea

Tel : +82-61-379-7666, Fax : +82-61-379-7673, E-mail : jung-ty@chonnam.ac.kr

• This is an Open Access article distributed under the terms of the Creative Commons Attribution Non-Commercial License (<http://creativecommons.org/licenses/by-nc/3.0>) which permits unrestricted non-commercial use, distribution, and reproduction in any medium, provided the original work is properly cited.

obtained from the right occipital region showed elevated lactate/lipid peaks, with mild decreased N-acetylaspartate and no elevation of choline, which suggested necrotic conditions. The lumbar-puncture examination cerebrospinal fluid did not show any infection signs. The body fluid parasite and anti-human immunodeficiency virus levels in the cerebrospinal fluid were negative.

An occipital craniotomy and biopsy was performed using the guidance of neuronavigation. In the operative field, there was a reddish color change of the cortex and the thickened arachnoid membrane had a yellowish color change (Fig. 2A). There was no definitive mass lesion. By using grasping forceps, the biopsy was done in the yellowish white matter. The biopsy showed many inflammatory cells containing some hyphae with the positive periodic acid-shiff stain (Fig. 2B). The pathology result showed a brain abscess caused by fungal infection that had the morphologically of aspergillus. Amphotericin B (50 mg/day) therapy was immediately started after the biopsy confirmation, but there were swelling, and skin eruptions at injection site, and fever. On the 3rd day of treatment, the antifungal agent was changed to ambisome (3 mg/kg/day). After 6 days, the serum creatinine level became elevated to 1.9 mg/dL and the antifungal agent was changed with voriconazole (400 mg/day). Voriconazole therapy was maintained for 3 months. The subjective visual symptom improved. There was no recurrence noted at the one year follow up MRI, but the remaining focal enhanced lesions were visible in the right temporal and occipital area (Fig. 1F).

DISCUSSION

Central nervous system aspergillosis is a rare disease in immuno-competent patients but there is a poor prognosis and a very high mortality (88-99%)^{7,16,22}. The stress of surgery may be a risk factor for fungal infection^{15,16}. Broad-spectrum antibiotics over a 3 month period could be a predisposing factor for CNS aspergillosis^{4,18}. The abuse of antibiotics may be a predisposing factor for CNS aspergillosis. This patient did not have any immuno-compromized disease other than those linked with diabetes mellitus.

Systemic aspergillus can be a risk factor of CNS aspergillosis²². Aspergillus invasion of the CNS usually occurs by the hematogenous spread from primary sources (such as the lungs or gastrointestinal tract)^{6,22}. This case did not show the systemic aspergillosis. Because of its ability to digest elastin in the vessel

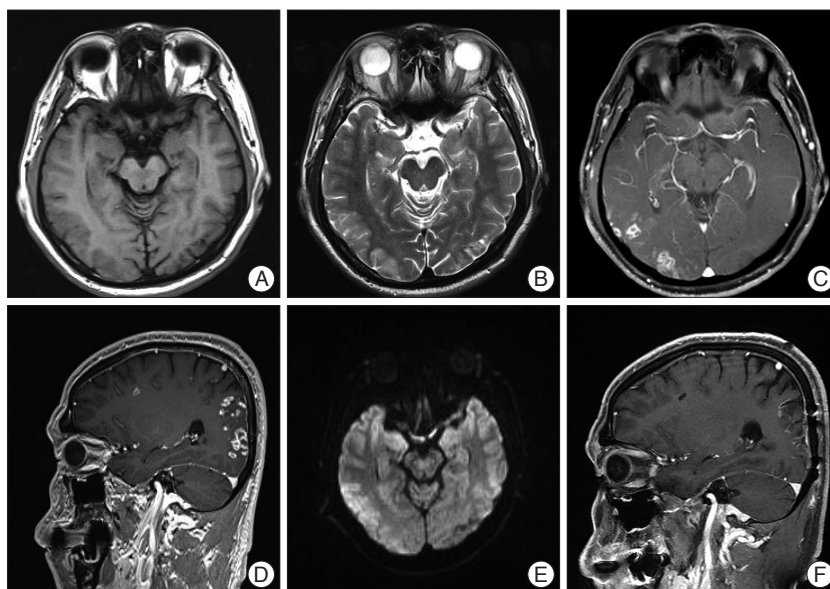


Fig. 1. Radiologic findings. A and B : In brain MRI, there are low-signal intensity on T1-weighted axial images and high-signal intensities in the T2-weighted axial image on right occipital cortex. C and D : Multiple enhancing nodules with necrotic change are shown in right frontotemporoparietal cortex and white matter. E : In diffusion MRI, the high-signal intensity lesions are shown in right frontotemporoparietal cortex and white matter. F : The recurrence does not appear in the right temporal and occipital area with remaining focal enhanced lesions.

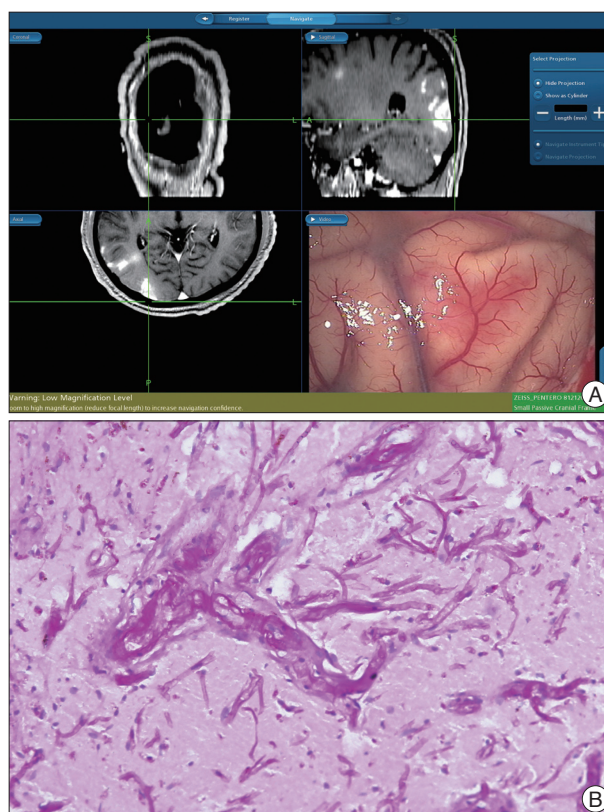


Fig. 2. Operative and pathologic findings. A : There was no definitive mass lesion, but reddish tissues of the cortex and the thickened yellowish arachnoid membrane are shown. B : In the biopsy, there are shown the hyphae with the positive periodic acid-shiff staining (original magnification $\times 200$).

walls, the fungus makes a highly virulent and angioinvasive organism^{6,22}. Hyphal elements may also grow through the vessel wall, compromising the structural integrity of the vessel wall and constructing aneurysms^{6,7,10,16,22}, so larger arteries could be ruptured and lead to hemorrhage. In addition, hyphal elements may occlude the lumen of the vessels completely, leading to ischemic stroke. Aspergillosis tends to occlude perforating arteries, so ischemic lesions may appear in sites that are rarely affected by other infectious organisms, such as the basal nuclei, thalami, corpus callosum, and brainstem^{1,3,28}.

Neuroimaging is useful in the diagnosis of CNS aspergillosis. In a brain computed tomography, the lesions have low attenuation and may be accompanied by hemorrhagic change^{6,16,22}. This case showed a low dense lesion without hemorrhage. Aspergillus abscesses generally appear as hypointense on non-enhanced T1-weighted MR images, but in some cases, high signal intensity lesions may be seen. The shortened T1 relaxation times may be related with the presence of iron, manganese, or methemoglobin in aspergillosis abscesses. In addition to abscess formation, CNS aspergillosis can rarely associated with mycotic aneurysm^{1,8}. Hemorrhagic lesions occur in 25% of cases^{1,28}. Dependent on the level of the inflammatory reaction, enhancement appears with variable features, with the stage of the infection and the immunity of the patient^{1,6}. On T2-weighted MR images, the lesions of low signal intensity at the periphery correspond to hemorrhage and can be seen on gradient-echo T2-weighted images^{1,27}. Zinreich et al.³⁰ demonstrated that the areas of low signal intensity on T2-weighted images were traced to the presence of iron, manganese, and magnesium in the fungal structures. Aspergillus abscesses have a dense population of hyphal elements peripherally, with a relative small lesions of fungal elements centrally, a feature that contributes to the distinct peripheral low signal intensity on T2-weighted images^{1,5}. On diffusion-weighted images, most CNS fungal abscesses appear in high signal intensity central areas, caused by the restricted diffusion of water in the presence of coagulative necrosis and polymorphonuclear cells, and the rim of the abscess may appear hypointense, caused by hemorrhagic or iron products^{1,20,24}. The ring enhancement lesions, especially in patients without known immunodeficiencies, can be solitary or multiple lesions^{21,26,28}. The ependymal and leptomeningeal enhancements are rare lesions, but dural enhancement may be visible^{6,16,22}. In immune-compromised patients, multiple ring enhancing lesions should distinguish lymphoma, metastatic disease, and multiple abscesses^{20,23}.

In this case, the MRI showed low-signal intensity on T1-weighted images and high-signal intensity on T2-weighted images with multiple nodular enhancing lesions in the right cerebral cortex and white matter. Also there was diffuse diffusion restriction in these areas. It was difficult to get the provisional diagnosis of fungal infection because the patient was immunocompetent with multiple enhancing lesions.

The definitive diagnosis is made with special staining and histopathological tests¹⁹. Hyphae with 45 degrees branches is a

typical and specific finding for aspergillosis^{11,14}. As a routine procedure, a surgical biopsy may help for the early diagnosis and subsequently early intervention^{4,13}. In unusual neuro-imaging appearances, even in patients that are immune-competent, treatment and evaluation about the fungal infection should be started as soon as possible with the hope for a better outcome. A search for the evidence of coexisting pulmonary or sinus infections should occur when evaluating this disease^{1,23}.

In CNS aspergillosis, a main cause of poor prognosis is the delay in diagnosis and the low penetration of antifungal agents into the CNS^{25,26}. The standard treatments of aspergillosis are the intravenous injection of amphotericin B or flucytocine and the oral medication of itraconazole¹⁷. Recently, a voriconazole is recommended for CNS aspergillus infection. But, this agent is expensive, so the actual medication is restricted. Even with high dose antifungal agents, the fatality rates range from 28% and 86%. The other fungal agents are, posaconazole and caspofungin. Amphotericin-B is a very useful antifungal agent, but has adverse effects (renal and hepatic toxicity, anemia, fever and electrolyte abnormalities), therefore therapeutic use is limited^{2,11}. A study by Herbrecht et al.⁹ compared voriconazole and amphotericin B in invasive aspergillus, and the success rate of treatment was high for voriconazole. In invasive aspergillus, many reports accepted that the efficacy and survival rate is higher with voriconazole than amphotericin B^{9,11}. A total or subtotal resection may be effective in a focal CNS aspergillosis lesion and one study showed that mortality can be reduced from 64% to 39%^{4,29}. Treatment of an antifungal agent alone has revealed a mortality of >90% in most series^{4,12}. However, this case showed a good prognosis. This patient had been treated for 3 months and showed a complete radiologic response.

CONCLUSION

This immune-competent patient showed the multiple enhancing CNS aspergillosis on the cerebral hemisphere, which showed a good outcome with antifungal agents. Although there was no history of immunodeficiency, early diagnosis and treatments are necessary a good outcome for the patient.

References

- Almutairi BM, Nguyen TB, Jansen GH, Asseri AH : Invasive aspergillosis of the brain : radiologic-pathologic correlation. *Radiographics* 29 : 375-379, 2009
- Alobid I, Bernal M, Calvo C, Vilaseca I, Berenguer J, Alos L : Treatment of rhinocerebral mucormycosis by combination of endoscopic sinus debridement and amphotericin B. *Am J Rhinol* 15 : 327-331, 2001
- Ashdown BC, Tien RD, Felsberg GJ : Aspergillosis of the brain and paranasal sinuses in immunocompromised patients : CT and MR imaging findings. *AJR Am J Roentgenol* 162 : 155-159, 1994
- Chen S, Pu JL, Yu J, Zhang JM : Multiple Aspergillus cerebellar abscesses in a middle-aged female : case report and literature review. *Int J Med Sci* 8 : 635-639, 2011
- Cox J, Murtagh FR, Wilfong A, Brenner J : Cerebral aspergillosis : MR imaging and histopathologic correlation. *AJNR Am J Neuroradiol* 13 :

- 1489-1492, 1992
6. DeLone DR, Goldstein RA, Petermann G, Salamat MS, Miles JM, Knechtle SJ, et al. : Disseminated aspergillosis involving the brain : distribution and imaging characteristics. *AJNR Am J Neuroradiol* 20 : 1597-1604, 1999
 7. Denning DW : Invasive aspergillosis. *Clin Infect Dis* 26 : 781-803; quiz 804-805, 1998
 8. Harris DE, Enterline DS : Neuroimaging of AIDS. I. Fungal infections of the central nervous system. *Neuroimaging Clin N Am* 7 : 187-198, 1997
 9. Herbrecht R, Denning DW, Patterson TF, Bennett JE, Greene RE, Oestmann JW, et al. : Voriconazole versus amphotericin B for primary therapy of invasive aspergillosis. *N Engl J Med* 347 : 408-415, 2002
 10. Klein HJ, Richter HP, Schachenmayr W : Intracerebral aspergillus abscess : case report. *Neurosurgery* 13 : 306-309, 1983
 11. Köse S, Cavdar G, Senger SS, Akkoçlu G : Central nervous system aspergillosis in an immunocompetent patient. *J Infect Dev Ctries* 5 : 313-315, 2011
 12. Lin SJ, Schranz J, Teutsch SM : Aspergillosis case-fatality rate : systematic review of the literature. *Clin Infect Dis* 32 : 358-366, 2001
 13. Liu W, Chen H, Cai B, Li G, You C, Li H : Successful treatment of sellar aspergillus abscess. *J Clin Neurosci* 17 : 1587-1589, 2010
 14. Maiorano E, Favia G, Capodiferro S, Montagna MT, Lo Muzio L : Combined mucormycosis and aspergillosis of the oro-sinonasal region in a patient affected by Castleman disease. *Virchows Arch* 446 : 28-33, 2005
 15. Merseburger AS, Oelke M, Hartmann J, Stenzl A, Kuczyk MA : Intracranial aspergillosis in a non-immunocompromised patient treated for muscle-invasive bladder cancer. *Int J Urol* 11 : 666-668, 2004
 16. Miaux Y, Ribaud P, Williams M, Guermazi A, Gluckman E, Brocheriou C, et al. : MR of cerebral aspergillosis in patients who have had bone marrow transplantation. *AJNR Am J Neuroradiol* 16 : 555-562, 1995
 17. Joung MK, Kong DS, Song JH, Peck KR : Concurrent nocardia related brain abscess and semi-invasive pulmonary aspergillosis in an immunocompetent patient. *J Korean Neurosurg Soc* 49 : 305-307, 2011
 18. Mylonakis E, Paliou M, Sax PE, Skolnik PR, Baron MJ, Rich JD : Central nervous system aspergillosis in patients with human immunodeficiency virus infection. Report of 6 cases and review. *Medicine (Baltimore)* 79 : 269-280, 2000
 19. Norlinah MI, Ngow HA, Hamidon BB : Angioinvasive cerebral aspergillosis presenting as acute ischaemic stroke in a patient with diabetes mellitus. *Singapore Med J* 48 : e1-e4, 2007
 20. Oner AY, Celik H, Akpek S, Tokgoz N : Central nervous system aspergillosis : magnetic resonance imaging, diffusion-weighted imaging, and magnetic resonance spectroscopy features. *Acta Radiol* 47 : 408-412, 2006
 21. Phuttharak W, Hesselink JR, Wixom C : MR features of cerebral aspergillosis in an immunocompetent patient : correlation with histology and elemental analysis. *AJNR Am J Neuroradiol* 26 : 835-838, 2005
 22. Pollack E, Bhaya A, Law M : Differentiating intracranial aspergillosis from a high grade glioma using MRI and MR spectroscopic imaging. *J Neuroimaging* 17 : 361-366, 2007
 23. Ruhnke M, Kofla G, Otto K, Schwartz S : CNS aspergillosis : recognition, diagnosis and management. *CNS Drugs* 21 : 659-676, 2007
 24. Schaefer PW, Grant PE, Gonzalez RG : Diffusion-weighted MR imaging of the brain. *Radiology* 217 : 331-345, 2000
 25. Schwartz S, Thiel E : Update on the treatment of cerebral aspergillosis. *Ann Hematol* 83 Suppl 1 : S42-S44, 2004
 26. Siddiqui K, Douglas M, Carey M, Benamer H : A case of invasive aspergillosis in a patient with no identifiable immunodeficiencies. *Libyan J Med* 3 : 49-51, 2008
 27. Tempkin AD, Sobonya RE, Seeger JF, Oh ES : Cerebral aspergillosis : radiologic and pathologic findings. *Radiographics* 26 : 1239-1242, 2006
 28. Yamada K, Shrier DA, Rubio A, Shan Y, Zoarski GH, Yoshiura T, et al. : Imaging findings in intracranial aspergillosis. *Acad Radiol* 9 : 163-171, 2002
 29. Young RF, Gade G, Grinnell V : Surgical treatment for fungal infections in the central nervous system. *J Neurosurg* 63 : 371-381, 1985
 30. Zinreich SJ, Kennedy DW, Malat J, Curtin HD, Epstein JI, Huff LC, et al. : Fungal sinusitis : diagnosis with CT and MR imaging. *Radiology* 169 : 439-444, 1988