

Close Contact Precautions could Prevent an Outbreak of Crimean-Congo Hemorrhagic Fever: A Case Series Report from Southern Part of Tehran

Masoud Mardani, Najmeh Namazee

Department of Infectious Diseases and Tropical Medicine, Shaheed Beheshti University (MC), Tehran, Iran

Correspondence to:

Dr. Najmeh Namazee,
Department of Infectious Diseases and Tropical Medicine, Shaheed Beheshti University (MC), Tehran, Iran.
E-mail: namazee_n@yahoo.com

Date of Submission: Apr 15, 2012

Date of Acceptance: Apr 28, 2012

How to cite this article: Mardani M, Namazee N. Close contact precautions could prevent an outbreak of crimean-congo hemorrhagic fever: A case series report from southern part of Tehran. *Int J Prev Med* 2013;4:715-9.

ABSTRACT

Between the end of June and the middle of July 2011, an outbreak of Crimean-Congo Hemorrhagic Fever occurred in southern part of Tehran, Iran. This study reports clinical, laboratory findings and outcome of six cases, who were all consanguine. Index case who was livestock-worker died with hemorrhagic manifestations; thereafter his pregnant wife, three brothers, mother-in-law and his pregnant sister-in-law were admitted and except for the latter, ribavirin was administered. The brother with close contact with body fluids and blood of index case, died with hemorrhage. Low platelet, high aminotransferases and elevated PT, PTT were detected in this case. Skin manifestations were present in five cases. Only in one case RT-PCR and IgM serology were reported as positive for CCHF virus by reference laboratory. In endemic areas, high index of suspicion should be kept in mind in successfully finding and treating cases in early phase of the disease.

Key words: Crimean-Congo hemorrhagic fever, tick-borne disease, outbreak, ribavirin prophylaxis

INTRODUCTION

Crimean-Congo hemorrhagic fever is a tick-borne viral disease reported from more than 30 countries in Africa, Asia, South-East, Europe, and the Middle East.^[1] CCHF was first observed in the Crimea by Russian scientists in 1994.^[2]

It is a zoonotic viral disease caused by Nairovirus (family Bunyaviridae). The disease has a wide distribution that correlates with the global distribution of *Hyalomma* tick, the vector responsible for viral transmission.^[3]

Clinical manifestations are non-specific and may include fever, myalgia, rash and encephalitis. Symptoms typically include high fever, headache, malaise, arthralgia, myalgia, nausea, abdominal pain and non-bloody diarrhea. Early signs typically include fever, hypotension, relative bradycardia, tachypnea, conjunctivitis and pharyngitis.^[4]

The hemorrhagic phase lasts for 4–5 days and in a majority of the patients it progresses to hemorrhagic diathesis. These include petechia, conjunctival hemorrhage, epistaxis, hematemesis, hemoptysis and melena.^[5]

Not all the patients develop the classical illness which is fatal in 3–30% of cases.^[6]

Community-acquired CCHF happens through transmission of virus by direct contact with blood or other infected tissue of livestock or from an infected tick bite.^[7]

Outbreaks have been reported from neighboring countries, and nosocomial transmission is well described.^[8-12]

The efficacy of ribavirin in treatment^[13-15] and prophylaxis^[5] for CCHF have been reported.

In this study we describe an outbreak and present the clinical, laboratory values and outcome of the six patients with symptoms and signs of CCHF.

CASE REPORT

Case 1

On 25th June 2011 a 24-year-old female, pregnant with gestational age of 16 weeks, presented to the Loghman Hakim Hospital, Tehran, Iran, with chief complaint of hematemesis, petechia on upper extremities and palmar areas.

She denied history of vaginal bleeding, fever, myalgia, headache, arthralgia, diarrhea or rectorrhagia. She claimed to have a close contact with her husband who was a livestock-worker and had died the week before, with symptoms of bloody diarrhea and hematemesis. She also had a history of close contact with domestic animals as she worked with her husband.

The patient was immediately transferred to an isolated room and serum was obtained for CCHF virus serology and RT-PCR.

Her laboratory studies revealed normal aminotransferases and PT, PTT. On baseline laboratory tests, anemia and thrombocytopenia were detected. urine analysis did not show hematuria. Obstetric examinations were normal and sonography showed normal alive twin fetuses. Because of her life-threatening condition, therapeutic ribavirin dose was administered to her.

The patient's condition was satisfactory after five days and she was discharged of hospital, with oral ribavirin.

Case 2

On 29th June 2011, a 36-year-old male construction worker presented to the same hospital with chief complaint of fever, malaise, myalgia and headache,

ecchymoses and hematemesis unresponsive to conservative managements. His symptoms were started 3 days prior to admission. There was no history of recent travel or direct contact with domestic animals, but a history of contact with his brother's blood and body fluid, who had worked in a live stock and died about 10 days before his admission.

On physical examination, the patient was hypotensive (mean arterial blood pressure: 80 mmHg), respiratory rate 36/min and pulse rate 100/min.

The patient had yellowish discoloration of sclera, a few petechiae on hard palate and multiple ecchymoses on extremities were detectable.

Laboratory tests revealed leukocytosis, thrombocytopenia, increased PT, PTT, INR, aminotransferases, CPK and creatinine.

Fluid resuscitation and critical care managements were started. Ribavirin, loading and first doses were administered to him.

Serum IgG, IgM ELISA tests and RT-PCR for CCHF virus were obtained.

After a few hours of admission, the patient developed intractable hematemesis and epistaxis, not responding to medical managements; the patient's condition deteriorated and finally he died on 30th June, 2011. Surprisingly report of RT-PCR was negative for CCHF virus by reference laboratory.

His family members and all close contacts were informed to refer for evaluation. On 30th June, 13 suspicious cases were evaluated, 4 out of 13 were admitted to the hospital and the others who met the criteria for receiving prophylactic ribavirin were discharged with oral ribavirin. They advised to refer to the hospital in case of finding any sign or symptom of CCHF (temperature over 38.5 by mouth, headache, myalgia, petechia, arthralgia, or hemorrhagic manifestations.)

Figure 1 shows the consanguinity of these cases.

Case 3

This 41-year-old male construction worker, whose two brothers had died, denied any symptoms of fever, myalgia headache or abdominal pain, but on physical examination there were a few petechiae on buccal mucosa. He had neither close contact with his two dead brothers nor history of contact with domestic animals.

Laboratory studies were within normal values. Empirical ribavirin was started for him with therapeutic dose.

His serum was obtained for evaluation of CCHF virus. He was discharged of hospital after 5 days without any complications, with oral ribavirin. His report of RT-PCR for CCHF virus was negative.

Case 4

A 27-year-old male florist whose two brothers had died also was admitted with mild fever without any history of myalgia, arthralgia headache or bleeding. He did not recall close contact with his brothers or domestic animals.

On physical examination he showed mild fever and petechia on hard palate.

Laboratory tests were all reported within normal values. RT-PCR was reported negative for CCHF virus. Ribavirin was administered to him and he was also discharged from hospital with satisfactory condition.

Case 5

This 50-year-old female housewife, whose son-in-law (index case) had died, was admitted

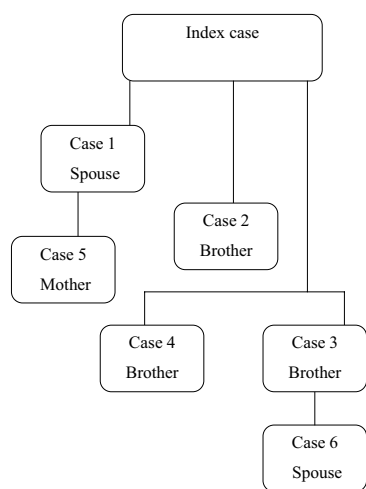


Figure 1: Organization scheme for the reviewing consanguinity of the cases

with suspicious symptoms and signs of CCHF. She claimed to have experienced myalgia, headache and fever. She had developed arthralgia, especially in both knees and shoulders a few days before admission. The patient had history of close contact with her daughter and her dead son-in-law.

Physical examinations revealed oral temperature of 38.5 and petechia on hard palate.

Laboratory tests showed mildly increased PT, INR and creatinine. Anemia and leukopenia were notable in baseline tests.

She also received ribavirin and became afebrile after 4 days. Platelet levels came into normal limits after 4 days ELISA IgM antibody and RT-PCR for CCHF virus were reported as positive in this patient by reference laboratory. Her general condition showed improvement.

The patient preferred to leave out the hospital the sixth day of treatment, so oral ribavirin was prescribed for her for the rest of treatment period.

Case 6

This 29-year-old pregnant female with gestational age of 32 weeks, whose two brothers-in-law had died, was admitted for better evaluation. She denied any history of bleeding, myalgia, arthralgia or fever. Physical examination and laboratory findings were all normal.

Obstetric examination and sonography showed normal alive fetus. The patient only was observed and was discharged after 3 days.

Her RT-PCR was reported negative for CCHF virus.

DISCUSSION

The first confirmed outbreak of CCHF in Iran was reported in June 1999.^[16] After that multiple

Table 1: Clinical manifestations, risk factors and outcome of cases

Patient	Fever	Myalgia	Petechia/ ecchymoses	Hemorrhagic manifestation	Occupation	Animal contact	Outcome
Index case	Yes	Yes	NA	Yes	Livestock worker	Yes	Dead
Case 1	No	No	Yes	Yes	Livestock worker	Yes	Alive
Case 2	Yes	Yes	Yes	Yes	Construction worker	No	Dead
Case 3	No	No	Yes	No	Florist	No	Alive
Case 4	Yes	No	Yes	No	Construction worker	No	Alive
Case 5	Yes	Yes	Yes	No	Housewife	No	Alive
Case 6	No	No	No	No	Housewife	No	Alive

NA: Data not available

reports from a few provinces showed that Iran should be known as an endemic area for CCHF.

In our case study all patients who were consanguine and had Afghan nationality, were living in Iran for a long time. The pregnant woman whose husband (index case) had died with hemorrhagic manifestations presented with suspicious signs and symptoms and received ribavirin. The use of ribavirin is now well established in most countries where CCHF is endemic.^[15]

Case 2, who had history of close contact with his brother's blood and body fluids, presented with hematemesis, bloody diarrhea and ecchymoses. The patient received loading and first dose of ribavirin, but ribavirin was administered to him when hemorrhagic manifestations had been established. Superior efficacy of early initiation of ribavirin has been discussed in different surveys.^[17,18] Investigations among 13 consanguine cases revealed four high risk cases who were admitted to the hospital. The others who met the criteria were administered prophylactics ribavirin and advised to refer in case of alarming signs and symptoms.

These signs and symptoms have been discussed in a study by Ertugrul *et al.*^[9]

In this outbreak the index case was a livestock worker who had history of contact with illegally imported cattles from the southeastern neighboring countries (Pakistan). There are some reports of CCHF outbreaks in southeastern neighboring countries.^[10]

In physical examination of the patients who were admitted skin manifestations especially petechia were present in 5 out of 6 and were the most common signs of the patients. Laboratory findings showed thrombocytopenia in two and leukopenia / leukocytosis each in one case.

Demographic, clinical characteristics and laboratory values have been shown in Tables 1–3.

PT, PTT, low platelet, aminotransferases rising and leukocytosis were all presented in case two and close contact with index case's body fluids and experienced severe disease and finally died. His outcome and laboratory findings reveal the importance of finding and treating the patients in early phase, and also the importance of contact prevention. For the individual, use of effective personal protective measures against tick bites and limiting animal exposure are the best ways to avoid the infection.^[19]

In this study two pregnant women were presented, one of them treated with ribavirin due to high index

Table 2: Demograaphic, clinical characteristics and outcome for the admitted patients

Characteristics	Value
Male	3 (6)
Symptoms and signs	
Fever	3 (6)
Petechia	5 (6)
Myalgia	2 (6)
Hemorrhagic manifestation	2 (6)
Abnormal laboratory findings	
Elevated AST, ALT	1 (6)
Leukocytosis	1 (6)
Leukopenia	1 (6)
Low platelet	2 (6)
Elevated PT, PTT	2 (6)
Outcome	
Alive	5 (6)

AST = Aspartate aminotransferase, ALT = Alanine aminotransferase, PT = Prothrombin time, PTT = Partial thromboplastin time

Table 3: Baseline laboratory studies of admitted cases

	WBC Count/ μ L	Hemoglobin g/dl	Platelet Count/ μ L	Creatinine mg/dl	AST U/L	ALT U/L	CPK U/L	PT sec	PTT sec	INR
Case 1	5400	7	58000	0.6	22	23	64	11	30.4	1
Case 2	21600	13.6	40000	2.2	4800	1200	7520	32.6	69	7.79
Case 3	5100	10.9	160000	1.3	18	32	122	11	33	1
Case 4	7400	14.7	307000	1.1	28	26	50	11	28	1
Case 5	2900	8.5	139000	1.5	49	18	150	12.7	40	1.3
Case 6	9200	10.7	247000	0.7	14	10	44	11	24	1

WBC = White blood cell, creat, creatinine; AST = Aspartate aminotransferase, ALT = Alanine aminotransferase, CPK = Creatinine phosphokinase, PT = Prothrombin time, PTT = Partial thromboplastin time, INR = International normalization ratio

of clinical suspicion, high illness to infection ratio of CCHF and high mortality.

A suspected patient should be placed in a private room, and negative-pressure respiratory isolation should be considered, particularly if coughing, vomiting, or other activities generating large-droplet aerosols occur. Those entering the patient's room should wear gloves and gowns, and those approaching within meter should wear face shields or surgical masks and eye protection to prevent contact with blood or other body fluids.^[19] As there is evidence on the effectiveness of preventive interventions and a significant reduction in mortality^[20], preventive attempts, play an important role in reducing transmission of this highly contagious disease.

This study only described manifestations, management and outcome of the cases in an outbreak. Larger and controlled studies are needed to evaluate the various aspects of the disease.

REFERENCES

- Mardani M, keshtkar-Jahromi M, Ataei B, Adibi P. A Report of Nosocomial Crimean-Congo Hemorrhagic Fever (CCHF) in Iran. *Am J Trop Med Hyg* 2009;81:675-8.
- Pirkani SG, Jomezai EK, Ilyas M. Crimean-Congo hemorrhagic fever (CCHF) in Blochistan. *Survey Report. Prof Med J* 2006;13:464-7.
- Lacy MD, Smego RA. Viral hemorrhagic fevers. *Adv pediatr Infect Dis* 1996;12:21-53.
- Hoogstraal H. The epidemiology of tick-borne Crimean-Congo hemorrhagic fever in Asia, Europe and Africa. *J Med Entomol* 1979;15:307-17.
- Appannanvar SB, Mishra B. An update on Crimean-Congo hemorrhagic fever. *J Glob Infect Dis* 2011;3:285-92.
- Rhanavardi M, Rajaeinejad M, Pourmalek F, Mardani M, Holakouie-Naieni K, Dowlathshahi S. Knowledge, and attitude toward Crimean-Congo hemorrhagic fever in occupationally at risk Iranian healthcare workers. *J Hosp Infect* 2008;69:77-85.
- Athar MN, Baqai HZ, Ahmad M, Khalid MA, Bashir N, Ahmad AM, *et al.* Crimean-Congo hemorrhagic fever outbreak in Rawalpindi, Pakistan. *Am J Trop Med Hyg* 2003;69:284-287.
- Ergonul O, Celikbas A, Dokuzoguz B, Eren S, Baykam N, Esener H. Characteristics of patients with Crimean Congo hemorrhagic fever in a recent outbreak in Turkey and impact of oral ribavirin therapy. *Clin Infect Dis* 2004;39:284-7.
- Ertugrul B, Uyar Y, Yavas K, Turan C, Oncu S, Saylak O, *et al.* An outbreak of Crimean-Congo hemorrhagic fever in western Anatolia, Turkey. *Intern J Infect Dis* 2009;13:e431-6.
- Athar M, Khalid MA, Ahmad AM, Bashir N, Baqai HZ, Ahmad M, *et al.* Crimean-Congo hemorrhagic fever outbreak in Rawalpindi, Pakistan, February 2002; Contact tracing and risk assessment. *Am J Trop Med Hyg* 2005;72:471-3.
- Mardani M. Nosocomial Crimean-Congo hemorrhagic fever in Iran, 1999 - 2000. *Clin Microbiol Infect* 2001;7(suppl 1):213.
- Weber DJ, Rutala, WA. Risk and Prevention of nosocomial transmission of rare zoonotic diseases. *Clin Infect Dis* 2001;32:446-56.
- Tasdelen Fisgin N, Ergonul O, Doganci L, Tulek N. The role of ribavirin in the therapy of Crimean-Congo hemorrhagic fever: Early use is promising. *Eur J Clin Microbiol Infect Dis* 2009;28:929-33.
- Soares-Weiser K, Thomas S, Thomson G, Garner P. Ribavirin for Crimean-Congo hemorrhagic fever: Systematic review and meta-analysis. *BMC Infect Dis* 2010;10:207.
- Keshtkar-Jahromi M, Kuhn JH, Christova I, Bradfute SB, Jahrling PB, Bavari S, *et al.* Crimean-Congo hemorrhagic fever: Current and future prospects of vaccines and Therapies. *Antiviral Res* 2011;90:85-92.
- Mardani M, Keshtkar-Jahromi M, Naieni KH, Zeinali M. The efficacy of oral ribavirin in the treatment of Crimean Congo hemorrhagic fever in Iran. *Clin Infect Dis* 2003;36:1613-8.
- Metanat M, Sharifi-Mood B, Salehi M, Alavi Naini R. Clinical outcome in Crimean-Congo hemorrhagic fever: A five-years experience in treatment of patients in oral ribavirin. *Int J Virol* 2006;2:21-4.
- Sharifi-Mood B, Metanat M, Ghorbani-Vaghei A, Fayyaz-Jahani F, Akrami E. The outcome of patients with Crimean-Congo hemorrhagic fever in Zahedan, Southeast of Iran: A comparative study. *Arch Iran Med* 2009;12:151-3.
- Mardani M, Keshtkar-Jahromi M. Crimean-Congo Hemorrhagic Fever. *Arch Iran Med* 2007;10:204-14.
- Ghadirian L, Sayarifard A. Isn't it the time for working on public health guidance in health system of Iran? *Int J Prev Med* 2013;4:125-7.

Source of Support: Nil **Conflict of Interest:** None declared.