

# CHROMOBACTERIUM VIOLACEUM, VAR. MANILAE AS A PATHOGENIC MICROÖRGANISM<sup>1</sup>

HERBERT J. SCHATTENBERG AND WILLIAM H. HARRIS

*Department of Pathology of Tulane University, School of Medicine and Tulane Service of the Charity Hospital of Louisiana, New Orleans*

Received for publication, March 10, 1942

A definite and rapidly fatal infection of the human subject with *Chromobacterium violaceum*, var. *manilae* afforded the culture concerned in the present study.

It is noteworthy that heretofore there have appeared in the literature only two reports concerning infection of the human subject and one of several carabao or water-buffalo with the microörganism usually termed *Bacillus violaceus*. It is of additional interest that all such infections in man or animal have sooner or later proved fatal to the invaded host.

It seems probable that *C. violaceum* has, in general, been erroneously considered as a distinctly non-pathogenic saprophyte because of lack of regard for group differentiation. Without proper recognition of variance for separate species as regards pathogenicity, it becomes difficult to comprehend that a supposedly innocuous chromobacterium should rarely become not only pathogenic but also possessive of death-producing virulence. Because of such facts, it appears in order to present briefly the salient features of the present day knowledge appertaining to *C. violaceum*.

## THE MICROÖRGANISM

This organism, a gram-negative, motile bacillus, first described by Schroeter in 1872, represents the type species of the genus *Chromobacterium* of Bergonzini (1881). A complete description of this group of microorganisms is given by Ford (1927). In as much as those working in the field of pathogenic bacteria have little if any knowledge of the many allied saprophytic varieties of this group, a review of this subject as presented by Ford will be found of value.

The particular strain studied by us conforms, in general, to that described by Woolley (1905) in an indefensible trinomial form as "*B. violaceus Manilae*." The morphological and biological characteristics of this bacillus will not be recounted in detail. Contrary to many members of this group, the optimum temperature of cultivation is 37°C. Upon potato media this organism presents a profuse rich violet growth, the purple pigment diffusing into the water of condensation. Its strong aerophilic proclivity is most striking as demonstrated by its surface flotation growth on tubed liquid media and heavy surface growth upon stab culture. Only scant, non-pigmented growth occurs along the stab beneath the surface. It liquefies gelatin to only a slight extent. Certain biochemical reactions upon various carbohydrate serum waters and pigment solubility in alcohol are quite consistent. As for other strains wherein the microö-

<sup>1</sup> Aided by a grant from the David Trautman Schwartz Research Fund.

ganism was of proven pathogenicity, no evidence of definite soluble or exotoxin production could be demonstrated.

The generally accepted opinion regarding the non-pathogenic and saprophytic nature of "*B. violaceus*" forms a distinct paradox to the high degree of pathogenicity for laboratory animals manifested by the cultures isolated from the few reported human cases.

#### DISEASE PRODUCTION

As stated, the instances on record wherein *C. violaceum* has demonstrated a definite pathogenic role are very limited. They consist of observations upon lower animal infection and in addition, two human invasions. These may be briefly summarized in chronological order:

In 1905 Woolley, described several fatal cases of infection in carabao or water-buffalo in Manila. These animals died suddenly with symptoms of acute hemorrhagic septicemia. Necropsy showed enlarged injected lymph glands and the lungs were studded with small firm gray nodules. *C. violaceum* was recovered from cultures of the lymph nodes and lungs. Since he could find no reference in the literature to the pathogenicity of *C. violaceum*, Woolley carried out rather extensive animal experimentation. He succeeded in reproducing the lesions of the carabao in various types of small animals by inoculation of the microorganism and was able to recover it in pure and abundant culture from the lesions and the heart's blood. He did not find evidence of any soluble toxin production for his strain. He termed this microorganism "*B. violaceus Manilae*."

Black and Shahan (1937), in Florida, reported what was apparently the first instance of definite infection with *C. violaceum* in man. The case was that of a six-year-old boy in whom *C. violaceum* was recovered from persistent "anthrax-like lesions" of the trunk and upper extremities.

This patient apparently had been perfectly well until the onset of his infection. He had waded in a pool two or three days previously. His first complaint was pain in the inguinal region and he presented later an acute inguinal adenitis. There eventually occurred multiple "anthrax-like lesions" over the trunk and upper extremities which were surrounded by a pustular ring showing a distinct violet color. Smears from these lesions showed a slender gram-negative bacillus. Culture on agar produced deep violet colonies. Agglutination tests were positive with dilutions to 1-1280. One rabbit was injected subcutaneously with a bouillon culture and died 48 hours later. *C. violaceum* was recovered in pure culture from the liver, lungs, spleen, kidneys, heart's blood, and site of inoculation of the animal. Following a stormy course the patient's skin lesions finally healed and he apparently recovered. It is to be noted, however, in a subsequent report of Soule (1939) in referring to this child that he reappeared thirteen months later with severe cervical adenitis, high fever and prostration. The adenitis abated and the body became covered with lesions varying from minute vesicles to large gangrenous areas. The boy died fifteen months after the original onset of his illness or thirteen months after the apparent healing of the original skin lesions. *C. violaceum* was the only organism ever incriminated

during the course of his infection. Unfortunately no necropsy was performed through which further study could have been made.

In 1939 Soule, in Michigan recorded the second fatal instance of human infection in which *C. violaceum* was isolated. The necropsy protocol of this case was presented by Weller. Pure cultures were obtained from the heart's blood, spleen and liver of a girl of fifteen years. This patient for nine months prior to death had suffered from a cervical adenitis which was diagnosed clinically and by biopsy, as tuberculosis even though *C. violaceum* was isolated from "pus" aspirated from the lesion. The tuberculin test, X-ray of the chest, as well as special cultures and guinea pig inoculation revealed no evidence of tuberculous infection. The material for animal injection was as usual, first treated with 4% potassium hydroxide. This chemical treatment apparently killed any *C. violaceum* present and would account for its failure to infect the animal. At necropsy of the patient, focal necrotized lesions were found in the lungs, spleen, liver and pelvic peritoneum which grossly resembled tuberculosis. Histologically these lesions proved to be of a necrotized, proliferative and, to some extent, pyogenic type presenting no essential evidence of tuberculous reaction. *C. violaceum* was recovered from the heart's blood and "pyemic abscesses" in the liver. The strain of *C. violaceum* isolated in this case was compared by Soule with the culture of Black and Shahan and with "2 old laboratory strains" of *C. violaceum*. Each strain produced the characteristic deep violet color *in vitro*, and the 4 strains appeared to be identical morphologically. Certain cultural differences were, however, noted. With experimental animals, he found that broth suspensions of each of the 4 strains were toxic in quantities of 0.5 ml.

In our recently encountered instance, the infection of *C. violaceum* demonstrated a rapid and fulminating invasion of the human subject. The patient was a robust young colored man who previously had enjoyed excellent health. There was no history of protracted or obscure infection occurring over many months as in the other reported cases. A rapid and definite invasion by *C. violaceum* occurred through a thorn wound of the foot with resulting inguinal adenitis, septicemia (positive blood culture) and death of the patient seven days after the onset. The details of the clinical case including the summarized necropsy are reported elsewhere (Schattenberg 1941).

At necropsy cultures were prepared upon various types of media from the lesions of the liver, lungs, inguinal lymph nodes and heart's blood and all of these yielded heavy growths of *C. violaceum*.

#### SALIENT AND COMPARATIVE PATHOLOGY

A marked necrosis of the inguinal lymph glands and disseminated bizarre-shaped pulmonary and hepatic nodules represented the tangible gross pathological factors present in this case. From the microscopic standpoint, the outstanding characteristic feature consisted of necrosis with comparatively little cellular response (figs. 1 and 2).

The necrosis did not conform grossly to the curdy or granular aspect of caseation nor was it similar to the pathological aspect of coagulation necrosis. It

had in the gross, the firmness of the latter lesion but microscopically conformed to the former or tuberculous necrosis. *En masse*, however, as found in the extensive glandular lesions there was evidence of liquefaction necrosis.

The reported instances of human infection with *C. violaceum* by Black and Shahan, and Soule present a clinicopathological aspect different from the present case. In the report of Black and Shahan, while systemic symptoms were recorded, the external skin lesions were emphasized. Inguinal adenitis had occurred in the early onset and eventually, after some months, extensive cervical adenitis developed during what was considered a "flare up" or recrudescence leading to death. Unfortunately no necropsy was held and no bacteriological

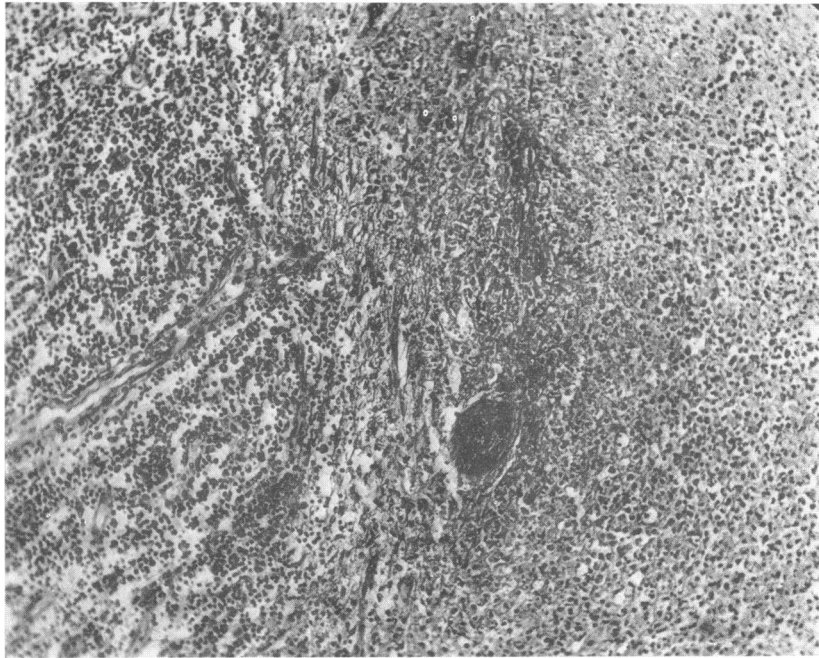


FIG. 1. PHOTOMICROGRAPH OF HUMAN INGUINAL LYMPH GLAND

Approximately two-thirds of the right portion demonstrates extensive necrosis of the lymphoid structure.  $\times 150$ .

study during the terminal "relapse" was reported. The total period of time involved from infection to death was fifteen months. The report of Soule has as yet appeared only in abstract form. This case was also of protracted duration, lasting nine months. A massive cervical adenitis was considered as tuberculous although only *C. violaceum* had been recovered by aspiration from the lesion. While a biopsy indicated possible tuberculosis, all efforts to demonstrate *Mycobacterium tuberculosis* failed, including special culture and guinea pig inoculation. The validity of infection by *C. violaceum* appeared, however, to have been established through the necropsy, at which time this microorganism was recovered from the heart's blood, liver and lung lesions. The pathology of

the cervical glands represented both a chronic proliferative and pyogenic type of reaction. This work is to be published more fully at a later time after continued study and observations have been completed.

It is noteworthy that marked adenitis has been found in all recorded human cases. Woolley also noted in the carabao marked enlargement of the pre-scapular glands. The rapidly fatal manifestations observed in these animals suggested to him hemorrhagic septicemia of cattle. The description of the

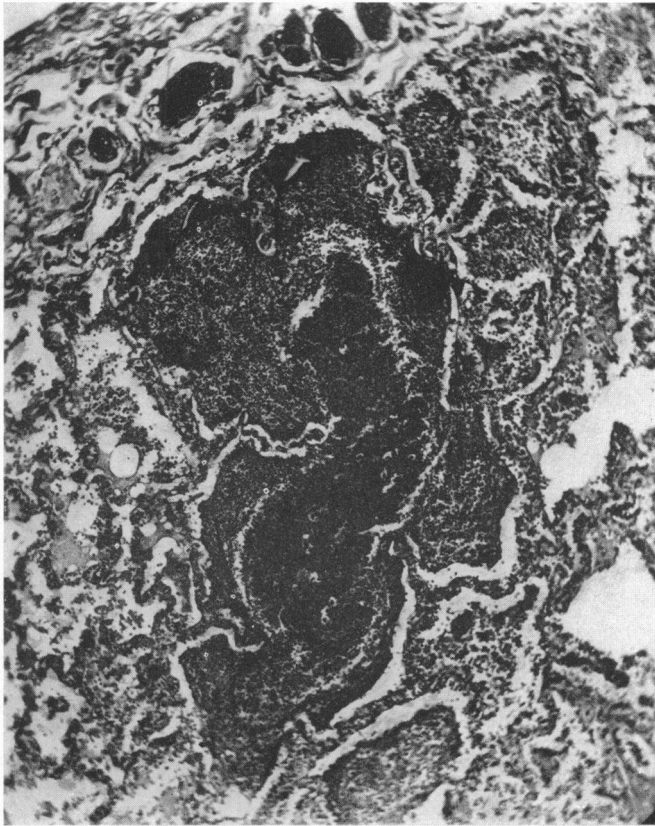


FIG. 2. PHOTOMICROGRAPH OF A NECROTIC AREA IN THE HUMAN LUNG

Extensive tissue destruction and karyorrhexis with resultant confluence of structure is present.  $\times 100$ .

lesions found at necropsy by Woolley conformed in general to those observed in our human subject. He obtained positive cultures of *C. violaceum* from the lymph nodes and lung lesions. His cultures proved pathogenic for many types of lower animals. He was convinced that *C. violaceum* was the causative factor of infection in the carabao. It may be stated that in general the clinical, bacteriological and pathological features of the human infection herein concerned conformed in all respects to those reported by Woolley in the carabao.

## EXPERIMENTAL

Certain phases of experimental study have been undertaken by us with the culture of *C. violaceum* isolated from the human infection herein described. These consist of studies upon pathogenicity with reproduction of the disease in the lower animals, mouse protection against infection and experimentation appertaining to the probable route of infection. One of us (Schattenberg 1940-1941) has recently presented preliminary reports upon certain of these observations. It is intended herein to stress especially the salient observations upon the pathogenicity of this strain for experimental animals and to deal briefly with the experiments upon protection against infection as well as those bearing upon the probable route of invasion by *C. violaceum*.

*Pathogenicity*

In all, fifty white mice, twelve rabbits, and ten guinea pigs were utilized.

*White mice.* The cultures employed were principally subcultures of that recovered from the human host. These cultures were grown in glucose broth and on nutrient agar. The injections of suspensions containing approximately one billion microorganisms per ml. were given intra-abdominally. All injected animals died and *C. violaceum* could readily be recovered from the peritoneal cavity and heart's blood. Where gross lesions were evident in the lungs, liver and spleen, positive cultures were obtained therefrom. Death of these animals occurred in from ten hours to three days, according not only to dosage but the media upon which the culture was grown. It was noted that the broth cultures, even in smaller doses, proved more virulent than the washings of the solid slanted medium. The doses of each type of suspension varied from .05 ml. up to 1 ml. In those animals that survived for three days gross lesions were found which conformed to those described in the human case. Microscopically the pathological changes were likewise similar. In the animals overwhelmed within a few hours, no discernible lesions could be found with the naked eye and only slight parenchymatous degenerative change was noted microscopically in the liver, kidneys and spleen.

*Rabbits.* Twelve animals were employed, six receiving intravenous injections and six others, intra-abdominal injections. The rabbits given intravenous injections, received 1 ml. of a saline suspension of *C. violaceum* which was markedly chromogenic and had been grown on nutrient agar. The suspension was diluted to contain one billion microorganisms per ml. Following these injections all animals died within twenty-four hours. Necropsies showed no gross lesions. *C. violaceum*, however, was readily recovered by culture from the lungs, liver, spleen, and heart's blood. Microscopically, degenerative changes were noted in all organs, but particularly in the liver.

Six other animals were injected intra-abdominally with varying amounts of a *C. violaceum* broth culture. Increasing amounts of 0.5 ml., 0.75 ml., 1 ml., 1.5 ml., and 2 ml. were given respectively. The two rabbits receiving the larger amounts, i.e., 2 ml. and 1.5 ml. died in twelve and twenty-four hours respectively. *C. violaceum* was recovered by culture from the organs and heart's

blood. The two rabbits receiving 1.25 ml. and 1 ml. survived for five days. At necropsy the lungs (fig. 3), liver and spleen showed yellowish-white necrotized areas varying from 1 mm. to 4 mm. in diameter. On microscopic examination these foci showed a central necrosis of the parenchymatous cells with a peripheral zone in which the tissue cells showed degenerative changes. There was only a slight cellular response which consisted mainly of an occasional neutrophile, and a few lymphoid and plasma cells.

The lesions, both grossly and microscopically, bore a striking resemblance to those in the human infection. As in the human case studied by us, no violet color of the lesions was noted in the experimental disease. *C. violaceum* was, however, readily recoverable on culture from the organs and also the heart's blood and presented the rich violet chrome.

The two rabbits receiving 0.5 ml. and 0.75 ml. respectively have survived.

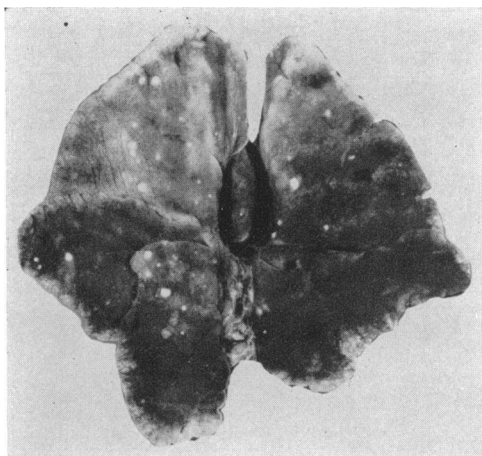


FIG. 3. LUNGS FROM RABBIT SURVIVING FOR FIVE DAYS SUBSEQUENT TO INTRAÄBDOMINAL INJECTION OF *B. VIOLACEUS*

Note subpleural nodules present in both lungs

*Guinea pigs.* A group of ten animals were injected intra-abdominally with suspensions of *C. violaceum*. The organism was grown on nutrient agar slants, washed off with sterile saline and the suspension diluted to contain 1 billion bacteria per ml. Five guinea pigs received 0.25, 0.5, 0.75, 1.0 and 1.5 ml. respectively of this suspension. Three of these animals died within twenty-four hours. Necropsy showed occasional minute white scattered areas in the liver on gross examination. The lungs appeared congested. Microscopically the liver cells were granular and necrotic, presenting fragmented nuclei. *C. violaceum* was cultured from the heart's blood and parenchymatous organs. Two remaining guinea pigs which received 0.25 and 0.5 ml. survived. Another group of five guinea pigs were given intra-abdominal injections of a broth culture of *C. violaceum* in similar amounts and also diluted to contain approximately 1 billion bacteria per ml. All of the animals in this group died within

sixteen hours. On histological examination the parenchymatous organs showed toxic degenerative changes, especially in the liver. The hepatic lesions showed swollen, granular changes in liver cells with occasional foci which presented areas of marked necrosis. *C. violaceum* was recovered from the heart's blood and organs.

#### *Route of infection*

Because of the history of a splinter wound in our human case and the probable invasion through surface injury with adenitis in one other reported human case as well in the infected carabao or water-buffalo, it was considered that skin surface abrasion might have been the portal of entry of infection. Accordingly, experiments were carried out with rabbits and white mice wherein surface injury was produced and liability of infection with *C. violaceum* rendered likely.

In five rabbits, the fur of one hind paw was clipped and an incision approximately 1 cm. in length was made through the skin and into the subcutaneous tissues. Splinters consisting of small portions of tooth-picks measuring approximately 6 mm. in length were dipped in a suspension of living *C. violaceum* and inserted in one end of this small incision. Three additional rabbits, after clipping the fur on the foot, received small crucial incisions down to the subcutaneous structure. The wounds were then swabbed with a broth culture of *C. violaceum*. Oozing of fluid was present in the fresh wound, hence on the following day, the crust was removed and a similar swabbing carried out.

The five rabbits receiving the infected splinters showed swelling and retraction of the infected limb within twenty-four hours and became definitely ill. One died in four days and two others in eight and nine days respectively. The two remaining rabbits survived.

The necropsies of these animals all revealed pathological evidences of severe *C. violaceum* infection, lesions being present in the heart, lung and liver (fig. 4). Congestion and swelling of lymph nodes was present along the path of invasion especially for those animals surviving for the longer periods. The gross and microscopic study was similar to that already described. *C. violaceum* was recovered in culture from the affected organs and the heart's blood of all animals.

Of the three rabbits wherein crucial incisions were made and exposure to living *C. violaceum* suspension had occurred, two showed swelling and oedema of the infected foot and leg. One died in eleven days and another in two weeks. The remaining animal survived. The necropsy findings in these animals were similar in all regards to those of the rabbits receiving splinters immersed in the *C. violaceum* suspensions. Four control rabbits wherein the fur was clipped but no abrasions of the paws were present, were swabbed in this area with a suspension of living *C. violaceum* but remained unaffected.

Twenty white mice were also submitted to *C. violaceum* infection. In ten of these, one of the hind foot-pads was scarified to the subcutaneous structure. The feet of these ten together with the feet of the ten control mice were dipped into or swabbed with a dilute suspension of living *C. violaceum* for a period of a minute on two successive days. Of the ten mice in which scarified wounds



had been produced, eight were perceptibly sick in four to six days. In four of these animals wherein death was impending, cultures were made from the heart's blood and yielded heavy growths of the chromogenic bacillus. Four others died twenty-four to forty-eight hours later. Two mice remained normal except for some temporary impairment of function in the affected leg. The infected animals, as in the instance of the rabbits, showed swelling and retraction of the leg wherein infection had occurred. All of the control mice remained normal.

The necropsies of the infected mice all revealed the same bacteriological and pathological findings as for the infected rabbits although several of these mice showed unusual multiple seeding of very small lesions, particularly in the liver.

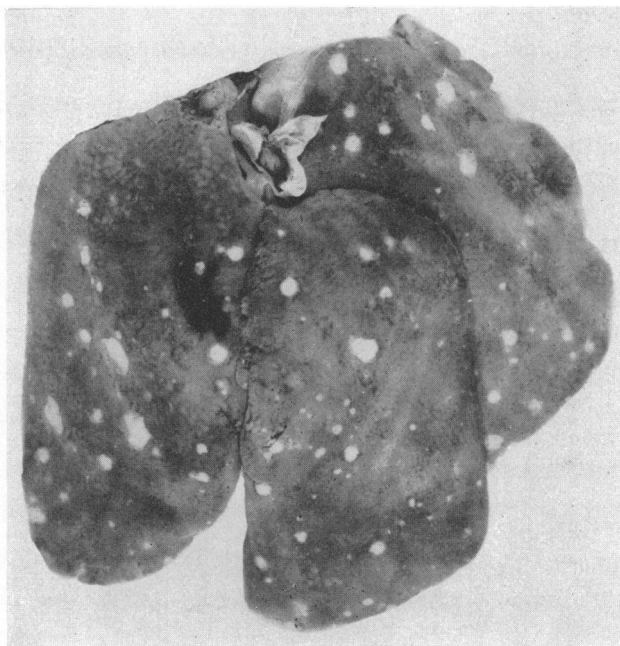

FIG. 4. LIVER OF RABBIT THAT DIED NINE DAYS SUBSEQUENT TO INTRODUCTION OF SPLINTER INFECTED WITH *B. VIOLACEUS*

Necrotic foci of varying sizes scattered beneath Glisson's capsule

It is evident from this series of experiments that *C. violaceum* may readily gain access to the host, causing infection and death, by route of body surface injury.

#### *Protection against infection*

In white mice that had been tested for the toxicity of Seitz filtrates of broth cultures with negative results, it was noted that when these were grouped with normal animals and injected with living culture they remained unaffected, whereas the normal animals died. Accordingly, tests were carried out to ascertain the constancy of such observations. Twenty white mice received two

intra-abdominal injections of 0.5 and 1.5 ml. of Seitz filtrate from broth cultures of *C. violaceum* grown for twenty-four and ninety-six hours apart. Two days subsequent to the last injection, all animals were injected intraabdominally with 0.1 ml. of a suspension of living *C. violaceum*. Twenty normal mice were used as controls for the pathogenicity of the same living suspensions, 10 receiving 0.1 ml. and 10 .05 ml. intra-abdominally. The protection afforded was complete, in that the twenty mice previously injected with broth culture filtrate survived whereas all controls died within three days. Three weeks of observation without apparent illness was considered as a survival period. In order to ascertain if the protein of the media may have occasioned reactions and thereby blocked invasion, five white mice were administered sterile nutrient bouillon intra-abdominally. This was given in the same doses and time intervals as for the broth culture filtrate and similarly 0.1 ml. of the living *C. violaceum* suspension was injected two days later. All of these animals subsequently died in from 24 to 72 hours.

It is apparent that definite protection against a lethal dose of *C. violaceum* is afforded by the broth culture filtrates. We have not as yet determined the matter of its specificity. It is evident that the bouillon also did not occasion an inflammatory protective reaction. Further work is in progress upon this problem relative to the specificity or simple local reaction affording protection.

#### COMMENT

It is noteworthy in the infection by *C. violaceum* presented herein as well as those observed in the carabao or water-buffalo, as reported by Woolley, that the infection was rapid and fulminating in its clinical course, proving fatal in a brief period of time.

In our case and probably those of the carabao, infection of the feet and involvement of drainage lymph nodes represented the mode of invasion. Woolley refers to the adenitis present in the preescapular glands. The reports of Black and Shahan and of Soule show, on the other hand, a very protracted illness with an enduring cervical adenitis and ensuing death after many months duration. In Black and Shahan's report, however, there was a history of primary inguinal adenitis. It appears rather remarkable that only these few authentic infections with this supposedly non-pathogenic microorganism have been recorded and furthermore that all have resulted in fatality. Black and Shahan's report presents the only notation of manifestation of a violet pigment in the lesions produced.

#### *Bacteriological considerations*

It has heretofore been generally represented that *C. violaceum* is rather ubiquitous in its distribution. This fact is recognized in certain geographical areas as regards the field of general bacteriology. We are informed by Dr. A. T. Henrici that those working extensively with natural waters are well acquainted with this group of microorganisms. He estimates that violet

colonies have appeared on plates made from about one out of twenty samples of lake water. In our experience and those here locally with whom we have conferred, its occurrence, even as a contaminant, has not been observed in medical bacteriological routine examination. In regard to food-stuffs, one of the members of the Federal Pure Food Division informs us that in an experience of five years in the examination of foods, often of contaminated character, he has never encountered this group of microorganisms. Even the variants of *Chromobacterium violaceum* that have been described, appear as of rare medical bacteriological occurrence. In this connection we have communicated with investigators in medical bacteriology in various sections of the United States as to their observations upon this group. The responses, all of negative character, are as follows: Parker at Boston has never encountered these microorganisms in routine bacteriological laboratory examinations amounting to approximately 20,000 per annum. Feemster also at Boston reports no personal contact. He states that others in the Public Health Division have seen violet colonies in the examination of water supplies. Bayne-Jones at New Haven, Turner at Baltimore, Hektoen and Cannon in Chicago, Meyer at San Francisco and Bohls at Austin, all report negative experience for *C. violaceum*. As this information is from representative men of experience who are located in widely distributed areas, it appears fully justifiable to state that this microorganism is encountered very rarely in the field of medical bacteriology in this country.

Because of the rich purple and violaceous chromes produced by these microorganisms, they must necessarily attract attention in examination of bacteriological plantings or of cultures made in routine examination. In addition to this fact this group grows very readily upon ordinary culture media. Because of these two features it is evident that any widespread distribution would necessarily be noted by those working in the field of medical bacteriology.

While *C. violaceum*, without differentiation, is generally considered saprophytic and non-pathogenic, it appears evident that in those instances wherein the pathogenic type has been isolated as the infectious agent, it has proven to be fatal to the human subject and consistently and promptly pathogenic in its effect upon the ordinary laboratory animals. We have observed that this property of pathogenicity remains constant although the microorganism has been perpetuated by sub-cultures for many months. Thus, our own strain now in continuous cultivation for over five months and likewise the strain of Black and Shahan received in this laboratory more than two years ago, still demonstrate strong pathogenicity for laboratory animals. Certainly there is no sudden reversion to an innocuous character manifested by these cultures. There seems but little doubt that the general statements regarding absence of pathogenicity have been applied to *C. violaceum* considered as one microorganism without recognition of distinctive types. It has not been universally appreciated that while members of this group show relationship in color, they differ distinctly in cultural activities and inoculation effects upon animals.

Although highly pathogenic for lower animals, the Seitz filtrate obtained from broth cultures of the present strain, grown for a period of a week or more,

fail to reveal any potent action upon animals. It is, however, noteworthy in this regard that white mice receiving two injections of such filtrates are immune to injection of the living bacilli in dosage even twice as large as those killing control animals within twenty-four hours.

It has been shown herein through animal experimentation, that surface injuries form plausible atria and routes of infection and invasion with *C. violaceum*.

### *Pathology*

The gross pathology of both the human being and the carabao wherein fulminating infection and death have occurred reveals a rather consistent picture. This is evidenced by nodular lesions varying from minute foci to those as large as 1 cm. in the longest diameter. They may be rounded or oval in shape but are usually of bizarre or irregular outline. Their color is generally a dirty white. They are of firm consistency although appearing somewhat granular upon cut surface. They are present more especially in the lungs, liver and spleen but may occasionally occur in other structures. When the drainage lymph nodes are involved, massive destruction and liquefaction may occur. Microscopically, the changes represent a granular necrosis of structure suggestive of escharotic action. The parenchymatous units, naturally, show more severe changes than does the framework tissue. There appears but little cellular or other exudative response on the part of the host although occasionally some lymphoid or polymorphonuclear neutrophilic cells may be present peripherally to the essential necrotized lesion. The experimentally produced lesions of the various animals employed reveal a distinct duplication of the natural disease both from the gross and microscopic study.

### *Comparative considerations involved*

The varying clinical manifestations of infection in the human subject together with the nonspecific gross and microscopic pathological picture although consistent in character, suggest the likelihood that other such occurrences may have passed unrecognized. The clinical findings are quite similar to those presented in certain other disease entities such as fatal tularemia and *Pasteurella pseudotuberculosis* or rodentium infection. In this group, aside from somewhat similar clinical manifestations, the gross pathological findings consists of localized areas of greyish-white nodules in the lung, liver and spleen. An accurate differential diagnosis of these closely allied conditions depends obviously upon isolation of the etiological agent. Identification of *C. violaceum* is most simple because of the facility of its cultivation and characteristic rich violet pigment production upon the ordinary types of laboratory media. It is not unlikely that because of the simplicity of culture and the general acceptance of *C. violaceum* as a harmless pigment-producing saprophyte, its isolation in some instances has been regarded as a contaminant rather than as the true etiological factor which it represented. It is to be also noted that the simple finding of gram-negative bacilli in smears of lesions as well as uncertain agglutination reactions may form misleading factors of diagnosis in this allied group of diseases.

## SUMMARY

1. A fatal infection of a human subject with *Chromobacterium violaceum*, var. *manilae*, formed the basis for these observations.

2. Two particular experimental observations have been made. First, the demonstration of definite pathogenicity and the reproduction of the disease in the lower animals and second, the protection afforded against experimental infection with *C. violaceum* by broth culture filtrates. In addition, it has been shown herein that fatal infection with this microorganism may be induced in animals through experimentally produced wounds of the feet, thus indicating a likely route of invasion in the natural infection of man or animal.

3. Emphasis is laid upon the fact that, in at least medical bacteriology routine, *C. violaceum* is not widespread in its occurrence in this country. Serious question is also raised as to the wisdom of regarding such cultures as innocuous or non-pathogenic saprophytes.

4. It is stressed that *C. violaceum* has been in general, erroneously considered only as a single species. In reality, it is one of a group wherein cultural and biological methods permit of definite differentiation. There seems but little doubt that many of the other members of this group are truly non-pathogenic saprophytes.

5. The culture concerned in the present observations conforms to that described by Woolley and identified by him as *C. violaceum*, var. *manilae*.

## REFERENCES

- BERGONZINI, CURZIO 1881 Sopra un nuova Batterio Colorato. Annuario della Societa dei Naturalisti in Moderna, Ser. 2, 14, 149-158.
- BLACK, M. E., AND SHAHAN, J. 1938 *Bacillus violaceus* infection in a human being. J. Am. Med. Assoc., 110, 1270-1271.
- FORD, WILLIAM W. 1927 Textbook of Bacteriology. W. B. Saunders Company, Philadelphia and London, 468-475.
- SCHATTENBERG, H. J., AND HARRIS, W. H. 1941 A definite and unique occurrence of rapidly fatal infection caused by *Bacillus violaceus* Manilae. J. Am. Med. Assoc., 117, 2060-2070.
- SCHATTENBERG, H. J. 1940 Experimental studies upon *B. violaceus* isolated from a fulminating infection. Proc. Soc. Exptl. Biol. Med., 45, 829-831.
- SCHATTENBERG, H. J., AND BROWN, D. V. 1941 Experimentally produced wounds as a route of fatal infection caused by *Bacillus violaceus*. Proc. Soc. Exptl. Biol. Med., 46, 478-482.
- SOULE, M. H. 1939 A study of two strains of *B. violaceus* isolated from human beings. Scientific Proc. Am. Assoc. Pathologists and Bacteriologists, Am. J. Path., 15, 592-595.
- WOOLLEY, P. G. 1905 *Bacillus violaceus* Manilae. (A pathogenic microorganism.) Bull. Johns Hopkins Hosp., 16, 89-93.