

Titanium Preformed Implants in Orbital Floor Reconstruction – Case Presentation, Review of Literature

Bogdan BANICA^a; Patricia ENE^b; Daniela VRANCEANU^b; Razvan ENE^c

^aDepartment of Oral and Maxillofacial Surgery, University Emergency Hospital Bucharest, Bucharest, Romania

^bDepartment of E.N.T, University Emergency Hospital Bucharest, Bucharest, Romania

^cOrthopedic Department, University Emergency Hospital Bucharest, Bucharest, Romania

ABSTRACT

The management of orbital fractures is one of the most interesting and difficult areas in facial trauma. The consequences of an orbital fracture are sometimes dramatic. They include varying types of defects from a loss of vision to diplopia, loss of an eye, epiphora, a disturbing loss of facial sensation, or even an unacceptable appearance of the eye and the hard and soft tissues around it. The controversies surrounding orbital fractures, and orbital floor fractures in particular include the following: the timing of primary surgery (early or late), bone grafting versus alloplastic materials, the management and prevention of diplopia, the prevention of enophthalmos, the management of infraorbital nerve numbness or dysesthesia.

Keywords: Orbital floor fracture, titanium preformed implants, diplopia

INTRODUCTION

The orbital floor is one of the parts of the maxillofacial skeleton that is frequently damaged in facial trauma, because of its ability to fracture selectively similar to a safety valve, allowing the dissipation of energy when orbit is struck. Can be considered as an evolutionary masterpiece, contributing to the orbit's prima-

ry role of protecting the globe in combination with the strength of its lateral walls (1).

Orbital floor fractures occur in both adult and pediatric populations. However the characteristics of the fracture, physical and radiographic findings, and course of recovery differ. **Linear nondisplaced orbital floor fractures** with inferior rectus muscle entrapment occur in pediatric population, with minimal trauma and few external signs of injury. All affected

Address for correspondence:

Bogdan Banica, DDS, PhD Student, University Emergency Hospital Bucharest, 169 Splaiul Independentei Street, Bucharest, Romania.
E-mail: bogdan.ddr@gmail.com

Article received on the 1st of February. Article accepted on the 7th of March.

eyes demonstrate significant limitation to elevation associated with diplopia, and despite prompt surgical repair, limited elevation and depression occur in the early postoperative period, possibly due to a compartment syndrome with raised pressure in the muscle sheath, hemorrhage and ischemia. Recovery of normal ocular motility may take weeks or month. CT evidence may be minimal in these cases (2-4).

In adult population – **orbital blow-out** fractures are characteristic and result in orbital volume expansion, with the orbital contents sagging into the maxillary sinus. Initially, enophthalmos (or sunken eye) and diplopia may not be apparent but, with clearance of hemorrhage and resolution of edema, the condition may be manifested. The decision to undertake surgical repair or reconstruction of these defects is based on functional limitations (impaired ocular motility, infraorbital anesthesia) or cosmetic deformity. Defects of 25% or less of the surface area, without entrapment, generally heal uneventfully without intervention. Repair of intermediate defects of 25% to 50% is based on degree of displacement, amount of volume expansion and any co-existing enophthalmos, even with edema. Larger or comminuted defects (greater than 50%) with significant disruption are best treated with early repair (within 7 days) because some degree of enophthalmos or diplopia is the norm when left unrepaired (5).

The main goal of orbital floor fracture repair is to restore the orbit to its preoperative status, which involves repositioning the herniated orbital tissues in the orbit and repairing the traumatic defect while preserving the orbital volume. The three-dimensional shape of the orbital walls in combination with a weak bony framework and close proximity to delicate anatomic structures define the challenges of the reconstructive procedure (6,7).

Principles of surgical treatment

Patients with isolated orbital floor fractures can be followed clinically initially. If surgery is needed, it is usually planned for 7-14 days after the trauma. Waiting allows time for spontaneous improvement, precise surgical planning, and resolution of swelling associated with the initial trauma because a too edematous orbit cannot allow an effective repair. Delaying surgery for over 14 days results in increased scarring of the orbit.

Specific indications for surgical repair:

- restrictive strabismus
- enophthalmos >2 mm
- CT evidence of muscle entrapment
- Oculocardiac reflex
- Hypo-ophthalmos
- Large floor fracture >50%, based on CT estimate of fracture size

Principles of surgical repair:

- Exposure
- Isolate the orbital soft tissue
- Restore orbital volume
- Provide a stable platform for soft tissue to rest

Usually, the fracture of the orbital floor is comminuted and bone fragments are missing, therefore one is reconstructing missing bone rather than reducing bone fragments.

There is hardly any anatomic region in the human body that is so controversial in terms of appropriate material used for fracture repair (8,9). There are different preferences of implant material depending on variations in schools of teaching, socio-economic factors but there is a paucity of evidence to support the ideal choice of an orbital implant.

In the past, the use of **autogenic bone** has been the gold standard in orbital wall reconstruction. Usually calvarial bone was used due to maximal biocompatibility and low cost. However, the harvesting of autogenous bone is associated with donor site morbidity, variable degree of resorption, prolonged total operating time, postoperative pain, scarring. Also autologous bone grafts are usually rigid and cannot be bend to match the concave-convex shape of



FIGURE 1. Titanium preformed floor plate.

the orbital floor, and provide less drainage from the orbit than with titanium (10-12).

Porous polyethylene sheets (PPE) – presents the advantage of easy contouring and smooth edges, but are not radiopaque and can present a lack of rigidity in heavily displaced fractures with massive tissue herniation into the maxillary sinus. However, infection is the most disastrous complication with the use of the PPE in the orbital wall reconstruction (13).

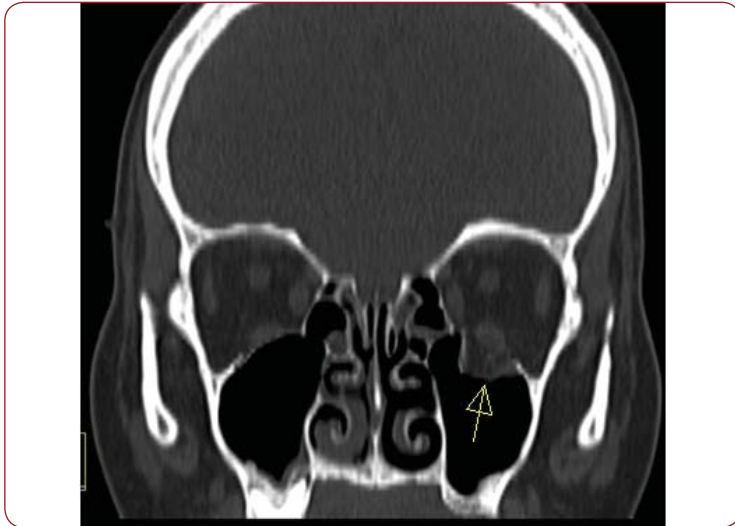


FIGURE 2. CT.

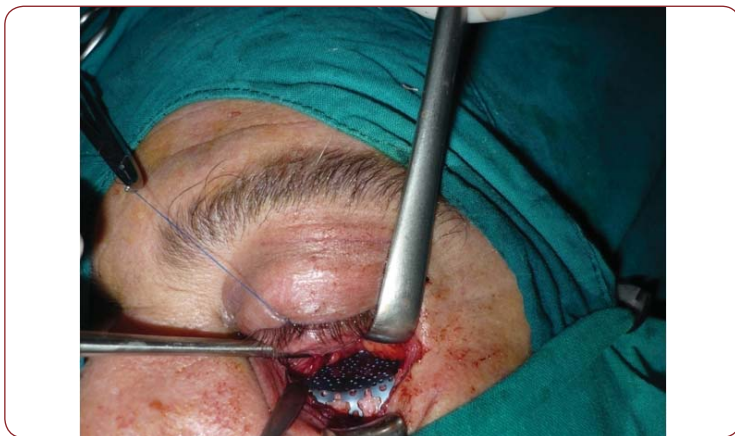

FIGURE 3. Orbital floor reconstruction.

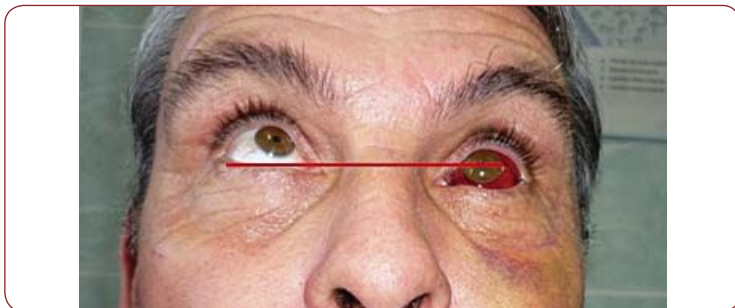

FIGURE 4. Preoperative aspect.

Composite of porous polyethylene and titanium (Medpor) are increasingly being used to prevent postoperative enophthalmos, but that are recent reports that show the risk of late complications such as infection, diplopia and implant migration associated with them.

An alternative **resorbable material** consisting of stiff sheets of pure polyglactin – **polydioxanone (PDS) implants (Ethysorb)** to bridge small-to-moderate defects has been described. After resorption of the implant, the resulting scar might not be stiff enough in all cases to provide adequate support for the globe and to prevent sagging of the periorbita into the maxillary sinus. Another drawback of pure PDS was that degradation may lead to an inflammatory reaction involving the surrounding periorbita, with possible scar formation and consecutive functional motility disturbances of the globe, leading to recurrence of diplopia (14).

Prefomed titanium meshes. Orbits reconstructed with titanium mesh show better results than those reconstructed with bone grafts (15-18). It is malleable and therefore easily adapted to the shape of the orbital defect and it is the most biocompatible of all available material. Because of the mesh structure (Figure 1), connective tissue can grow around and through the implant and prevent migration. It is also preferred in significant fractures with large defects. However this has the potential disadvantage of making the implant very difficult to remove if required.

Case report

A 54 year old man sustained a left orbital fracture after a human assault. Immediately after the injury, the patient noticed diplopia and discomfort in all fields of gaze. At the initial examination, there was important periorbital edema, ecchymosis, marked limitation of infra-duction and supra-duction of the right eye and associated pain and diplopia in all fields of gaze, complete anesthesia in the left V2 nerve territory. In addition, there was 2.5 mm of right enophthalmos – measured with Hertel exophthalmometer.

A preoperative computed tomography (Figure 2) scan showed an extensive fracture of the right orbital floor with major herniation of the orbital soft tissue in the maxillary sinus, of pure type. The clinical and radiographic findings supported the diagnosis of entrapment of the inferior rectus muscle.

At surgery, the orbital wall was approached sub tarsally, with a dissection carried in a preseptal plane. After subperiosteal dissection to expose the orbital floor, the herniated tissue was repositioned within the orbit and a 25 mm x 16 mm x 0.85 mm titanium floor plate was positioned over the bony defect (Figure 3). An intraoperative forced duction test was performed to ensure the release of the incarcerated inferior rectus muscle. The periosteum was meticulously sutured at the orbital rim.

Postoperatively, the patient received intravenous antibiotics (Cefuroxime 1g IV every 12h for 5 days), systemic corticosteroids (Dexamethasone 4mg/ml per day for 5 days). The patient still had diplopia during the first week of follow-up, perhaps owing to the initial muscle and soft tissue edema, thereafter, the ductions of the right eye normalized, and the diplopia resolved by the end of the first month of follow up (Figure 4, Figure 5).

The follow-up was extended 6 months after the titanium mesh was implanted, and the clinical assessment demonstrated good biocompatibility, good overall support of the orbital contents without the relapse of enophthalmus and no signs of local inflammatory reaction.

Surgical repair was performed using a sub tarsal approach, and preformed titanium orbital floor implants (Stryker-Leibinger) secured with titanium screws at the infraorbital rim.

The lower eyelid offers numerous incision opportunities for exposure, based on skin creases at this level. They include – subciliary, subtarsal, and infraorbital incisions. Except for the infraorbital incision, the other two offer an exceptional healing, with almost no chance of hypertrophic scar.

After the transection of the orbicularis muscle, the dissection is performed in a preseptal orbital plane in order to avoid the herniation of the orbital fat in the operating field. At the infraorbital rim level, the periosteum is incised and the raised so that wide access to orbital floor is obtained.

The preformed titanium implants offer the advantage of minimal contouring and stability. The implant is trimmed off to protect the soft tissues, and contoured to achieve the required shape in order to accommodate key anatomical structures (nasolacrimal duct, infraorbital nerve and optic nerve). It is advisable not to extend the implant further posterior than 1 cm anterior to the optic canal entrance. Under ad-

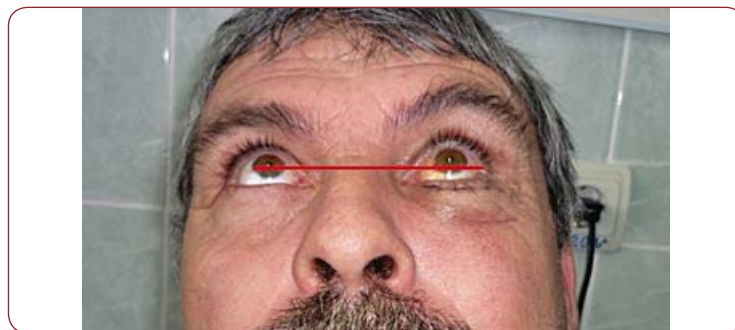

FIGURE 5. Postoperative 7 days.

equate retraction of the intraorbital soft tissue, the mesh has to be positioned so that proper and stable recontouring of the orbital wall results. Care has to be taken that neither orbital fat nor muscles are entrapped. During the insertion process, the mesh may require rotation in order to be properly positioned. Once in place, the mesh is fixed over the orbital rim to prevent migration. After the implant insertion it is imperative to perform a forced duction test in order to assure that the implant has not created a decrease in ocular motility (19,20). □

DISCUSSION

Orbital floor fractures are one of the most common injuries observed in the middle facial region. One of the most important points of reconstruction of orbital wall fractures is restoration of normal orbital volume.

Numerous articles have been published on the subject of orbital tissue reconstruction. The ideal material for orbital reconstruction remains controversial. Numerous materials are available at present including lyophilized dura, polyethylene or polydioxanone sheets, titanium mesh and autogenous bone graft. The more elastic materials are not capable of withstanding the dynamic stresses of large bony orbital defects; resorbable implants are prone to produce foreign body reactions, implant exposure may occur and only fibrous connective tissue remaining after resorption. The disadvantages of autologous bone graft include minimal contourability and donor site defects.

Titanium mesh has a long track record in the reconstruction of large orbital defects and correction of globe malposition. Advantages of titanium mesh plates are availability, easy intraoperative contouring and rigid fixation (21). Disadvantages include difficulties with ease of insertion, as rough or irregular edges on the

mesh tend to catch on adjacent soft tissues. Intraoperative bending and repetitive removal of titanium mesh for orbital reconstruction may cause damage to the orbital soft tissue. Using preformed implants for orbital reconstruction in larger defects, avoids the time consuming and traumatic intraoperative bending and adjustment of the implants.

Four patients with pure orbital floor fractures and diplopia were treated by osteosynthesis of the fractures using preformed titanium implant between January 2011 and January 2012. All four patients had double vision particularly on extreme downward and upward gaze. Two patients were operated on immediately after the injury and two after approximately 7 days because of the extensive periorbital swelling on admission. All presented extensive fractures with multiple fragments projected into the maxillary sinus cavity. The orbital floor was exposed via a sub tarsal approach, and the infraorbital nerve was located and protected before plating (Table 1).

Postoperative clinical, RX and CT scan verified the anatomical reduction of the orbital floor. None of the patients had diplopia or enophthalmos postoperatively and there was no displacement or resorption of the orbital floor or loosening of the screws 6 months after the

operation, and no modifications in the visual acuity.

Nowadays computer assisted methods by creating an orbital model based on the data of the virtual orbital reconstruction, permit precise performing of individual titanium mesh implants for a 3D reconstruction of the orbital cavity (with or without the use of a stereolithographical resin based model) (22-24). The ideal form of the injured orbital cavity is recalculated using the mirror image of the unaffected side. This method facilitates the quick subperiosteal placement of the implants, without the repetitive trial fitting of the titanium mesh, therefore, the procedure is less traumatic to the periorbital tissues. □

CONCLUSION

The placement of preformed orbital implants for the reconstruction of extensive orbital defects proved to be less time consuming and more precise compared to “free hand” reconstruction efforts of orbital injuries using titanium mesh, calvarial or iliac grafts, and also the time and costs are significantly lower compared with the use of stereolithographic models. □

*Conflict of interest: none declared.
Financial support: none declared.*

	Preoperative	Postoperative 7 days	Postoperative 1 month	Postoperative 6 months
Diplopia	4 patients	Unchanged 1 Improved 3 Worse 0	Unchanged upper gaze 2 Normal 2	Persistent extreme upper gaze 1 Normalized 3
Enophthalmus >2 mm	2 patients	Improved 4	Absent 4	-
V2 anesthesia	4 patients	Unchanged 2 Worse 2	Improved 4	Persistent at the upper lip 2 Normalized 2
Hypoglobus	1 patient	Improved	Absent 4	-

TABLE 1.

REFERENCES

- Burm JS, Chung CH, Oh SJ** – Pure Orbital Blowout Fracture, New Concepts and Importance of Medial Orbital Blowout Fracture. *Plast Reconstr Surg* 1999;103:1839-1849
- Burm JS** – Internal Fixation in Trapdoor-Type Orbital Blowout Fracture. *Plast Reconstr Surg* 2005;116:962-970
- Burnstine MA** – Clinical Recommendations for Repair of Orbital Facial Fractures. *Curr Opin Ophthalmol* 2003;14:236-240
- Chang EL, Bernardino CR** – Update on Orbital Trauma. *Curr Opin Ophthalmol* 2004;15:411-415
- Hammer B, Prein J** – Correction of Post-Traumatic Orbital Deformities: Operative Techniques and Review of 26 Patients. *J Craniomaxillofac Surg* 1995;23(2):81-90
- Nagasao T, Hikosaka M, Morotomi T, et al.** – Analysis of the Orbital Floor Morphology. *J Craniomaxillofac Surg* 2007;35:112-119
- Parsons GS, Mathog RH** – Orbital Wall and Volume Relationships. *Arch*

- Otolaryngol Head Neck Surg* 1988;114:743-747
8. **Potter JK, Ellis E** – Biomaterials for Reconstruction of the Internal Orbit. *J Oral Maxillofac Surg* 2004;62:1280-1297
 9. **Hoffmann J, Cornelius CP, Groten M, et al.** – Orbital Reconstruction with Individually Copy-Milled Ceramic Implants. *Plast Reconstr Surg* 1998;101:604-612
 10. **Goldberg RA, Garbutt M, Shorr N** – Oculoplastic Uses of Cranial Bone Grafts. *Ophthalmic Surg* 1993;24:190-196
 11. **Habal MB** – Bone Grafting The Orbital Floor for Posttraumatic Defects. *J Craniofac Surg* 1992;3:175-180
 12. **Kelly CP, Cohen AJ, Yavuzer R, et al.** – Cranial Bone Grafting for Orbital Reconstruction: Is It Still the Best? *J Craniofac Surg* 2005;16:181-185
 13. **Lee S, Maronian N, Most SP, et al.** – Porous High-Density Polyethylene for Orbital Reconstruction. *Arch Otolaryngol Head Neck Surg* 2005;131:446-450
 14. **Buchel P, Rahal A, Seto I, et al.** – Reconstruction of Orbital Floor Fracture with Polyglactin 910/ Polydioxanon Patch (Ethisorb): Retrospective Study. *J Oral Maxillofac Surg* 2005;63:646-650
 15. **Ellis III E, Tan Y** – Assessment of Internal Orbital Reconstructions for Pure Blowout Fractures: Cranial Bone Grafts versus Titanium Mesh. *J Oral Maxillofac Surg* 2003;61:442-453
 16. **Kuttenberger JJ, Hardt N** – Long-term Results Following Reconstruction of Craniofacial Defects with Titanium Micro-Mesh Systems. *J Craniomaxillofac Surg* 2001;29:75-81
 17. **Gear AJL, Lokeh A, Aldridge JH, et al.** – Safety of Titanium Mesh for Orbital Reconstruction. *Ann Plast Surg* 2002;48:901-910
 18. **Kuttenberger JJ, Hardt N** – Long-term Results Following Reconstruction of Craniofacial Defects with Titanium Micro-Mesh Systems. *J Craniomaxillofac Surg* 2001;29:75-81
 19. **Metzger MC, Schön R, Weyer N, et al.** – Anatomical 3-Dimensional Pre-bent Titanium Implant for Orbital Floor Fractures. *Ophthalmology* 2006;113:1863-1868
 20. **Schon R, Metzger MC, Zizelmann C, et al.** – Individually Preformed Titanium Mesh Implants for True-to-Original Repair of Orbital Fractures. *Int J Oral Maxillofac Surg* 2006;35:990-995
 21. **Scolozzi P, Momjian A, Heuberger J, et al.** – Accuracy and Predictability in Use of AO Three-Dimensionally Preformed Titanium Mesh Plates for Posttraumatic Orbital Reconstruction: a Pilot Study. *J Craniofac Surg* 2009; 20:110-13
 22. **Eufinger H, Wittkamp AR, Wehmoller M, et al.** – Single-Step Fronto-Orbital Resection and Reconstruction with Individual Resection Template and Corresponding Titanium Implant: a New Method of Computer-Aided Surgery. *J Craniomaxillofac Surg* 1998;26:373-378
 23. **Lauer G, Pradel W, Schneider M, et al.** – Efficacy of Computer Assisted Surgery in Secondary Orbital Surgery. *J Craniomaxillofac Surg* 2006;34:299-305
 24. **Luebbers HT, Messmer P, Obwegeser JA, et al.** – Comparison of Different Registration Methods for Surgical Navigation in Cranio-Maxillofacial Surgery. *J Craniomaxillofac Surg* 2008;36:109-116.