

Post-traumatic impaction of maxillary incisors: diagnosis and treatment

Valeria Paoloni, DDS¹
 Chiara Pavoni, DDS¹
 Manuela Mucedero, DDS¹
 Patrizio Bollero, DDS, PhD²
 Giuseppina Laganà, DDS¹
 Paola Cozza, MD, DDS, MS¹

¹ Department of Orthodontics, University of Rome "Tor Vergata", Italy

² Department of Oral Pathology, University of Rome "Tor Vergata", Italy

Corresponding author:

Giuseppina Laganà
 Department of Orthodontics,
 University of Rome "Tor Vergata"
 Via G. Baglivi, 5/E
 00161 Rome, Italy
 Phone: +39 06 44232321
 E-mail: giuseppinalagana@libero.it

Summary

Aim. To provide clinicians with useful information for immediate diagnosis and management of impacted maxillary incisors due to trauma.

Methods. We present a case of post-traumatic impaction of a central right maxillary incisor in a young patient. The treatment plan consisted in the interceptive management (surgical and orthodontic), the valuation of the necessary space to move the impacted tooth in the normal position and the biomechanical approach for anchorage, avoiding prosthetic/implants replacement.

Results. The therapy of an impacted maxillary incisor due to trauma requires a multidisciplinary approach: orthodontic, surgical, endodontic and periodontal considerations are essential for successful treatment.

Conclusions. Surgical exposure and orthodontic traction is the treatment most often used in case of posttraumatic impacted incisor: this technique in fact can lead to suitable results at the periodontal, occlusal and esthetics levels at an early stage and more definitively than with other treatment options.

Key words: eruption disturbances, impacted incisor, oral trauma, orthodontic traction, early diagnosis.

Introduction

Trauma to oral and facial structures is a significant problem that may have serious medical, esthetic and psychologic consequences on both children and their parents. Studies have shown that approximately 30% of all children under the age of 7 years experience injuries to ≥ 1 of their primary incisors and that most serious injuries to primary teeth occur between the ages of 1 and 3 years (1).

This high incidence is related to the passage to the upright posture, the early stages of walking, a lack of motor coordination and the unconsciousness of the child.

The majority of the trauma occurs as a result of fall accidents at home or during sporting activities (1, 2).

According to gender, boys were injured more frequently in all age than girls (2) and owing to their exposed position in the dental arch, the upper central incisors are the teeth most commonly affected by traumatic injury in both primary and permanent dentition (1).

In primary dentition intrusions are the most common type of trauma. These are luxation injuries which usually results from an axially directed impact, displacing the incisor deeper into the alveolar socket. The primary incisors is driven deeply into the alveolar bone invading the follicle of permanent germ which lies palatally in close proximity to its root. In fact there is a close anatomic relationship between the apices of the primary incisors and the germs of the succeeding teeth: the hard tissue barrier between them has a thickness of less than 3 mm and it might simply consist of connective fibrous tissue (3).

This close relationship explains why injuries to primary teeth are easily transmitted to the permanent dentition (4).

The displacement results in compression of and damage to the periodontal ligament, contusion to the socket walls and injury to the pulp of the intruded incisor. The reported prevalence of intrusion injuries affecting primary incisors varies among different studies and ranges from 4.4% to 22% (3). This high incidence is because of the pliability of the facial skeleton and of the periodontal ligament, the large volume of teeth in relation to the bone in primary and mixed dentition and finally the shorter roots of primary teeth (5).

Therefore traumas to primary dentition may interfere with further odontogenesis of permanent teeth and according to site and extension of the injury, different malformations may occur ranging from a slight disturbance in the mineralization of enamel to a sequestration of the entire tooth germ (4). They may lead to abnormality in the path of eruption of permanent series which may result in impaction or ectopic eruption (6). The percent-

age of developmental disturbances of the permanent incisors that could be attributed to injuries of their predecessors ranges from 12% to 74% (3). Early diagnosis is very important to monitor and prevent complications (6).

Sequelae

The effects of trauma on the permanent tooth germ become clinically manifest only after the normal exfoliation period is over. It is possible, however, that in an earlier stage a malformation may be discovered radiographically (7).

The age of the child at the time of injury (germs of the permanent teeth are particularly sensitive in the early stages of their development, which occurs between the ages of 4 months and 4 years), the developmental phase of the permanent tooth germ, the direction and severity of the trauma, the type of injury sustained and the presence of alveolar bone fracture are important variables influencing the effect on the developing permanent germ (1, 3, 4, 7).

The consequences for permanent dentition after a trauma to primary dentition may affect the coronal or root region or the whole of the permanent tooth germ (5).

Many sequelae can be found in the coronal region: 1) white or yellow-brown discoloration of enamel; 2) white or yellow-brown discoloration of enamel and circular enamel hypoplasia, that represented the borderline between hard tissue formed before and after injury; 3) crown dilaceration, that is described as an acute deviation in the long axis of the crown originating from a non-axial displacement of already formed hard tissue in relation to the developing noncalcified tissue (crown dilaceration can result from an intrusion of the primary incisor when a child is around that age of 2 years, when half the crown would be formed) (3-5).

Sequelae affecting the root region include: 1) root duplication; 2) root dilaceration, these lesions appeared as a marked curvature confined to the root portion and may result from intrusion of a primary incisor after completion of permanent crown formation between the ages of 2 and 5 years; 3) partial or complete arrest of root formation, rare sequelae resulting from injury to primary incisors between the ages of 4 and 7 years (3-5).

When the entire permanent tooth germ is affected, alterations to the process of eruption of the permanent tooth may be noted: 1) delayed eruption due to early loss of a primary incisor and formation of thick, fibrous gingival tissue; 2) accelerated eruption, when the primary incisor is lost after the child is aged 5 years especially in the presence of alveolar bone resorption following an infection of the injured tooth; 3) ectopic eruption or (4) impaction that can be explained by the physical displacement of the permanent germ with or without dilaceration at the time of the injury, the lack of eruption guidance from prematurely lost primary incisor, ankylosis or alterations of root resorption; 5) malformation of the permanent germ giving the appearance of an odontoma; 6) sequestration of the permanent tooth germ (3-5).

Diagnosis

The impaction of maxillary permanent incisor is often clinically and radiologically diagnosed in early ages because the non-eruption of the anterior tooth causes concern to parents during early mixed dentition phase (8).

Clinical signs of an impacted tooth include asymmetric eruption of more than 6 months in relation to its homologue, change of the sequence and chronology of normal eruption, retention of the primary tooth, midline deviation, space closure and elevation of the soft tissue of the palatal or labial mucosa (8, 9).

Diagnosis of impacted tooth is verified and its location determined through radiographic evaluation. Panoramic radiograph is considered the standard radiographic first-step examination for treatment planning of impacted teeth because (10, 11) it is unique in that it will show the entire dentition as a whole (12) and it may reveal the existence of an impacted tooth. Unfortunately, lesions of permanent teeth resulting from previous trauma to the deciduous dentition are not always clearly observable on panoramic radiograph because the deciduous teeth are projected onto the permanent teeth and the direction of projection is unfavorable in regard to the root curvature (7).

Due to the highly detailed three-dimension information obtained, computerized tomography is the method of choice for accurately defining the position of an unerupted tooth and identifying any root resorption of adjacent teeth not detectable by other methods (12). The highly detailed information and the excellent tissue contrast without blurring and overlapping of adjacent structures outweighs the high radiation dose, limited availability, and high cost (13, 14).

Three-dimensional imagery enables analysis of the precise location and orientation of impacted teeth, their situation relative to obstacles to eruption, their external and internal anatomy, the labial and palatal bone thickness; any resorption of the adjacent teeth or pathological bone loss; the presence or absence of a continuous radiolucent line between the root and the bone (possible ankylosis) (15).

Recently cone beam CT (CBCT) has been introduced as a technique dedicated to the imaging of dental and maxillofacial structures. It has one-sixth of the radiation of computed tomography, is more time efficient, more cost effective, is still able to provide three dimensional images, excellent bone differentiation and an unlimited number of views (11, 12). Its disadvantages include spatial resolution of subtle structures that is slightly inferior to that of CT and limited representation of soft tissues (due to the lower radiation dose) (11).

Treatment

The therapy of an impacted maxillary incisor due to trauma requires a multidisciplinary approach: orthodontic, surgical, endodontic and periodontal considerations are essential for successful treatment (16). Careful

planning is required especially because these are often dilacerated incisors (17).

If there is a retained, necrotic, ankylosed primary incisor it must be surgically removed because it represents an obstacle to spontaneous eruption of the permanent one. Sometimes after primary tooth's removal, the permanent incisor erupts without any further treatment. When the displacement is severe and prevents the spontaneous eruption, an orthodontic treatment is necessary.

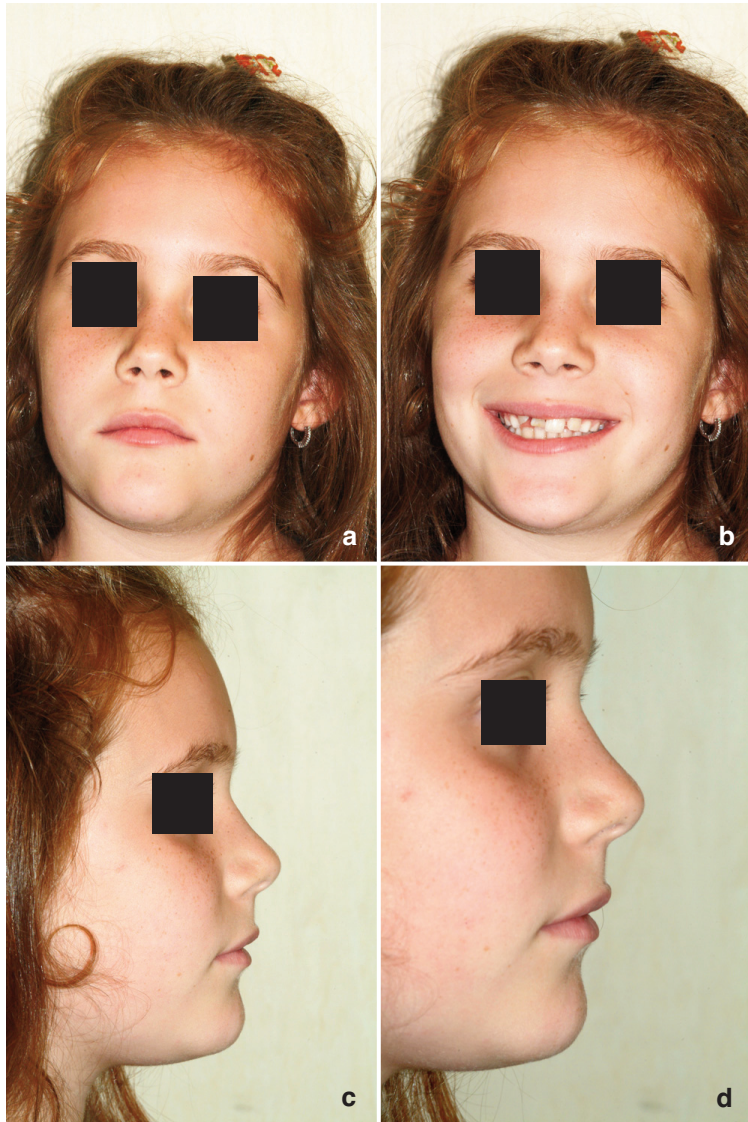
Depending on the localization of the tooth and the degree of dilacerations different treatment options have been suggested in literature (8): surgical excision of the impacted incisor and subsequent restoration with a bridge or implant after orthodontic space opening when growth had stabilized; surgical excision of the impacted incisor, orthodontic space closure and prosthodontics restoration of the left lateral incisor as the central incisor at a later stage; orthodontic space opening, uncovering the impacted tooth using the apical reposi-

tioned flap and orthodontic traction into proper alignment (18).

The most commonly solution is surgical extraction of the impacted incisor (19) followed by an orthodontic treatment either to close the space or to keep it open until the patient reaches an age when definitive prosthodontic treatments may be used.

Both methods have associated problems: orthodontic space closure substituting the lateral incisor for the central one with subsequent resin restoration is seldom indicated nor aesthetically satisfactory, while removable prosthetic replacement during childhood and adolescence may be unsatisfactory for psychological reasons (18). Moreover early loss of a maxillary incisor may result in loss of alveolar height in the anterior region of the maxilla (20). In some cases extraction of the tooth is unavoidable because of the severity of the inversion of the tooth (8).

The surgical-orthodontic approach is the solution most widely adopted to save an impacted incisor (20) and it



Figures 1 a-d. Pretreatment extraoral photographs.

would yield satisfactory results with carefully planned procedures (18).

This technique is commonly directed to surgical exposure of the crown and to apply an orthodontic traction. The strategy adopted for the surgical exposure is minimal bone removal and closed eruption after placing an attachment on the unerupted incisor. This is considered a good surgical choice considering the long-term esthetic-periodontal status (9).

The degree and level of dilacerations, tooth's vertical position, tooth's maturity, flap design and orthodontic traction are factors determining the success rate of orthodontic-surgical management of impacted incisors (18).

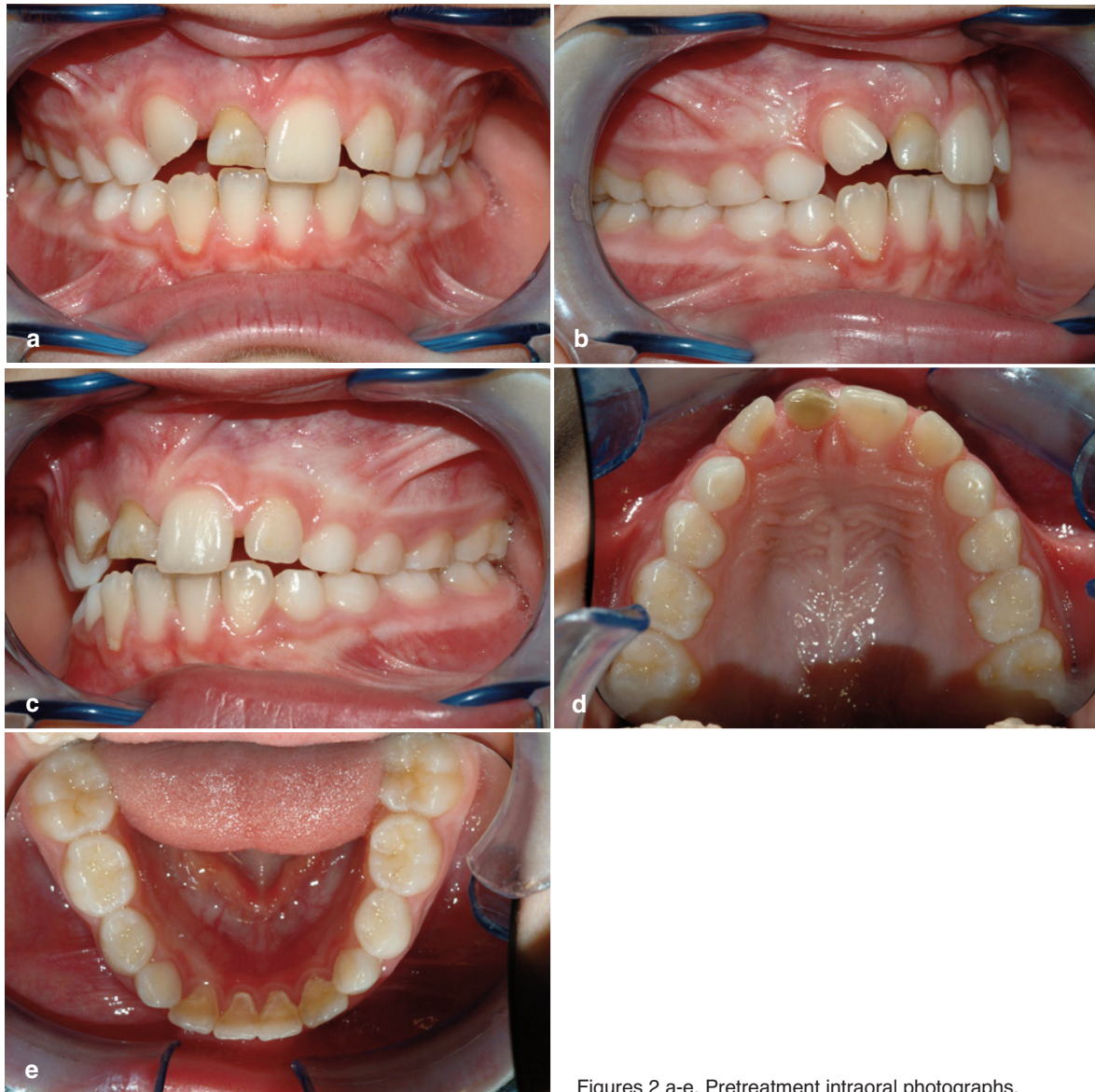The chances of failure could be due to ankylosis, external root resorption, root exposure after orthodontic traction, loss of attachment (17, 21).

Autotransplantation with premolars or supernumerary teeth and surgical repositioning of impacted incisor has been reported in dental literature (20).

Aim of this report was to show the interceptive management (surgical and orthodontic) of a case with an impacted central maxillary incisor caused by trauma in a young patient, avoiding prosthetic/implants replacement.

Case report

A 9-year-old Caucasian girl was referred by his general dentist to the Department of Orthodontics of the University of Rome "Tor Vergata" for an orthodontic evaluation. The chief complaint was concern about an eruption disturbance, which had resulted in an unaesthetic appearance. The child was in excellent physical health and had no history of disease, but there was a history of anterior dental trauma at age 4 to its primary incisors. This trauma induced the necrosis and ankylosis of the maxillary primary right central incisor.



Figures 2 a-e. Pretreatment intraoral photographs.

Diagnosis

The patient had balanced facial pattern with a good profile, and an asymmetric ugly smile. Intraoral clinical examination showed a mixed dentition, an altered sequence of eruption, the absence of the maxillary permanent right central incisor and the ankylosis and necrosis of the maxillary primary right central incisor (Figs. 1a-1d).

Occlusal analysis revealed a molar Class I relationship. There was not significant dental crowding in both arches. The maxillary right central incisor was absent while the maxillary right lateral incisor was erupting. Overbite was reduced (Figs. 2a-2e).

Radiological examinations were performed to complete clinical evaluation.

Panoramic radiograph showed the complete set of permanent teeth in different stage of formation and the impaction of the upper permanent right central incisor which showed a severe intraosseous displacement (Fig. 3).

The vertical position of the delayed permanent incisor in relation to the contralaterally erupted central incisor was in sector v3 (22) (Pict. 1), while its angulation to the mid-sagittal plane was 90° (23) (Pict. 2).

CT-Dentascan evaluation defined exactly the place of the impacted incisor: the tooth was positioned horizontally and its crown was close to the anterior nasal spine and across the midline, while the root was displaced palatally (6) (Figs. 4a, 4b).

Cephalometric analysis revealed a skeletal Class I malocclusion (ANB T1: 3°) and a normofacial pattern (FMA T1: 26°). Lower incisor showed good inclination on mandibular plane (IMPA T1: 89°) (Figs. 5a, 5b).

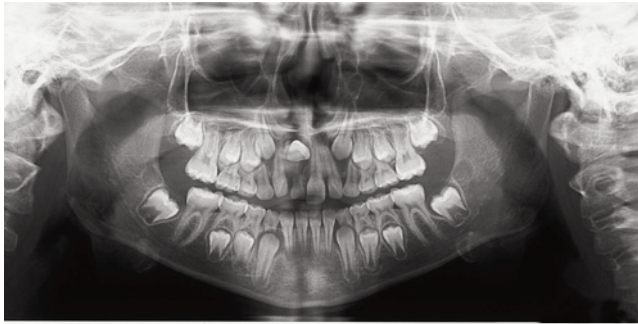
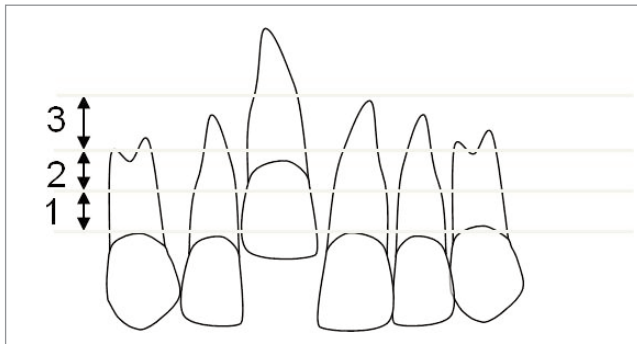
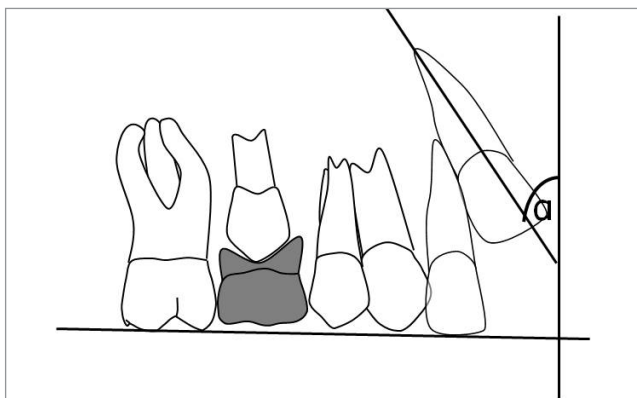


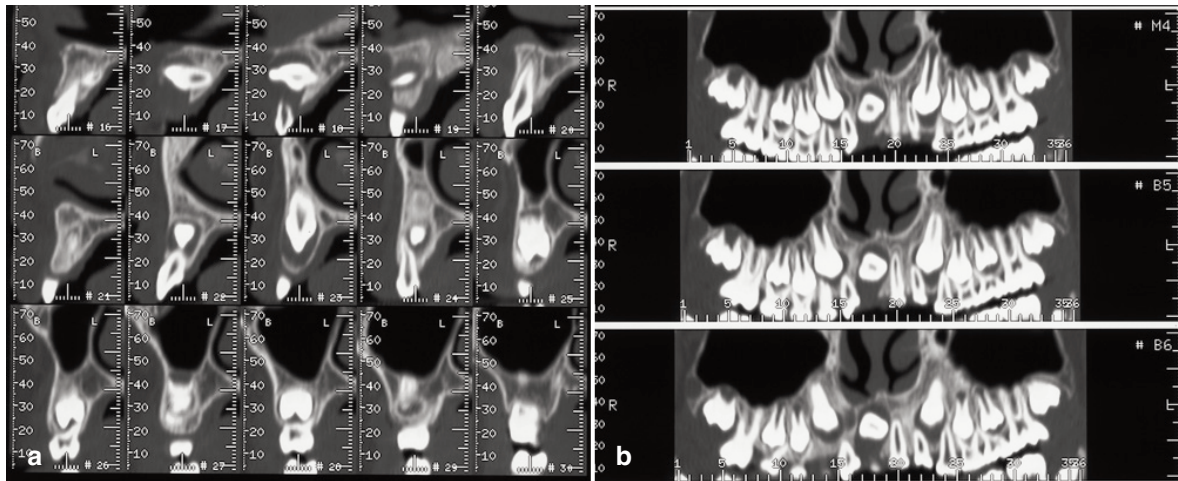
Figure 3. Pretreatment panoramic radiograph.



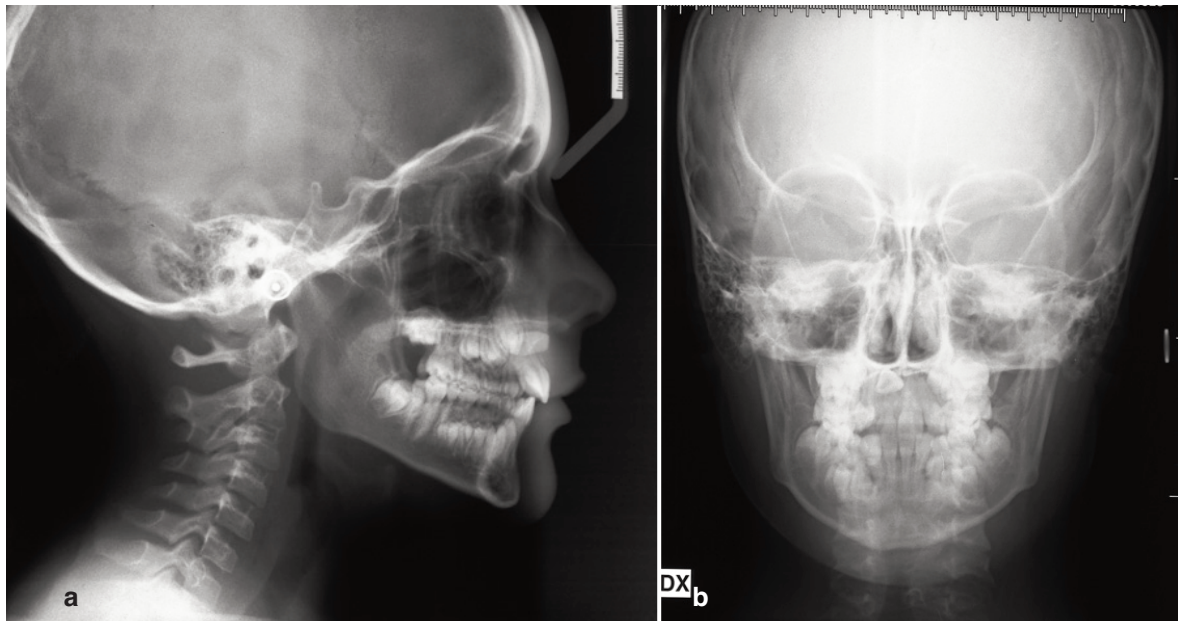
Picture 1. Smailiene et al. measurement (22).



Picture 2. Bryan et al. measurement (23).



Figures 4 a-b. Pretreatment CT-Dentascan.



Figures 5 a-b. Pretreatment cephalometric radiographs.

Treatment objectives

The purpose of this treatment was to guide the impacted incisor into proper alignment with the adjacent teeth, without root damage, and to re-create a complete anterior dentition and a stable functional occlusion. The treatment aimed also to extrude the incisor with all its supporting tissues (alveolar bone and attached gingiva), to investigate the effects that surgical exposure, orthodontic movements and final tooth position would have had on them and to evaluate the long-term gingival and periodontal conditions (19).

Treatment progress

The multidisciplinary approach involved a combined surgical/orthodontic treatment. After evaluating the advantages and disadvantages of the therapeutic options, the following treatment steps were established: 1) surgical removal of the ankylosed and necrotic maxillary primary right central incisor which represented an obstacle to permanent incisor's eruption, 2) monitoring for spontaneous eruption, 3) orthodontic traction, 4) fixed appliance to obtain the proper alignment. First of all the primary incisor was surgically removed. After 6 months the maxillary right incisor erupted in an

ectopic position parallel to the occlusal plane, near to the labial fornix (Fig. 6).

A modified Quad Helix with a TMA arm and a terminal loop was applied to the upper arch as anchorage. A button was bonded on vestibular surface of tooth and an elastomeric module was connected from the button to the loop of the TMA arm. The elastic module generated a constant light force of no more than 30-50 g (24-26). The force was activated monthly creating a physiological direction of tooth eruption (27-29) (Figs. 7a-7b).

Once the impacted tooth moved close to its place in dental arch, brackets were placed on the upper arch and it

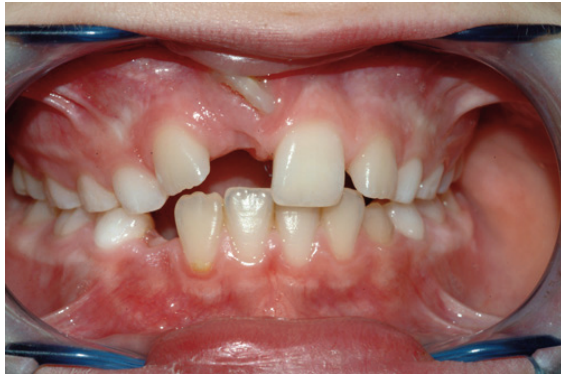
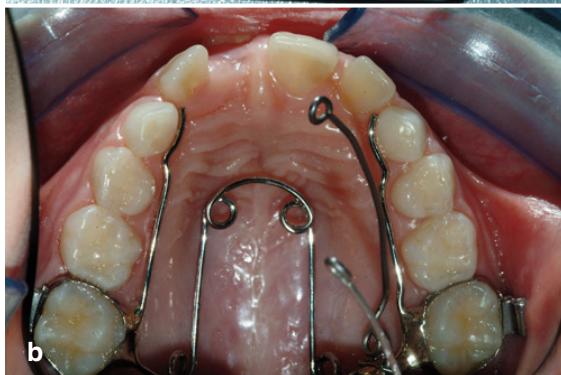
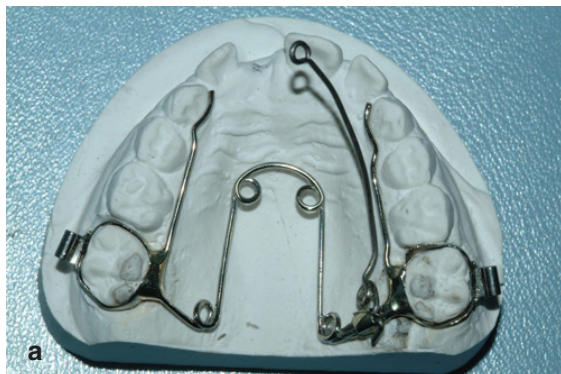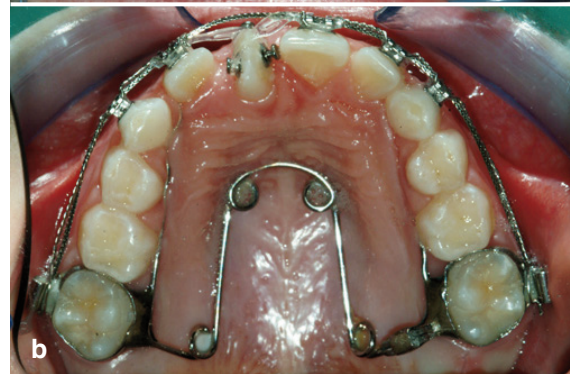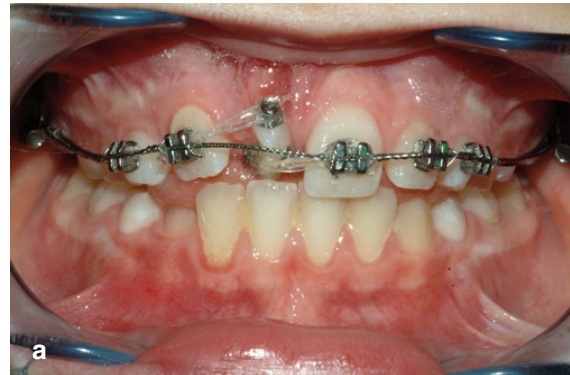Figure 6. Spontaneous eruption after surgical removal of the ankylosed and necrotic primary incisor.



Figures 7 a-b. Modified Quad Helix with a TMA arm and a terminal loop.



Figures 8 a-b. Incisor's derotation.

was tied to an archwire (0.016 x 0.022-in multibraid stainless steel). Thanks to a lingual button and elastic chain the incisor was derotated. Interim radiographs were requested to verify the root positioning. Active treatment with fixed appliance took 10 months (Figs. 8a-8b). When the impacted incisor was in its position in upper arch, brackets were debonded and the patient began wearing essix retainers.

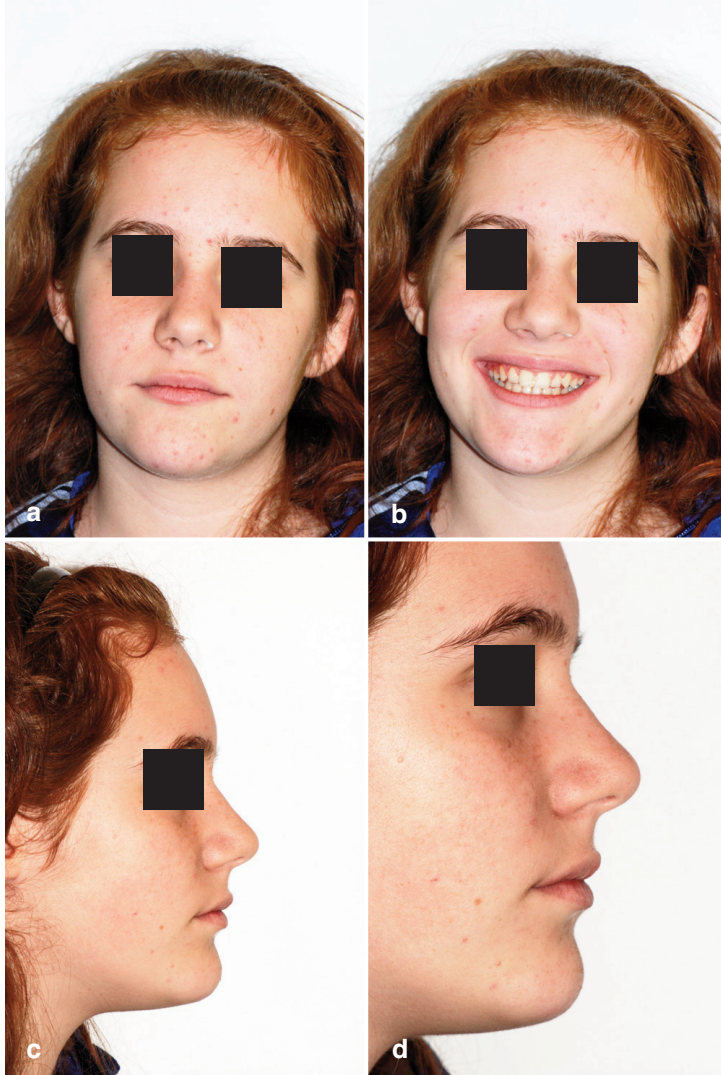
Treatment result

The patient showed a good smile arch and balanced profile (Figs. 9a-9d).

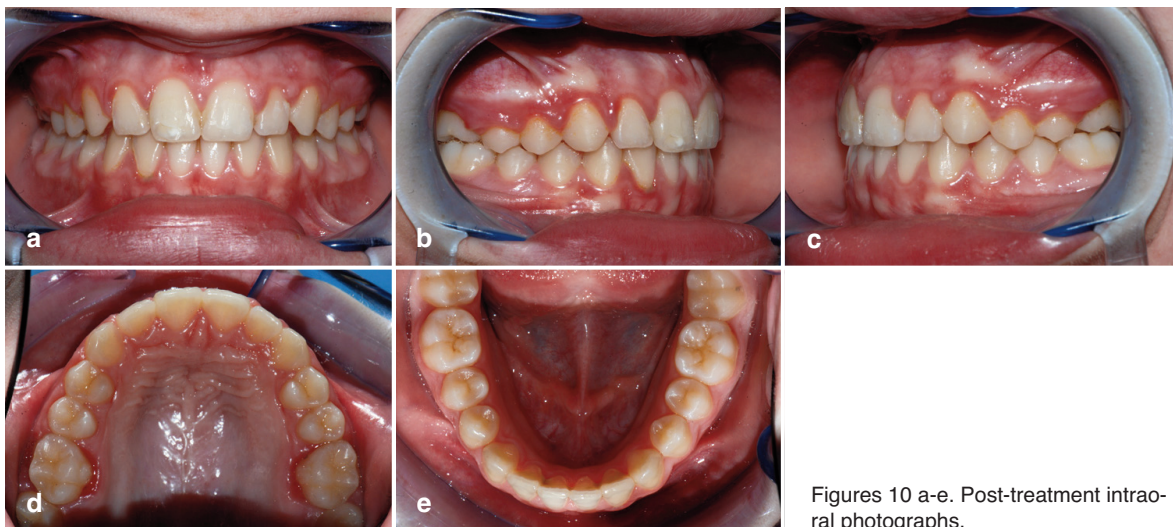
The impacted maxillary right central incisor was successfully brought into proper position. The final appearance of the tooth was esthetically pleasing, with gingival margins at the same level with similar clinical crowns sizes. The tooth responded well to vitality and did not show abnormalities in crown shape. No pulp pathology or color change was found. From a periodontal point of view a band of labial keratinized gingival measuring 4 mm was present, and pocket depth ranged from 1 to 2 mm (Figs. 10a-10e).

Final radiographs indicated intact roots, proper root alignment, and no root disease.

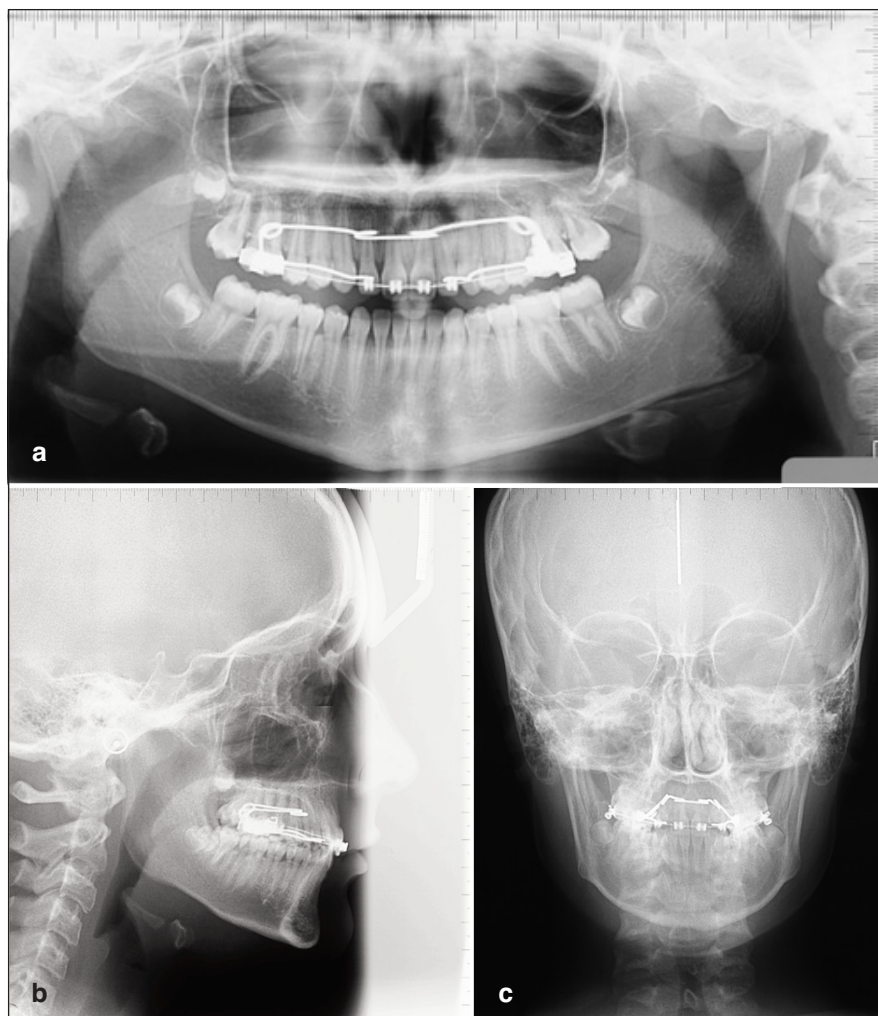A skeletal class I (ANB 3°) was maintained. An ideal overbite and overjet were established and a Class I molar and canine relationship was presented. Upper and lower incisors showed good inclination (IMPA 89°; U1^FH 110°) (Figs. 11a-11c).



Figures 9 a-d. Post-treatment extraoral photographs.



Figures 10 a-e. Post-treatment intraoral photographs.



Figures 11 a-c. Radiographic records: two months before debonding.

Conclusions

A traumatic injury in early age can realize a delay of eruption and eventually an impacted tooth. Upper incisors are the most frequent impacted teeth due to trauma (6).

Surgical exposure and orthodontic traction is the treatment most often used: this technique in fact can lead to suitable results at the periodontal, occlusal and esthetics levels at an early stage and more definitively than with other treatment options.

Sometimes the surgical removal of the retained traumatized primary incisor alone can lead to spontaneous eruption of the permanent tooth.

However long-term monitoring of the stability and periodontal health of the impacted incisor is very important after orthodontic traction (30).

References

1. Altun C, Cehreli ZC, Güven G, Acikel C. Traumatic intrusion of primary teeth and its effects on the permanent successors: a clinical follow-up study. *Oral Surg Oral Med Oral Pathol Oral Radiol Endod* 2009; 107(4):493-498.
2. Kargul B, Caglar E, Tanboga I. Dental trauma in Turkish children, Istanbul. *Dent Traumatol* 2003; 19:72-75.
3. Diab M, elBadrawy HE. Intrusion injuries of primary incisors. Part III: Effects on the permanent successors. *Quintessence Int* 2000; 31(6):377-384.
4. Andreasen JO, Sundström B, Ravn JJ. The effect of traumatic injuries to primary teeth on their permanent successors. I. A clinical and histologic study of 117 injured permanent teeth. *Scand J Dent Res* 1971; 79(4):219-83.
5. Arenas M, Barberia E, Lucavechi T, Maroto M. Severe trauma in the primary dentition - diagnosis and treatment of sequelae in permanent dentition. *Dent Traumatol* 2006; 22(4):226-230.
6. Cozza P, Mucedero M, Ballanti F, De Toffol L. A case of an unerupted maxillary central incisor for indirect trauma localized horizontally on the anterior nasal spine. *J Clin Pediatr Dent* 2005; 29(3):201-203.
7. von Gool AV. Injury to the permanent tooth germ after trauma to the deciduous predecessor. *Oral Surg Oral Med Oral Pathol* 1973; 35(1):2-12.
8. Kuvvetli SS, Seymen F, Gencay K. Management of an unerupted dilacerated maxillary central incisor: a case report. *Dent Traumatol* 2007; 23(4):257-261.
9. Valladares Neto J, de Pinho Costa S, Estrela C. Orthodontic-surgical-endodontic management of unerupted maxillary central incisor with distoangular root dilaceration. *J Endod* 2010; 36(4):755-759.

10. Becker A. The orthodontic treatment of impacted teeth. United Kingdom: Informa Healthcare Editor; 2006.
11. Chaushu S, Chaushu G, Becker A. The role of digital volume tomography in the imaging of impacted teeth. *World J Orthod* 2004; 5(2):120-132.
12. Huber KL, Suri L, Taneja P. Eruption disturbances of the maxillary incisors: a literature review 1: *J Clin Pediatr Dent* 2008; 32(3):221-230.
13. Sawamura T, Minowa K, Nakamura M. Impacted teeth in the maxilla: usefulness of 3D dental-CT for preoperative evaluation. *Eur J Radiol* 2003; 47:221-226.
14. Walker L, Enciso R, Mah J. Three-dimensional localization of maxillary canines with cone-beam computed tomography. *Am J Orthod Dentofacial Orthop* 2005; 128(4):418-423.
15. Chokron A, Reveret S, Salmon B, Vermelin L. Strategies for treating an impacted maxillary central incisor. *Int Orthod* 2010; 8(2):152-176.
16. Machtei EE, Zyskind K, Ben-Yehouda A. Periodontal considerations in the treatment of dilacerated maxillary incisors. *Quintessence Int* 1990; 21(5):357-360.
17. Uematsu S, Uematsu T, Furusawa K, Deguchi T, Kurihara S. Orthodontic treatment of an impacted dilacerated maxillary central incisor combined with surgical exposure and apicoectomy. *Angle Orthod* 2004; 74(1):132-136.
18. Chew MT, Ong M M-A. Orthodontic-surgical management of an impacted dilacerated maxillary central incisor: a clinical case report. *Pediatric Dent* 2004; 26:341-344.
19. Farronato G, Maspero C, Farronato D. Orthodontic movement of a dilacerated maxillary incisor in mixed dentition treatment. *Dent Traumatol* 2009; 25(4):451-456.
20. Tsai TP. Surgical repositioning of an impacted dilacerated incisor in mixed dentition. *J Am Dent Assoc* 2002; 133(1):61-66.
21. Lin YT. Treatment of an impacted dilacerated maxillary central incisor. *Am J Orthod Dentofacial Orthop* 1999; 115(4):406-409.
22. Smailiene D, Sidlauskas A, Bucinskiene J. Impaction of the central maxillary incisor associated with supernumerary teeth: initial position and spontaneous eruption timing. *Stomatologija* 2006; 8(4):103-107.
23. Bryan RA, Cole BO, Welbury RR. Retrospective analysis of factors influencing the eruption of delayed permanent incisors after supernumerary tooth removal. *Eur J Paediatr Dent* 2005; 6(2):84-89.
24. Kearns HP. Dilacerated incisors and congenitally displaced incisors: three case reports. *Dent Update* 1998; 25:339-342.
25. Kokavi D, Becker A, Zilbermann Y. Surgical exposure, orthodontic movement and final tooth position as factor in periodontal breakdown treated palatally impacted canines. *Am J Orthod Dentofacial Orthop* 1984; 85:72-77.
26. Crawford LB. Impacted maxillary central incisor in mixed dentition treatment. *Am J Orthod Dentofacial Orthop* 1997; 76:310-315.
27. Farronato GP, Santoro F, Pignanelli M. Terapia chirurgico ortodontica di denti inclusi in soggetti adulti. *Mondo Ortodontico* 1982; 1:38-49.
28. Vanarsdall RL, Corn H. Soft-tissue management of labially positioned unerupted teeth. *Am J Orthod* 1977; 72:53-64.
29. Vermette ME, Kokich VG, Kennedy DB. Uncovering labially impacted teeth: apically positioned flap and closed-eruption techniques. *Angle Orthod* 1995; 65:23-32.
30. Cozza P, Marino A, Condò R. Orthodontic treatment of an impacted dilacerated maxillary incisor: a case report. *J Clin Pediatr Dent* 2005; 30(2):93-98.