

Iatrogenic Infection of *Clostridium welchii* Following Intramuscular Injection of Sodium Diclofenac

Hemavathi Sathyanarayana, Leela Rani¹, R Rajendran¹, Pooja Sarmah

Departments of Microbiology, Sapthagiri Institute of Medical Sciences and Research Center,
¹Vydehi Institute of Medical Sciences and Research Center, Bangalore, India

Address for correspondence: Dr. Hemavathi Sathyanarayana, E-mail: hemasathyanarayana@yahoo.com

ABSTRACT

Injection site abscess is an iatrogenic infection. Intramuscular (IM) injection is a common route to administer medication. Microorganisms known to cause injection site abscess are *Staphylococcus aureus*, *Pseudomonas*, *Klebsiella*, *Escherichia coli* commonly, *Atypical mycobacteria*, *Clostridium* species rarely. Gas gangrene is a necrotic infection of soft tissue with high mortality, often necessitating amputation in order to control the infection. Here, presenting a case of gas gangrene in a 19-year-old healthy male, who developed a life-threatening infection after IM injection of sodium diclofenac. Prompt clinical diagnosis, laboratory support, and timely surgical intervention saved the patient's life.

Key words: *Clostridium welchii*, gas gangrene, intramuscular injection

INTRODUCTION

Gas gangrene is seen after road accidents or battlefield. In hospitals, danger of gas gangrene occurring postoperatively is recognized, but following intramuscular (IM) injection is rare.^[1] *Clostridium* species is a large intestine commensal and widely distributed in the perianal region and lower limb.^[1] Before administering an injection, skin is cleaned with alcohol, which removes only the vegetative bacteria but not the spore form.^[2] Two essential factors for gas gangrene are implantation of spores and lowered oxygen tension for germination and growth. Traumatic or postoperative gas gangrene accounts for 70% of the cases, followed by spontaneous or nontraumatic gangrene.^[3]

CASE REPORT

A 19-year-old male, presented to our hospital in September 2008, with severe pain in the right gluteal

region. He gave the history of receiving an IM injection- diclofenac sodium from a local practitioner for viral fever and body ache. Within 7-8 h of receiving the injection, pain increased in intensity and radiated toward thigh, by 10-12 h he developed fever and pain increased in severity. He also had difficulty in walking. With the above features, he visited our hospital emergency department. On examination, patient had diffuse swelling with signs of inflammation in the upper posterior aspect of gluteal region there was no hematoma or local tissue damage and patient was febrile (102°F). Systemic examination was normal without other toxic symptoms at the time of admission. Various investigations showed Hb %-11g%, total WBC count-11,400 cells/mm³, Differential count-neutrophil-75%, lymphocytes-20%, monocyte-3%, and eosinophil-2%, ESR-35 mm/h. The diagnosis was injection site abscess and treated with systemic antibiotics (cephalosporin group) and antipyretics.

Within 24 h, patient developed toxic symptoms and had difficulty in moving the limb. Signs of inflammation spread to the lateral part of the thigh. On palpation, crepitus was present. Immediately X-ray of the part was taken which showed gas-filled sac near right hip joint [Figure 1]. Patient was immediately shifted to operation theater and wound debridement was done. Tissue bits were sent for Gram's stain and

Access this article online	
Quick Response Code: 	Website: www.jlponline.org
	DOI: 10.4103/0974-2727.115924

anaerobic culture. Gram's stain revealed plenty of thick, Gram positive bacilli, and very few pus cells. Culture on Robertson's cooked meat media showed abundant gas which was foul smelling. Growth on neomycin blood agar showed grey colonies with swarming. Growth on egg yolk media showed opalescence around the colony. Nagler's reaction was positive which confirmed the organism as *C. welchii*.

Postoperatively patient was started on systemic penicillin, ceftazidime, and metronidazole. Temperature and other vitals were regularly recorded which came to normal by the 8 postoperative day. Patient's general condition gradually improved and range of lower limb movements resumed thereafter. Patient went back home walking at the end of 30 days.

DISCUSSION

Gas gangrene following IM injection is rare and seldom reported in literature. *Clostridium* spores are ubiquitous. Gas gangrene is a rapidly developing and spreading infection mediated by toxins released by *Clostridium spp.*^[4] These infections most likely present with pain out of proportion to the clinical examination. The presence of crepitus can be a late and non specific sign, so the absence of this sign should not sway one from pursuing this diagnosis.^[5]

Identifying the type of *Clostridium* helps predict mortality. With *Cl. Septicum*, it is approximately 63%, and 11% with *Cl. welchii*.^[5] But there is no difference in clinical findings between these two *Clostridial* species infections. Most patients present with nonspecific findings such as fever, leukocytosis, and pain as seen in our case.^[6] *Cl. welchii* myonecrosis usually occurs following trauma. Cases of myonecrosis have been reported following IM administration of adrenaline^[1,7] Vitamin B 12.^[8] In our case the source of *Cl. welchii* could have been the needle, syringe, contamination of the injected fluid or the patient's own skin. The typical incubation period for gas gangrene is short (i.e., <24 h), but incubation periods of 1 h to 6 weeks has also been reported.^[9] In our patient, the symptoms started early that is, 6-7 h.

It should be remembered that even routine procedures like administration of IM injections can lead to dreaded complication like gas gangrene; hence, precautions should be taken for prompt diagnosis and treatment.

The development of central supply department and introduction of disposable sterilized syringes have greatly

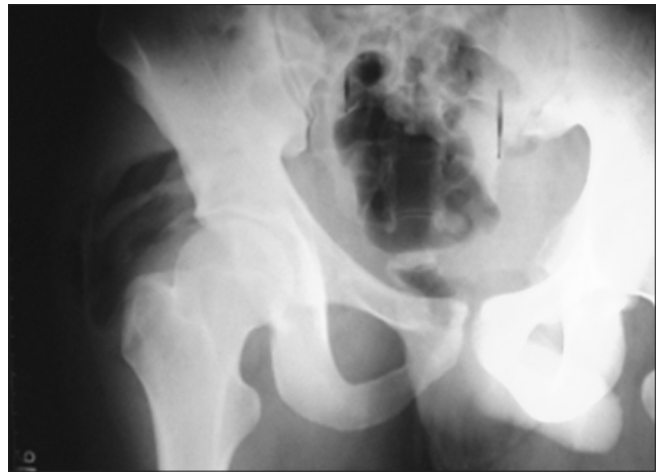


Figure 1: X-ray pelvis anterior posterior view shows evidence of IM gas lucencies, with soft tissue edema in the right gluteal region. No bone involvement

reduced the infections but no means eliminated the risk of infection which can be introduced by injection.^[1]

ACKNOWLEDGEMENTS

Department of General Surgery, Vydehi Institute of Medical Sciences and Research Center, Bangalore for referring the patient

REFERENCES

1. Harvey PW, Purnell GV. Fatal case of gas gangrene associated with intramuscular injection. Br Med J 1968;1:744-6.
2. Rubbo SD, Gardner JF. Intramuscular injection and gas gangrene. Br Med J 1968;241-2.
3. Aggelidakis J, Lasithiotakis K, Topalidou A, Koutroumpas J, Kouvidis G, Katonis P. Limb salvage after gas gangrene: A case report and review of the literature. World J Emerg Surg 2011;6:28.
4. Zelić M, Kunišek L, Mendriła D, Gudelj M, Abram M, Uravić M. Endogenous gas gangrene after laparoscopic cholecystectomy. West Indian Med J 2011;60:96.
5. Feldman MJ, Prosciak M, Maleki Z, Milner SM. Gas gangrene. J Surg Radiol 2010;1:100-1.
6. Myers G, Ngoi SS, Cennerazzo W, Harris L, DeCosse JJ. Clostridial septicemia in an urban hospital. Surg Gynecol Obstet 1992;174:291-6.
7. van Hook R, Vandeveld AG. Gas gangrene after intramuscular injection of epinephrine: Report of a fatal case. Ann Intern Med 1975;83:669-70.
8. Peerapur BV, Mantur BG, Uppin BC, Patil AV. Gas gangrene following intramuscular injection of vitamin B-Complex: Report of a fatal case. Indian J Med Microbiol 2002;20:169.
9. Hoi Ho. Gas Gangrene. Available from <http://emedicine.medscape.com/article/217943-overview#a0104> [Last accessed on 2012 Mar 15].

How to cite this article: Sathyanarayana H, Rani L, Rajendran R, Sarmah P. Iatrogenic infection of *Clostridium welchii* following intramuscular injection of sodium diclofenac. J Lab Physicians 2013;5:58-9.

Source of Support: Nil. **Conflict of Interest:** None declared.