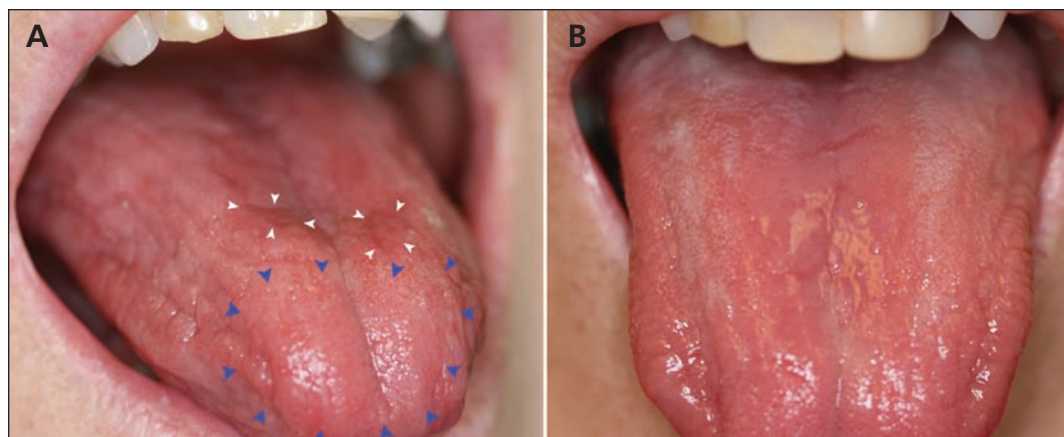


## Glossitis secondary to vitamin B<sub>12</sub> deficiency anemia

Eric T. Stoopler DMD, Arthur S. Kuperstein DDS



**Figure 1: (A) Generalized dryness of the tongue of a 61-year-old woman with vitamin B<sub>12</sub> deficiency, with atrophy (blue arrowheads) and erythematous plaques (white arrowheads). (B) Normal appearance of the tongue 3 days after the patient received a single injection of vitamin B<sub>12</sub>.**

A 61-year-old woman presented with a 6-month history of a persistent burning sensation on her tongue (Figure 1A). The patient was not taking any medications and had not been exposed to any new foods or oral hygiene products at the time her symptoms began. Our clinical diagnosis was glossitis. A cytologic evaluation did not show evidence of *Candida* species. Laboratory investigations to rule out underlying hematologic diseases showed macrocytic anemia and low levels of vitamin B<sub>12</sub> (83 [normal 200–700] pg/mL), consistent with vitamin B<sub>12</sub> deficiency anemia. The patient was referred to her primary care physician for further management of the condition. She received a single injection (1000 µg) of vitamin B<sub>12</sub>, which resulted in complete resolution of her symptoms and the normal clinical appearance of her tongue after 3 days (Figure 1B). The cause of the patient's condition and her need for long-term supplementation remain under investigation.

Vitamin B<sub>12</sub> deficiency anemia most commonly results from malabsorption syndrome (primarily because of a lack of intrinsic factor) or inadequate consumption of the vitamin.<sup>1</sup>

Older people and people with a vegetarian diet are at the highest risk for this form of anemia; up to 20% of older adults have been reported to have the condition.<sup>1,2</sup> The initial clinical presentation of vitamin B<sub>12</sub> deficiency anemia often includes nonspecific symptoms such as fatigue, weakness, paresthesias and vertigo.<sup>2</sup>

Glossitis is present in up to 25% of cases,<sup>3</sup> initially presenting as inflammatory changes characterized by bright red plaques; it may then evolve into the atrophic form, noted as atrophy of the lingual papillae, affecting more than 50% of the tongue's surface.<sup>3</sup> Reported oral symptoms include a burning sensation, pruritus, lingual paresthesia, glossodynia and dysgeusia.<sup>3</sup> Treatment is usually lifelong intramuscular or oral administration of vitamin B<sub>12</sub>.<sup>3</sup>

### References

1. Ryan-Harshman M, Aldoori W. Vitamin B<sub>12</sub> and health. *Can Fam Physician* 2008;54:536-41.
2. Gupta AK, Damji A, Uppaluri A. Vitamin B<sub>12</sub> deficiency. Prevalence among south Asians at a Toronto clinic. *Can Fam Physician* 2004;50:743-7.
3. Graells J, Ojeda RM, Muniesa C, et al. Glossitis with linear lesions: an early sign of vitamin B<sub>12</sub> deficiency. *J Am Acad Dermatol* 2009;60:498-500.

**Competing interests:** Eric Stoopler is a member of the executive committee and board of the American Academy of Oral Medicine; he has received grants from the Health Resources and Services Administration; he has received payment for lectures from Dent-Ed Solutions LLC, Kent-Sussex Dental Society and the US Veterans Administration (VA); he receives royalties from the American Dental Association; and he has provided testimony as an expert witness for various legal firms. Arthur Kuperstein has received payment for lectures from the Philadelphia VA Medical Centre and various dental societies in the tristate area.

This article has been peer reviewed.

**Affiliation:** From the Department of Oral Medicine, University of Pennsylvania School of Dental Medicine, Philadelphia, Pa.

**Correspondence to:** Eric T. Stoopler, ets@dental.upenn.edu

**CMAJ 2013. DOI:10.1503/cmaj.120970**