

## Original Article

# Locoregional extension patterns of nasopharyngeal carcinoma and suggestions for clinical target volume delineation

Wen-Fei Li<sup>1,2</sup>, Ying Sun<sup>1,2</sup>, Mo Chen<sup>1,2</sup>, Ling-Long Tang<sup>1,2</sup>, Li-Zhi Liu<sup>1,3</sup>, Yan-Ping Mao<sup>1,2</sup>, Lei Chen<sup>1,2</sup>, Guan-Qun Zhou<sup>1,2</sup>, Li Li<sup>1,3</sup> and Jun Ma<sup>1,2</sup>

## Abstract

Clinical target volume (CTV) delineation is crucial for tumor control and normal tissue protection. This study aimed to define the locoregional extension patterns of nasopharyngeal carcinoma (NPC) and to improve CTV delineation. Magnetic resonance imaging scans of 2366 newly diagnosed NPC patients were reviewed. According to incidence rates of tumor invasion, the anatomic sites surrounding the nasopharynx were classified into high-risk (>30%), medium-risk (5%–30%), and low-risk (<5%) groups. The lymph node (LN) level was determined according to the Radiation Therapy Oncology Group guidelines, which were further categorized into the upper neck (retropharyngeal region and level II), middle neck (levels III and Va), and lower neck (levels IV and Vb and the supraclavicular fossa). The high-risk anatomic sites were adjacent to the nasopharynx, whereas those at medium- or low-risk were separated from the nasopharynx. If the high-risk anatomic sites were involved, the rates of tumor invasion into the adjacent medium-risk sites increased; if not, the rates were significantly lower ( $P < 0.01$ ). Among the 1920 (81.1%) patients with positive LN, the incidence rates of LN metastasis in the upper, middle, and lower neck were 99.6%, 30.2%, and 7.2%, respectively, and skip metastasis happened in only 1.2% of patients. In the 929 patients who had unilateral upper neck involvement, the rates of contralateral middle neck and lower neck involvement were 1.8% and 0.4%, respectively. Thus, local disease spreads stepwise from proximal sites to distal sites, and LN metastasis spreads from the upper neck to the lower neck. Individualized CTV delineation for NPC may be feasible.

**Key words** Nasopharyngeal carcinoma, magnetic resonance imaging, local extension, lymph node spread, clinical target volume

Nasopharyngeal carcinoma (NPC) has an extremely unbalanced endemic distribution, and it is prevalent in southern China, with Chinese accounting for 40% of all incident NPC cases worldwide<sup>[1]</sup>; thus, NPC is also known as the “Cantonese cancer.” Radiotherapy is the mainstay treatment modality for NPC. Intensity-modulated radiotherapy (IMRT) has gradually replaced

two-dimensional conventional radiotherapy as the primary means of radiotherapy because of better tumor target coverage and normal tissue sparing. With the application of IMRT, the treatment outcome and quality of life for NPC patients have been greatly improved<sup>[2-6]</sup>. IMRT requires the delineation of target volumes on cross-sectional imaging; precise target volume delineation is crucial for tumor control and normal tissue protection because of the highly conformal radiation dose distribution in IMRT. According to the International Commission on Radiation Units and Measurements (ICRU) reports 50<sup>[7]</sup> and 62<sup>[8]</sup>, the gross tumor volume (GTV) consists of primary tumor and metastatic lymphadenopathy. In addition, clinical tumor volume (CTV) can be subdivided into CTV1 (high-risk subclinical disease) and CTV2 (low-risk subclinical disease), though the optimal delineation has not been determined. Better understanding the locoregional extension patterns of

**Authors' Affiliations:** <sup>1</sup>State Key Laboratory of Oncology in South China, Guangzhou, Guangdong 510060, P. R. China; <sup>2</sup>Department of Radiation Oncology, <sup>3</sup>Imaging Diagnosis and Interventional Center, Sun Yat-sen University Cancer Center, Guangzhou, Guangdong 510060, P. R. China.

**Corresponding Author:** Jun Ma, Department of Radiation Oncology, Sun Yat-sen University Cancer Center, 651 Dongfeng Road East, Guangzhou, Guangdong 510060, P. R. China. Tel: +86-20-87343469; Email: majun@susucc.org.cn.

doi: 10.5732/cjc.012.10095

NPC will directly impact individualized CTV delineation. Therefore, we reviewed magnetic resonance imaging (MRI) scans of a large sample of NPC patients and documented the patterns of locoregional extension of NPC, aiming to improve CTV delineation.

## Materials and Methods

### Patients

A total of 2366 patients with non-distant metastatic and histologically proven NPC newly diagnosed between January 2003 and December 2008 were included in our

study. All patients completed a pre-treatment evaluation that included physical examination, nasopharyngeal fiberoptic endoscopy, MRI scan of the nasopharynx and neck, chest radiography, abdominal sonography, and whole body bone scan. Additionally, 184 (7.8%) patients underwent  $^{18}\text{F}$ -fluorodeoxyglucose-positron emission tomography/computed tomography (FDG-PET/CT). Medical records and imaging studies were analyzed, and all patients were restaged according to the 7th edition of the Union for International Cancer Control/American Joint Committee on Cancer (UICC/AJCC) staging system<sup>[9]</sup>. Patient clinicopathologic characteristics are shown in Table 1.

**Table 1. Clinicopathologic characteristics of the 2366 nasopharyngeal carcinoma (NPC) patients**

Characteristic	No. of patients (%)
Gender	
Male	1775 (75.0)
Female	591 (25.0)
Age (years)	
> 50	766 (32.4)
≤ 50	1600 (67.6)
Histology	
WHO type I	4 (0.2)
WHO type II/III	2362 (99.8)
Radiotherapy	
Two-dimensional conventional radiotherapy	1540 (65.1)
Three-dimensional conformal radiotherapy	17 (0.7)
Intensity-modulated radiotherapy	809 (34.2)
Chemotherapy	
Yes	1615 (68.3)
Concurrent chemoradiotherapy	621 (26.2)
Neoadjuvant + concurrent chemoradiotherapy	442 (18.7)
Concurrent chemoradiotherapy + adjuvant	117 (4.9)
Others	435 (18.4)
No	751 (31.7)
T category	
T1	481 (20.3)
T2	525 (22.2)
T3	868 (36.7)
T4	492 (20.8)
N category	
N0	446 (18.9)
N1	1288 (54.4)
N2	452 (19.1)
N3	180 (7.6)
Stage	
I	161 (6.8)
II	580 (24.5)
III	978 (41.3)
IVa	467 (19.7)
IVb	180 (7.6)

## Imaging protocol

All patients underwent MRI using a 1.5-T system (Signa CV/i; General Electric Healthcare, Chalfont St. Giles, United Kingdom) to examine the region from the suprasellar cistern to the inferior margin at the sternal end of the clavicle with a head-and-neck combined coil. T1-weighted fast spin-echo images in the axial, coronal, and sagittal planes (repetition time 500–600 ms, echo time 10–20 ms, 22-cm field of view) and T2-weighted fast spin-echo images in the axial plane (repetition time 4000–6000 ms, echo time 95–110 ms, 22-cm field of view) were obtained before injection of contrast material. After intravenous administration of gadopentetate dimeglumine (Gd-DTPA; Magnevist, Schering, Berlin, Germany) at a dose of 0.1 mmol/kg, T1-weighted spin-echo axial and sagittal sequences and T1-weighted spin-echo fat-suppressed coronal sequences were performed sequentially with the same parameters prior to Gd-DTPA injection, using a section thickness of 5 mm

and a matrix size of 512 × 512.

## Image assessment and diagnostic criteria

Two radiologists specializing in head-and-neck cancers evaluated all scans separately, and any disagreements were resolved by consensus. The anatomic sites surrounding the nasopharynx are listed in Table 2. Nasal cavity invasion was defined as the tumor invading the bony nasal septum, turbinate or exceeding beyond the line connecting bilateral pterygopalatine fossae<sup>[9,12]</sup>. Oropharyngeal involvement was defined as tumor involvement below the plane of the superior surface of the soft palate or the lower margin of C1<sup>[9,12-14]</sup>. Hypopharyngeal involvement was defined as tumor detection below the plane of the superior border of the hyoid bone or the lower margin of C3<sup>[9,10,12]</sup>. Infratemporal fossa involvement was defined as extension beyond the anterior surface of the lateral pterygoid muscle or lateral extension beyond the posterolateral wall of the maxillary

**Table 2. Rates of tumor invasion into anatomic sites surrounding the nasopharynx**

Anatomic site	No. of patients (%)
<b>High-risk</b>	
Tensor veli palatine muscle	1570 (66.4)
Nasal cavity	1224 (51.7)
Basis of sphenoid bone	1105 (46.7)
Pterygoid process	1063 (44.9)
Clivus	934 (39.5)
Petrous apex	932 (39.4)
Prevertebral muscle	876 (37.0)
Foramen lacerum	826 (34.9)
<b>Medium-risk</b>	
Foramen ovale	557 (23.5)
Great wing of sphenoid bone	554 (23.4)
Oropharynx	509 (21.5)
Medial pterygoid muscle	449 (19.0)
Cavernous sinus	424 (17.9)
Pterygopalatine fossa	407 (17.2)
Sphenoidal sinus	374 (15.8)
Hypoglossal canal	256 (10.8)
Lateral pterygoid muscle	219 (9.3)
Ethmoid sinus	124 (5.2)
Jugular foramen	120 (5.1)
<b>Low-risk</b>	
Orbit	93 (3.9)
Infratemporal fossa	73 (3.1)
Cervical vertebrae	54 (2.3)
Maxillary sinus	51 (2.2)
Hypopharynx	21 (0.9)
Frontal sinus	5 (0.2)

sinus or pterygomaxillary fissure<sup>[15]</sup>. The criterion for orbit invasion was the tumor extending to the orbital apex, the inferior orbital fissure, or the superior orbital fissure<sup>[16]</sup>. Bilateral NPC was defined as the primary tumor extending across the midline of the nasopharynx<sup>[17]</sup>. According to incidence rates of tumor invasion, the anatomic sites surrounding the nasopharynx were classified into high-risk (>30%), medium-risk (5%–30%), and low-risk (<5%) groups.

The diagnostic criteria for lymph node (LN) metastases<sup>[18,19]</sup> included (a) lateral retropharyngeal lymph node (RLN) with a minimal axial diameter (MID) of  $\geq 5$  mm in the largest plane or any node in the median retropharyngeal group; (b) cervical lymph node (CLN) in the jugulodigastric region with a MID  $\geq 11$  mm or all other CLNs  $\geq 10$  mm; (c) LNs of any size with central necrosis or a contrast-enhanced rim; (d) nodal grouping, the presence of 3 or more aggregated LNs, each having an MID of 8 to 10 mm; and (e) LNs of any size with extracapsular spread as characterized by irregular LN capsular enhancement, obliterated fat space between the node and adjacent tissues, and/or confluent LNs. The assignment of LN location was made according to the Radiation Therapy Oncology Group (RTOG) guidelines<sup>[20,21]</sup>. Using the superior border of the hyoid bone and the lower border of the cricoid cartilage as two separators, we further categorized the neck node levels into three volumes: upper neck, which included retropharyngeal region (RP) and level II; middle neck, which included levels III and Va; and lower neck, which included levels IV and Vb and the supraclavicular fossa (SCF).

## Statistical analysis

Statistical analysis was performed using Statistical Package for the Social Sciences (SPSS) 13.0 (Chicago, IL, USA). The Chi-square test was used to examine differences between categorical variables, and two-tailed *P* values < 0.05 were considered significant.

## Results

### Characteristics and pattern of local tumor extension

The cumulative rates of tumor invasion into the anatomic sites surrounding the nasopharynx are shown in Table 2. The tensor veli palatine muscle (TVPM) had the highest involvement rate (66.4%), followed by the nasal cavity (51.7%). The anatomic sites at high risk included the TVPM, nasal cavity, basis of sphenoid bone, pterygoid process, clivus, petrous apex,

prevertebral muscle, and foramen lacerum. The medium-risk anatomic sites included the foramen ovale, great wing of the sphenoid bone, oropharynx, medial pterygoid muscle, cavernous sinus, pterygopalatine fossa, sphenoidal sinus, hypoglossal canal, lateral pterygoid muscle, ethmoid sinus, and jugular foramen. The low-risk sites included the orbit, infratemporal fossa, cervical vertebrae, maxillary sinus, hypopharynx, and frontal sinus. Thus, the high-risk anatomic sites were adjacent to the nasopharynx, whereas those at medium or low risk were separated from the nasopharynx (except the oropharynx).

If high-risk anatomic sites were involved, the rates of tumor invasion into the adjacent medium-risk sites increased; if not, the rates were significantly lower ( $P < 0.01$ ) (Table 3). For example, when the tumor invaded the TVPM, 28.5% of patients had medial pterygoid muscle involvement; in contrast, when the TVPM was not involved, only 0.3% of patients had medial pterygoid muscle involvement. Similarly, the rate of tumor invasion into the cavernous sinus reached more than 40% if the clivus, petrous apex, and/or foramen lacerum were involved; if not, the rate was lower than 3%.

Among all patients, 94% had bilateral NPC, and most had tumor invasion of the superior-posterior wall and extending across the midline of the nasopharynx. However, most anatomic sites were at low risk of concurrent bilateral tumor invasion (<10%) except the TVPM (13.8%) and prevertebral muscle (13%).

### Characteristics and pattern of LN metastasis

In this cohort of patients, the rate of LN metastasis was 81.1% (1920/2366), and bilateral LN involvement was observed in 52.3% (1004/1920) of patients. Among the neck node levels according to the RTOG guidelines, RP (84.8%, 1628/1920) and level IIb (61.5%, 1181/1920) were the most frequently involved regions, followed in order by levels IIa, III, Va, IV, Vb, SCF, and Ib. No LN metastasis was found in the retrostyloid space or in levels Ia or VI (Table 4).

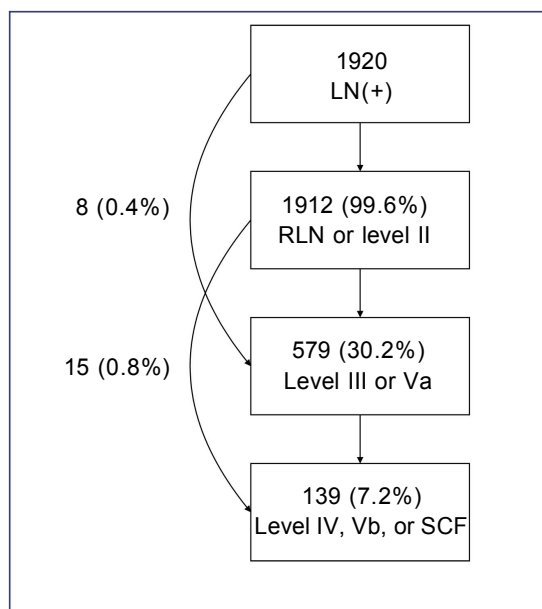
In the 1920 patients with positive LNs, the involvement rates of upper neck (RP and level II), middle neck (levels III and Va) and lower neck (levels IV, Vb, and SCF) were 99.6% (1912/1920), 30.2% (579/1920) and 7.2% (139/1920), respectively, and skip metastasis occurred in only 1.2% (23/1920) of patients (Figure 1). In the 929 patients who had unilateral upper neck involvement, the involvement rates of ipsilateral middle neck and lower neck were 19.5% (181/929) and 4.3% (40/929), respectively, whereas the involvement rates of contralateral middle neck and lower neck were only 1.8% (17/929) and 0.4% (4/929), respectively. However, in the 983 patients with bilateral upper neck involvement, the rates of LN metastasis to the middle neck and lower

**Table 3. Relationship between tumor invasion into anatomic sites at high risk and invasion into the adjacent medium-risk anatomic sites**

Medium-risk site	Tumor invasion		<i>P</i>
Tensor veli palatine muscle			
	Invasion	Non-invasion	
Foramen ovale	33.9% (533/1570)	3.0% (24/796)	< 0.01
Great wing of sphenoid bone	33.8% (531/1570)	2.9% (23/796)	< 0.01
Medial pterygoid muscle	28.5% (447/1570)	0.3% (2/796)	< 0.01
Oropharynx	28.3% (445/1570)	8.0% (64/796)	< 0.01
Pterygopalatine fossa	24.1% (378/1570)	3.6% (29/796)	< 0.01
Nasal cavity			
	Invasion	Non-invasion	
Pterygopalatine fossa	29.4% (360/1224)	4.1% (47/1142)	< 0.01
Ethmoid sinus	9.2% (113/1224)	1.0% (11/1142)	< 0.01
Basis of sphenoid bone			
	Invasion	Non-invasion	
Great wing of sphenoid bone	48.8% (539/1105)	1.2% (15/1261)	< 0.01
Foramen ovale	47.5% (525/1105)	2.5% (32/1261)	< 0.01
Sphenoidal sinus	33.1% (366/1105)	0.6% (8/1261)	< 0.01
Pterygoid process			
	Invasion	Non-invasion	
Great wing of sphenoid bone	49.1% (522/1063)	2.5% (32/1303)	< 0.01
Foramen ovale	48.4% (515/1063)	3.2% (42/1303)	< 0.01
Medial pterygoid muscle	37.7% (401/1063)	3.7% (48/1303)	< 0.01
Pterygopalatine fossa	36.9% (392/1063)	1.2% (15/1303)	< 0.01
Lateral pterygoid muscle	19.4% (206/1063)	1.0% (13/1303)	< 0.01
Clivus			
	Invasion	Non-invasion	
Great wing of sphenoid bone	54.0% (504/934)	3.5% (50/1432)	< 0.01
Foramen ovale	52.5% (490/934)	4.7% (67/1432)	< 0.01
Cavernous sinus	42.4% (396/934)	2.0% (28/1432)	< 0.01
Sphenoidal sinus	36.3% (339/934)	2.4% (35/1432)	< 0.01
Hypoglossal canal	26.6% (248/934)	0.6% (8/1432)	< 0.01
Jugular foramen	12.5% (117/934)	0.2% (3/1432)	< 0.01
Petrous apex			
	Invasion	Non-invasion	
Foramen ovale	54.8% (511/932)	3.2% (46/1434)	< 0.01
Great wing of sphenoid bone	54.4% (507/932)	3.3% (47/1434)	< 0.01
Cavernous sinus	42.8% (399/932)	1.7% (25/1434)	< 0.01
Hypoglossal canal	27.0% (252/932)	0.3% (4/1434)	< 0.01
Jugular foramen	12.8% (119/932)	0.1% (1/1434)	< 0.01
Prevertebral muscle			
	Invasion	Non-invasion	
Oropharynx	32.6% (286/876)	15.0% (223/1490)	< 0.01
Hypoglossal canal	26.9% (236/876)	1.3% (20/1490)	< 0.01
Jugular foramen	11.9% (104/876)	1.1% (16/1490)	< 0.01
Foramen lacerum			
	Invasion	Non-invasion	
Foramen ovale	57.9% (478/826)	5.1% (79/1540)	< 0.01
Great wing of sphenoid bone	56.7% (468/826)	5.6% (86/1540)	< 0.01
Cavernous sinus	46.4% (383/826)	2.7% (41/1540)	< 0.01

**Table 4. Characteristics of nodal spread of the 1920 patients with node-positive NPC**

Level	No. of patients (%)
Retropharyngeal region	1628 (84.8)
Level IIb	1181 (61.5)
Level IIa	706 (36.8)
Level III	545 (28.4)
Level Va	155 (8.1)
Level IV	102 (5.3)
Level Vb	50 (2.6)
Supraclavicular fossa	46 (2.4)
Level Ib	39 (2.0)

**Figure 1. The pattern of lymph node metastasis.** RLN, retropharyngeal lymph node; SCF, supraclavicular fossa.

neck increased to 39.2% (385/983) and 9.6% (94/983), respectively.

## Discussion

The CTV in IMRT planning for NPC includes CTV1 and CTV2. CTV1 is defined as high-risk regions including GTV (the primary tumor and RLN) plus a 5- to 10-mm margin and the entire nasopharyngeal mucosa plus a 5-mm submucosal volume. CTV2 includes the low-risk areas of the nasopharynx and neck that need prophylactic irradiation, but the optimal region remains controversial<sup>[3-6,22,23]</sup>. In some treatment centers, there is no CTV2 but CTV1 in NPC treatment planning, and the region of CTV1 is similar to that of CTV2. At treatment centers in North America<sup>[23]</sup>, Hong Kong<sup>[3]</sup>, and Singapore<sup>[4]</sup>, CTV2 includes the entire nasopharynx, posterior 1/4 to 1/3 of the nasal cavity and maxillary sinuses, parapharyngeal space, pterygoid fossae, anterior 1/2 to

2/3 of the clivus (entire clivus, if involved), skull base (foramen ovale bilaterally), inferior sphenoid sinus, cavernous sinus, and bilateral RP, and levels II–IV (Table 5). Although locoregional control rates greater than 90% have been reported in these centers, the method of CTV2 delineation was largely derived from the experience of conventional radiotherapy, which encompassed most anatomic sites surrounding the nasopharynx bilaterally and did not differ according to the clinical stage. Thus, this delineation method is suboptimal and lacks individualization. Ng *et al.*<sup>[24]</sup> reported the patterns of failure after IMRT in 193 NPC patients and found that most of the locoregional failure occurred “in field” (within the 95% isodose lines), whereas marginal or outside-field failure was uncommon. Therefore, whether the volume of CTV2 can be selectively reduced to better protect normal tissue without affecting local tumor control has become a research focus in the field of IMRT planning for NPC.

**Table 5. Differences of delineation of clinical target volume (CTV, for CTV2) in intensity-modulated radiotherapy for NPC in different cancer centers**

Region	RTOG0615 <sup>[23]</sup>	Singapore <sup>[4]</sup>	Hong Kong <sup>[3]</sup>	Fuzhou <sup>[5]</sup>	Chinese guideline <sup>[22]</sup>
Nasal cavity	Posterior 1/4–1/3	Posterior 1/3	Posterior 1/3	5 mm anterior to the posterior nasal aperture	Posterior part
Maxillary sinus	Posterior 1/4–1/3	Posterior 1/3	Posterior 1/3	5 mm anterior to the maxillary mucosa	5 mm anterior to the maxillary mucosa
Clivus	Anterior 1/2–2/3 (entire if involved)	Anterior 1/2 (entire if involved)	Anterior 1/2 (entire if involved)	Anterior 1/3	Anterior 1/3
Foramen ovale	Bilaterally	Bilaterally	Bilaterally	–	Bilaterally
Sphenoid sinus	Inferior part (entire in T3–T4 disease)	Included	Included	Inferior part (entire if involved)	Inferior wall/basis
Cavernous sinus	Included in high-risk patients (T3, T4, bulky disease involving the roof of the nasopharynx)	Included	Included	Inferior part	–
Retropharyngeal lymph node	Bilaterally (skull base to cranial edge of the hyoid)	Bilaterally (skull base to the level of the hyoid)	Bilaterally (skull base to the bottom of the hyoid)	Bilaterally (skull base to cranial edge of C2)	Bilaterally (skull base to caudal edge of C2)
Levels II–V	Bilaterally	Bilaterally	Electively irradiated	Bilaterally	Electively irradiated
Level Ib	Bilaterally included in node-positive patients	Included if the ipsilateral neck involved	Electively irradiated	–	Electively irradiated

Recently, Lin *et al.*<sup>[5]</sup> reported that IMRT using a reduced-CTV2 technique (Table 5) for NPC provided favorable 3-year local control, regional control, and overall survival rates of 95%, 98%, and 90%, respectively. In total, 10 of the 12 cases with local recurrence occurred within the GTV, and 2 additional cases recurred locally with a component out of the GTV. No isolated recurrence was found at the margin of the reduced CTV2. Among the 6 patients with regional recurrence, 4 recurred within the CTV2, and 2 additional cases recurred within the region of the spared parotid gland. Tang *et al.*<sup>[25]</sup> compared the prognosis of 138 NPC patients with N0 disease with or without prophylactic lower neck irradiation. None of the patients in either group experienced regional failure, and the risks of distant metastasis did not differ statistically. Gao *et al.*<sup>[26]</sup> retrospectively analyzed the clinical data of 410 patients with LN-negative NPC. CTV2 in the neck only included bilateral RP and levels II, III, and Va, instead of whole-neck irradiation. In a median follow-up of 54 months, 4 patients developed LN recurrence: 3 had nodal recurrences occurred in level II, and only 1 had outside-field LN recurrence in level IV. The above results suggest that individualized radiotherapy with reduced CTV2 in treating NPC is feasible.

The delineation of CTV2 should be designed individually based on the GTV, the locoregional

extension patterns, and the biological nature of NPC, so that unnecessary or missed irradiation can be avoided<sup>[17]</sup>. For the local extension pattern, we classified the anatomic sites surrounding the nasopharynx into high-risk, medium-risk, and low-risk groups, and found that the risk of tumor invasion into various anatomic sites was closely correlated with the distance to the nasopharynx and whether the adjacent anatomic sites were involved. The anatomic sites at high risk, such as the TVPM, nasal cavity, and basis of sphenoid bone, were adjacent to the nasopharynx, whereas the anatomic sites at medium or low risk (except oropharynx) were distant from the nasopharynx and separated from it by other anatomic sites. If the high-risk anatomic sites were involved, the rates of tumor invasion into the adjacent medium-risk sites increased; if not, the rates were significantly lower ( $P < 0.01$ ). The results of this study indicate that local disease spreads stepwise from proximal sites to distal sites, and a skip pattern of local extension is unusual, which further confirms the findings of Liang *et al.*<sup>[17]</sup>.

Notably, in some cases, the rates of tumor invasion into the anatomic sites at medium risk still reached more than 5%, even when the adjacent high-risk sites were not involved. For example, oropharyngeal involvement had a rate of 8%–15% without TVPM and/or prevertebral muscle involvement, which indicated that NPC could directly

invade the oropharynx through submucosal infiltration. There is a complicated relationship between the various anatomic sites surrounding the nasopharynx, and an anatomic site is usually adjacent to various structures and connected with other distant sites through natural cavity and neural foramina. Dubrulle *et al.*<sup>[27]</sup> and Liang *et al.*<sup>[17]</sup> reported several common pathways of local NPC extension. The well-known routes included tumor invasion into the cavernous sinus through the foramen lacerum and/or foramen ovale, involvement of the infratemporal fossa through pterygopalatine fossa, and others. Thus, whether the anatomic site should be included in CTV2 may not only depend on if adjacent sites are involved. Because NPC has multiple focus origins and usually involves both sides of the nasopharynx, we recommend that bilateral anatomic sites at high risk (i.e., the parapharyngeal space, posterior part of nasal cavity, pterygoid process, prevertebral muscle, clivus, petrous apex, foramen lacerum, and basis of the sphenoid bone), as well as other high-risk neural foramina (i.e., the pterygopalatine fossa and foramen ovale bilaterally) should be included in CTV2, which is similar to the definition of CTV2 in the 2010 Chinese Consensus Guidelines for NPC IMRT planning (Table 5)<sup>[22]</sup>. However, the decision to include anatomic sites at medium or low risk in the definition of CTV2 should be based on multiple factors, including the distance from GTV, involvement of the ipsilateral adjacent anatomic sites, and the common routes of tumor spread, to maximize the tumor-killing and normal tissue-protecting effects and achieve individualized treatment.

For the pattern of LN metastasis, Tang *et al.*<sup>[25]</sup> showed that RP and level II were the first echelon of LN metastasis in NPC, with levels III and V being the second echelon, and levels IV and SCF being the third echelon. In the current study, we used the superior border of the hyoid bone and lower border of the cricoid cartilage as two separators and categorized the RTOG guidelines into upper neck (RP and level II), middle neck (levels III and Va), and lower neck (levels IV, Vb, and SCF). We found that the rates of LN metastasis to the upper, middle, and lower neck decreased successively, and skip metastasis happened only in 1.2% of patients. Moreover, in patients with unilateral upper neck involvement, the involvement rates of ipsilateral middle neck and lower neck were 19.5% and 4.3% respectively, whereas the involvement rates of contralateral middle or lower neck were less than 2%. However, when the bilateral upper neck was involved, the rates of LN metastasis to the middle or lower neck markedly increased. Our results confirm that LN metastasis spreads from upper neck to lower neck, and skip

metastasis is unusual, which concurs with the findings of Tang *et al.*<sup>[25]</sup>. Tomita *et al.*<sup>[28]</sup> investigated the pattern of LN metastasis in unilateral NPC and found that the involvement rates of contralateral RLN and level II were 10% and 16%, respectively, whereas less than 3% of patients had involvement of contralateral levels III, IV, and/or V. Thus, the authors indicated that contralateral LN areas other than RLN and level II could be omitted in patients with unilateral NPC. In this study, 94% of patients had bilateral NPC, and the relationship between the laterality of local disease and LN metastasis was not analyzed. Therefore, we recommend that for patients with N0 disease, CTV2 should only include bilateral RP and levels II, III, and Va. For patients with unilateral LN involvement, CTV2 can include whole ipsilateral neck and contralateral RP and levels II, III, and Va; for patients with bilateral LN involvement, bilateral whole neck should be included.

The 2010 Chinese Consensus Guidelines were similar to our recommendations on the setting of nodal CTV2. However, they separated RLNs from CLNs and proposed that the CTV2 of RLN should refer to that of the primary disease because of their close relation. Furthermore, for patients with RLN metastasis alone, CTV2 can only include bilateral RP and levels II, III, and Va<sup>[22]</sup>. Several studies have indicated that both RLNs and level II nodes are the first-echelon nodes in NPC<sup>[25,29]</sup>, and RLN metastasis has been classified as N1 disease<sup>[9,10]</sup>. Thus, the nodal CTV2 for patients with RLN metastasis should be the same as that for patients with level II involvement. Most recently, Ou *et al.*<sup>[30]</sup> reviewed records of 119 NPC patients with RLN metastasis alone and found that the treatment outcome of elective irradiation to RP and levels II, III, and Va was not inferior to that of whole neck irradiation; however, these results need to be confirmed with prospective data.

In conclusion, we showed in this large sample size, retrospective study that local disease spread stepwise from proximal sites to distal sites, that LN metastasis spread from upper neck to lower neck in NPC, and that a skip pattern of local extension and LN metastasis was unusual. Elective radiation of the anatomic sites surrounding the nasopharynx and the RTOG guidelines for neck levels may be feasible. However, our recommendations for individualized CTV delineation for NPC should be considered suggestive and not definitive until these results can be confirmed by large prospective studies.

Received: 2012-04-15; revised: 2012-06-11;  
accepted: 2012-07-04.



## References

- [1] Parkin DM, Whelan SL, Ferlay J, et al. Cancer incidence in five continents, Vol. VIII. Lyon: IARC Press. 2002.
- [2] Lee N, Xia P, Quivey JM, et al. Intensity-modulated radiotherapy in the treatment of nasopharyngeal carcinoma: an update of the UCSF experience. *Int J Radiat Oncol Biol Phys*, 2002,53:12–22.
- [3] Kam MK, Teo PM, Chau RM, et al. Treatment of nasopharyngeal carcinoma with intensity-modulated radiotherapy: the Hong Kong experience. *Int J Radiat Oncol Biol Phys*, 2004,60:1440–1450.
- [4] Tham IW, Hee SW, Yeo RM, et al. Treatment of nasopharyngeal carcinoma using intensity-modulated radiotherapy—the national cancer centre Singapore experience. *Int J Radiat Oncol Biol Phys*, 2009,75:1481–1486.
- [5] Lin S, Pan J, Han L, et al. Nasopharyngeal carcinoma treated with reduced-volume intensity-modulated radiation therapy: report on the 3-year outcome of a prospective series. *Int J Radiat Oncol Biol Phys*, 2009,75:1071–1078.
- [6] Lai SZ, Li WF, Chen L, et al. How does intensity-modulated radiotherapy versus conventional two-dimensional radiotherapy influence the treatment results in nasopharyngeal carcinoma patients? *Int J Radiat Oncol Biol Phys*, 2011,80:661–668.
- [7] International Commission of Radiation Units and Measurements. ICRU report 50: prescribing, recording, and reporting photon beam therapy. Bethesda: International Commission on Radiation Units and Measurements, 1993.
- [8] International Commission of Radiation Units and Measurements. ICRU report 62: prescribing, recording, and reporting photon beam therapy (supplement to ICRU report 50). Bethesda: International Commission on Radiation Units and Measurements, 1999.
- [9] Edge SB, Byrd DR, Compton CC, et al. AJCC cancer staging manual. 7th edition. New York: Springer. 2010.
- [10] Committee of Chinese Clinical Staging of Nasopharyngeal Carcinoma. Report on the revision of nasopharyngeal carcinoma '92 staging. *Chin J Radiat Oncol*, 2009,18:2–6. [in Chinese]
- [11] Sun Y, Ma J. Comment for the Chinese 2008 staging system for nasopharyngeal carcinoma. *Chin J Cancer*, 2009,28:1016–1021.
- [12] Liao XB, Mao YP, Liu LZ, et al. How does magnetic resonance imaging influence staging according to AJCC staging system for nasopharyngeal carcinoma compared with computed tomography? *Int J Radiat Oncol Biol Phys*, 2008,72:1368–1377.
- [13] Chong VF, Mukherji SK, Ng SH, et al. Nasopharyngeal carcinoma: review of how imaging affects staging. *J Comput Assist Tomogr*, 1999,23:984–993.
- [14] Heng DM, Wee J, Fong KW, et al. Prognostic factors in 677 patients in Singapore with nondisseminated nasopharyngeal carcinoma. *Cancer*, 1999,86:1912–1920.
- [15] Cooper J, Fleming ID, Henson DE. AJCC cancer staging manual. 6th edition. Philadelphia: JB Lippincott. 2002.
- [16] Hsu WM, Wang AG. Nasopharyngeal carcinoma with orbital invasion. *Eye (Lond)*, 2004,18:833–838.
- [17] Liang SB, Sun Y, Liu LZ, et al. Extension of local disease in nasopharyngeal carcinoma detected by magnetic resonance imaging: improvement of clinical target volume delineation. *Int J Radiat Oncol Biol Phys*, 2009,75:742–750.
- [18] van den Brekel MW, Stel HV, Castelijns JA, et al. Cervical lymph node metastasis: assessment of radiologic criteria. *Radiology*, 1990,177:379–384.
- [19] Tang L, Li L, Mao Y, et al. Retropharyngeal lymph node metastasis in nasopharyngeal carcinoma detected by magnetic resonance imaging: prognostic value and staging categories. *Cancer*, 2008,113:347–354.
- [20] Gregoire V, Levendag P, Ang KK, et al. CT-based delineation of lymph node levels and related CTVs in the node-negative neck: DAHANCA, EORTC, GORTEC, NCIC, RTOG consensus guidelines. *Radiother Oncol*, 2003,69:227–236.
- [21] Gregoire V, Eisbruch A, Hamoir M, et al. Proposal for the delineation of the nodal CTV in the node-positive and the post-operative neck. *Radiother Oncol*, 2006,79:15–20.
- [22] Committee of Chinese Clinical Staging of Nasopharyngeal Carcinoma. 2010 Consensus Guidelines for intensity-modulated radiotherapy target volume and dosimetric planning in nasopharyngeal carcinoma. *Chin J Radiat Oncol*, 2011,20:267–269. [in Chinese]
- [23] Lee NY, Zhang Q, Pfister DG, et al. Addition of bevacizumab to standard chemoradiation for locoregionally advanced nasopharyngeal carcinoma (RTOG 0615): a phase 2 multi-institutional trial. *Lancet Oncol*, 2012,13:172–180.
- [24] Ng WT, Lee MC, Hung WM, et al. Clinical outcomes and patterns of failure after intensity-modulated radiotherapy for nasopharyngeal carcinoma. *Int J Radiat Oncol Biol Phys*, 2011,79:420–428.
- [25] Tang L, Mao Y, Liu L, et al. The volume to be irradiated during selective neck irradiation in nasopharyngeal carcinoma: analysis of the spread patterns in lymph nodes by magnetic resonance imaging. *Cancer*, 2009,115:680–688.
- [26] Gao Y, Zhu G, Lu J, et al. Is elective irradiation to the lower neck necessary for N0 nasopharyngeal carcinoma? *Int J Radiat Oncol Biol Phys*, 2010,77:1397–1402.
- [27] Dubrulle F, Souillard R, Hermans R. Extension patterns of nasopharyngeal carcinoma. *Eur Radiol*, 2007,17:2622–2630.
- [28] Tomita N, Fuwa N, Arijii Y, et al. Factors associated with nodal metastasis in nasopharyngeal cancer: an approach to reduce the radiation field in selected patients. *Br J Radiol*, 2011,84:265–270.
- [29] Liu LZ, Zhang GY, Xie CM, et al. Magnetic resonance imaging of retropharyngeal lymph node metastasis in nasopharyngeal carcinoma: patterns of spread. *Int J Radiat Oncol Biol Phys*, 2006,66:721–730.
- [30] Ou X, Shen C, Kong L, et al. Treatment outcome of nasopharyngeal carcinoma with retropharyngeal lymph nodes metastasis only and the feasibility of elective neck irradiation. *Oral Oncol*, 2012. [Epub ahead of print].