

NOTES

Ultraviolet Red Fluorescence of *Bacteroides melaninogenicus*

M. BERT MYERS, GEORGE CHERRY, BETTE B. BORNSIDE, AND GEORGE H. BORNSIDE

Department of Surgery, Louisiana State University School of Medicine, New Orleans, Louisiana 70112, and
Touro Research Institute, New Orleans, Louisiana 70115

Received for publication 5 February 1969

Under longwave ultraviolet light, *Bacteroides melaninogenicus* fluoresced vivid red on blood-agar plates as well as in chronic cutaneous ulcers and purulent drainage.

Brilliant red fluorescence, produced by *Bacteroides melaninogenicus*, was observed in colonies on blood-agar plates, in cutaneous ulcers, and on dressings from abdominal abscesses viewed under longwave ultraviolet light. Ward and associates (10) described the usefulness of longwave ultraviolet (Wood's) light in identifying fluorescein, the yellow fluorescent pigment of *Pseudomonas aeruginosa*, in burns. Since this was a simple and possibly useful test clinically, we began viewing open wounds in the dark under a Wood's light. Twenty-one chronic cutaneous ulcers, mostly of the stasis type, were studied; in seven of them the yellow fluorescent pseudomonal pigment was seen. However, in another eight of the ulcers, strikingly brilliant red hues were observed in the dark under the ultraviolet light; these colors were absent under normal illumination. The fluorescent pigment was most often seen in the border of the ulcers, but at times it covered the entire base and spread onto the surrounding uninjured skin. The color could easily be scraped from the wound and was also present in the drainage seen on the bandages (Fig. 1).

Although we suspected that the color might be of bacterial origin, routine hospital cultures failed to identify the agent. Specimens from five of the lesions were subsequently subjected to extensive aerobic and anaerobic bacteriological examination. The specimens harbored a mixed flora consisting of *B. melaninogenicus* and other *Bacteroides* species, *Staphylococcus aureus*, *Streptococcus pyogenes*, *Streptococcus faecalis*, *P. aeruginosa*, *Mima polymorpha*, *Proteus mirabilis*, *Proteus vulgaris*, *Proteus morganii*, and aerobic diphtheroids. We used 5% human blood in Brain Heart Infusion Agar. Anaerobic blood-agar plates were incubated at 37 C for 4 days in Brewer jars containing an atmosphere of 95%

H₂-5% CO₂. Red fluorescence was observed in mixed cultures growing anaerobically on blood-agar plates. Subcultures from such areas were streaked to blood-agar plates containing 4% agar to inhibit swarming by the *Proteus* species. The organism producing red fluorescence on blood-agar was isolated in pure culture from each of the lesions; it was found to be an obligately anaerobic, gram-negative coccobacillus which produced typical black colonies on blood-agar and was therefore identified as *B. melaninogenicus*. None of the other isolates produced red fluorescence.

The color was also seen on dressings from two patients with draining intra-abdominal abscesses. The first patient's infection followed resection of strangulated intestine. Cultures were not taken at the time the fluorescence was seen; subsequent dressings failed to show the color or to grow out any *Bacteroides*. The next patient had a resection of a right tubo-ovarian abscess, and at surgery the wound was drained. Specimens taken in the operating room revealed *Bacteroides* species and microaerophilic streptococci. The dressing was changed on the 6th day and exhibited areas of ultraviolet red fluorescence. Specimens cultured at that time revealed *B. melaninogenicus* in pure culture. Each patient recovered after a prolonged convalescence.

The brown-black pigment produced by *B. melaninogenicus* was thought to be melanin by early investigators, but was later demonstrated to be a hemein (ferriprotoporphyrin) derivative (8). Some of our strains produced a tan pigment on blood-agar; others produced the typical black pigmentation. When observed at intervals during 21 days of incubation, the tan progressed to brown, dark brown, and black, and the blood-agar became clear. When viewed under the

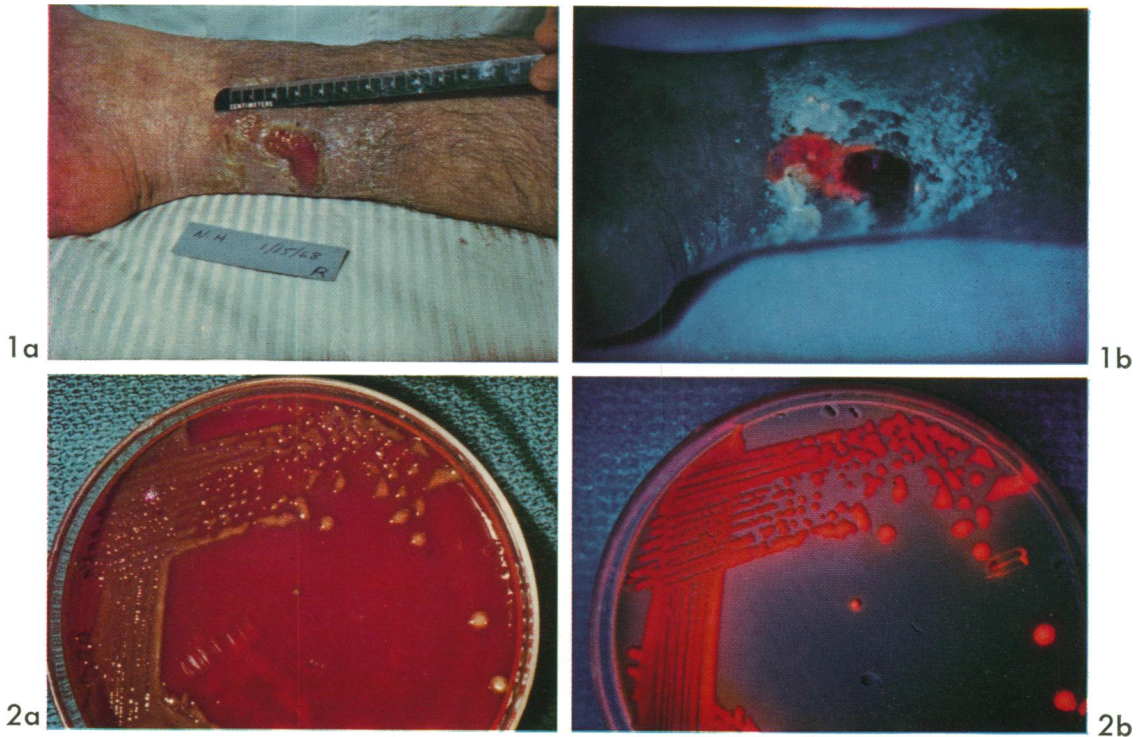


FIG. 1. (a) Stasis ulcer in a 36-year-old male (N.H.). (b) Under ultraviolet light, red fluorescence surrounds the ulcer and extends into an excoriated area.

FIG. 2. (a) *B. melaninogenicus* isolated from scrapings of fluorescent area in patient M.R. At 6 days colonies are tannish. (b) Under ultraviolet light, the colonies show the same brilliant fluorescence seen on the patient.

Wood's light, the tan and brown colonies fluoresced salmon, orange, or pink hues when first observed at 48 hr. Dark brown and black colonies fluoresced vivid scarlet red hues (Fig. 2). After longer periods of incubation, the colonies became characteristically jet black and no longer fluoresced. However, a small quantity of the black growth emulsified in methanol exhibited bright red fluorescence, suggesting that the black color was due to saturation of the red fluorescence. No red fluorescence occurred during growth of *B. melaninogenicus* on Brain Heart Infusion Agar in the absence of blood. The fluorescent red pigment was soluble in methanol, dilute hydrochloric acid, and pyridine. Spectrophotometric examination of methanol extracts of the red fluorescent pigment on soiled bandages, in mixed cultures from lesions, and in pure cultures of *B. melaninogenicus* showed a peak in the vicinity of 400 nm, which is characteristic of porphyrins (Fig. 3). The spectral absorption curve of a pyridine extract of a black pigmented culture of *B. melaninogenicus* resembled that of crystalline hemin (Fig. 4).

The role of *B. melaninogenicus* in chronic cutaneous ulcers is not known. The red fluorescence disappeared after treatment with topical chemo-

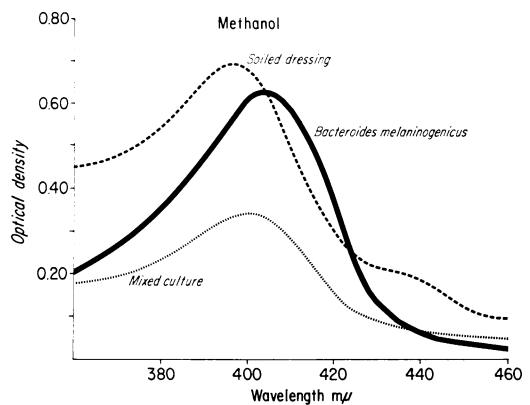


FIG. 3. Spectral absorption curves in ultraviolet region, showing peaks characteristic of porphyrins. Taken from right leg of chronic cutaneous ulcer patient N.H.

therapeutic agents, but healing was not accelerated. This was not surprising, because bacterial infection has never been shown to be etiological in stasis ulcers. Many investigators (1, 11; Finegold et al., *Bacteriol. Proc.*, p. 72, 1964) have

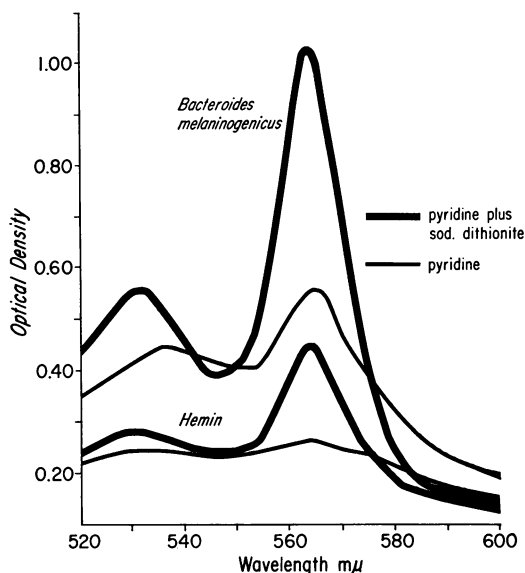


FIG. 4. Spectral absorption curves in visual region showing resemblance between pyridine extracts of black *B. melaninogenicus* and crystalline hemin.

isolated *B. melaninogenicus* from a variety of clinical infections and have demonstrated a synergistic role for it in experimental infections, but pure cultures of the organism have usually been found to be noninfective. Socransky and Gibbons (9) showed *B. melaninogenicus* to be essential for the infectivity of experimental mixed anaerobic infections, and suggested its importance in the etiology of bacteriologically non-specific infections which harbor a mixed anaerobic flora.

Red fluorescence has also been reported in a variety of cutaneous lesions. Sarkany and colleagues (6, 7) attributed the coral-red fluorescence of erythrasma to *Corynebacterium minutissimum*, an aerobic gram-positive diphtheroid which produced a diffusible, water-soluble, fluorescent pigment on agar media. Ronchese and colleagues (4) reported vivid reddish-orange fluorescence in necrotic ulcerated surfaces of squamous cell epitheliomas of the skin, in necrotic adenocarcinomas of the breast, and in a facial fibrosarcoma; *Streptomyces albus* was cultured from one of these cases and produced a faint but similar fluorescence on media containing blood.

Ghadially (3) observed red fluorescence in experimentally induced tumors which had ulcerated. Cornelius and Ludwig (2) demonstrated that the orange-red fluorescence of comedones was due to porphyrins produced by the anaerobic *Corynebacterium acnes* (*Propionibacterium acnes*). *B. melaninogenicus* is not a component of the normal bacterial flora of the skin but is commonly found in the human oral cavity and intestine and on the external genitalia (5). It is possible that the fluorescence seen in necrotic tumors was due to *B. melaninogenicus*.

Vivid red fluorescence appears to be specific for *B. melaninogenicus* and has not hitherto been reported for this species. The ability to reveal the presence of a single anaerobic bacterial species in lesions characterized by a mixed flora is a unique aid for the study of lesions in vivo. Red fluorescence has also been a practical laboratory aid for rapid, presumptive identification of *B. melaninogenicus*.

This work was supported by a grant from The John A. Hartford Foundation and by Public Health Service research grant AM 10727 from the National Institute of Arthritis and Metabolic Diseases.

LITERATURE CITED

1. Altmeier, W. A. 1942. The pathogenicity of bacteria of appendicitis peritonitis. An experimental study. *Surgery* 11:374-384.
2. Cornelius, C. E., III, and G. D. Ludwig. 1967. Red fluorescence of comedones: production of porphyrins by *Corynebacterium acnes*. *J. Invest. Dermatol.* 49:368-370.
3. Ghadially, F. N. 1960. Red fluorescence of experimentally induced and human tumours. *J. Pathol. Bacteriol.* 80:345-351.
4. Ronchese, F., B. S. Walker, and R. M. Young. 1954. The reddish-orange fluorescence of necrotic cancerous surfaces under the Wood light. *Arch. Dermatol. Syphilis.* 69:31-42.
5. Rosebury, T. 1962. *Microorganisms indigenous to man*. McGraw-Hill Book Co., New York.
6. Sarkany, I., D. Taplin, and H. Blank. 1961. Erythrasma—common bacterial infection of skin. *J. Amer. Med. Assoc.* 177:130-132.
7. Sarkany, I., D. Taplin, and H. Blank. 1962. Incidence and bacteriology of erythrasma. *Arch. Dermatol.* 85:578-582.
8. Schwabacher, H., D. R. Lucas, and C. Rimington. 1947. *Bacteroides melaninogenicus*—a misnomer. *J. Gen. Microbiol.* 1:109-120.
9. Socransky, S. S., and R. J. Gibbons. 1965. Required role of *Bacteroides melaninogenicus* in mixed anaerobic infections. *J. Infect. Dis.* 115:247-253.
10. Ward, C. G., J. G. Clarkson, D. Taplin, and H. C. Polk, Jr. 1967. Wood's light fluorescence and *Pseudomonas* burn wound infection. *J. Amer. Med. Ass.* 202:127-128.
11. Weiss, C. 1943. The pathogenicity of *Bacteroides melaninogenicus* and its importance in surgical infection. *Surgery* 13:683-691.