

# Closed Reductions and Percutaneous 'K' Wire Fixation for Adolescent Intercondylar Fractures of the Distal Humerus

JULFIQAR<sup>1</sup>, AJAY PANT<sup>2</sup>, N. HUDA<sup>3</sup>, WASIM AHMED<sup>4</sup>

## ABSTRACT

**Introduction:** Intercondylar (T-Condylar) fractures of the humerus are very rare in children. The usual mechanism of the injury which is involved is a fall on a flexed elbow. The treatment options vary, depending upon the degree of the displacement and the amount of comminution and; they may range from a simple application of traction to open reduction and internal fixation with plates and screws. Open reduction is associated with significant post-operative stiffness of the elbow and subsequent less than satisfactory functional results. In this publication, we are presenting our experience of treating seven adolescent T-Condylar fractures of the distal humerus with closed reductions and internal fixations with the percutaneous Kirchner ('K') wire.

**Method:** Seven patients (M:F-6:1) with an average age of 14 (range 12–16) years were treated by closed reduction and internal fixation with a 2.0 mm 'K' wire fixation under an image intensifier. Following the surgery, all the elbows were immobilised in plaster of Paris (POP) splints for three weeks. At three weeks

after the surgery, the pop splints were removed and gentle elbow exercises were started. Five weeks after the surgery, the 'K' wires were removed, based on the radiological evidence of a bridging callus formation.

**Results:** Six patients (85%) out of seven showed satisfactory functional results on the Mayo Elbow Performance Score (MEPS), with a good range of motion at the elbow joint. Three (42%) patients had mild elbow stiffness, which resolved on subsequent treatment, while one (14%) had a mild pin tract infection, who was managed conservatively. There was one patient (14%) who was lost to follow-up, who ultimately had a painful and a stiff elbow. The remaining six patients were able to return to the pre-morbid state.

**Conclusion:** We recommend closed reduction and percutaneous 'K' wire fixation for adolescent T-Condylar fractures of the humerus as an easy and inexpensive procedure with satisfactory functional results.

**Key words:** T-Condylar fracture, Distal humerus, Adolescent, Closed reduction, Percutaneous fixation

## INTRODUCTION

The T-condylar fracture of the distal humerus is a very rare fracture in the adolescent age group, which accounts for less than 1% of the elbow fractures [1]. A paediatric T-Condylar fracture can sometimes be confused with an extension type supracondylar fracture of the humerus; therefore, good quality radiographs are necessary for making a proper diagnosis and for the treatment. The key to the differentiation between the two is a fracture line which extends into the intercondylar region of the distal humerus. The goal behind the treatment of such fractures is restoration of the articular anatomy of the distal end of the humerus. The treatment depends upon the amount of displacement and the extent of comminution of the articular surface. An open reduction is required when there is a fracture displacement and a marked articular displacement. A closed reduction and a percutaneous Kirchner wire fixation are thought to be sufficient when there is no or minimal displacement of the Condylar region and when the articular surfaces are fairly maintained. A rigid internal fixation with an early mobilization is recommended for the displaced paediatric intercondylar fractures of the humerus, as in adults. Our study presents the experience of closed reductions and percutaneous Kirchner (K) wire fixations, even in displaced intercondylar fractures of the distal humerus in children. As was highlighted by Kundel et al., the overall rate of the complications; like iatrogenic nerve palsies, heterotopic ossifications, deep infections, fixation failures which lead to nonunions/malunions, etc, following open reductions and internal fixations of the intercondylar fractures of the distal humerus can be as high as 22%. No such high rates of the same types of complications have been described in the clinical series in which similar fractures were treated by closed reductions and internal fixations with percutaneous 'K' wires.

## MATERIAL AND METHODS

Between June 2008 to December 2011, seven patients (6 males and 1 female) with an average age of 14 years (range 12–16 years) who had intercondylar fracture of the distal humerus were treated at a tertiary health care centre. An institutional ethical committee clearance was obtained before actually starting the study. Patients were recruited in the study only after obtaining informed written consents from them. All the fractures presented within three (range 0–3 days) days of sustaining the injury. After the relevant history was taken, a thorough clinical examination was done, with particular emphasis on the distal neurovascular status. The fractures were the result of falls from a height over the ground, with the elbows flexed and the tips of the olecranon directly coming in contact with the ground. A non-dominant extremity was involved in six (85%) cases and a dominant extremity was injured in one (15%) patient. All the patients were investigated by using plain X-rays of the injured elbows, which included the antero-posterior (AP) and the lateral views [Table/Fig-1a and 1b]. A CT scan was not required in any case in the present study, due to the clear interpretation of the intercondylar fractures on the plain radiographs. There was a significant intra-articular gap in six cases; one patient had a minimally displaced T-Condylar fracture. The column integrity was assessed before labeling a fracture as an intercondylar fracture of the distal humerus.

All the patients were operated either under general or regional anaesthesia, depending upon the anaesthetist's choice. The local part preparation was done just prior to the operation. All the patients were given an injectable broad spectrum antibiotic one hour prior to the surgery. Intraoperatively, no antibiotic was given, because the duration of the procedure was not more than

one hour in any case. After adequate anaesthesia was given, the patients were mounted on plain orthopaedic tables in the supine position. No tourniquet was applied in any case. With the patients lying supine on plain operation tables, the limbs which had to be operated were supported on radiolucent side arm rests with a 90 degree abduction at the shoulder joints and flexion at the elbows.

Thereafter, a closed reduction of the intercondylar parts of the fractures was obtained, keeping the elbows of the patients flexed and held with bone holding clamps; the reduction was checked under a C-arm. After the closed reduction, 2.0 mm Kirchner wires were passed horizontally, parallel to the elbow joints, starting from the lateral to the medial epicondyles, thereby converting the intercondylar fractures into two part supracondylar fractures. Two or more 2.0 mm Kirchner wires were passed through the medial and the lateral epicondyles of the humeri into the proximal fragment, to achieve the remaining fixation. While passing the wires from the medial epicondyles, the ulnar nerve was secured by identifying it through stab incision over the medial epicondyles. The final positions of the fractures after the closed reduction and the percutaneous 'K' wire fixation were checked under an image intensifier by using the standard radiological criteria. The average operation time was one hour. In all the cases, the 'K' wires were left protruding outside the skin at approximately 2 cm. The wires were bent outside. The 'K' wires crossed the opposite cortex and they were placed in a criss cross manner. Both a hand drill as well an electric drill were used to insert the 'K' wires. Following the surgeries, the elbows were immobilized in above elbow plaster of Paris (pop) splints.

All the patients were discharged from the hospital after the first Check X-ray was taken on the second day after the surgery. Thereafter, the patients were called back at 1 week after the surgery for the first follow-up, to check the maintenance of the reduction by taking check X-rays of the operated elbows, which included the antero-posterior and the lateral views. The second follow-up was done at three weeks after the surgery and on the radiological attempts at callus

formations [Table/Fig-2a and 2b], the pop splints were removed and cuff and collar slings were given to all the patients alongwith instructions to do gentle elbow exercises. The third follow up was done 5 weeks after the surgery and on a radiological evidence of bridging callus formations, the 'K' wires were removed [Table/Fig-3a and 3b].

## RESULTS

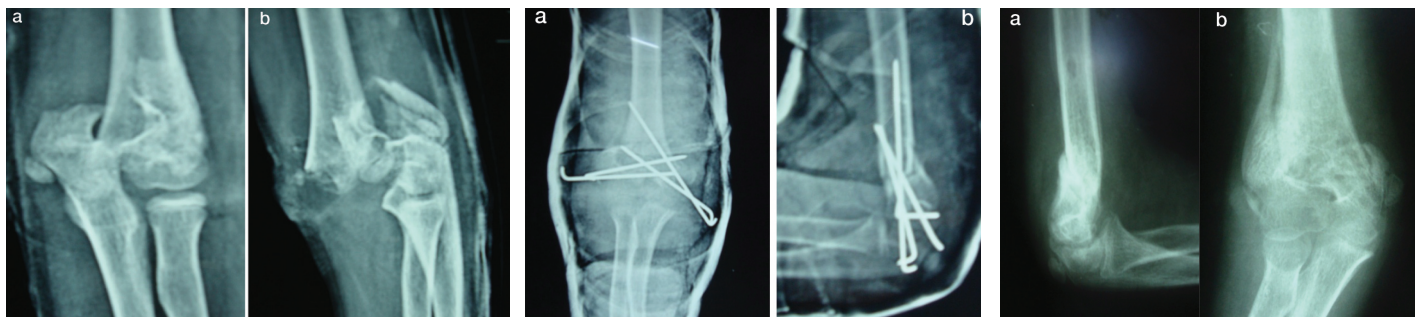
**Union of the fracture:** It is defined as a radiological evidence of the bridging callus formation, which was achieved in all of our patients, with the average time for the union being 6 weeks (range 5–7 weeks). Mild elbow stiffness was seen in three (42%) patients at 5 weeks of follow-up, which was dealt with by planning vigorous physiotherapy schedules after the 'K' wire removal. A pin tract infection was seen in one (14%) patient, who was treated successfully conservatively. A consolidated fracture union was seen at an average interval of 3 months after the surgery [Table/Fig-4a and 4b]. At the end of the final follow-up, at 2 years after the surgery, all the patients had a satisfactory range of motion at the elbow joint [Table/Fig-5a and 5b] and they were able to return to their pre-morbid states. The average Mayo Elbow Performance Score (MEPS) for six patients was 85, which was rated as good; except in one (14%) patient who was lost to follow-up initially, who returned with a painful and a stiff elbow with an MEPS of 40 only [Table/Fig-6].

There were no growth disturbances. There was no functional disability [Table/Fig-7].

There were no complications like an early fixation failure, an iatrogenic neurovascular injury, growth disturbances and instability at the elbow joint.

## DISCUSSION

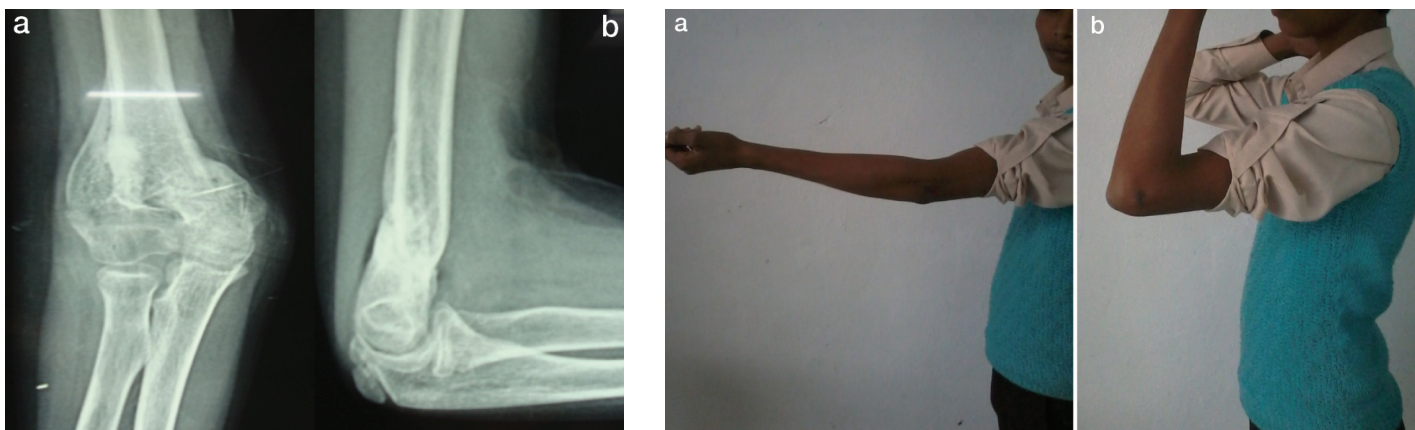
No large report series are available for the exact treatment plans and the outcomes of paediatric T-condylar fractures of distal humerus.



[Table/Fig-1a & b]: Anteroposterior and lateral radiographs of elbow showing intercondylar fracture of the humerus

[Table/Fig-2a & b]: Postoperative anteroposterior and lateral radiographs showing fixation with 'K' wires (3 weeks post-op.), showing radiological callus formation

[Table/Fig-3a & b]: Anteroposterior radiograph of the elbow showing union of the fracture (5 weeks post-op.), showing bridging callus



[Table/Fig-4a & b]: Anteroposterior and lateral radiograph of elbow 3 months after surgery showing consolidated union.

[Table/Fig-5a & b]: Clinical photographs of the patient showing range of motion at the elbow joint.

Serial no. of patient/elbow score pint	1	2	3	4	5	6	7
Pain	30	45	30	30	45	30	15
Motion	20	15	15	20	15	20	05
Stability	10	10	10	10	10	10	10
Function of elbow	25	20	25	25	20	25	10
Total score of individual patient	85	90	80	85	90	85	40

**[Table/Fig-6]:** Showing MEP score of individual patients

Complication	No. of patients	%
Nonunion	0	0
Malunion	0	0
Deep infection/draining sinus	0	
Growth disturbance	0	0
Elbow instability	0	0
Nerve injury	0	0
Early Fixation failure	0	0
Mild elbow stiffness	3	42
Severe elbow stiffness	1	14
Heterotopic ossification	0	0

**[Table/Fig-7]:** Showing various complications in the patients

The ideal treatment for a paediatric T- Condylar fracture of the humerus is open reduction and internal fixation with plates and screws, to allow an early mobilization of elbow, to prevent elbow stiffness. However, the treatment options may vary, depending upon the amount of displacement of the Condylar pillars, the extent of the comminution and the integrity of the articular surfaces. Most of the surgeons agree that when the integrity of the columns is maintained, thus allowing a stable fracture pattern and when the articular surface is undisturbed, then such paediatric intercondylar fractures can be simply treated conservatively with excellent results [2]. The difference of opinion mainly lies in the management of the increasingly displaced and the comminuted fractures [3]. Some authors say that even the displaced paediatric intercondylar fractures can be treated by closed reductions and percutaneous pinning, with satisfactory functional results [3,4]. Others say that the ideal treatment for a displaced intercondylar fracture is open surgical reduction and internal fixation with reconstruction plates, so as to allow an early elbow mobilization, to prevent elbow stiffness, as has been mentioned earlier [5-7]. But at the same time, an open surgical reduction leads to more injury to the surrounding soft tissues and it increases the risk of elbow stiffness [8-10]. In our study, the union rate was 100% and there was no need of carrying out a secondary surgical procedure for a failed implant/or to remove the 'K' wires from

the elbow. In the study which was conducted by Kundel et al., who treated distal humeral intercondylar fractures by open reductions and internal fixations by using plates; only 52% cases were found to have good to excellent results. Kundel et al., observed iatrogenic nerve injuries in 16% cases, heterotopic bone formations in 49% cases, deep infections which included draining sinuses in 8% cases, and fixation failures which led to revision surgeries in 5% cases. In our study, there were no such complications and 85% of the patients had good functional results. The technique that we have chose was fairly simple and it can be done by the most average orthopaedic surgeon. With a closed reduction and a percutaneous pinning, there is no iatrogenic trauma to the surrounding soft tissues, particularly the extensor mechanism at the elbow joint, which could lead to subsequent elbow stiffness. There is no complication which is related to bulky hardware like impingement and pain in the soft tissues and skin necrosis. There is no need of carrying out another surgical procedure to remove the pins, because these can be removed very easily as an outdoor procedure, which decreases the risk of surgical and anaesthetic risks to the patient and it is also very cost effective. Moreover, the surgical time is very less as compared to that of the open surgical reduction of the fracture. The major limitation of the present study was that it was uncontrolled in nature and that it involved a smaller number of patients. The use of physician based assessment criteria was another limitation of the present study.

## CONCLUSION

The present study concludes that even displaced paediatric intercondylar fractures of the distal humerus can be satisfactorily treated with closed reductions and percutaneous pinning.

## REFERENCES

- [1] Kasser JR, Beaty JH. Supracondylar fractures of the distal humerus. In: Rockwood and Wilkins' fractures in Children. 5th, Beaty JH, Kasser JR.(Eds), Lippincott Williams and Wilkins, Philadelphia 2001 ;577.
- [2] Mohamed Faouzi HMDI, Issam ALOUI, Makrem ZRIG, Semir NOUIRA. *Turkish Journal of Trauma and Emergency Surgery*. 2009;15(5): 518-19.
- [3] Lee WS, Chung WY, Kim WS, et al. Intercondylar fracture of distal humerus in children. *J Korean fract Soc*. 2004 Oct; 17(4):380-83.
- [4] Anastasios D. Kanellopoulos, Christos K Yiannakopoulos. Closed reduction and percutaneous stabilization of pediatric T Condylar fractures of the humerus. *J Pediatr Orthop*. 2004; 24:13-16.
- [5] Jarvis JG, D'Astous JL. The pediatric T-supracondylar fracture. *J Pediatr Orthop*. 1984; 4:697-99.
- [6] Papavasiliou VA, Beslikas TA. T-Condylar fractures of the distal humeral condyles during childhood: an analysis of six cases. *J Pediatr Orthop*. 1986; 6:302-05.
- [7] Re PR, Waters PM, Hresko T.T- Condylar fractures of the distal humerus in children and adolescents. *J Pediatr Orthop*. 1999; 19: 313-18.
- [8] Gupta R. intercondylar fractures of distal humerus in adults. *Injury* 1996; 27:569-72.
- [9] Kundel k, Braun W, Wieberneit J et al. Intraarticular distal humerus fractures. Factors affecting functional outcomes. *Clin Orthop*. 1996; 332:200-08.
- [10] Toniolo MR., Wilkins KE. T-Condylar fractures. In Rockwood CA, Wilkins KE, Beaty JH. Fractures in children. Philadelphia: Lippincott-Raven, 1996; 830-32.

### PARTICULARS OF CONTRIBUTORS:

1. Assistant Professor, Department of Orthopaedics, Teerthanker Mahaveer Medical College & Research Centre (TMMCRC); Moradabad, UP, India.
2. Professor and Head Department of Orthopaedics, Teerthanker Mahaveer Medical College & Research Centre (TMMCRC); Moradabad, UP, India.
3. Associate Professor, Department of Orthopaedics, Teerthanker Mahaveer Medical College & Research Centre (TMMCRC); Moradabad, UP, India.
4. Assistant Professor, Department of Orthopaedics, Teerthanker Mahaveer Medical College & Research Centre (TMMCRC); Moradabad, UP, India.

### NAME, ADDRESS, E-MAIL ID OF THE CORRESPONDING AUTHOR:

Dr. Julfiqar,  
Assistant Professor, Department of Orthopaedics,  
Teerthanker Mahaveer Medical College & Research Centre (TMMCRC); Moradabad, UP, India.  
Phone: +91-8979949300, E-mail: drzulfiqar1983@rediffmail.com

FINANCIAL OR OTHER COMPETING INTERESTS: None.

Date of Submission: **Jan 19, 2013**  
Date of Peer Review: **Feb 02, 2013**  
Date of Acceptance: **Apr 11, 2013**  
Date of Publishing: **Aug 01, 2013**