

Jie Zhao
Tiesheng Hou
Xinwei Wang
Shengzhong Ma

Posterior lumbar interbody fusion using one diagonal fusion cage with transpedicular screw/rod fixation

Received: 15 December 2000
Revised: 9 November 2001
Accepted: 13 November 2001
Published online: 11 January 2003
© Springer-Verlag 2003

Abstract Posterior lumbar interbody fusion (PLIF) using threaded cages has gained wide popularity for lumbosacral spinal disease. Our biomechanical tests showed that PLIF using a single diagonal cage with unilateral facetectomy does add a little to spinal stability and provides equal or even higher postoperative stability than PLIF using two posterior cages with bilateral facetectomy. Studies also demonstrated that cages placed using a posterior approach did not cause the same increase in spinal stiffness seen with pedicle screw instrumentation, and we concluded that cages should not be used posteriorly without other forms of fixation. On the other hand, placement of two cages using a posterior approach does have the disadvantage of risk to the bilateral nerve roots. We therefore performed a prospective study to determine whether PLIF can be accomplished by utilizing a single diagonal fusion cage with the application of supplemental transpedicular screw/rod instrumentation. Twenty-seven patients underwent a PLIF using one single fusion cage (BAK, Sulzer Spine-Tech, Minneapolis, MN, USA) inserted posterolaterally and oriented anteromedially on the symptomatic side with unilateral facetectomy and at the same level supplemental fixation with a transpedicular screw/rod system. The internal fixation systems included 12 SOCON spinal systems (Aesculap AG, Germany) and 15 TSRH spinal systems (Medtronic Sofamor Danek, USA). The inclusion criteria were grade 1 to 2 lumbar isthmic spondylolisthesis, lumbar degenerative spondylolisthesis, and recurrent lum-

bar disc herniations with instability. Patients had at least 1 year of low back pain and/or unilateral sciatica and a severely restricted functional ability in individuals aged 28–55 years. Patients with more than grade 2 spondylolisthesis or adjacent-level degeneration were excluded from the study. Patients were clinically assessed prior to surgery by an independent assessor; they were then reassessed at 1, 3, 6, 12, 18, and 24 months postoperatively by the same assessor and put into four categories: excellent, good, fair, and poor. Operative time, blood loss, hospital expense, and complications were also recorded. All patients achieved successful radiographic fusion at 2 years, and this was achieved at 1 year in 25 out of 27 patients. At 2 years, clinical results were excellent in 15 patients, good in 10, fair in 1, and poor in 1. Regarding complications, one patient had a postoperative motor and sensory deficit of the nerve root. Reoperation was required in one patient due to migration of pedicle screws. No implant fractures or deformities occurred in any of the patients. PLIF using diagonal insertion of a single threaded cage with supplemental transpedicular screw/rod instrumentation enables sufficient decompression and solid interbody fusion to be achieved with minimal invasion of the posterior spinal elements. It is a clinically safer, easier, and more economical means of accomplishing PLIF.

Keywords Lumbar · Fusion cage · Implant · Transpedicular screw · Interbody

J. Zhao · T. Hou · S. Ma
Orthopedic Surgery Department,
Changhai Hospital, 174 Changhai Road,
Shanghai 200433, P.R. China

X. Wang (✉)
Orthopedic Department,
Changzheng Hospital, 415 Feng yang
Road, Shanghai, 200003, P.R. China
e-mail: orth.wang@263.net,
Tel.: 86-21-25071456,
Fax: 86-21-25070583

Introduction

Posterior lumbar interbody fusion (PLIF), introduced by Dr. Ralph Cloward in the 1940s [2], laid the foundations for future biomechanically ideal fusion. A successful PLIF has the advantages of restoring the disc height, immobilizing the unstable degenerated intervertebral disc, decompressing the dural sac and the nerve roots, and restoring load-bearing to anterior structures [1]. Numerous techniques have been described, including use of autologous iliac crest bone graft, allograft bone, dowel-shaped graft, key stone graft, tricortical graft, and bone chips. Threaded-cage PLIF has the advantages of minimizing complications of graft resorption and disc space collapse and has therefore been recommended [5, 7].

The PLIF method that was introduced involving implantation of two threaded cages [4, 7] lacked supplemental internal fixation with a pedicle screw system. Insertion of one anterior or lateral cage has been successful on a limited basis. It is challenging to insert two cages of appropriate size posteriorly during the surgical procedure without extensive laminectomy and bilateral facetectomy. From a mechanical point of view, posterior element deficiencies adversely affect the stiffness of intervertebral fusion cages immediately after insertion, as these structures provide resistance to flexion and torsion. In addition, there is the obvious potential for neurological damage during surgery [8].

The results of our biomechanical tests show that the posterolateral single threaded cage PLIF with unilateral facetectomy led to significantly higher postoperative stiffness than PLIF using two cages with bilateral facetectomy in pure compression, left bending, and left and right torsion. Flexion and extension loading modes also showed stiffer values in the single-cage group than in the two-cage group, but this was not statistically significant [9]. We therefore decided to perform PLIF utilizing a single diagonal cage with the application of supplementary transpedicular screw/rod instrumentation while maintaining minimal invasion of the posterior elements. This study concerns the first 27 patients who have reached the 2-year follow-up interval.

Patients and methods

From July 1997 to August 1998, 27 patients with symptomatic lumbar disease were treated by PLIF using single BAK (Bagby and Kuslich) and additional pedicle screw internal fixation. Nine patients with grade 1 to 2 lumbar isthmic spondylolisthesis, 11 with lumbar degenerative spondylolisthesis, and 7 with recurrent lumbar disc herniations with instability were treated prospectively. The internal fixation systems included 12 SOCON spinal systems (Aesculap AG, Germany) and 15 TSRH spinal systems (Medtronic Sofamor Danek, USA). There were 16 men and 11 women. The mean age was 46 years (range, 28–55 years). The minimum follow-up for review of 24 months.

Table 1 Data on 27 patients

	IS	DS	RDH
Patients (<i>n</i>)	9	11	7
Average age (years)	43±8	50±3	47±5
Sex			
Male (<i>n</i>)	7	2	2
Female (<i>n</i>)	2	9	5
Average blood loss (ml)	711±105	891±274	1000±327
Average surgery time (min)	201±31	225±72	225±56
Average hospital stay (days)	14±2	12±3	13±2
Average hospital costs (US dollars)	4975±318	4872±459	4872±459

IS, isthmic spondylolisthesis; DS, degenerative spondylolisthesis; RDH, recurrent disc herniation.

Table 2 Pre- and postoperative data on 27 patients

	Preoperative	Postoperative
Symptoms		
Low back pain (<i>n</i>)	27	8
Intermittent claudication (<i>n</i>)	6	2
Leg pain (<i>n</i>)	12	2
Fitness for work		
Disability (<i>n</i>)	7	0
Partial disability (<i>n</i>)	15	2
Restricted duty (<i>n</i>)	5	10
Return to previous work (<i>n</i>)	0	15
Clinical results		
Poor (<i>n</i>)	16	0
Fair (<i>n</i>)	10	2
Good (<i>n</i>)	1	10
Excellent (<i>n</i>)	0	15

Inclusion criteria

The inclusion criteria were grade 1 to 2 lumbar isthmic spondylolisthesis, lumbar degenerative spondylolisthesis, and recurrent lumbar disc herniations with instability. Patients had at least 1 year of low back pain and/or unilateral sciatica and a severely restricted functional ability in individuals under 60 years of age. The preoperative data on all 27 patients are shown in Table 1 and Table 2.

Exclusion criteria

The exclusion criteria included active infection, osteopenia, symptomatic vascular disease, active malignancy, gross obesity, greater than grade 2 spondylolisthesis, adjacent level degeneration, and pregnancy.

Surgical technique

The patient was placed in the kneeling/sitting position on an Andrew's frame under general anesthesia. The surgical procedure is illustrated in Fig. 1. For patients with stenosis, unilateral laminectomy

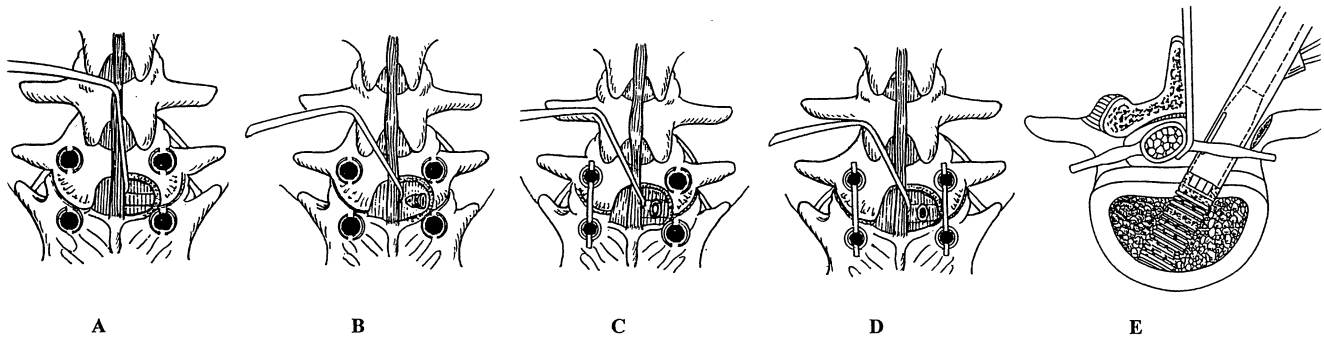


Fig. 1A–E Demonstration of the surgical procedure of posterior lumbar interbody fusion (PLIF) using one diagonal fusion cage with transpedicular screw fixation. **A** An appropriate hemi-laminectomy and unilateral partial facetectomy of the symptomatic side was performed, and pedicle screws were inserted bilaterally. **B** The disc space was then cleaned and the distraction plug gradually inserted until the desired annular tension was achieved. **C** A single rod was applied to the contralateral side of the distraction plug, and locking nuts were tightened to maintain distraction. **D** After bone grafting, the BAK was inserted diagonally; finally, the second rod was put in place, and all the nuts were tightened. **E** Cross-section of extra bone graft previous to the BAK (Bagby and Kuslich) insertion

tomy and facetectomy of the symptomatic side was able to achieve adequate decompression of the stenosis. For patients with spondylolisthesis, sequential distraction until the desired annular tensions were achieved was able to reduce slippage to some extent. Before cage insertion, the bone from laminectomy was grafted into the prepared disc space, while the iliac bone graft was placed in the cage. We believe that the bone outside the cage has greater fusion potential than the bone inside.

X-rays or fluoroscopic images were taken in both the anteroposterior and lateral planes. The size of the implanted cage was determined by both the templates for X-ray, computed tomography (CT) or magnetic resonance imaging (MRI) scans and the extent of distraction during surgery.

Patients' clinical symptoms were assessed prior to surgery by an independent assessor (the third author) and reassessed at 1, 3, 6, 12, 18, and 24 months postoperatively by the same assessor; patients were put into four categories: excellent, good, fair, and poor. Clinical results were rated as excellent if the patient was pain-free and had returned to work at their previous occupation. If the patient continued to have mild backache requiring non-narcotic medication only and had returned to full-time work, the results were rated as good. A fair result indicated that the patient's continuing back pain prevented him or her returning to work or narcotic medication was required. A poor result indicated that the patient's condition was worse than it was preoperatively or required additional surgery at the same level [10]. Operative time, blood loss, and hospital expense were also recorded (Table 1).

Fusion status was determined from the anteroposterior, lateral, and flexion–extension radiographs. All radiographs were reviewed by the blinded assessor (the fourth author), who determined whether there was radiographic fusion or nonunion. For a fusion to be deemed solid, the anteroposterior or lateral radiograph had to show mature bony trabeculae bridging the fusion area. Flexion–extension films were considered to show fusion with less than 2° of motion on the lateral film. Fusion results were purely determined by radiographic means [3].

Results

All patients achieved successful radiographic fusion at 2 years, and 25 out of 27 patients at 1 year (Fig. 2). Clinical results at 2 years were excellent in 15 patients, good in 10, fair in 1, and poor in 1 (reoperation). Ten patients were able to return to work, but not to their previous occupation. Fifteen patients worked in their previous occupation. From a functional point of view, 12 patients had a mild level of low back pain, intermittent claudication, or sciatica, while 15 patients had no pain (Table 2). Regarding complications, one patient had a postoperative temporary motor and sensory deficit of the adjacent nerve root. Reoperation was required in one patient due to migration of pedicle screws. No implant fractures or deformities occurred in any of the patients.

Discussion

PLIF using threaded cages has gained wide popularity for lumbosacral spinal disease. Although many studies have concluded that threaded cages provide the same amount of stabilization as a PLIF bone graft with supplementary transpedicular screws/rod constructs, controversy still exists [6, 9]. The threaded fusion cages were originally designed to be placed anteriorly; they have also been used from a posterior lumbar approach, which often involves removal of much of the facet joints to allow safe implantation. Our biomechanical test [9] showed that PLIF using a single diagonal cage with unilateral facetectomy does add a little to spinal stability, but it provides equal or even higher postoperative stability than PLIF using two posterior cages with bilateral facetectomy. Tencer et al. [8] also found that posterior placement of an insert can compromise the facet and lamina structures by reducing torsion stiffness, which is further reduced when two inserts are used. They believe that these data can be interpreted as indicating that it may be better to use a single insert rather than two.

Oxland et al. [6] demonstrated that cages placed from both anterior and posterior directions provided good stability in flexion, but not in extension. Supplementary pos-

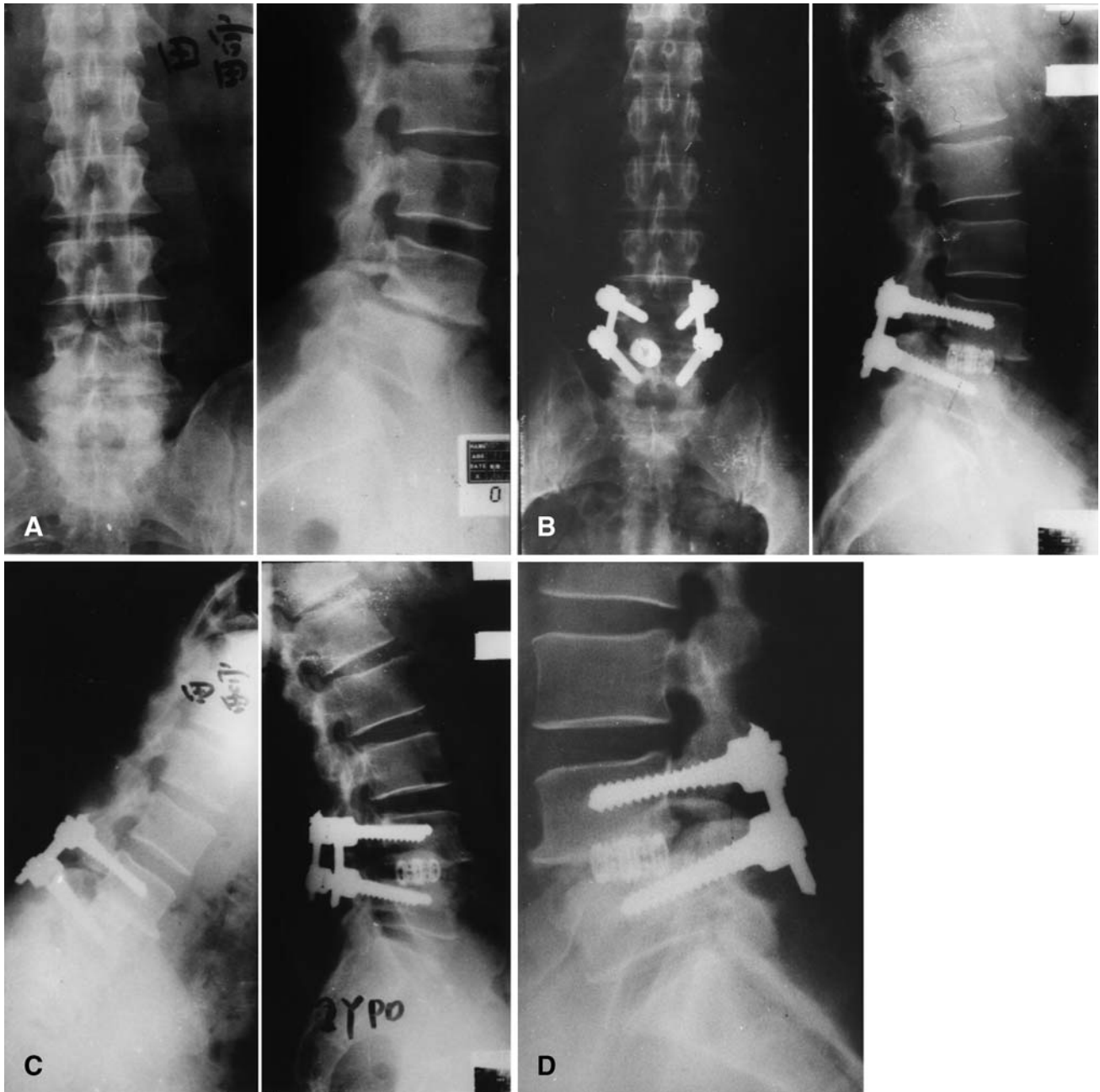

Fig. 2 A A 41-year-old man with symptomatic grade 1 isthmic spondylolisthesis. B He was treated with posterior lumbar interbody fusion (PLIF) using one diagonal BAK cage with unilateral facetectomy and with transpedicular screw fixation. C The result at 2-year follow-up. D The lateral radiograph at 2-year follow-up showed bony trabeculae bridging the fusion level

terior fixation with pedicle or translaminar screws substantially improves stability in all directions. On the other hand, placement of two cages from a posterior approach does have the disadvantage of risk to the bilateral nerve

roots [4, 7]. Since posteriorly placed interbody fusion cages offer no significant increase in stiffness, their use as a stand-alone device may not be appropriate.

This method has some obvious advantages. It is an easier technique compared to routine two-cage PLIF. In treatment of patients with unilateral sciatica, the cage can be placed from the symptomatic side so as to avoid retraction of the nerve root and dural sac of the asymptomatic side. Since the application of the supplementary instrumentation can provide adequate postoperative stability immediately, an undersized cage can be used without worrying about its displacement. Regarding surgical procedure, sin-

gle-cage PLIF also has the advantages of less blood loss, shorter surgery time, and a shorter hospital stay.

Indications for PLIF using single threaded fusion cages with supplementary instrumentation in lumbar spine have not yet been fully established or proved by long-term outcome studies. They might include degenerative or less than grade 2 isthmic spondylolisthesis after completion of a decompressive laminectomy, iatrogenic instability after previous decompressive procedures, and certain cases of

retrolisthetic instability with disc space collapse and restoration of alignment.

We conclude that PLIF using diagonal insertion of a single threaded cage with supplementary transpedicular screw/rod instrumentation enables sufficient decompression and solid interbody fusion to be achieved, while maintaining minimal invasion to the posterior elements. It is a clinically safer, easier, and more economical way of achieving PLIF.

References

1. Bagby GW (1988) Arthrodesis by the distraction-compression method using a stainless steel implant. *Orthopedics* 11:931–934
2. Cloward RB (1953) The treatment of ruptured lumbar intervertebral discs by vertebral body fusion. Indications, operation technique, after care. *J Neurosurg* 10:154–168
3. Herkowitz HN, Kurz LT (1991) Degenerative lumbar spondylolisthesis with spinal stenosis. *J Bone Joint Surg [Am]* 73:802–808
4. Kuslich SD, Danielson G, Dowdle JD, Sherman J, Fredrickson B, Yuan H, Griffith SL (2000) Four-year follow-up results of lumbar spine arthrodesis using the Bagby and Kuslich lumbar fusion cage. *Spine* 25:2656–2662
5. Kuslich SD, Ulstrom CL, Griffith SL, Ahern JW, Dowdle JD (1998) The Bagby and Kuslich method of lumbar interbody fusion. History, techniques, and 2-year follow up results of a United States prospective, multicenter trial. *Spine* 23:1267–1278
6. Oxland TR, Lund T (2000) Biomechanics of stand-alone cages and cages in combination with posterior fixation: a literature review. *Eur Spine J Suppl*:S95–101
7. Ray CD (1997) Threaded titanium cages for lumbar interbody fusions. *Spine* 22:667–679, discussion 679–680
8. Tencer AF, Hampton D, Eddy S (1995) Biomechanical properties of threaded inserts for lumbar interbody spinal fusion. *Spine* 20:2408–2414
9. Zhao J, Hai Y, Ordway NR (2000) Posterior lumbar interbody fusion using posterolateral placement of a single cylindrical threaded cage. *Spine* 25:425–433
10. Zdeblick TA (1993) A prospective, randomized study of lumbar fusion: preliminary results. *Spine* 18:983–991