

TOTAL KNEE REPLACEMENT: SHOULD IT BE CEMENTED OR HYBRID?

Cecil H. Rorabeck, MD

OBJECTIVE: To compare the complication rates associated with total knee arthroplasty against the types of fixation (hybrid or cemented), using a single total knee design (the anatomic modular knee [AMK] prosthesis).

DESIGN: A prospective, nonrandomized, controlled trial.

SETTING: University Hospital in London, Ont., a tertiary care teaching centre.

PATIENTS: Two groups made up of 484 knees in 395 patients (89 bilateral).

INTERVENTIONS: In 260 knees a hybrid configuration (cemented tibia and noncemented femur) was used (group 1). In 224 knees the femoral *and* tibial components were cemented (group 2). All patellae were cemented in both groups.

MAIN OUTCOME MEASURES: Clinical results were assessed by The Knee Society Clinical Rating Scores at 3 months, 6 months and yearly intervals. Radiographic results were determined by 3-foot standing radiographs and at each follow-up visit standing knee radiographs, lateral and skyline views. Radiographs were analysed for alignment, presence or absence of radiolucent lines or changes in the position of the implant. All reoperations and nonoperative complications were recorded.

RESULTS: At an average follow-up of 4.8 years, 8 knees (1.6%) required reoperation. An analysis of the complications leading to reoperation demonstrated no difference between the 2 groups.

CONCLUSIONS: There was no difference in outcome whether the femoral component was cemented or not. Medium-term results of the AMK are excellent with a very low reoperation rate.

OBJECTIF : Comparer les taux de complications associés à une arthroplastie totale du genou au type de fixation (hybride ou cimentée) en utilisant un seul concept du genou total (la prothèse du genou modulaire anatomique [GMA]).

CONCEPTION : Étude contrôlée prospective non randomisée.

CONTEXTE : Hôpital universitaire de London (Ontario), centre d'enseignement de soins tertiaires.

PATIENTS : Deux groupes constitués de 484 genoux chez 395 patients (deux côtés dans 89 cas).

INTERVENTIONS : Dans 260 genoux, on a utilisé une configuration hybride (tibia cimenté et fémur non cimenté) (groupe 1). Dans les 224 autres cas, on a cimenté les pièces fémorale et tibiale (groupe 2). Toutes les rotules ont été cimentées dans les deux groupes.

PRINCIPALES MESURES DE RÉSULTATS : Les résultats cliniques ont été évalués au moyen des scores d'évaluation clinique proposés par la Knee Society à trois mois, six mois et chaque année. Les résultats radiographiques ont été établis au moyen de radiographies prises en position debout à trois pieds et, au cours de chaque consultation de suivi, de radiographies du genou prises en position debout, vues latérale et verticale. On a analysé les radiographies pour déterminer l'alignement, la présence ou l'absence de lignes radio-opaques ou si l'implant avait changé la position. On a consigné toutes les nouvelles interventions et les complications non opératoires.

RÉSULTATS : Pour un suivi moyen de 4,8 ans, il a fallu réopérer huit genoux (1,6 %). Une analyse des complications qui ont entraîné une nouvelle intervention n'a révélé aucune différence entre les deux groupes.

CONCLUSIONS : Les résultats ne présentent aucune différence, que la pièce fémorale ait été cimentée ou non. Les résultats à moyen terme du GMA sont excellents et présentent un taux très faible de répétition d'intervention.

From the London Health Science Centre, University of Western Ontario, London, Ont.

Accepted for publication July 28, 1998

Correspondence to: Dr. Cecil H. Rorabeck, LHSC—University Hospital, 339 Windermere Rd., London ON N6A 5A5; fax 519 663-3838, cecil.rorabeck@lhsc.on.ca

© 1999 Canadian Medical Association (text and abstract/résumé)

The aim of total knee arthroplasty in patients suffering from end-stage arthritis is to relieve pain and to restore function. Most early prostheses of total knee replacement were inserted using cement, and the conformity between the femoral component and the tibial polyethylene component was substantial. Although a large contact area was beneficial in terms of reducing wear, many of these conforming designs were associated with a high incidence of aseptic loosening, particularly of the tibial component.^{1,2} In an attempt to decrease forces at the bone-cement interface and restore normal "knee kinematics" (including femoral roll-back), flat-on-flat designs emerged as the "avant-garde" knee of the 1980s.

Porous-coated technology, introduced in 1981, was intended to solve the problem of cement failure and component loosening, particularly on the tibial side. As the result of concern over limited bony ingrowth of the tibial component, the hybrid concept — cementing the tibial component and using a cementless femoral component — was introduced. More recently, there has been an interest in returning to a fully cemented total knee replacement, in part because of cost considerations.³

Because of experience with the Miller-Galante I prosthesis (Zimmer, Inc., Warsaw, Ind.), which demonstrated a 9% reoperation rate within 3 years, a search was made for a primary total knee system that would address the issues of patellofemoral conformity without metal backing.⁴ In 1988 the anatomic modular knee (AMK; DePuy, Warsaw, Ind.) was introduced in the hope that extensor mechanism problems would be eliminated.⁵

The purpose of this study was to compare the complication rates with hybrid or cemented fixation using the AMK. The hypothesis was that the

clinical results and complications would be similar, irrespective of the method of fixation (hybrid or cemented).

PATIENTS AND METHOD

This report is a single surgeon's experience in which 484 knees (89 bilateral) in 395 patients were replaced primarily with the AMK. This knee comprises a cobalt chrome femoral component available in 7 sizes, with either smooth backing for cemented applications or plasma-spray backing for noncemented applications. The tibial tray, available in 5 sizes, is plasma-sprayed, allowing for the attachment of modular stems. It can be inserted with or without cement. The patella is an all-polyethylene dome (Fig. 1), which comes in 4 sizes.

The preoperative indications for surgery in this series were osteoarthritis in 449 knees, rheumatoid arthritis in 29 and avascular necrosis in 6. Of the 484 knees, 281 were replaced in women and 203 in men. The average height and weight for the women was 157 cm and 80.7 kg, and for the men was 173 cm and 90.3 kg. The mean age at time of surgery was 68 years for both groups.

The operation was performed in 1 of 2 ways. In group 1 (260 knees), a hybrid configuration consisting of a noncemented femoral component and a cemented tibial component was used. In group 2 (224 knees) both components were cemented. All patellar components, in both groups, were non-metal backed and all were cemented. Follow-up ranged from 3 to 8 years (mean 4.8 years).

The groups were not randomized; the femoral component fixation technique used depended upon the accuracy of the femoral bone cuts as observed with a trial component and as judged by the surgeon. When cement

was used it was vacuum-mixed and pressurized into the tibia and femur with a cement gun. In both groups, all cemented components, including the patella, were cemented at the same time, the components were inserted and the knee placed into extension.

At the beginning of the series, canal-referenced instruments were used. This necessitated that the surgeon judge the amount of external rotation of the distal femoral cutting jig by eye. These instruments were discontinued after surgery on knee 227 (after 1990); from that point on, the instruments used assured 3° of external rotation of the femoral component. This change allowed a comparison of the efficacy of 2 different instrument systems as they related to the incidence of lateral retinacular release. Intramedullary referencing was used on the femoral side and extramedullary referencing on the tibial side. In both groups, the patella was prepared by measuring the height of the existing patella and resecting an amount of bone equal to the thickness of the patellar implant. Electrocautery was used to make a "circumcision" around the equator of the patella in all patients in an attempt to divide any remaining nerves to the cut surface of the patella. Maximum coverage of the raw patellar bone was obtained with the appropriately sized implant. The patella button was placed centrally or in a slightly medial position.

All patients were assessed preoperatively, and postoperatively at 3 months and 6 months and at yearly intervals thereafter. The Knee Society Clinical Rating Scores (KSCRSs) were documented independently by a clinical study nurse. A standing 3-foot radiograph was obtained preoperatively and 1 year after surgery, to measure alignment. At every follow-up, standing knee radiographs, and lateral and skyline views were obtained.

RESULTS

Of the 395 patients in this study, 16 died and 1 was lost to follow-up (17 knees), leaving 467 knees available for postoperative study.

Clinical assessment

An analysis of the KSCRSs demonstrated the following. The typical patient had a preoperative pain score of 13, a range of motion (ROM) of 5° to 106° and a knee score of 44 with a function score of 44, for a total of 88. At the 1-year follow-up visit, an analysis of group 1 knees demonstrated a mean ROM of 108° (from 2° to 110°). This ROM was maintained throughout the 6-year follow-up period (Table I) as was the KSCRS of 175 at 1 year and at each subsequent follow-up interval (Table II). Similarly, in group 2 the ROM at 1 year was 109° (from 1° to 110°), and this was maintained throughout the 6-year follow-up interval. An analysis of the KSCRSs during the same period revealed no statistical difference throughout the 6-year follow-up (173) (Table II). It is important to note that the clinical results showed no tendency toward deterioration over time.⁶

Radiographic assessment

Preoperatively, 73 knees had genu valgum and the remaining 411 were considered to be in some degree of varus; the varus deformity averaged 11° (tibial femoral angle) and the valgus deformity 12°. The operative procedure was successful in both groups, correcting the mechanical alignment.

Postoperatively, radiographic analysis demonstrated that no patient in either group had signs of “definite loosening,” which would be indicated by a change in the position of the tibial or

femoral component. On the femoral side, knees with a cemented femoral component did equally well when compared to knees with a noncemented femoral component. Once again, there was no evidence of global radiolucent or radiosclerotic lines around the femoral component, whether it was inserted with or without cement.

Conversely, on the tibial side, radiolucent lines were noted more commonly on the anteroposterior view of the cemented tibial component. The radiolucent lines were most often seen under the medial tibial plateau, extending a centimetre or less toward the cen-

tral peg and were usually less than 1 or 2 mm thick (Fig. 2). For the cemented tibial component, the rate of radiolucent lines was 12%; however, only 1% of the lines were thought to be progressive, and in no instance were the radiolucent lines noted to be global or circumferential around the tibial stem. Conversely, on the lateral side, radiolucent lines under the lateral plateau were distinctly uncommon and were noted in only 5% of knees. These lines averaged 8 mm in length and 1 to 2 mm in thickness, and in no case was loosening considered to be probable or definite. There was no statistical difference in the



FIG. 1. A femoral component of the anatomic modular knee demonstrating the articulation with an all polyethylene patellar button. Note the conformity of the patellofemoral joint.

Table I

Range of Motion (in Degrees) Preoperatively and During Follow-up in Patients Who Had a Noncemented (Group 1) or a Cemented (Group 2) Femoral Component

Group	Preop	Follow-up interval, yr			
		1	2	4	6
1	5-106	108	114	111	112
2	5-106	109	112	114	115

Table II

Mean Knee Society Clinical Rating Score (KSCRS) Preoperatively and During Follow-up in Patients Who Had a Noncemented (Group 1) or a Cemented (Group 2) Femoral Component

Group	Preop	Follow-up interval, yr			
		1	2	4	6
1	88	175	173	176	175
2	88	173	173	175	174

rate or location of radiolucent lines, irrespective of whether the femoral component was cemented or not cemented.

Complications

Eight knees (1.6%) required reoperation during the follow-up period, which averaged 4.8 years. Comparison of complications between the 2 groups demonstrated the following: in group 2 (cemented), 5 knees required reoperation, 3 for polywear and 2 for late sepsis (more than 30 days postoperatively). In group 1 (hybrid), 3 knees required reoperation, 2 for (arthrofibrosis) and 1 for wound dehiscence (caused by the patient having a fall on the second postoperative day).

Other significant complications occurred, not requiring operation. Seven knees (3 in group 1 and 4 in group 2) were slow to regain their ROM, and a manipulation was performed under epidural anesthesia. Four patients complained of ongoing pain, which was believed to be related to the lateral rise of the femoral component. At least 1 injection of a long-acting anesthetic and cortisone was administered in each patient in an attempt to relieve the symptoms. This approach was successful in 2 patients, but in the others the pain persisted. An additional 4 (2 in each group) patients suffered a fracture of the patella, which was managed without surgery. All were vertical fractures with an intact extensor

mechanism and presumably occurred secondary to a tight lateral retinaculum. They were probably stress fractures, and although none of them have healed no patient has been significantly symptomatic to necessitate reoperation.

A comparison of complications in knees requiring reoperation and those not requiring reoperation showed no significant difference between the 2 study groups. Complications were low in both groups.

Lateral retinacular release

At the beginning of the series, when canal-referenced instruments were used, external rotation of the

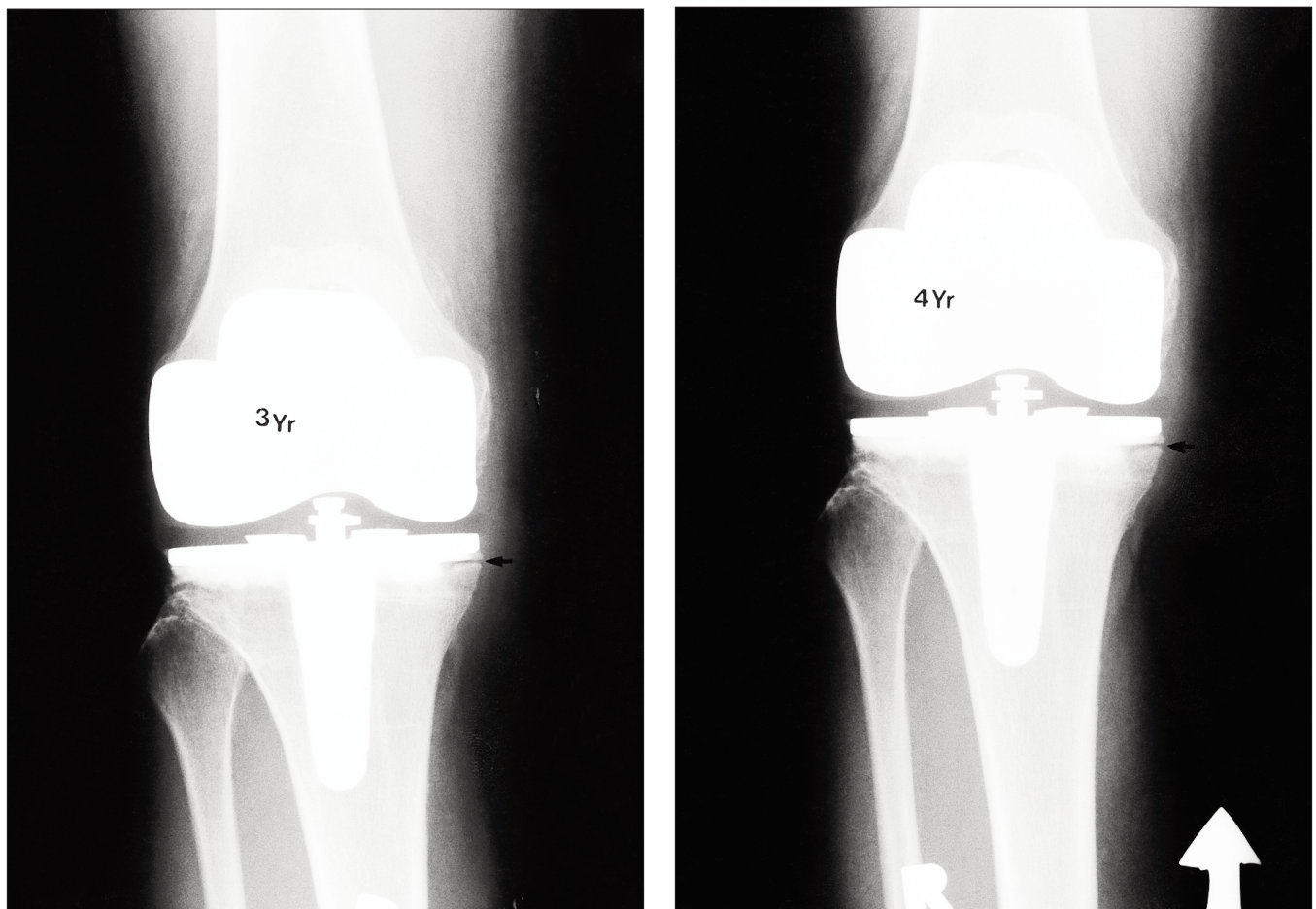


FIG. 2. A cemented tibial component showing a nonprogressive radiolucent line beneath the medial plateau and beneath the lateral plateau on sequential anteroposterior x-ray films.

femoral component was *not assured*, and a lateral retinacular release was performed 31% of the time. When instrumentation with 3° of external rotation was used, a lateral retinacular release was performed only 7% of the time. Thus, it appears that the practice of externally rotating the femoral component 3° has had a dramatic effect on the need for lateral retinacular release. More importantly, none of the patients in either group experienced dislocation or subluxation of their patellar component.

DISCUSSION

The results of total knee arthroplasty in this series compare favourably with those of other reports.^{1,2,4,5,7-9} At medium-term follow-up (average 4.8 years) the reoperation rate was 1.6%. Kaplan–Meier analysis of the KSCRS and ROM demonstrated no significant difference between the all-cemented and the hybrid groups (Tables I and II).

The complication rate was independent of the method of fixation of the femoral component. There was no statistically significant difference in the reoperation rate or in the number of complications not requiring surgery whether the femoral component was inserted with or without cement. Of importance is that 3 knees had premature polyethylene wear. All 3 had thin polyethylene liners, 1 of 8 mm and 2 of 10 mm. However, the actual thickness of the liners at the point of contact was only 4 mm in the 8-mm liner and 6 mm in the 10-mm liners. It is tempting to speculate as to the etiology of the polyethylene wear in these 3 knees, and whereas all 3 liners had been gamma irradiated, so had many of the other liners inserted in this series. The practice of using 8-mm polyethylene inserts is not recommended.

Although the average ROM of 109° in this study was perhaps slightly

less than that reported by others, it is important to note that the ROM achieved occurred irrespective of the method of fixation of the femoral component. The ROM reported in this study compares favourably with that reported for other knee systems used at the University Hospital in London, Ont., namely Miller–Galante I and II (Zimmer, Inc., Warsaw, Ind.) (112°), PCA (Howmedica, Inc., Rutherford, NJ) (106°) and Genesis I (Smith and Nephew Richards, Memphis, Tenn.) (109°).^{1,5}

The introduction of instrumentation that assured external rotation of the femoral component has had a marked effect on the need for lateral retinacular release (from 31% to 7%). Although restoration of patellofemoral kinematics is clearly a goal for patients who undergo total knee replacement, the use of femoral instrumentation that does not assure external rotation of the femoral component is clearly associated with a higher risk of lateral retinacular release. This did not seem to affect outcome as judged by either the ultimate ROM or the complication rate; nevertheless, the reduced requirements for lateral retinacular release seemed to be of benefit as far as the patient's recovery was concerned. The decrease in the need for lateral retinacular release emphasizes the importance of external rotation in restoring patellofemoral tracking.

Of some concern were the 4 knees associated with persistent anterior knee pain. Initially it was thought that the anterior knee pain might be related to the lateral rise of the femoral component. A recent study by Barrack and colleagues¹⁰ demonstrated a 7% incidence of anterior pain in the Miller–Galante knee, an implant that did not have a prominent lateral rise. Thus, the incidence of anterior knee pain reported in our series is considerably lower than that reported in previ-

ous series, suggesting that the lateral rise of the femoral component was probably not causally related to the patient's symptoms.

Four patients suffered a lateral vertical fracture of the patella. These were believed to be stress fractures, and no obvious mechanism or history of injury could be obtained. All fractures were vertical, involved the lateral facet of the patella and were only visible in the skyline views. Although none of the 4 knees required surgery, this complication is disturbing and one of which surgeons must be aware. If the lateral retinaculum seems to be tight at the time of closure, then a lateral retinacular release should be considered even though the patella seems to be tracking well.

No loosening of the femoral component, whether inserted with or without cement, was evident. On the tibial side, however, a 12% rate of radiolucent lines was noted, and they were more common on the medial side. The rate of radiolucent lines was not related to the method of femoral component fixation, and none of the tibial components were deemed to be probably or definitely loose. Osteolysis was not noted under the tibial tray in any of the patients. Of interest is that radiolucent lines observed on the anteroposterior radiographs under the tibial component seem to start peripherally and were noted most commonly on the medial side. A cemented tibial titanium tray was used in all cases, and with the relatively low modulus of elasticity of the titanium and the repeated loading of the edges of the base plate, it is possible that micro-movement may occur between the base plate and the underlying bone cement construct, which would account for the appearance of peripheral radiolucent lines.

This study demonstrated no benefit with respect to outcome from use

of a noncemented femoral component in primary knee replacement arthroplasty with the AMK prosthesis during a mean 4.8-year follow-up. Considering the added expense of a noncemented femoral component there is no economic, clinical or radiographic justification for noncemented femoral fixation.

References

1. Callahan CM, Drake BG, Heck DA, Dittus RS. Patient outcomes following tricompartmental total knee replacement. A meta-analysis. *JAMA* 1994; 271(17):1349-57.
2. Grewal R, Rimer MG, Freeman MA. Early migration of prostheses related to long-term survivorship. Comparison of tibial components in knee replacement. *J Bone Joint Surg [Br]* 1992;74:239-42.
3. Whiteside LA. Four screws for fixation of the tibial component in cementless total knee arthroplasty. *Clin Orthop* 1994;299:72-6.
4. Ritter MA, Faris PM, Keating EM, Meding JB. Postoperative alignment of total knee replacement. Its effect on survival. *Clin Orthop* 1994;299:153-6.
5. Rorabeck CH, Bourne RB, Lewis PL, Nott L. The Miller-Galante knee prosthesis for the treatment of osteoarthritis: a comparison of the results of partial fixation with cement and fixation without any cement. *J Bone Joint Surg [Am]* 1993;75:402-8.
6. Ferguson GA. *Statistical analysis in physiology and education*. 3rd ed. Toronto: McGraw-Hill Book Company; 1971. p. 160-2.
7. Barnes CL, Scott RD. Patellofemoral complications of total knee replacement. *Instr Course Lect* 1992;42:303-7.
8. Bourne RB, Rorabeck CH, Vaz M, Kramer J, Hardie K, Robertson D. Resurfacing versus not resurfacing the patella during total knee replacement. *Clin Orthop* 1995;321:156-61.
9. Boyd AD Jr, Ewald FC, Thomas WH, Poss R, Sledge CB. Long-term complications after total knee arthroplasty with or without resurfacing of the patella. *J Bone Joint Surg [Am]* 1993; 75(5):674-81.
10. Barrack RL, Wolfe MA, Milicic M, Waldman DA, Bertot A. Patellar resurfacing in total knee arthroplasty: a prospective randomized study. Presented at the 64th annual meeting of the American Academy Orthopaedic Surgeons, San Francisco, Feb. 13-17, 1997.

Essential reading

from CMA Publications

- CMAJ
- Canadian Journal of Surgery
- Clinical and Investigative Medicine
- Journal of Psychiatry & Neuroscience

For information contact
 CMA Member Service Centre
 888 855-2555
 cmamsc@cma.ca

