

TREATMENT OF OSTEONECROSIS OF THE FEMORAL HEAD BY FREE VASCULARIZED FIBULAR GRAFTING: AN ANALYSIS OF SURGICAL OUTCOME AND PATIENT HEALTH STATUS

Brian E. Louie, MD, MHA;* Michael D. McKee, MD;† Robin R. Richards, MD;‡ James L. Mahoney, MD;§ James P. Waddell, MD;¶ Dorcas E. Beaton, BSc, OT, MSc;** Emil H. Schemitsch, MD;†† Daniel J. Yoo, MD‡‡

OBJECTIVE: To evaluate the limb-specific outcome and general health status of patients with osteonecrosis of the femoral head treated with vascularized fibular grafting.

DESIGN: A retrospective review.

SETTING: A single tertiary care centre.

PATIENTS: Fifty-five consecutive patients with osteonecrosis of the femoral head who underwent fibular grafting (8 bilaterally).

INTERVENTION: Vascularized fibular grafting.

OUTCOME MEASURES: Limb-specific scores (Harris Hip Score, St. Michael's Hospital Hip Score), general health status (Nottingham Health Profile, SF-36 health status survey) and radiographic outcome measures (Steinberg stage).

RESULTS: Patients were young (mean age 34 years, range from 18 to 52 years) and 80% had advanced osteonecrosis (Steinberg stages IV and V). Fifty-nine hips were followed up for an average of 50 months (range from 24 to 117 months) after vascularized fibular grafting. Sixteen hips (27%) were converted to total hip arthroplasty (THA). To date, 73% of hips treated with vascularized fibular grafting have required no further surgery. Preoperative and postoperative Harris Hip Scores were 57.3 and 83.6 respectively ($p < 0.001$). As measured by patient-oriented health status questionnaires (SF-36, Nottingham Health Profile) and compared with population controls, patients had normal mental health scores and only slight decreases in physical component scores.

CONCLUSIONS: Free vascularized fibular grafting for osteonecrosis of the femoral head provides satisfactory pain relief, functional improvement and general health status and halts the progression of symptomatic disease.

OBJECTIF : Évaluer la santé du membre et l'état de santé général de patients atteints d'ostéonécrose de la tête du fémur traités au moyen d'une greffe péronière vascularisée.

CONCEPTION : Étude rétrospective.

CONTEXTE : Centre de soins tertiaires.

PATIENTS : Cinquante-cinq patients consécutifs atteints d'ostéonécrose de la tête du fémur qui ont reçu une greffe péronière (bilatérale dans huit cas).

INTERVENTION : Greffe péronière vascularisée.

From the Division of Orthopedics and Division of Plastic Surgery, St. Michael's Hospital, University of Toronto, Toronto, Ont.

Presented in part at the annual meeting of the Canadian Orthopaedic Association, Hamilton, Ont., June 1, 1997, and the annual meeting of the American Academy of Orthopaedic Surgery, San Francisco, Calif., Feb. 13, 1997.

**Surgical Resident, Department of Surgery, University of Alberta, Edmonton, Alta.*

*†Assistant Professor, ‡Associate Professor and Head, ¶Professor, **Research Clinician, ††Associate Professor and ‡‡Research Assistant, Division of Orthopedics, St. Michael's Hospital*

§Associate Professor and Head, Division of Plastic Surgery, St. Michael's Hospital

Accepted for publication Oct. 6, 1998.

Correspondence to: Dr. Michael D. McKee, Suite 800, 55 Queen St. E, Toronto ON M5C 1R6

© 1999 Canadian Medical Association (text and abstract/résumé)

MESURES DE RÉSULTATS : Santé du membre (cote de la hanche de Harris, cote de la hanche de l'Hôpital St. Michael's), état de santé général (profil de la santé de Nottingham, questionnaire sur l'état de santé SF-36) et résultats radiographiques (stade de Steinberg).

RÉSULTATS : Les patients étaient jeunes (âge moyen de 34 ans, intervalle de 18 à 52 ans) et 80 % étaient atteints d'ostéonécrose avancée (stades IV et V de Steinberg). On a suivi 59 hanches pendant 50 mois en moyenne (intervalle de 24 à 117 mois) après une greffe péronière vascularisée. Dans 16 cas (27 %), on a procédé à une arthroplastie totale de la hanche. Jusqu'à maintenant, 73 % des hanches traitées par greffe péronière vascularisée n'ont pas eu besoin d'autre intervention chirurgicale. Les cotes de la hanche de Harris avant et après l'intervention étaient de 57,3 et 83,6 respectivement ($p < 0,001$). Selon des questionnaires sur l'état de santé axés sur les patients (SF-36, profil de l'état de santé de Nottingham), et comparativement à des populations témoins, les patients présentaient un état de santé mental normal et de légères baisses seulement des cotes relatives aux éléments physiques.

CONCLUSIONS : Une greffe péronière vascularisée libre pour traiter l'ostéonécrose de la tête du fémur soulage la douleur de façon satisfaisante, améliore le fonctionnement du membre et l'état de santé général et arrête l'évolution de la maladie symptomatique.

Recent studies have called attention to the increasing incidence and prevalence of osteonecrosis of the femoral head (ONFH), especially in young patients.¹⁻⁵ Corticosteroid use, excessive alcohol intake, trauma and hemoglobinopathy are frequently identified as the most common causes; 20% to 30% have no identified etiology.^{1,2,4-7}

Several recent studies have shown that the natural history of symptomatic ONFH, especially after subchondral fracture or femoral head collapse, is progressive collapse and resultant osteoarthritis.^{1,2,8} These studies suggest that progression of the osteonecrosis, both clinically and radiographically, occurs within the first 3 years after diagnosis.

The treatment of ONFH depends on symptomatology, the radiographic stage of the disease and the age of the patient. Early ONFH (stages I and II) has been treated with core decompression with or without bone grafting,^{3,9-13} but the success rate, especially in younger patients or those with collapse of the femoral head, has been inconsistent.^{6,7,11,14-19} Whereas older patients do well, THA for advanced disease has been demonstrated to have higher complication rates and a poorer prognosis in younger patients.²⁰⁻²³

Free vascularized fibular grafting with microvascular anastomosis has

been shown to be effective for younger patients with advanced ONFH,²⁴⁻²⁹ but previous reports have used a limited definition of "success" as the absence of any further hip procedure and have concentrated exclusively on hip or joint-specific outcome measures. The purpose of our study was to assess the effectiveness, using both conventional and patient-oriented outcome measures such as the Nottingham Health Profile (NHP) and the SF-36 health status survey,³⁰⁻³³ of free vascularized fibular grafting in the treatment of patients under 50 years of age with symptomatic osteonecrosis of the femoral head.

PATIENTS AND METHODS

We retrospectively reviewed 55 patients (63 consecutive hips) who had vascularized fibular grafting done for osteonecrosis of the femoral head by a single surgical team between 1986 and 1993 (Figs. 1 to 4). The procedure was reserved for symptomatic patients who had radiographically documented osteonecrosis of the femoral head and were 50 years of age or younger. Of the 55 patients (63 hips), 4 (4 hips, 6%) were lost to follow-up. Of the remaining 51 patients (59 hips) (41 men, 10 women, average age 34 years [range from 18 to 52 years]) who underwent vascularized fibular grafting, 8 (16%) had bilateral grafts. All 51 patients underwent a comprehensive evaluation of

their outcome, including history, physical examination, determination of the Harris Hip Score³⁴ and St. Michael's Hospital Hip Score,²⁰ and radiographic staging of the hip according to the classification of Steinberg.³

Two patient-oriented health status questionnaires were also used: the Medical Outcome Study — SF-36^{31,33} and the NHP.^{30,32} These health status questionnaires are useful in the assessment of orthopedic interventions.^{31,32}

Patients were followed up for an average of 50 months (range from 24 months to 117 months). The associated etiologic factors included steroid use in 63% (37 hips), alcohol consumption in 20% (12 hips) and trauma in 12% (7 hips). The remaining 5% (3 hips) were classified as idiopathic because no etiologic factor was identified.

Each hip was staged radiographically at the time of operation and followed up by Steinberg's classification.³ Preoperatively, no hips were assessed as stage I, 5 hips (8%) were classified as stage II; 7 hips (12%) were assigned stage III, 38 hips (64%) were stage IV, 7 hips (12%) were stage V and 1 hip (2%) was felt to be stage VI. The preoperative radiographs for 1 hip were lost.

OPERATIVE PROCEDURE

The procedure was a variation of the method of Urbaniak and colleagues^{26,28} Preparation of the hip and recipient

vessels, and elevation of the fibular graft were performed simultaneously by 2 separate surgical teams. The fibular graft was inserted into the centre of the osteonecrotic focus, usually in the anterior, superior quadrant of the femoral head. The peroneal (donor) and lateral femoral circumflex (recipient) vessels were anastomosed with the help of an operating room microscope. Postoperatively, patients were kept well hydrated with intravenous saline solution (0.9% sodium chloride solution at a flow rate of 200 mL/h) for 2 days and were given 5000 units of heparin subcutaneously 3 times daily for 5 days. The patency of the microvascular anastomosis was assessed by bone scanning within 48 hours of surgery in each patient. The patients received a caffeine-free diet and were asked not to smoke for 12 weeks. Patients were kept non-weight bearing with crutches for approximately 6 weeks. Then they were then allowed partial weight bearing with crutches for a further 6 weeks and at the conclusion of the 3-month rehabilitation period were gradually progressed to weight bearing as tolerated. Resistance or strengthening physiotherapy exercises were avoided for these first 3 months.

Statistical analysis of the data was by paired 2-tailed *t*-tests and analysis of variance, Kaplan–Meier survivorship analysis and Cox modelling. All patients who had THA at follow-up were first compared with patients who underwent vascularized fibular grafting and were then excluded from further analysis of the vascularized fibular grafts.

RESULTS

Four patients died during the study period. At the time of operation the average age of these 4 patients was 40.6 years (range from 34 to 44 years). Consumption of alcohol was identified as the underlying etiologic factor leading to ONFH in 3 cases. An

error in diagnosis was made in 1 patient who died 3 months postoperatively of metastatic carcinoma. The cause of death in each case was not related to the operation, and no patient had undergone any further hip surgery before death.

Hip scores

Each hip was evaluated preoperatively and postoperatively by 2 hip

scoring systems: the Harris Hip Score³⁴ and the St. Michael's Hospital Hip Score.²⁰ Hips converted to THA were excluded from the follow-up scores. The mean Harris Hip Score increased from 57.3 preoperatively to 83.6 at the most recent follow-up ($p < 0.001$). This is illustrated in Fig. 5, according to the stage of the disease. The mean St. Michael's Hospital Hip Score increased from 12.8 preoperatively to 18.1 at most recent fol-

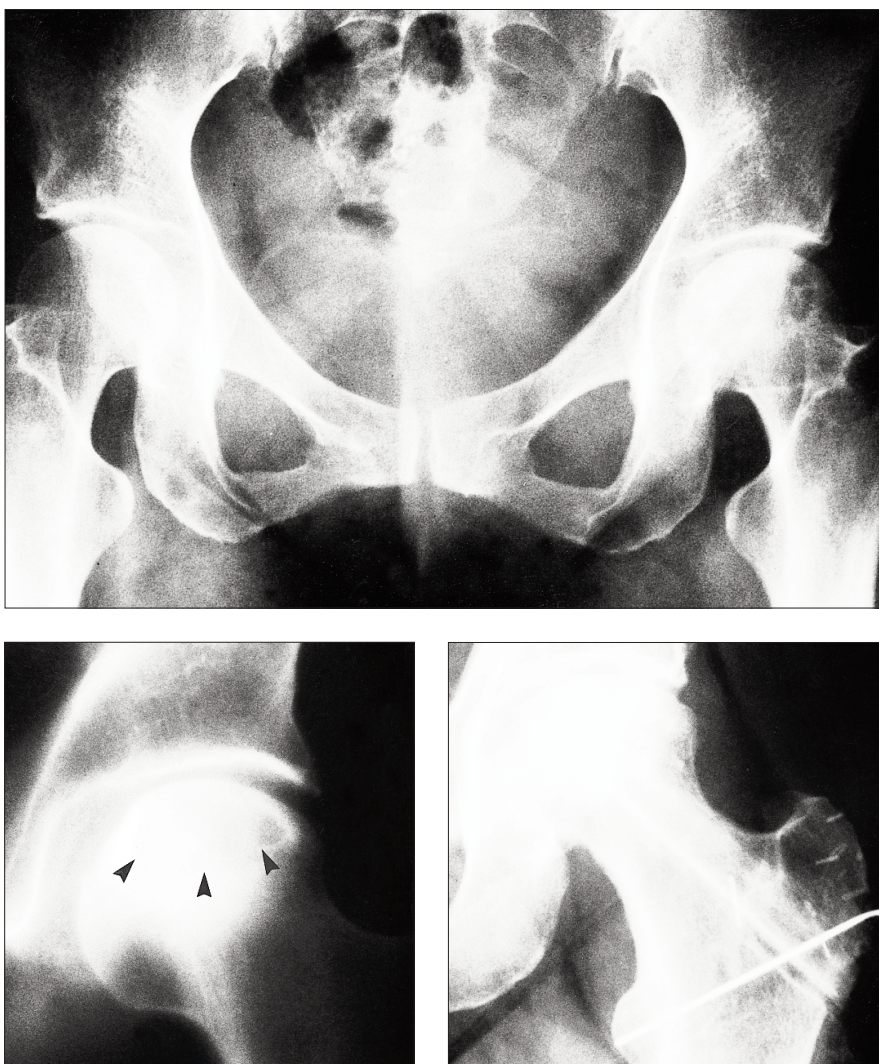


FIG. 1. (Top) Anteroposterior radiograph of the hip of a 34-year-old woman with severe hip pain and steroid-induced osteonecrosis of the left hip, Steinberg stage II. Preoperative Harris Hip Score was 48. (Bottom left) A tomogram reveals the extent of the osteonecrotic focus, typically in the anterior, superior quadrant of the femoral head (arrows). (Bottom right) Anteroposterior radiograph obtained 6 years after vascularized fibular grafting. Note the position of the graft in the centre of the osteonecrotic focus and maintenance of femoral head sphericity. The Harris Hip Score was 95.

low-up ($p < 0.001$), and is displayed similarly in Fig. 6. Pain symptoms are recorded as part of the Harris Hip Score with a maximum of 44 points

equal to no pain and a minimum score of 0 (worst pain). Overall, the mean pain component of the Harris Hip Score went from 19.2 points preoper-

atively to 34.9 points at the most recent follow-up. Fig. 7 shows the pain component according to the stage of disease. Improvements in each group were significant ($p = 0.016, 0.011, 0.012$, for stages II, IV and V respectively, paired 2-tailed t -test), except for stage III due to small sample size. None of the groups was significantly different from any other.

Conversion to total hip arthroplasty

Sixteen hips (27%) were converted to THA an average of 2.6 years (range from 1 to 6 years) after vascularized fibular grafting at an average patient age of 38 years (range from 21 to 51 years). The primary indication for reoperation was pain. None of the 5 stage II hips was converted to THA. Two (28%) of the 7 stage III hips were converted to THA. Of 38 stage IV hips, 10 (26%) underwent conversion to THA. Three (43%) of 7 stage V hips were also converted to THA. The 1 stage VI hip was converted to THA. Kaplan-Meier survivorship analysis showed that the overall probability for conversion to THA at 50 months after free vascularized fibular grafting was 27% (Fig. 8). There was a trend for stage II hips to be less likely ($p = 0.14$) and stages V and VI hips to be more likely ($p = 0.15$) to require conversion to THA when compared with all other groups, but this trend was not significant. The probability for conversion by patient age was also analysed. The probability for conversion within 50 months of grafting for patients aged 10 to 19 years was 0%, for patients aged 20 to 29 years 22.6%, for patients aged 30 to 39 years 26.3% and for patients aged 40 and older 70%. Patients over the age of 40 years were more likely to require conversion to THA ($p = 0.01$).

Radiographic progression

Radiographic progression of the osteonecrosis occurred in 4 of 5 stage

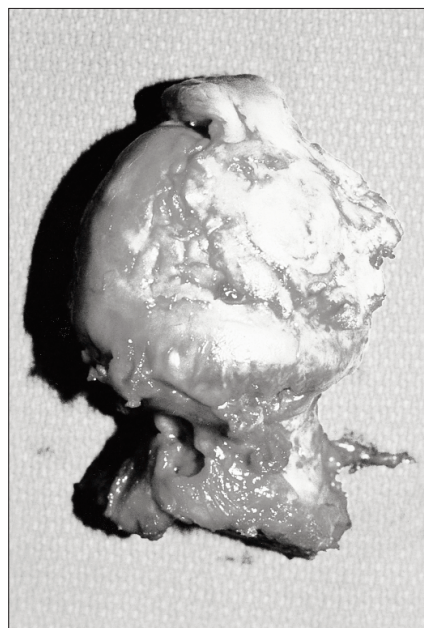
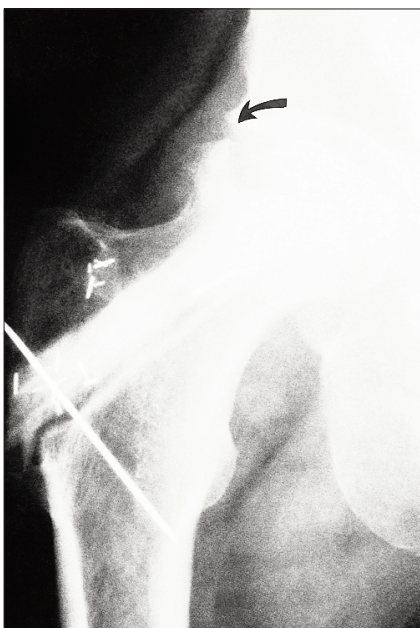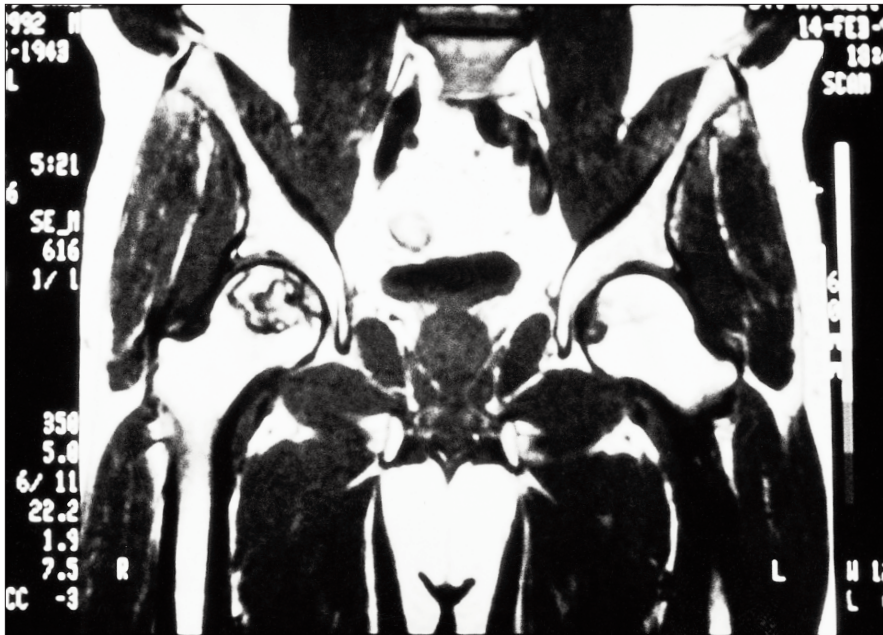


FIG. 2. (Top) Magnetic resonance imaging of the hips of a 46-year-old man who had extensive osteonecrosis of the right femoral head and suffered from alcohol abuse. Plain radiographs revealed a subchondral fracture line (Steinberg's stage III). (Bottom left) Anteroposterior radiograph taken 2 years after vascularized fibular grafting reveals collapse of the femoral head and osteophyte formation at the acetabular margin (arrow). The patient had severe pain and stiffness, and subsequently underwent total hip arthroplasty (THA). (Bottom right) The resected femoral head at the time of THA, revealing severe articular damage.

II hips, although none of these required THA. Of 7 stage III hips, 1 showed evidence of femoral head collapse and 2 subsequently needed THA. Although 17 of 38 stage IV hips showed no evidence of radiographic progression after vascularized fibular grafting, 19 had progressed. Nine of these hips developed either joint-space narrowing or showed evidence of acetabular changes. Five of 7 stage V hips showed evidence of radiographic progression. Overall, 52% of hips demonstrated some progression, radiographically, of the osteonecrosis. Although there was a trend toward a lower reoperation rate in those hips that did not show radiographic progression, the trend was not statistically significant.

Bilateral grafts

Patients with bilateral vascularized fibular grafts were analysed as a subgroup to determine their prognosis in relation to those with unilateral grafts.

Eight patients (16 hips) underwent bilateral vascular grafting. Of these, 12 cases of osteonecrosis were steroid induced and 4 were secondary to exces-

sive alcohol use. A mean of 50 weeks (range from 23 to 142 weeks) elapsed between operating on the first hip (HIP 1) and operating on the second

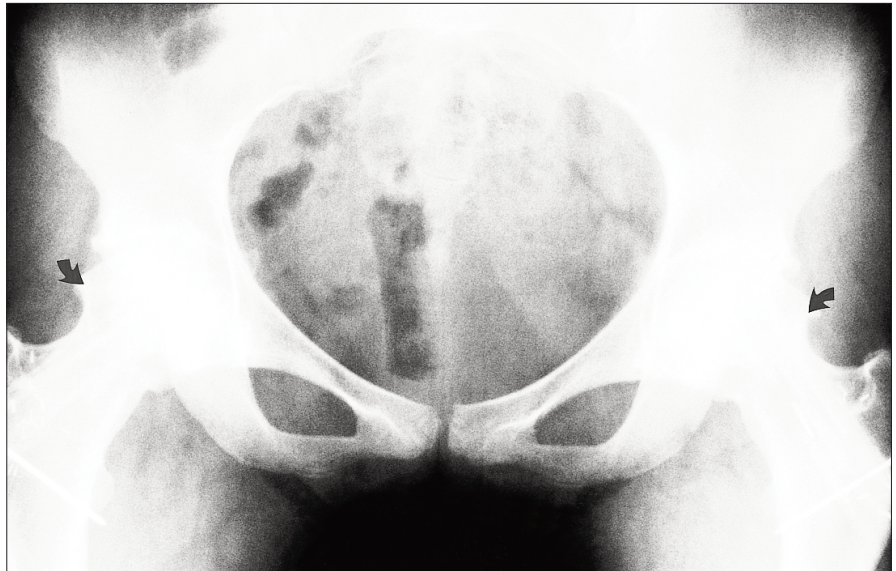


FIG. 3. Anteroposterior view of the pelvis of a 29-year-old woman 9 years after vascularized fibular grafting for bilateral steroid-induced osteonecrosis of the femoral head. Some degenerative changes can be seen at the margins of the femoral heads (arrows), but the joint space is well maintained and the patient was minimally symptomatic with Harris Hip Scores of 90 (left hip) and 92 (right hip).

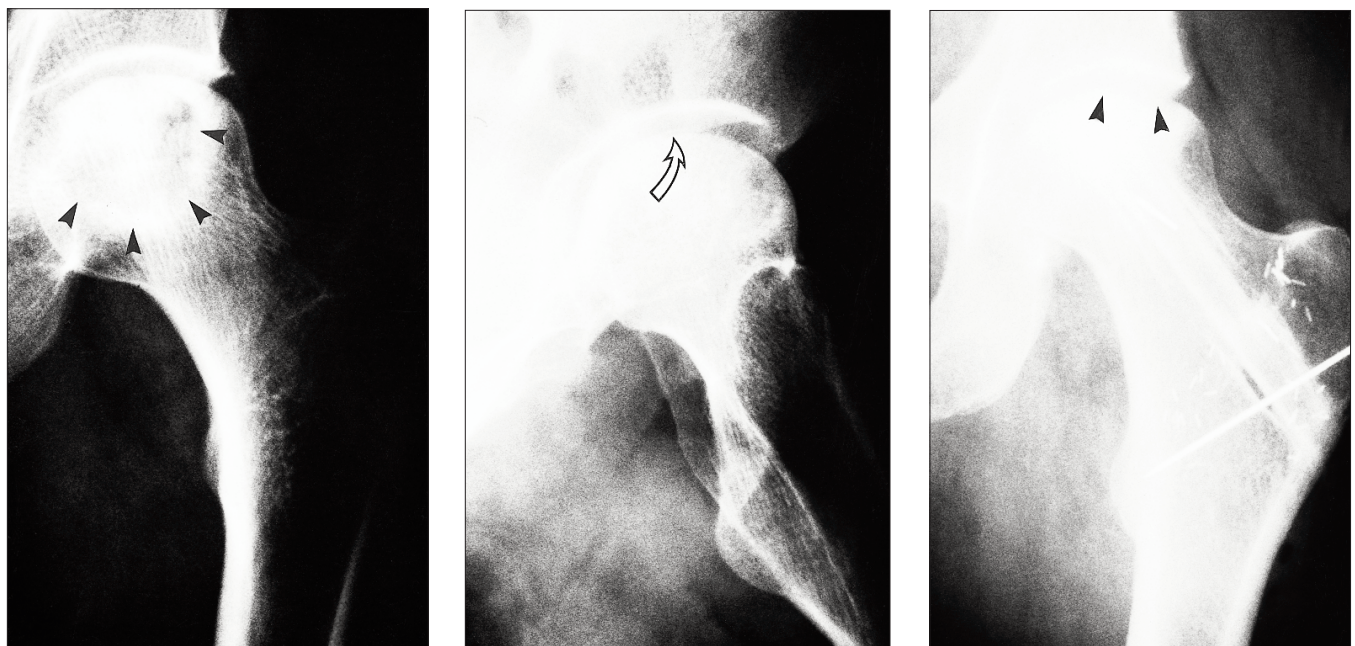


FIG. 4. (Left) Anteroposterior view of the left hip of a 33-year-old man patient with Steinberg stage III osteonecrosis of the femoral head. The arrows show the extensive nature of the lesion. (Centre) Lateral radiograph illustrating subchondral fracture line (arrow). (Right) Anteroposterior radiograph taken 5 years after vascularized fibular grafting. Radiographic progression is illustrated by some loss of sphericity of the femoral head (arrows). This patient was minimally symptomatic with a Harris Hip Score of 84.

hip (HIP 2). Three patients had both hips converted to THA, and 1 patient had 1 hip converted to THA, a mean of 27.1 months (range from 12 to 45 months) after the vascularized fibular grafting procedure. Although there was a trend toward a higher failure rate when compared with unilateral hips (44% versus 21%, $p = 0.08$), there were no significant differences in the improvements in hip scores (21.2 points versus 26.3 points, $p = 0.2$) or

general health status scores in the hips not converted to THA when compared with unilateral vascularized fibular grafts.

Health status

Forty-four (94%) of 47 surviving patients completed both SF-36 and NHP health questionnaires. Scores for the SF-36 were divided into composite physical component scores (physi-

cal function, bodily pain and physical role function, Fig. 9) and composite mental component scores (mental health, mental role function, social function, vitality and general health) and compared with North American normative data for a similar population. Overall, patients who had a vascularized fibular graft had composite SF-36 scores of 75.8% of normal controls for the physical component score, and 106.6% of normal controls

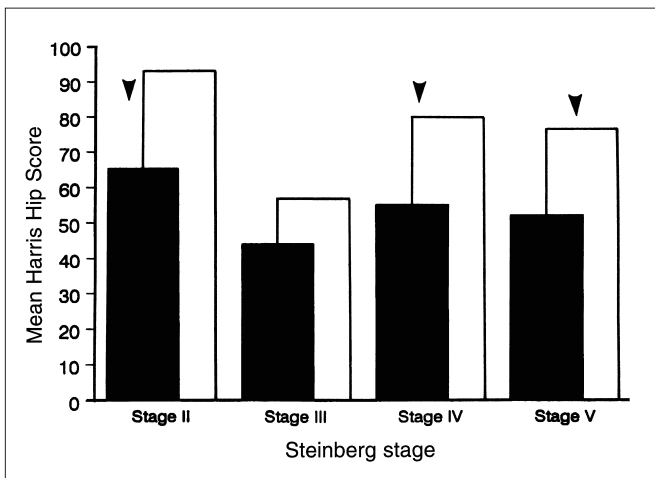


FIG. 5. The mean Harris Hip Scores for each Steinberg stage of the disease preoperatively (black bars) and at most recent follow-up (white bars). Patients subsequently treated with THA are excluded. Arrows = $p < 0.001$ preoperative versus postoperative values.

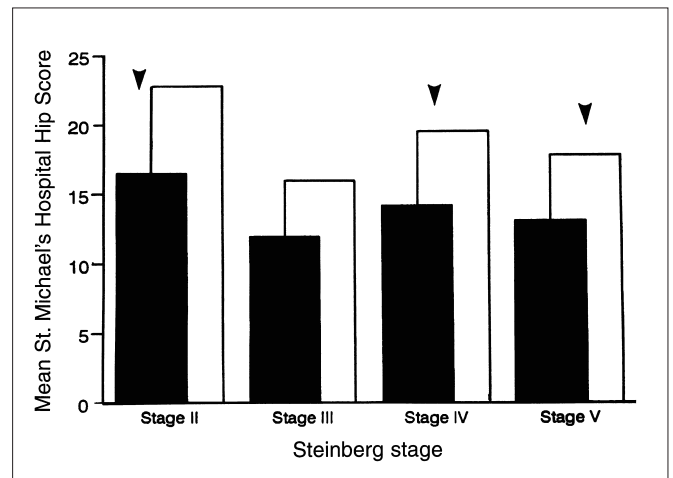


FIG. 6. Mean St. Michael's Hospital Hip Score for each stage preoperatively (black bars) and at most recent follow-up (white bars). Patients subsequently treated with THA are excluded. Arrows = $p < 0.001$ preoperative versus postoperative values.

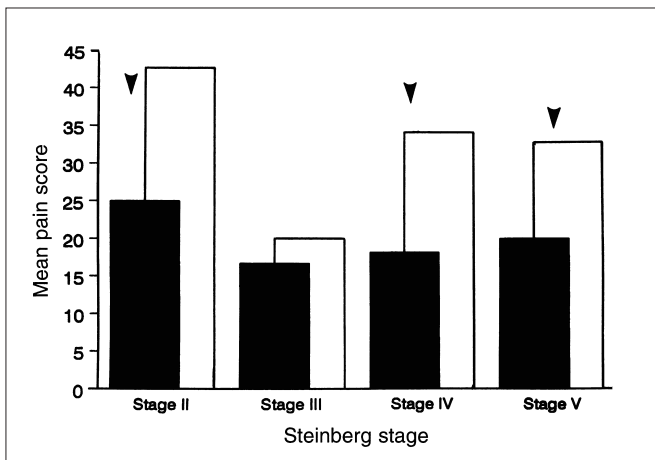


FIG. 7. The mean pain component of the Harris Hip Score for each stage preoperatively (black bars) and at most recent follow-up (white bars). Patients subsequently treated with THA are excluded. Arrows = $p < 0.016$ preoperative versus postoperative values. Maximum score = 44 points, indicating no pain.

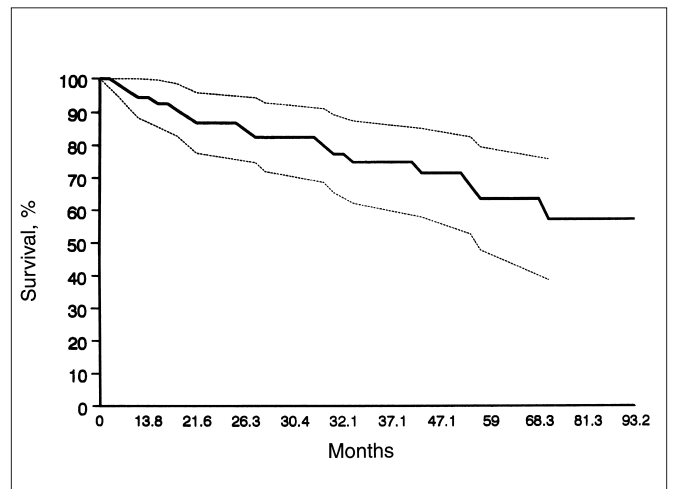


FIG. 8. Kaplan-Meier survivorship (solid line) analysis with 95% confidence interval (dotted lines) for all patients (all stages) treated with vascularized fibular grafting for osteonecrosis of the femoral head.

for the mental component score. The average NHP score was 76.4 points (with 100 equal to "ideal health"). The individual mean component scores included: pain — 54.2, physical disability — 71.4, energy — 79.5, sleep — 80.0, emotional reaction — 83.1, and social isolation — 90.0.

Bone scanning

In 59 hips clear evidence of tracer uptake along the fibular graft could be seen, in 2 hips the results were equivocal, and in 2 hips there was no evidence of tracer uptake.

Pathological findings

Pathological reports and intraoperative notes were available for 12 (75%) of the 16 hips converted to THA. All 12 fibular grafts contained viable osteocytes on microscopic evaluation, although 5 (42%) showed some areas of necrosis. New bone formation could be seen at the end of the fibular graft, underneath the subchondral bone, in 10 (84%) of the 12 grafts, as has been previously de-

scribed.³⁵ One graft was fractured. Grossly, all grafts were firmly incorporated into the tract in the femoral head and neck, and no motion was visible on manual stressing. Pathologically, all femoral heads displayed changes typical of osteonecrosis with subchondral fracture, collapse of the weight-bearing portion of the head and irregularity of the cartilaginous surface (Fig. 2, bottom right).

Complications

Complications were divided into 2 types: general complications related to the surgery and complications related to the harvesting of the fibular graft (i.e., donor site complications). In terms of general complications, there were 4 wound infections and 3 cases of deep vein thrombosis. In addition, 1 patient had a postoperative ileus, requiring extended hospitalization for both vascularized grafts that the patient underwent. One patient had a vascular clip migrate into the hip joint requiring arthrotomy to remove it 2 years after grafting. One patient suffered a corneal abrasion and another

had a serous otitis media from positioning during the operation. None of these 12 general complications led to failure of the graft.

Morbidity related to the donor site has been addressed in depth in a separate study.³⁶ Overall, over 90% of patients were satisfied with the appearance, level of pain and function of the lower limb after fibular harvesting. There was no case of peroneal nerve palsy or any other neurologic disturbance in the lower extremity. Weakness of extension of the great toe, related to the harvesting of the fibula, was seen in 2 patients. Two patients had flexion contractures of the great toe secondary to contracture of the flexor hallucis longus tendon and required a subsequent Z-plasty lengthening of the tendon, performed on an outpatient basis.

DISCUSSION

The multitude of procedures described for the treatment of ONFH, particularly for young patients with advanced disease, gives testimony to the lack of any one "ideal" technique that reliably reduces symptoms and retards the progression of the disease.^{2,9,11,28,37} The natural history of this condition carries a poor prognosis, and numerous studies have documented the dismal results of nonoperative or conservative treatment for this problem in symptomatic patients.^{2,8} The initial results of core decompression procedures, especially for early disease, were promising, but enthusiasm has been tempered by inconsistent results and an inability to reproduce previous success rates.^{1,3,8,12} A recent randomized clinical trial comparing core decompression with conservative care alone showed no difference in the 2 groups, with the disease in almost 80% of patients in both groups progressing to femoral head collapse.⁸ A review by Jones in 1993² of 9 studies of core decompression

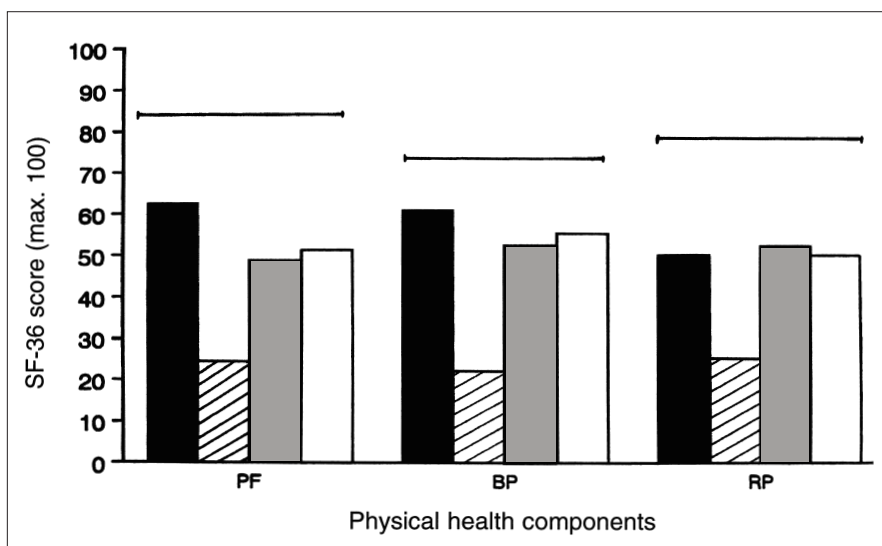


FIG. 9. The physical health components of the SF-36 health survey for each stage (black bars = stage II, hatched bars = stage III, grey bars = stage IV and white bars = stage V) at the most recent follow-up examination. PF = physical function, BP = bodily pain, RP = physical role function. Patients who subsequently required THA were excluded. Solid black lines indicate normative North American data.

showed a failure rate of close to 60% at early follow-up. Osteotomy, although successful in certain groups, is less effective with increasing femoral head involvement, and results in the North American population are inconsistent.^{6,17-19}

A recent report by Urbaniak and colleagues²⁸ has shown promising results for vascularized fibular grafting in young patients with osteonecrosis of the femoral head. The theoretic advantages of this technique include: the ability to perform a core decompression of the femoral head and to perform curettage and removal of the osteonecrotic focus; impaction of autogenous cancellous graft securely in the defect created by removal of the osteonecrotic bone, followed by the structural support of the fibular graft; and the addition of vascularized bone and blood supply to the area of osteonecrosis. Unlike conventional bone grafts, vascularized grafts can remodel and hypertrophy in response to stress, thus enhancing their ability to support the femoral head while revascularization takes place. Although it is impossible to restore congruity that has been lost, the prevention of symptomatic progression of the disease is an obtainable goal.

Patient selection is critical in deciding when to perform vascularized fibular grafting for osteonecrosis.^{6,11,24,28,37} We currently reserve this technique for patients with 2 mm or less of femoral head collapse as measured on plain radiographs ("early" Steinberg stage IV). Our study supports the trend seen by Urbaniak and colleagues²⁸ that older patients have a higher failure rate after vascularized fibular grafting. The apparent difference in outcome in relation to age may be due to a number of factors including the inherent ability of a younger patient's femoral head to remodel or revascularize compared with that of an older patient. Since we defined failure in our series as conversion to THA, it may also represent a reluctance

on the part of the treating surgeon to perform THA on these younger patients and to persist with conservative care. In any event, these findings reinforce our recommendation that this procedure be reserved for younger patients, usually for those under 40 years old. Patients in the 40 to 50-year age bracket may be reasonable candidates if the disease is at an early stage, but for older patients we recommend THA when symptoms are sufficient to warrant operative intervention.

The patients in this series were young (mean age 34 years) and 80% had some evidence of subchondral fracture or femoral head collapse (Steinberg stage IV or greater). Other series describing core decompression alone for patients with similar stages of advanced disease have reported reoperation rates of up to 80%.^{8,12,38}

Another important prognostic variable is the geographic extent of the osteonecrosis in the femoral head, as described by Koo and Kim.³⁹ They have shown that MRI is an extremely effective technique for quantifying femoral head involvement, and that patients with more extensive disease have a worse prognosis.⁴⁰ Although this may have some influence on patient selection in the future, since our series began before MRI was available, we cannot comment on it.

The patients in our series who had failure of the graft and subsequent THA had intraoperative parameters of the arthroplasty procedure (estimated blood loss, operative time, operative difficulty) that were similar to those of primary THAs performed for osteonecrosis from the same institution.^{7,20} Fibular grafting does not alter proximal femoral architecture as osteotomy does, facilitating conversion to arthroplasty. At the time of THA, the fibular grafts were well incorporated in all patients. On pathological examination of the resected femoral head, viable osteocytes could be seen in the graft usually with "fronds" of new bone growth from the

end of the fibular graft. This phenomenon has been described before,³⁷ and seems to indicate that viability of the graft does not guarantee clinical success. Conversely, as has been reported previously,²⁸ failure of the microvascular anastomosis does not appear to be associated with clinical failure in all cases.

A number of our patients had bilateral osteonecrosis of the femoral head. Our concern originally was that by operating on the second hip within a year of the first we would compromise the results of the first hip by placing excessive demands on it. Although we did not find any difference between the first and second hips, we did find a higher failure rate in patients who underwent bilateral grafting. This may be due to a more aggressive clinical course of osteonecrosis in these patients or to some other unrecognized factor.

The initial and follow-up hip radiographs were scored according to the classification of Steinberg.³ It has generally been recognized that progressive collapse of the femoral head will occur after the development of a crescent sign or subchondral fracture on plain radiographs. Our procedure does not seem to reliably alter this progression. However, the correlation between clinical symptoms, decreased function and radiographic change is not clear, and patient outcome even when radiographic collapse is documented can be quite variable.

Whereas previous assessment methods have concentrated on radiographic scoring and joint-specific or disease-specific outcome measures, newer assessment techniques include patient-oriented health status questionnaires such as the SF-36³³ or the NHP.³⁰ Scored against standardized normative controls, vascular fibular graft patients had SF-36 scores corresponding to "normal" function for the mental components of the test and good to moderate outcome for the physical component of the test. These

results compare favourably with those of patients treated for low back pain and thoracolumbar burst fractures and are superior to scores from patients with diabetes or on renal dialysis.³¹ The NHP scores show gratifyingly good results in the "sleep" category, which corresponds clinically to the relief of night or rest pain usually seen with this procedure. The remainder of the NHP scores are quite favourable, approaching the level seen with THA in most categories.³² Outcome studies of this nature are important to augment comparison of different medical and surgical interventions and their impact on a patient's quality of life, especially as competition for scarce medical resources intensifies.

Donor-site morbidity after the harvesting of a fibular graft has been the subject of previous studies.^{16,36,41-45} In a separate study examining the effect of the fibular harvest on the patient, we found that the patients in our series are, for the most part, satisfied with the appearance, function and lack of discomfort of the lower leg after fibular transfer.³⁶

CONCLUSIONS

Although it did not reliably prevent radiographic progression of the disease, vascularized fibular grafting for osteonecrosis of the hip may provide satisfactory results in carefully selected patients. Due to the low morbidity associated with the operation, the clinical success rate, the preservation of the patient's own femoral head and the ease of conversion to THA if failure occurs, vascularized fibular grafting remains our procedure of choice for osteonecrosis of the femoral head in appropriately selected young patients.

References

1. Ficat RP. Idiopathic bone necrosis of the femoral head. *J Bone Joint Surg [Br]* 1985;67(1):3-9.
2. Jones JP Jr. Osteonecrosis. In: McCarty DJ, Koopman WJ, editors. *Arthritis and allied conditions: a textbook of rheumatology*. 12th ed. Philadelphia: Lea & Febiger; 1993. p. 1677-96.
3. Steinberg ME. Avascular necrosis of bone. *Ann Roy Coll Physicians Surg Can* 1989;22(5):323-6.
4. Ueno R, Akamatsu N, Itami Y, Tagawa H, Yoshino S, editors. *The hip: clinical studies and basic research*. New York: Elsevier Science Publishers; 1984. p. 163-75, 184-92.
5. Urbaniak JR, editor. *Microsurgery for major limb reconstruction*. Toronto: CV Mosby; 1987. p. 179-99, 205-8.
6. Dean MT, Cabanela ME. Trans-trochanteric anterior rotational osteotomy for avascular necrosis of the femoral head. Long-term results [see comment]. *J Bone Joint Surg [Br]* 1993;75(4):597-601. Comment in: *J Bone Joint Surg [Br]* 1994;76(3):505.
7. Schemitsch EH, Tsang G, Morton J, Harrison M, Waddell JP. Cementless total hip arthroplasty in patients with avascular necrosis. In: Canadian Orthopaedic Association: *Proceedings of the Canadian Orthopaedic Association meeting, Quebec, May 26, 1996*. Montreal: The Association, 1996; p. 99.
8. Koo K, Kim R, Ko GH, Song HR, Jeong ST, Cho SH. Preventing collapse in early osteonecrosis of the femoral head. A randomised clinical trial of core decompression [see comment]. *J Bone Joint Surg [Br]* 1995; 77(6):870-4. Comment in: *J Bone Joint Surg [Br]* 1996;78(4):681-2.
9. Melzer C, vd Boom H, Manz P. Operative treatment of femoral head necrosis. *Arch Orthop Trauma Surg* 1992;111(2):85-90.
10. Baksi DP. Treatment of osteonecrosis of the femoral head by drilling and muscle-pedicle bone grafting. *J Bone Joint Surg [Br]* 1991;73(2):241-5.
11. Bakx PA, van Biezen FC, van Linge B. Failure of tibial bone grafting for femoral head necrosis. *Acta Orthop Scand* 1991;62(3):230-1.
12. Brown TD, Pedersen DR, Baker KJ, Brand RA. Mechanical consequences of core drilling and bone-grafting on osteonecrosis of the femoral head. *J Bone Joint Surg [Am]* 1993;75(9): 1358-67.
13. Buckley PD, Gearen PF, Petty RW. Structural bone-grafting for early atraumatic avascular necrosis of the femoral head. *J Bone Joint Surg [Am]* 1991;73(9):1357-64.
14. Weiland AJ. Vascularized free bone transplants. *J Bone Joint Surg [Am]* 1981;63(1):166-9.
15. Rosenwasser MP, Garino JP, Kiernan HA, Michelsen CB. Long term follow up of thorough debridement and cancellous bone grafting of the femoral head for avascular necrosis. *Clin Orthop* 1994;306:17-27.
16. Goh JCH, Lee EH, Ang EJ, Bayon P, Pho RWH. Biomechanical study on the load bearing characteristics of the fibula and the effects of fibular reconstruction. *Clin Orthop* 1992;279:223-8.
17. Scher MA, Jakim I. Intertrochanteric osteotomy and autogenous bone-grafting for avascular necrosis of the femoral head. *J Bone Joint Surg [Am]* 1993;75(8):1119-33.
18. Sugano N, Takaoka K, Ohzono K, Matsui M, Saito M, Saito S. Rotational osteotomy for non-traumatic avascular necrosis of the femoral head. *J Bone Joint Surg [Br]* 1992;74(5):734-9.
19. Sugioka Y, Hotokebuchi T, Tsutsui H. Transtrochanteric anterior rotational osteotomy for idiopathic and steroid-induced necrosis of the femoral head. *Clin Orthop* 1992;277:111-20.
20. Alpert B, Waddell JP, Morton J, Bear RA. Cementless total hip arthroplasty

- in renal transplant patients. *Clin Orthop* 1992;284:164-9.
21. Collis DK. Cemented total hip arthroplasty in patients who are less than fifty years old. *J Bone Joint Surg [Am]* 1984;66(3):353-9.
 22. Cornell CN, Salvati EA, Pellicci PM. Long-term follow-up of total hip replacement in patients with osteonecrosis. *Orthop Clin North Am* 1985; 16:757-69.
 23. Saito S, Saito M, Nishina T, Ohzono K, Ono K. Long-term results of total hip arthroplasty for osteonecrosis of the femoral head. *Clin Orthop* 1989;244:198-207.
 24. Brunelli G, Brunelli G. Free microvascular transfer for idiopathic femoral head necrosis: long-term follow-up. *J Reconstr Microsurg* 1991;7(4):285-95.
 25. Fujimaki A, Yamauchi Y. Vascularized fibular grafting for treatment of aseptic necrosis of the femoral head — preliminary results in four cases. *Microsurgery* 1983;4(1):17-22.
 26. Malizos KN, Soucacos PN, Beris AE, Korobilias AB, Xenakis TA. Osteonecrosis of the femoral head in immunosuppressed patients: hip salvaging with implantation of a vascularized fibular graft. *Microsurgery* 1994;15: 485-91.
 27. Richards RR. Bone grafting with microvascular anastomosis in osteonecrosis of the femoral head. *Semin Arthroplasty* 1991;2(3):198-207.
 28. Urbaniak JR, Coogan PG, Gunneson EB, Nunley JA. Treatment of osteonecrosis of the femoral head with free vascularized fibular grafting. *J Bone Joint Surg [Am]* 1995;77(5): 681-94.
 29. Yoo MC, Chung DW, Hahn CS. Free vascularized fibula grafting for the treatment of osteonecrosis of the femoral head. *Clin Orthop* 1992;277: 128-38.
 30. Hunt SM, McKenna SP, McEwen J, Williams J, Papp E. The Nottingham Health Profile: subjective health status and medical consultations. *Soc Sci Med [A]* 1981;15(3 Pt 1):221-9.
 31. Kramer WJ, Schemitsch EH, Lever J, McBroom RJ, McKee MD, Waddell JP. Functional outcome of thoracolumbar burst fractures without neurological deficit. *J Orthop Trauma* 1996;10(8):541-5.
 32. Nilsson LT, Frazen H, Carlsson AS, Onnerfalt R. Early radiographic loosening impairs the function of a total hip replacement. The Nottingham Health Profile of 49 patients at five years. *J Bone Joint Surg [Br]* 1994; 76(2):235-9.
 33. Ware JE, Snow KK, Kosinski M, Gandek B. *SF-36 health survey manual and interpretation guide*. Boston: New England Medical Center, The Health Institute; 1993.
 34. Harris WH. Traumatic arthritis of the hip after dislocation and acetabular fractures: treatment by mold arthroplasty. An end-result study using a new method of result evaluation. *J Bone Joint Surg [Am]* 1969;51(4):737-55.
 35. Malizos KN, Quarles LD, Seaber AV, Rizk WS, Urbaniak JR. Analysis of failed grafts in femoral head necrosis treated with implantation of vascularized fibula. *Proceedings of the American Association of Orthopaedic Surgeons*. Orlando, Fla, Feb. 20, 1995. p. 245
 36. Tang CL, Mahoney JL, McKee MD, Richards RR, Waddell JP, Louie B. Donor site morbidity following vascularized fibula grafting. *Microsurgery* 1998;18(6):383-6.
 37. Iwata H, Torii S, Hasegawa Y, Itoh H, Mizuno M, Genda E, et al. Indications and results of vascularized pedicle iliac bone graft in avascular necrosis of the femoral head. *Clin Orthop* 1993;295: 281-8.
 38. Smith SW, Fehring TK, Griffin WL, Beaver WB. Core decompression of the osteonecrotic femoral head. *J Bone Joint Surg [Am]* 1995;77(5):674-9.
 39. Koo KH, Kim R. Quantifying the extent of osteonecrosis of the femoral head. A new method using MRI [see comment]. *J Bone Joint Surg [Br]* 1995; 77(6):875-80. Comment in: *J Bone Joint Surg [Br]* 1996;78(4):681-2.
 40. Shimizu K, Moriya H, Sakamoto M, Suguro T. Prediction of collapse with magnetic resonance imaging of avascular necrosis of the femoral head. *J Bone Joint Surg [Am]* 1994;76(2):215-23.
 41. Coghlan BA, Townsend PLG. The morbidity of the free vascularised fibula flap. *Br J Plast Surg* 1993;46:466-9.
 42. Goodacre TEE, Walker CJ, Jawad AS, Jackson AM, Brough MD. Donor site morbidity following osteocutaneous free fibula transfer. *Br J Plast Surg* 1990;43:410-2.
 43. Gore DR, Gardner GM, Sepic SB, Mollinger LA, Murray MP. Function following partial fibulectomy. *Clin Orthop* 1987;220:206-10.
 44. Lee EH, Goh JCH, Helm R, Pho RWH. Donor site morbidity following resection of the fibula. *J Bone Joint Surg [Br]* 1990;72(1):129-31.
 45. Vail TP, Urbaniak JR. Donor Site morbidity with use of vascularized autogenous fibular grafts. *J Bone Joint Surg [Am]* 1996;78(2):204-11.