

# Oligoclonal populations of T and B cells in a case of angioimmunoblastic T-cell lymphoma predominantly infiltrated by T cells of the VB5.1 family

E Hodges, C T Quin, D H Wright, J L Smith

## Abstract

**Aims**—Immunohistological and molecular characterisation of a case of peripheral T-cell lymphoma (PTCL) of angioimmunoblastic T-cell lymphoma (AILD) type.

**Methods**—Frozen and paraffin wax sections of the diagnostic lymph node were stained with a panel of T- and B-cell lineage monoclonal antibodies. DNA was isolated from the paraffin wax embedded biopsy material for T-cell receptor (TCR) and immunoglobulin (Ig) PCR amplification, and resultant PCR products were cloned and sequenced.

**Results**—Immunohistological analysis of the presenting lymph node was consistent with an extensive infiltrate of pleomorphic CD3+CD8+ lymphocytes. Most (>80%) of these infiltrating CD3+ cells were also positive for the TCR VB5.1 gene family product, and were shown to be oligoclonal by TCRB PCR amplification and sequencing. Three oligoclonal B cells were also demonstrable by PCR amplification with Ig heavy chain primers and sequencing, a finding at variance with the diagnosis of AILD.

**Conclusions**—These data demonstrate the complexity and heterogeneity of PTCL which require extensive histological examination and molecular characterisation.

(J Clin Pathol: Mol Pathol 1997;50:15-17)

## Methods

Frozen and paraffin wax sections were stained with monoclonal antibodies including those directed against CD3, CD4, CD8, CD20, and CD79a, and KiM4B (dendritic cells), MIB1 (proliferation marker), BF1 (TCRB chain), LC4 (VB5.1), ICI (VB5.2 + 5.3), W112 (VB5.3), OT145 (VB6.7 A allele), 16G8 (VB8), and S511 (VB12.1) as described previously.<sup>2</sup> Positively stained cells were counted using a visual image display system. Monoclonal antibody directed against Epstein-Barr virus (EBV) latent membrane protein 1 (LMP-1) and in situ hybridisation (EBV probe kit; Novocastra Laboratories, Newcastle upon Tyne, UK) were used to detect infected cells.

DNA was isolated from paraffin wax embedded biopsy material for TCRG, B and IgH PCR amplification and sequencing using methods described previously.<sup>3</sup> Briefly, primer combinations VGJG and VGJGP were used for TCRG PCR analysis. The PCR reaction mixture consisted of 1 µg DNA, 50 pmols of each primer, 125 µM of each dNTP, and 1 unit Taq polymerase. Primer pairs VBJB2 and DB1JB2 were used for TCRB PCR analysis. The PCR reaction mixture consisted of 1 µg DNA, 68 pmols of each primer, 200 µM of each dNTP, 10 µl bovine serum albumin (BSA; 1 mg/ml), and 1 unit Taq polymerase. TCRG and TCRB PCR conditions were 93°C for one minute, 52°C (TCRB) or 55°C (TCRG) for one minute, and 73°C for one minute for 35 (TCRB) and 30 (TCRG) cycles. PCR products were electrophoresed on a 10% polyacrylamide gel and stained with ethidium bromide.

Primers VB5.1, JB1 and JB2 were used for TCR VB5.1 PCR amplification for subsequent sequence analysis. The PCR reaction mixture consisted of 1 µg DNA, 250 ng each primer, 200 µM each dNTP, 10 µl BSA (1 mg/ml), 3 mM MgCl<sub>2</sub>, and 1 unit Taq polymerase. PCR conditions, using the hot start method, were 93°C for one minute, 60°C for one minute, and 73°C for one minute for 30 cycles. PCR products were electrophoresed on a 7% polyacrylamide gel.

Semi-nested PCR amplification was used for immunoglobulin (Ig) FR2 PCR analysis using primers FR2 LJH in the first round and FR2 VLJH in the second round. The first round PCR reaction mixture consisted of 250 ng DNA, 20 pmol of each primer, 200 µM each

Keywords: peripheral T-cell lymphoma; PCR; oligoclonal.

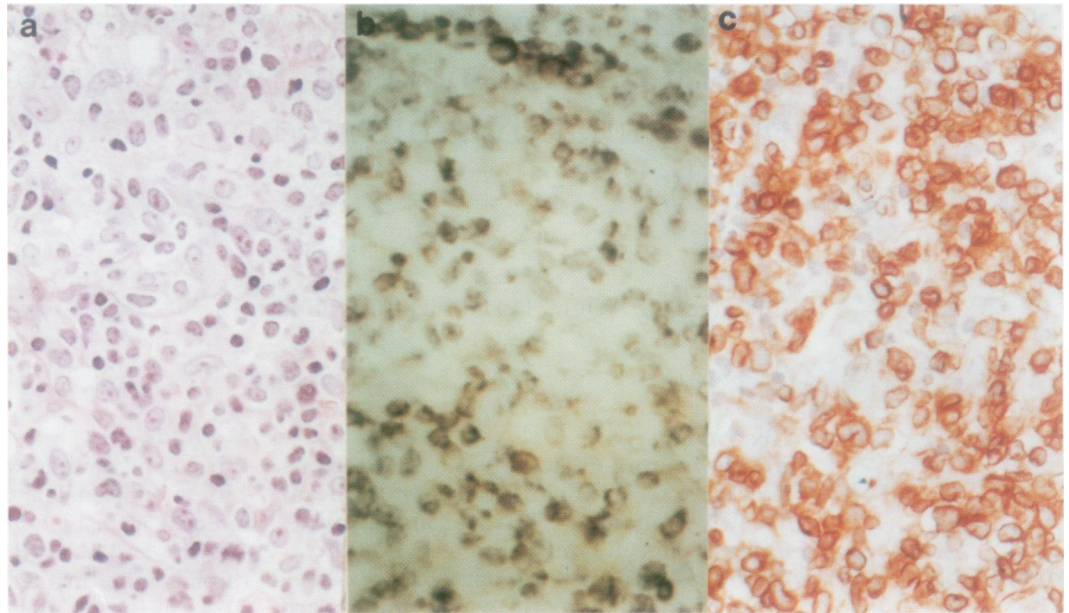
An 82 year old woman presented in March 1987 with a one month history of neck swelling, rashes and night sweats. Examination revealed a cervical mass and a chest x ray film revealed a widened mediastinum. A lymph node biopsy specimen was taken and the histology was consistent with a peripheral T-cell lymphoma (PTCL) of angioimmunoblastic T-cell lymphoma (AILD) type.<sup>1</sup> At the time of diagnosis, no particular therapeutic recommendations were in force and the patient was treated with chlorambucil. Despite regression of nodal masses, the patient became leucopenic and thrombocytopenic. Chlorambucil was withdrawn but the patient's clinical condition continued to deteriorate and she died seven months after presentation.

**Molecular Immunology Group, Wessex Immunology Service, Southampton University Hospitals NHS Trust**  
E Hodges  
C T Quin  
J L Smith

**University Department of Pathology**  
D H Wright

Correspondence to:  
Dr E Hodges, Molecular Immunology Group, Wessex Immunology Service, Southampton University Hospitals NHS Trust, Tremona Road, Southampton SO16 6YD.

Accepted for publication  
8 October 1996



**Figure 1** High power sections of the lymph node stained with (a) haematoxylin and eosin, (b) TCR VB5.1 and (c) for CD3. There is intense membrane staining of the T cells in (c) and a predominant proportion of these T cells stained with the VB5.1 monoclonal antibody in (b). Staining was assessed over the total area of the tissue section using a visual display system as described in Methods.

dNTP, 3.5 mM MgCl<sub>2</sub>, and 1 unit Taq polymerase. The second round PCR reaction mixture consisted of 0.5 µl of the primary PCR products, 1.5 mM MgCl<sub>2</sub>, and 0.5 units Taq polymerase. PCR conditions were 93°C for 45 seconds, 50°C for 45 seconds, and 72°C for 110 seconds for 30 (first round)/20 (second round) cycles. PCR products were electrophoresed on a 5% polyacrylamide gel.

TCRG, TCRB and Ig FR2 PCR products were blunt-end ligated into pGEM-TA vector (Promega, Southampton, UK) and transformed into JM109 competent cells (Promega). Clones were randomly selected for each case. Single stranded DNA was prepared and sequenced using the dideoxy chain termination method with sequenase (Amersham, Buckinghamshire, UK) and M13 primers. Sequence data were analysed using Genbank and current databases with MacVector 4.1 sequence analysis software.

## Results

Immunohistology revealed an actively dividing CD3+, predominantly CD8+ pleomorphic T-cell population with absent B-cell follicles; about 80% of the CD3+ cell population was positive for TCR VB5.1 (fig 1). Immunohistol-

ogy of paraffin wax embedded tissue confirmed a predominant infiltrating pleomorphic T-cell population, and staining with the proliferative marker MIB-1 revealed active cell division among the T-cell population. B cells were not predominantly positive for either immunoglobulin κ or λ light chain, and histologically atypical B cells staining for CD79a or CD20 were not identified in paraffin wax sections. EBV infected cells were not detected by immunostaining for LMP-1, nor by in situ hybridisation with the EBER probe.

PCR amplification with TCRG primers resulted in two clonal PCR bands in a polyclonal smear, as visualised on the polyacrylamide gels. TCRB PCR amplification with consensus VB and VB5.1 family primers resulted in a polyclonal smear and two bands in a polyclonal smear, respectively. The two TCRG clonal products (67 bp and 75 bp) were cloned, and sequenced and a predominant sequence was found in three of six and four of six clones, respectively. Both clones used one of the VGI subgroup genes but the exact gene could not be identified as sufficient VG gene sequence data were not available. The deduced amino acid sequences of these clones are shown in table 1, and revealed a stop codon in the V to J junctional regions and were non-functional. The cloning of specific VB5.1 PCR products revealed two functional sequences, consisting of four and three identical clones, respectively (table 1)

IgH FR2 PCR amplification revealed two clonal bands on a faint polyclonal smear by polyacrylamide gel electrophoresis; one band was very intense (251 bp) and the other was faint (243 bp). On sequencing the IgH FR2 PCR reaction mixture, three clones with functional sequences consisting of four, three and two identical clones were identified; the deduced amino acid sequences are shown in table 1.

**Table 1** PCR and sequence data

Loci	Primers	Size of clonal band(s) (bp)	Deduced amino acid sequence of clonal products	
			----- CDR3 region -----	n
TCRG	VG/JG	67, 75	#SGVYYCATW*PKRNSLAVEQHL	3/6
			#SGVYYCATWDRTVL*ETLWQWNNT	4/6
IgH	FR2/JH	251, 243, 229	TAVYYCAKDGSGSYEGNYFDYW	4/16
			TAVYYCARAEPDSSFDYWGQGTL	3/16
			TAVYYCARDLGYWGQGTLV	2/16
			CASSLAGGGADEQFFGPGTRLTLV	4/8
TCRB	VB5.1/JB	197, 200	CASSWTGLGLYNEQFFGPGTRLTLV	3/8

\*Stop codon; #non-functional sequences; n = number of identical clones/total number of clones.

## Discussion

The immunohistology of the case described in this report was consistent with AILD with a predominant CD3+ pleomorphic cell population and a network of dendritic cells in the absence of B-cell follicles. However, a predominance of CD8+ compared with CD4+ cells was noted in contrast to other cases.<sup>1</sup> The most remarkable finding in this case was the presence of an expanded TCR VB5.1 family comprising >80% of the CD3+ population. There was no histological evidence for abnormal B cells positive for CD79a and CD20 on paraffin wax sections.

The molecular analysis of this case was complex. PCR amplification of DNA with a consensus VB primer revealed polyclonal smears on electrophoresis, whereas PCR amplification with a VB5.1 family primer identified two minor bands that, on sequencing, revealed two functional clones consistent with oligoclonal among the TCR VB5.1 population. These oligoclonal were not identified using the consensus VB primer owing to the lack of homology of the VB primer, which has a mismatch of three of 19 bases with the VB5.1 family sequence.<sup>4</sup> Analysis of TCRG PCR products revealed two bands in a polyclonal background. Both clonal rearrangements proved to be non-functional; such data are consistent with TCRAB expressing T cells. Alternatively, these non-functional rearrangements may be associated with the oligoclonal B-cell populations identified.

IgH FR2 PCR amplification revealed two clonal bands whereas sequence analysis of the IgH FR2 PCR reaction mixture revealed three functional immunoglobulin VH3 family clonal sequences; these data are consistent with oligoclonal B-cell populations rather than somatic mutations within a single tumour population.<sup>5</sup> The molecular weights of two of the clones, as judged from sequence analysis, corresponded to the two bands demonstrated by gel electrophoresis. A third minor clone, which was not clearly visible by gel electrophoresis, was identified after sequence analysis. In a previous study, we detected oligoclonal in a diffuse, high grade B-cell lymphoma<sup>3</sup> but have never demonstrated oligoclonal from PCR amplification of normal human peripheral blood. These PCR data are supportive evidence for the T- and B-cell oligoclonal found in this patient.

The role of T- and B-cell oligoclonal in the disease pathogenesis of this case is uncertain. The clear demonstration of oligoclonal T-cell populations by PCR amplification is suggestive of reactive rather than malignant T-cell infiltrates. Polyclonal or oligoclonal restricted T-cell family responses have also been described in autoimmune diseases<sup>6</sup> in response to superantigens and among CD3/CD8 populations in the elderly.<sup>7</sup> Nevertheless, reports of expanded TCR V gene families in autoimmunity and in the elderly do not include aetiologies comparable with this case; and the patient did not have preexisting autoimmune

disease or evidence of neutropenia or red cell aplasia which are commonly associated with clonal CD3/CD8 lymphocyte populations.<sup>8</sup>

The presence of oligoclonal of B cells has not been described in B-cell non-Hodgkin lymphoma, and sequence analysis indicated the presence of different clones rather than somatic mutations within one clone. Such populations are found in EBV infiltrates although evidence of EBV infection was not found. Whether these populations represent neoplastic clones is not known in the absence of histological evidence for malignant B cells associated with T-cell-rich B-cell lymphoma. It is conceivable that these B-cell populations elicited an oligoclonal T-cell response as restricted TCR V gene family responses have been described in B-cell chronic lymphocytic leukaemia and myeloma.<sup>9</sup> Indeed, we have recently described an oligoclonal VB5.1 population in an immunoblastic B-cell lymphoma.<sup>3</sup>

In summary, a case of histologically defined PTCL is described in which, on molecular analysis, both T- and B-cell oligoclonal were detected in the presence of a predominant TCR VB5.1 T-cell family. In the absence of functional studies, the relation between the T- and B-cell oligoclonal in this case is open to speculation. These T-cell responses may be recognising shared tumour antigens or tumour related antigens. In the case described here, B-cell oligoclonal in the biopsy specimen may be presenting antigens that elicit such a T-cell response. Alternatively, the sustained T-cell response may be the result of cytokine networks described in patients with PTCL.<sup>10</sup> This case demonstrates further the complexity and heterogeneity of this histological entity.

Supported by grants from the Leukaemia Research Fund and from the South and West Regional Health Authority. We thank Dr B Wilkins for additional review of histology.

- Harris NL, Jaffe ES, Stein H, Banks PM, Chan JKC, *et al.* A revised European-American classification of lymphoid neoplasms: A proposal from the International Lymphoma Study Group. *Blood* 1994;84:1361-2.
- Smith JL, Lane AC, Hodges E, Reynolds WM, Howell WM, Jones DB, *et al.* T-cell receptor variable (V) gene usage by lymphoid populations in T-cell lymphoma. *J Pathol* 1992;166:109-12.
- Hodges E, Swindell AM, Quin CT, Lane AC, Jones DB, Sweetenham J, *et al.* Expanded TCRV $\beta$ 5.1 family in a diffuse high grade B cell immunoblastic lymphoma. *Leukemia* 1995;9:1108-12.
- McCarthy KP, Sloane JP, Kabarowski JHS, Matutes E, Wiedemann LM. The rapid detection of clonal T-cell proliferations in patients with lymphoid disorders. *Am J Pathol* 1991;138:821-8.
- Schroeder HW, Dighiero G. The pathogenesis of chronic lymphocytic leukaemia: analysis of the antibody repertoire. *Immunol Today* 1994;15:288-94.
- Hafler DA, Saadeh MG, Kuchroo VK, Milford E, Steinman L. TCR usage in human and experimental demyelinating disease. *Immunol Today* 1996;17:152-9.
- Posnett DN, Sinha R, Kabak S, Russo C. Clonal populations of T cells in normal elderly humans: The T cell equivalent to 'benign monoclonal gammopathy'. *J Exp Med* 1994;179:609-18.
- Loughran TP. Clonal diseases of large granular lymphocytes. *Blood* 1993;82:1-14.
- Janson CH, Grunwald J, Osterberg A, Der Simonian H, Brenner MB, Mellstedt H, *et al.* Predominant T cell receptor V gene usage in patients with abnormal clones of B cells. *Blood* 1991;77:1776-80.
- Raziuddin S, Abu ES, Sheikh A. Peripheral T-cell lymphomas. Immunoregulatory cytokine (interleukin-2, interleukin-4, and interferon-gamma) abnormalities and autologous mixed lymphocyte reaction. *Cancer* 1994;74:2843-9.