

Successful Prognosis of Brain Abscess during Pregnancy

Masashi Yoshida^{1*}, Hideo Matsuda², Kenichi Furuya¹

1- Department of Obstetrics and Gynecology, National Defense Medical College, Saitama, Japan

2- Division of Perinatology, Matsuda Perinatal Clinic, Saitama, Japan

Abstract

Introduction: Brain abscess in pregnancy is very rare, which mostly progresses to neurological abnormalities.

Case Presentation: The patient is a 24-year-old pregnant woman. She was referred to Saitama hospital due to severe headache and nausea on October 2008. Brain MRI detected a 1.5 cm abscess mass with extensive edema in the right frontal lobe. We performed intensive therapy using some antibiotics that included cefotaxime and meropenem and depressants for intracranial pressure for six weeks. There was a good prognosis for the woman and her fetus without any sign of neurological abnormalities.

Conclusion: Early medical intervention is required before it is too late for brain abscess in pregnancy.

Keywords: Brain abscess, Magnetic Resonance Imaging (MRI), Pregnancy.

To cite this article: Yoshida M, Matsuda H, Furuya K. Successful Prognosis of Brain Abscess during Pregnancy. *J Reprod Infertil.* 2013;14(3):152-155.

* Corresponding Author:
Masashi Yoshida, Department of Obstetrics and Gynecology, National Defense Medical College 3-2 Namiki, Tokorozawa, 3598513 Saitama, Japan
E-mail:
dr22023@ndmc.ac.jp

Received: May 23, 2013

Accepted: Jul. 10, 2013

Introduction

Brain abscess caused by bacterial infection has extremely low incidence, and a high mortality rate of 30%. It causes poor prognosis for both mother and fetus, regardless of the state of pregnancy. Unlike non-pregnant women, infection tends to be severe because the immunity power diminishes in pregnant women.

Case Presentation

A 24-year-old woman who lived in Saitama, Japan had three pregnancies, two childbirths, body mass index (BMI) of 22.3, and unremarkable past medical and family histories. Furthermore, her pre pregnancy weight was 55 kg and her height 163 cm.

She also had an uneventful first trimester, but developed a fever of $>39^{\circ}\text{C}$ at 22nd week, 1st day of pregnancy. Because of prolonged headache and nausea, she was referred to our hospital in Saitama for complete physical examination on October 2008. On admission, she had blood pressure of 103/51 mmHg, heart rate of 100 beats per min (bpm), body temperature of 39.0°C , mild stiffness

in the neck, and cold extremities. No neurological abnormalities, such as consciousness disturbance or paralysis, were observed. However, brain computed tomography (CT) for the prolonged headache revealed a 1.5 cm mass in the right frontal lobe, while hematological analysis showed an elevated white blood cell count of 12,400 cells/ μl (neutrophils, 87.7%). Cerebrospinal fluid findings were positive for gram-positive bacteria, an increased cell count (especially for neutrophils) of 2,332 cells/ μl , and a low glucose concentration of 30 mg/dl. Brain MRI revealed a 1.5 cm mass with a high intensity signal inside and a low intensity T2 signal on the margin in the deep white matter of the right frontal lobe. Based on the above findings and a high intensity zone surrounding the mass on diffusion-weighted images, she was immediately placed on intensive therapy with concurrent administration of antibiotics cefotaxime (2 g/day) and meropenem (3 g/day), as well as glycerin 20 g/day to reduce intracranial pressure. Table 1 shows a list of examinations performed in search of causal factors, while the results show the

Table 1. Causes of brain abscess

Location	Method	Result
Pharynx		
	Culture	MSSA, Corynebacterium
	Antigen reaction	Influenza virus: negative
Nasal discharge	Culture	CNS, Corynebacterium
Blood	Culture	Negative
Merigial flood	Culture	Negative, Cell count: 2352/ μ l, Glucose: 30 mg/dl
Unite	Culture	Negative
Vaginal discharge	Culture	Negative
Heart	Ultrasound	Infectious endocarditis: not detected
Tooth	CT	Dental caries: not detected
Lung	CT, Ultrasound	Abscess or inflammation: not detected

MSSA: methicillin-sensitive staphylococcus aureus, CNS: coaglesse negative staphylococcus

isolation of methicillin-sensitive *Staphylococcus aureus* (MSSA) from the throat. On the other hand, she had no dental problems. Because of unremarkable upper gastrointestinal endoscopy findings and a negative fecal occult blood test result, the possibility of brain metastasis of a malignant tumor was ruled out. After six weeks of intensive therapy with concurrent administration of two antibiotics and glycerin, the headache and nausea disappeared along with a reduction in the number of white blood cells. Subsequent brain MRI at 28th week, 4th day of pregnancy showed no enlargement of the abscess and disappearance of the surrounding edema, with no indication of puncture drainage. At this point, she was switched to oral administration of amoxicillin 750 mg/day for four weeks and was discharged at 29th week, 3rd day of pregnancy. Figure 1 shows the post admission course.

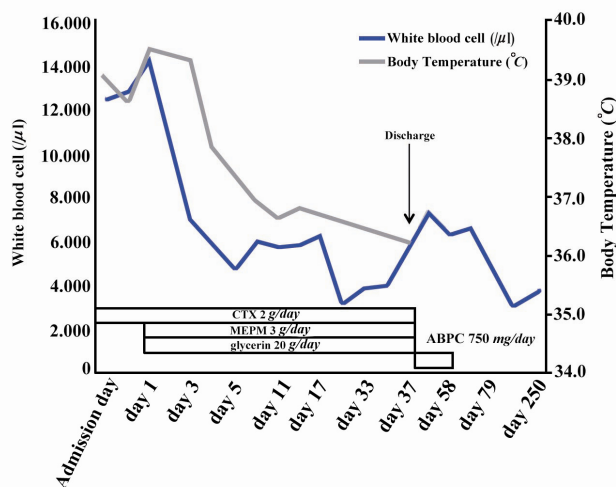


Figure 1. Course of treatment. Body temperature slowed down after the day 7

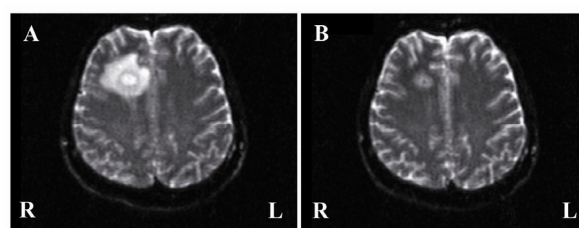


Figure 2. Magnetic resonance images of the brain abscess. Both images are taken by diffusion weighed imaging. A: Axial image at 22nd week of pregnancy shows the large right frontal abscess with severe edema. B: Axial image at 28th week of pregnancy shows no enlargement of the abscess and disappearance of the surrounding edema

She vaginally delivered a 2,890 g girl baby at 38th week, 5th day of pregnancy, with no abnormalities. No neurological abnormalities were evident during a five-year follow-up observation conducted over the phone.

MRI findings at the 22nd and 28th week of pregnancy are shown in figure 2.

Discussion

Despite the extremely low incidence, brain abscess caused by bacterial infection has a high mortality rate of 30% and is therefore a disease with poor prognosis for both mother and fetus, regardless of the state of pregnancy. Although we listed previous reports on brain abscess during pregnancy (Table 2), it should be noted that the number is extremely small (1–6). Approximately, 7% of the previous cases were related to dental treatment (7), but no dental abnormalities were observed in the present case. During the pregnancy, maternal immunity is reduced due to a hormonal imbalance, and according to Lanciers et al., 26.6% of

Table 2. Brain abscess in pregnancy (Literature review)

Author	Age	Diagnosis	Location of brain abscess	Cell culture	Internal treatment	Surgical treatment	Neurological prognosis
Braun TI (1991)	25	16 GW	Left occipital lobe	Nocardia asteroides	Sulfisozazole, ampicillin, ceftriaxone	Left occipital craniotomy	No residual neurologic deficit
Baxi LV	36	10 GW	Left basal ganglion	Propionobacterium acnes, staphylococcus capitis	Cefotaxime, ceftazime, vancomycin	None	Residual hemipares, amenorrhea
Wax (2004)		36 GW	Left temporal lobe	Not detected	Cefepime, vancomycin, metronidazole, dexamethasone, phosphenyntion	None	No influence
Kim HC (2007)	38	30 GW	Pituitary	Streptococcus viridians	None	Transsphenoidal microsurgical removal	No influence
Jacob CE (2009)	23	35 GW	Left cerebellar hemisphere	Pseudomonas aeruginosa	Penicillin, ciprofloxacin, trimethoprim/sufamethaxazole	Partial excision of the abscess, modified radical mastoidectomy	Dry left ear, with no residual hearing
Hobson DT(2011)	35	21 GW	Left frontal, temporal and parietal lobe	Bacteroides fragilis, Wolinella species, campylobacter gracilis, Prevotella buccae	Dexamethasone, ampicillin, cefotaxime, metronidazole, levetiracetam	Drainage, Lobectomy	Neurologic deficits which included broca's aphasia and apraxia with righ hemiplegia
Yoshida M(2013)	24	22 GW	Right frontal lobe	Methicillin sensitives staphylococcus aureus (MSSA)	Cefotaxime, meropenem, amoxicillin, glycerin	None	No influence

GW: gestational week

pregnant women, as opposed to 11.0% of non-pregnant women, are significantly infected with *Helicobacter pylori* (8). It goes without saying that organisms with low pathogenicity under normal circumstances can cause serious infection during pregnancy. In this case, the clear source of infection was not identified. It seems that the pregnant woman whose immunity was diminished is vulnerable to MSSA, which was extremely rare and considered as a serious case.

The symptoms of brain abscess include headache, nausea, and localized neurological abnormalities (9). Headache is the most common symptom, occurring in 75% of pregnant women, followed by 67% of neurological abnormalities and 58% of altered consciousness (10). Diagnostic imaging is useful for the diagnosis of a brain abscess. Although no adverse effects of MRI have been reported (11, 12), the CT should be avoided as much as possible because there are some problems about the degree of radiation exposure in pregnant women. Therefore, MRI may be a safer and is a highly sensitive diagnostic imaging modality for use in pregnancy (13). Yet, because of potential thermal tissue damage due to the high magnetic field, the National Radiological Protection Board recommends that pregnant women avoid MRI examination during the first trimester.

To treat a brain abscess, it is necessary to select antibiotics capable of effectively crossing the

blood brain barrier and their sensitivity should be proven in bacterial culture. The use of steroidal drug is also recommended to prevent an increase in intracranial pressure and the development of brain edema (13). However, because intensive therapy for a brain abscess with antibiotics and steroidal drugs takes somewhere between six to eight weeks, its effect on the fetus is a huge concern. Betamethasone and dexamethasone, which are transported via the placenta, should be avoided because they may affect the development of the fetal central nervous system. Furthermore, the early administration of antiepileptic drugs is recommended because 70 % of patients with a brain abscess develop epilepsy (13).

Conclusion

Even infection by vulnerable bacteria becomes serious and early treatment intervention is desirable because immunity power diminishes during the pregnancy.

Acknowledgement

We would like to acknowledge the contributions of many friends and colleagues. For this treatment, we would like to express our thanks to Dr. Masafumi Kato, Dr. Tadashi Aoyama.

Conflict of Interest

There is no potential conflict of interest for any

of the authors. No financial support was received for the treatment. Our treatment obtained ethics approval from the regional ethics committee responsible for human experimentation and conformed to the provisions of the Declaration of Helsinki.

References

- Braun TI, Kerson LA, Eisenberg FP. Nocardial brain abscesses in a pregnant woman. *Rev Infect Dis.* 1991;13(4):630-2.
- Baxi LV, Mayer SA, Mansukhani M. Cerebral abscess and thrombophilia in pregnancy. A case report. *J Reprod Med.* 2001;46(6):606-8.
- Wax JR, Blackstone J, Mancall A, Cartin A, Pinette MG. Sinogenic brain abscess complicating pregnancy. *Am J Obstet Gynecol.* 2004;191(5):1711-2.
- Kim HC, Kang SG, Huh PW, Yoo do S, Cho KS, Kim DS. Pituitary abscess in a pregnant woman. *J Clin Neurosci.* 2007;14(11):1135-9.
- Jacob CE, Kurien M, Varghese AM, Aleyamma TK, Jasper P, Prabu K, et al. Treatment of otogenic brain abscess in pregnancy. *Otol Neurotol.* 2009;30(5):602-3.
- Hobson DT, Imudia AN, Soto E, Awonuga AO. Pregnancy complicated by recurrent brain abscess after extraction of an infected tooth. *Obstet Gynecol.* 2011;118(2 Pt 2):467-70.
- Pallasch TJ, Slots J. Antibiotic prophylaxis and the medically compromised patient. *Periodontol* 2000. 1996;10:107-38.
- Lanciers S, Despinasse B, Mehta DI, Blecker U. Increased susceptibility to *Helicobacter pylori* infection in pregnancy. *Infect Dis Obstet Gynecol.* 1999;7(4):195-8.
- Yang SY. Brain abscess: a review of 400 cases. *J Neurosurg.* 1981;55(5):794-9.
- Wax JR, Pinette MG, Blackstone J, Cartin A. Brain abscess complicating pregnancy. *Obstet Gynecol Surv.* 2004;59(3):207-13.
- Duncan KR. The development of magnetic resonance imaging in obstetrics. *Br J Hosp Med.* 1996;55(4):178-81.
- Nicklas AH, Baker ME. Imaging strategies in the pregnant cancer patient. *Semin Oncol.* 2000;27(6):623-32.
- Lu CH, Chang WN, Lui CC. Strategies for the management of bacterial brain abscess. *J Clin Neurosci.* 2006;13(10):979-85.