

# Long segment jejuno-ileal duplication cyst with ectopic gastric mucosa detected on $^{99m}\text{Tc}$ -pertechnetate scintigraphy

Anish Bhattacharya, Ram Samujh<sup>1</sup>, Katragadda Lakshmi Narasimha Rao<sup>1</sup>, Bhagwant Rai Mittal

Departments of Nuclear Medicine and <sup>1</sup>Pediatric Surgery, Post Graduate Institute of Medical Education and Research, Chandigarh, India

**ABSTRACT** Enteric duplication cysts (EDC) are uncommon congenital anomalies that may occur anywhere along the digestive tract. Ectopic gastric mucosa (EGM), another rare condition, is usually present as short segments in the small intestine and may be associated with EDC. Abdominal scintigraphy with  $^{99m}\text{Tc}$  pertechnetate may be useful in the diagnosis, since the radiotracer is concentrated by functioning gastric mucosa. In this case report, the authors describe a child with a 150 cm long jejuno-ileal duplication cyst containing EGM identified by intense  $^{99m}\text{Tc}$  pertechnetate uptake on scintigraphy without any pharmacological intervention.

**Keywords:** Ectopic gastric mucosa, enteric duplication, pertechnetate, scintigraphy

## INTRODUCTION

Enteric duplication cysts (EDC) are uncommon congenital anomalies that generally occur in the small intestine. Ultrasonography (USG) and computerized tomography are the usual imaging modalities employed to make a diagnosis.  $^{99m}\text{Tc}$  pertechnetate is concentrated by ectopic gastric mucosa (EGM) that may occur in these cysts and scintigraphy using this radiotracer may be a useful modality in the pre-operative diagnosis of this rare anomaly.

## CASE REPORT

A 6-year-old male child operated for exstrophy of the urinary bladder 4 years back presented with a 10 days history of fever, vomiting, abdominal pain and hematochezia. At presentation, hemoglobin was 10 g/100 ml and total leucocyte count 10,200/mm<sup>3</sup> with normal coagulation parameters. Suspecting a Meckel's diverticulum, dynamic abdominal scintigraphy was performed

under a gamma camera for 20 min after intravenous injection of 37 MBq (1 mCi) of  $^{99m}\text{TcO}_4^-$  (pertechnetate). Tracer uptake was seen in the central abdomen, corresponding to the shape of the small intestinal loops. The intensity was seen to increase simultaneously with that of the stomach, indicative of extensive ectopic functioning gastric mucosa [Figure 1]. USG showed a large well defined bean-shaped cystic lesion in the left lumbar region with a positive gut signature and internal debris and echoes, suggestive of an infected EDC. Exploratory laparotomy was performed and a 150 cm long tubular jejuno-ileal duplication cyst communicating with the ileal lumen was excised [Figures 2 and 3]. Presence of EGM in the cyst was confirmed on histopathology, which showed hyperplastic gastric lining epithelium, with viliform transformation at places [Figure 4] and marked edema and vascular congestion in the submucosa. However, the patient's condition deteriorated post-operatively, and the child died of septicemia 9 days after surgery.

## DISCUSSION

EDC are uncommon congenital anomalies, may be single or multiple and may occur anywhere along the digestive tract on the mesenteric side. The small intestine accounting for about 50% of all lesions is the most commonly involved. Two thirds of the lesions are ileal in location and one-third jejunal.<sup>[1,2]</sup> The lumen of the duplication is usually not in continuity with the normal intestine; however, the two structures share a

### Access this article online

#### Quick Response Code:

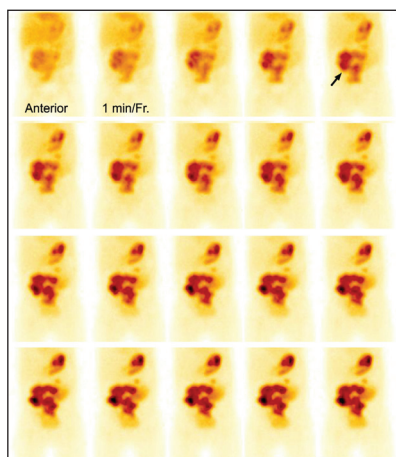


Website:  
www.ijnm.in

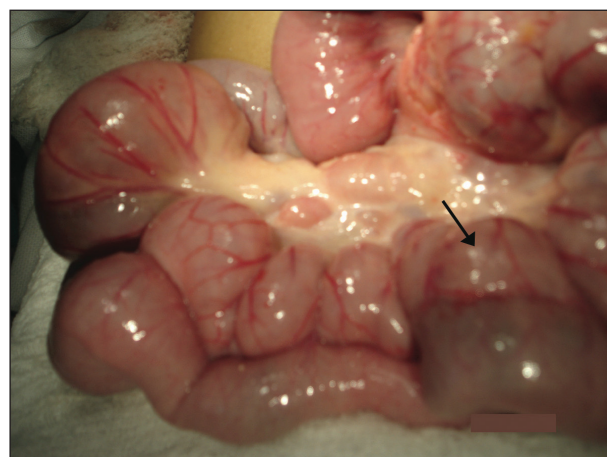
DOI:  
10.4103/0972-3919.118260

### Address for correspondence:

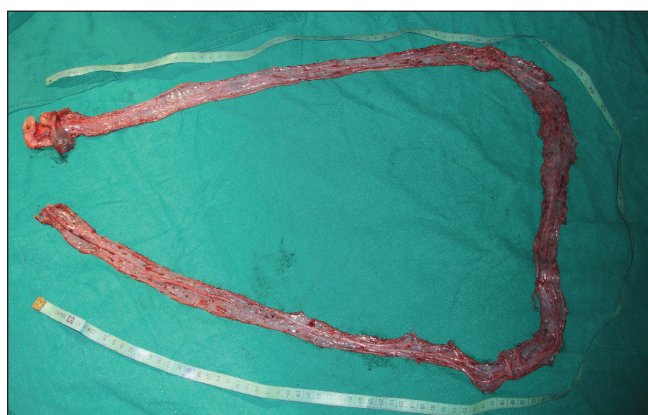
Dr. Anish Bhattacharya, Department of Nuclear Medicine, Post Graduate Institute of Medical Education and Research, Chandigarh - 160 012, India.  
E-mail: anishpgi@yahoo.co.in



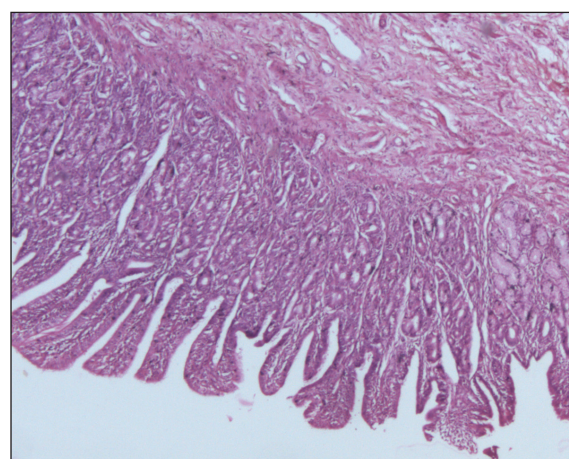
**Figure 1:** 99mTc pertechnetate scintigraphy showing increased tracer concentration in the central abdomen (arrow) corresponding to the small bowel. The intensity is seen to increase simultaneously with that of the stomach indicative of ectopic functioning gastric mucosa



**Figure 2:** Operative photograph showing the duplicated small bowel (arrow)



**Figure 3:** The entire excised duplication cyst measured post-operatively



**Figure 4:** Histological section from the cystic duplication showing hyperplastic gastric lining epithelium, with villiform transformation with submucosal edema and vascular congestion

portion of the muscular coat and vascular supply.<sup>[3]</sup> Presenting symptoms include abdominal distention, vomiting, bleeding and a palpable abdominal mass, with complications like perforation, intussusception, bowel obstruction, volvulus and associated malignancy. Frequent micturition is a rare presentation.<sup>[4]</sup> This condition needs to be differentiated from other causes of lower gastrointestinal bleeding in children like polyps, clotting disorders, arteriovenous malformations and Crohn's disease.<sup>[3]</sup>

On USG, a double-layered wall (the combination of an echogenic inner mucosal layer and hypoechoic outer muscular layer) is found in over 50% of duplication cysts.<sup>[5]</sup> 99mTc pertechnetate is concentrated by EGM in a duplication cyst, similar to the uptake seen in gastric mucosa within a Meckel's diverticulum, and this phenomenon may be useful to diagnose this condition. However, the presence of gastric mucosa within duplication cysts is variable, and has been reported to be 17-36%.<sup>[6]</sup> Both Meckel's diverticulum and intestinal duplication should be included as differential diagnostic possibilities for a focus of increased tracer activity on 99mTc pertechnetate abdominal scintigraphy, because the two conditions cannot be distinguished based on the

size or location of the EGM.<sup>[3]</sup> A normal 99mTc pertechnetate study should not show any focal tracer accumulation other than in the stomach and the urinary tract. The sensitivity of 99mTc pertechnetate imaging for detection of EDC is reported to be 75%.<sup>[7]</sup> False-positive uptake of this radiotracer may be seen in intussusception, focal hyperemia or bowel inflammation, gastrointestinal bleeding unrelated to EGM, uterine blush, retention of tracer in the urinary collecting system, vascular lesions such as hemangiomas and arteriovenous malformations.<sup>[3]</sup>

EGM in the alimentary tract is a rare condition, and the length of the involvement usually ranges from a few to several centimeters, with contiguous or composed of islands of EGM. It is usually diagnosed during laparotomy for complications of EGM, such as perforation or obstruction. While 99mTc pertechnetate scintigraphy in Meckel's diverticulum has been described in several studies, the pre-operative diagnosis of EGM in the small intestine using this technique is less common. The localized tracer activity in EGM shows a variable pattern, and tends to decrease during the course of imaging due to dilution with intestinal

secretions. Locally concentrated tracer also gets washed away by peristaltic activity.<sup>[8-10]</sup> The present case differs significantly from others previously described in the literature in the unusual length of the involved segment.

## REFERENCES

1. Bower RJ, Sieber WK, Kiesewetter WB. Alimentary tract duplications in children. *Ann Surg* 1978;188:669-74.
2. Holcomb GW 3rd, Gheissari A, O'Neill JA Jr, Shorter NA, Bishop HC. Surgical management of alimentary tract duplications. *Ann Surg* 1989;209:167-74.
3. Emamian SA, Shalaby-Rana E, Majd M. The spectrum of heterotopic gastric mucosa in children detected by Tc-99m pertechnetate scintigraphy. *Clin Nucl Med* 2001;26:529-35.
4. Otter MI, Marks CG, Cook MG. An unusual presentation of intestinal duplication with a literature review. *Dig Dis Sci* 1996;41:627-9.
5. Barr LL, Hayden CK Jr, Stansberry SD, Swischuk LE. Enteric duplication cysts in children: Are their ultrasonographic wall characteristics diagnostic? *Pediatr Radiol* 1990;20:326-8.
6. Tong SC, Pitman M, Anupindi SA. Best cases from the AFIP. Ileocecal enteric duplication cyst: Radiologic-pathologic correlation. *Radiographics* 2002;22:1217-22.
7. Rose JS, Gribetz D, Krasna IH. Ileal duplication cyst: The importance of sodium pertechnetate Tc 99m scanning. *Pediatr Radiol* 1978;6:244-6.
8. Heinrichs VM, Kemper MJ, Burdelski M, Kluth D, Mueller-Wiefel DE, Schaefer H, *et al.* Disseminated islands of gastric mucosa in jejunum and ileum detected by technetium-99m-pertechnetate scintigraphy. *J Nucl Med* 1997;38:818-20.
9. Kumar R, Tripathi M, Chandrashekar N, Agarwala S, Kumar A, Dasan JB, *et al.* Diagnosis of ectopic gastric mucosa using 99Tcm-pertechnetate: Spectrum of scintigraphic findings. *Br J Radiol* 2005;78:714-20.
10. Kiratli PO, Aksoy T, Bozkurt MF, Orhan D. Detection of ectopic gastric mucosa using 99mTc pertechnetate: Review of the literature. *Ann Nucl Med* 2009;23:97-105.

**How to cite this article:** Bhattacharya A, Samujh R, Rao KN, Mittal BR. Long segment jejuno-ileal duplication cyst with ectopic gastric mucosa detected on 99mTc-pertechnetate scintigraphy. *Indian J Nucl Med* 2013;28:96-8.

**Source of Support:** Nil. **Conflict of Interest:** None declared.

## New features on the journal's website

### Optimized content for mobile and hand-held devices

HTML pages have been optimized of mobile and other hand-held devices (such as iPad, Kindle, iPod) for faster browsing speed.

Click on **[Mobile Full text]** from Table of Contents page.

This is simple HTML version for faster download on mobiles (if viewed on desktop, it will be automatically redirected to full HTML version)

### E-Pub for hand-held devices

EPUB is an open e-book standard recommended by The International Digital Publishing Forum which is designed for reflowable content i.e. the text display can be optimized for a particular display device.


Click on **[EPub]** from Table of Contents page.

There are various e-Pub readers such as for Windows: Digital Editions, OS X: Calibre/Bookworm, iPhone/iPod Touch/iPad: Stanza, and Linux: Calibre/Bookworm.

### E-Book for desktop

One can also see the entire issue as printed here in a 'flip book' version on desktops.

Links are available from Current Issue as well as Archives pages.

Click on  View as eBook