

CARCINOMA OF THE CERVIX IN ASSOCIATION WITH PROCIDENTIA

EUGENE A. EDWARDS, M.D. and ROBERT A. BEEBE, M.D.¹

THERE have been about 92 cases of carcinoma of the cervix in association with prolapse of the uterus reported in the literature to the present time. In 1943, Harvey and Ritchie collected 78 cases for a radiologic review. They added one case to the 78 reported. Since their study, an additional 13 cases may be added from the reports of Ashton (2 cases), Dutra (8 cases), and de Barros and Rocha (3 cases).

The rarity of the occurrence of these two lesions has been commented upon by many investigators. In 1882, according to Ashton, Fritsch said that the two conditions do not occur together. Cullen saw but one case in consultation away from Johns Hopkins Hospital. Martzloff, in 1923, stated that no cases had been reported in that hospital. Judd and Graves state, according to Harvey, that carcinoma of the cervix is present in about 0.14 per cent of procidentias.

At the St. Luke's Hospital, Chicago, from January 1, 1922 to January 1, 1949 there has been one case of carcinoma of the cervix in association with prolapse of the uterus. During this same time there have been 521 cases of carcinoma of the cervix diagnosed by our pathology department.

CASE REPORT

Mrs. E. E. N., a 50-year-old para II, gravida II (a private patient of Dr. John I. Brewer) was admitted to the St. Luke's Hospital on June 20, 1946 because of intermittent vaginal bleeding and spotting for the previous six weeks. The bleeding followed intercourse and the use of a douche. She had complained of "falling of the womb" for several years and also of a feeling of pressure and dragging in the lower abdomen. She had moderate frequency. The essential part of the past history revealed that the patient had a normal menstrual cycle and that the menses still occurred every month.

On June 21, 1946, under general anesthesia, pelvic examination revealed that the cervix

protruded beyond the introitus. The left half of the cervix was involved in an elevated tumor mass. There was no apparent extension to the vagina and there was no induration of the surrounding broad ligament tissues.

A biopsy of the cervix was taken. A 50 milligram radium bolus was placed in the cervical canal and eight needles, each ten milligrams, were inserted in palisade about the cervix. The total dose of radium given was 3900 milligram hours.

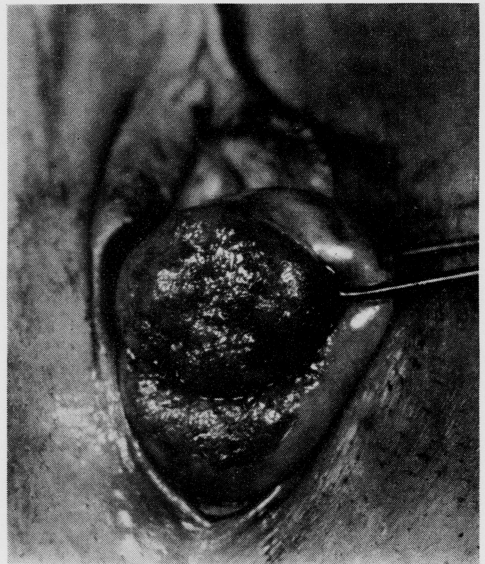


Fig. 1. Lesion on external cervix. (Brewer, John I.: *Gynecology*, New York, Thomas Nelson & Sons, 1950.)

The microscopic report from the pathology department by Dr. Edwin F. Hirsch was as follows: This tissue has a fibrous stroma along one edge with considerable chronic inflammation and is extensively ingrown here by masses of atypical epithelial cells arranged in mosaics. The individual cells are medium in size, have vesicular nuclei with chromatin granules and a small amount of granular cytoplasm, some with more and with a suggestion of hornification. The exudates are mainly lymphocytes and plasma cells. In some epithelial masses the center portions are necrotic and contain granular precipitates. Diagnosis: Stratified squamous cell carcinoma of the cervix.

¹From the Department of Obstetrics and Gynecology, Northwestern University Medical School. Received for publication, December 17, 1949.

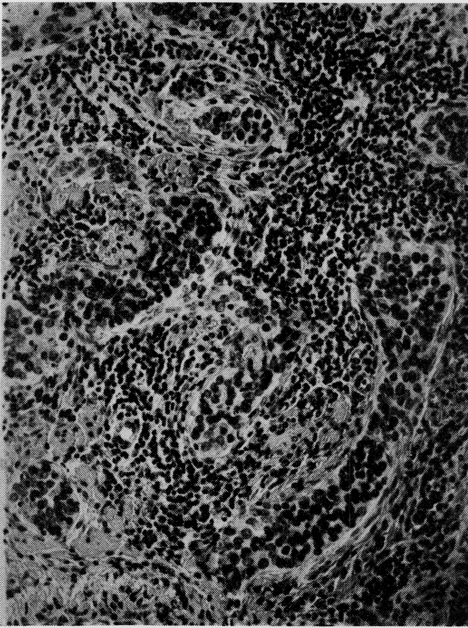


Fig. 2. Microphotograph showing the squamous cell carcinoma of the cervix. X198.

This patient received a course of deep pelvic X-ray. The postoperative course was satisfactory. In March 1948, she developed a daily temperature elevation as high as 103F. Examination of the pelvis revealed a small cervix apparently free of tumor tissue. The small uterus was to the left. There was a hard large mass in the right broad ligament. This mass was incised and drained vaginally of a large amount of necrotic material. The patient died in 1948 from carcinoma of the cervix with extensive local metastases in the pelvis.

DISCUSSION

The theory most often advanced for the rarity of these two lesions in association is that cornification of the epithelium in prolapse of the uterus raises the resistance of the cervical tissues to carcinoma. Emmert and Taussig disagree with this theory. They are inclined to believe that excessive cornification would favor the development of malignancy. They further believe that it is not such a rare lesion and that if more biopsies of decubital ulcers were taken more carcinomas of the cervix would be seen. In 10 consecutive cases of procidentia during a five-year period, they found 4 complicated by carcinoma of the cervix. Dutra mentions, in addition to cornification, the poor blood supply and lymph circulation associated with prolapse of the uterus. Hamant, according to Dutra, believes that the lack of irritating secretions observed in prolapsed uteri removes a factor in the development of cancerous growths of the cervix.

REFERENCES

1. Harvey, R. A. and Ritchie R. N.: *Radiology*, 41:48-51, 1943.
2. Ashton, D.: *Am. J. Obst. & Gynec.*, 55:299, 1948.
3. Emmert, F. V. and Taussig: *Am. J. Obst. & Gynec.*, 28: 521, 1934.
4. Dutra, L. H.: *Obst. & Gynec., latino-am.*, 2: 350-370, 1944.
5. de Barros, R. M. and Rocha, A. H.: *Rev. de gynec. e d' obst.*, 2:234-243, 1946.