

Severe Oral Lesions in Chickens Caused by Ingestion of Dietary Fusariotoxin T-2¹

R. D. WYATT, B. A. WEEKS, P. B. HAMILTON, AND H. R. BURMEISTER

Department of Poultry Science and Department of Microbiology, North Carolina State University, Raleigh, North Carolina 27607, and Northern Regional Research Laboratory, Agricultural Research Service, U. S. Department of Agriculture, Peoria, Illinois 61604

Received for publication 4 April 1972

Fusariotoxin T-2 is a mycotoxin produced by *Fusarium tricinctum* which was implicated in moldy corn toxicosis of farm animals. Graded concentrations of dietary fusariotoxin T-2 (0, 1, 2, 4, 8, and 16 $\mu\text{g/g}$, respectively) were given to groups of 40 chickens. Raised yellowish-white lesions on the mouth parts were produced by all concentrations, and the size of the lesions was dose-related. The growth rate was reduced significantly ($P < 0.05$) by concentrations of 4, 8, and 16 $\mu\text{g/g}$. The mouth fluid of the affected birds contained greatly increased numbers of bacteria, including *Staphylococcus epidermidis* and *Escherichia coli*, which proved avirulent when inoculated into scarified tissue of control birds. Microscopy examinations of the lesions revealed a fibrinous surface layer, intermediate layers containing invaginations filled with rods and cocci, and a heavy infiltration of the underlying tissues with granular leukocytes. These data suggest that the role of fusariotoxin T-2 in field cases of moldy corn toxicosis should be reinvestigated since oral lesions were not mentioned in the original descriptions of the disease. However, the lesions bear some features of those characteristic of the third or septic angina stage of alimentary toxic aleukia, a nutritional toxicosis of humans produced by eating grains infested with *F. tricinctum*.

Fusariotoxin T-2 is a mycotoxin produced by *Fusarium tricinctum* (Corda) Snyder and Hansen, strain T-2. It has been identified as 4, 15-diacetoxy-8-(3-methylbutyryloxy)-12, 13-epoxy- Δ^9 -trichothecen-3-ol (1), and, like most 12,13 epoxy- Δ^9 -trichothecen compounds, it is a potent skin irritant and inflammatory agent (15). In trout, dietary fusariotoxin T-2 causes a rapid sloughing of the intestinal mucosa (15). Rats fed T-2 toxin develop a severe inflammation around the nose and mouth; topical application results in necrosis of the dermal tissues (15).

Fusariotoxin T-2 was isolated as the result of an investigation into moldy corn toxicosis of farm animals (1, 10) but one of its more interesting features is its possible role in alimentary toxic aleukia (ATA; reference 16). ATA was a major health problem in Russia for about two

decades (16); it was considered to be caused by overwintered grain made toxic as the result of infestation with *F. sporotrichoides* (17). This mold is now considered to be synonymous with *F. tricinctum* (23). However, the cause of ATA has not been assigned to a specific chemical entity. In an attempt to gain information about fusariotoxin T-2 and its possible role in moldy corn toxicosis (9) and in ATA, its effects in chickens were investigated. The present communication describes the oral lesions in chickens caused by graded doses of dietary fusariotoxin T-2.

MATERIALS AND METHODS

Fusariotoxin T-2. *F. tricinctum* NRRL 3299 was grown on white corn grits (7). The toxin was extracted and purified by the method of Burmeister (7) to give a crystalline product melting at 150 to 152 C.

Animal husbandry. One-day-old male broiler chickens were obtained commercially and were housed in electrically heated batteries which were provided with constant lighting. Feed and water were available ad libitum. The feed consisted of a commercial broiler-starter diet free of all medica-

¹ Paper no. 3730 of the Journal Series of the North Carolina State University Agricultural Experiment Station, Raleigh, N.C. A preliminary account of part of this work was given at the 60th Annual Meeting of the Poultry Science Association, Fayetteville, Arkansas, August 1971.

tions. Fusariotoxicosis was induced by incorporating into small portions of the diet known amounts of crystalline T-2 toxin dissolved in 50% (v/v) aqueous ethanol. The portions of feed containing T-2 toxin were dried at 100 C to evaporate the ethanol before being mixed thoroughly into the remainder of the feed. The experimental diets were fed from hatching until 3 weeks of each replicate were measured so that the effect of T-2 toxin on the feed conversion efficiency could be calculated.

Experimental design. There were four replicates of 10 birds at each dose level. The dose levels were 0, 1, 2, 4, 8, and 16 μg of fusariotoxin T-2 per g of diet. The treatments and birds were completely randomized. The replicate means were evaluated statistically by analysis of variance, and the treatment means were compared by the method of least significant differences (6).

Microbiological flora of the mouth. The microbiological flora of the mouths of the birds were determined by swabbing the mouth anterior to the larynx with cotton swabs calibrated to absorb 0.1 ± 0.01 ml (mean \pm standard error of the mean) of mouth fluid. The swabs were placed in a container of sterile saline solution (0.85%), and the total bacterial count of the mouth fluid was determined by using the pour plate technique with Brain Heart Infusion Agar (Difco). The swabs from each treatment were pooled. Staphylococci were isolated with *Staphylococcus* no. 110 medium (Difco) and coliforms were isolated with Violet Red Bile Agar (Difco). The agar plates were incubated for 72 hr at 37 C before the colonies were counted. Fungi were isolated from the mouth by streaking mouth swabs on Sabouraud Dextrose Agar (Difco) containing 40 μg of chloramphenicol per ml. The fungi were identified according to Raper and Fennell (21) and Beneke and Rogers (5). Mouth swabs were also streaked on Pagano-Levin medium (Difco) to test for the presence of *Candida albicans*.

Staphylococcal isolates. Representative isolates varying in colonial morphology were selected and grown in Brain Heart Infusion (Difco) for 18 hr at 37 C before being tested for coagulase activity in reconstituted rabbit plasma (Difco). Fermentation of mannitol was determined on Mannitol Salt Agar (Difco) under both aerobic and anaerobic conditions by incubating the isolates for 48 hr at 37 C. Deoxyribonuclease activity was studied on DNase Test Medium (Difco). After incubation for 24 hr at 37 C, the plates were flooded with 0.1 N HCl and were inspected visually for the amount of deoxyribonucleic acid hydrolysis. The presence of hemolysins was tested on blood-agar plates prepared from fresh human, sheep, and chicken blood. The plates were incubated for 72 hr at 37 C before examining for clear zones around isolated colonies.

Lesion size. The size of the oral lesions caused by ingestion of dietary fusariotoxin T-2 was determined gravimetrically. The raised lesions, which were yellowish-white in color, were teased from the mouth parts with the aid of surgical forceps. The pathological material from all birds in a replicate were placed in tared weighing pans and dried in a forced-draft

oven for 12 hr at 80 C. After cooling, the pans and their contents were weighed on a semimicrobalance, and the weights were recorded as milligrams of dry weight per bird.

Lesions for microscopic examination. Mouth parts of affected birds containing lesions were fixed immediately in 10% neutral buffered Formalin for 24 hr. After embedding in paraffin, 6- μm sections were stained with hematoxylin and eosin.

Microbiological examination of blood and visceral organs. Before necropsy, a blood sample was obtained aseptically by cardiac puncture, and a 1-ml sample was added to 10 ml of Trypticase Soy Broth (Difco). Another sample was streaked on Blood Agar Base (Difco) containing sterile sheep blood.

At necropsy, exposed portions of the liver and spleen were seared with a hot spatula. A sterile loop was inserted into each organ through the seared area, and the material removed was streaked on sheep blood-agar plates. The inoculated medium was incubated at 37 C for 7 days and examined for bacterial and fungal growth.

RESULTS

The effect of fusariotoxin T-2 on the growth rate of broiler chickens is shown in Fig. 1. The growth rate was inhibited significantly ($P < 0.05$) by doses of 4 $\mu\text{g}/\text{g}$ and above, and the degree of inhibition was dose-related. The efficiencies of conversion of feed to increased body weight for this experiment were calculated, and the T-2 toxin had no effect at even the high dose levels that inhibited growth.

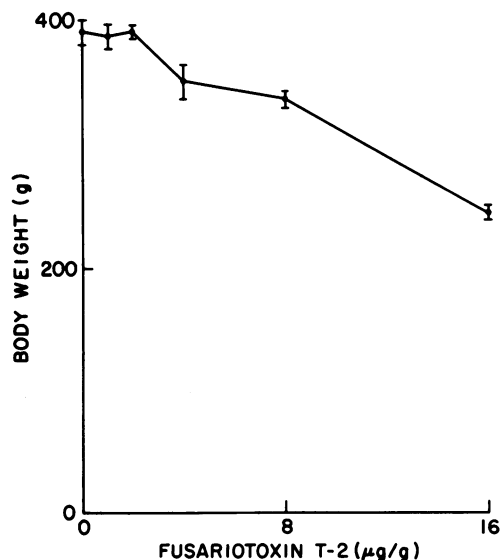


FIG. 1. Effect of graded levels of dietary fusariotoxin T-2 on the growth rate of chickens. Each point represents the mean body weight of forty birds at three weeks of age. The vertical bars on a point are the standard error of the mean.

The oral lesions characteristic of T-2 toxicosis first appeared when the chickens were about 1 week old. The lesions appeared first on the hard palate and along the margin of the tongue. The raised lesions were yellowish-white in color and caseous in texture. By 2 weeks, the lesions increased in size and invaded the lingual papillae at the root of the tongue. The lesions also occurred on the underside of the tongue and on the inside of the lower beak lateral to the midline. At 3 weeks, the size of the lesions increased to the extent that some birds on the higher dose levels of toxin were unable to close their mouth completely. Figure 2 shows a typical severe case. The inside of the lower beak of a bird that received only 4 μg of fusariotoxin T-2/g is shown in Fig. 3. The lesions here are restricted mainly to V-shaped streaks, which occurred on both the upper and lower beaks. T-2 toxin at a dose of 1 $\mu\text{g}/\text{g}$ produced only isolated lesions on the hard palate and along the margin of the tongue.

During early stages of lesion formation, lesions could not be removed from the underlying tissue without producing hemorrhage. At the end of the 3-week experimental period, the lesions could be removed with little hemorrhaging. In Fig. 4, the lesion size at 3 weeks of age is plotted as a function of dietary levels of fusariotoxin T-2. There was essentially a linear increase in lesion size with increasing toxin concentration. Lesions occurred without exception in all birds receiving T-2 toxin.



FIG. 2. Oral inflammatory response to dietary fusariotoxin T-2 in the young chicken. This bird which was unable to close its mouth completely because of the extensive lesions received 16 μg of toxin per g of diet from hatching until 3 weeks of age.

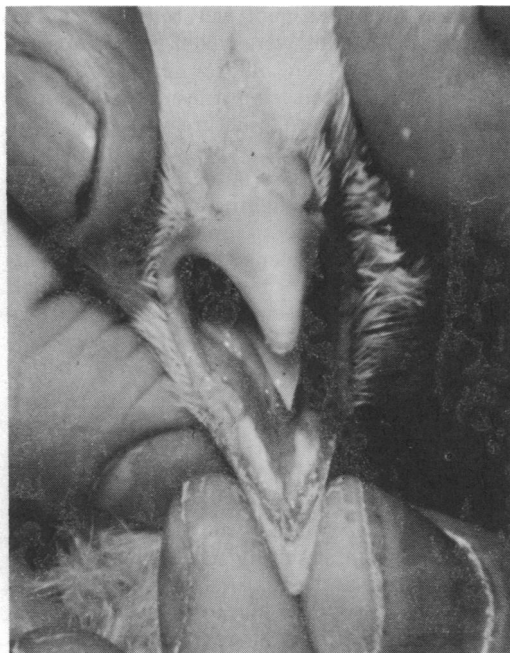

FIG. 3. Oral lesions produced by 4 μg of dietary fusariotoxin T-2 per g of diet. The lesions, on the inside of the lower beak, manifest themselves mainly as V-shaped streaks.

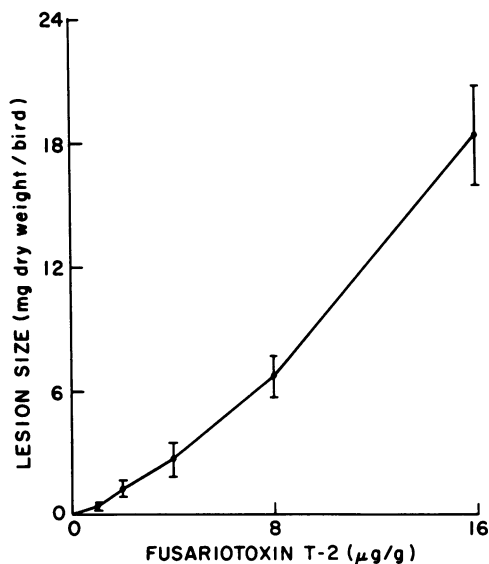


FIG. 4. Effect of dietary fusariotoxin T-2 on the oral lesion size in the chicken. The lesions were teased from the mouth parts of birds receiving the indicated level of dietary fusariotoxin T-2 from hatching until 3 weeks of age. Each data point represents the mean of 40 birds, and the vertical bars on the points represent the standard error of the mean.

When the experiment was terminated, sections of the lesions were taken for histopathological analysis. A photomicrograph of a stained thin section from a lesion is presented in Fig. 5. The overall picture was that of an intense inflammatory response coupled with localized necrosis. The outer layers of the lesion consisted of sloughing fibrinous material while the underlying tissue was heavily infiltrated with granular leukocytes. At varying intervals in the intermediary tissues, small eroded areas were seen which contained large numbers of bacteria. Both rods and cocci were evident.

The total viable bacterial count of the mouth fluid is shown in Fig. 6 related to dietary fusariotoxin T-2 concentration. The total count was increased by the higher T-2 toxin levels approximately 20-fold over the control value. Representative colonies from the plates used for the isolation of staphylococci and coliforms were isolated and identified. *Staphylococcus epidermidis* and *Escherichia coli* predominated among the organisms in the mouth fluid of both control and experimental birds. Randomly selected strains of *S. epidermidis*, which were isolated from experimental birds and which varied in colonial characteristics, were negative for deoxyribonuclease, coagulase, and hemolysins, and did not produce acid from mannitol under aerobic or anaerobic culture conditions. Isolates of *S. epidermidis* and *E. coli* proved to be avirulent when inoculated individually or in combination into scarified mouth parts of control birds. *S. aureus* was not isolated from any of the animals. No bacteria or fungi could be isolated from the liver, spleen, or blood.

A fungus identified as *Fusarium moniliforme* was isolated consistently from the mouths of about half of the affected birds, but it occurred with the same frequency in control birds. *Aspergillus fumigatus*, *A. flavus*, *A. candidus*, *A. versicolor*, *Cephalosporium* sp., *Alternaria* sp., and *Penicillium* sp. also were isolated, but, when they occurred, it was in less than 5% of both the control and experimental birds. *C. albicans* could not be isolated from any of the birds.

DISCUSSION

The primary effect of fusariotoxin T-2 in chickens appeared to be an inflammatory response in the mouth. The initial inflammation progressed to a necrotic lesion, which was invaded by normal microbial flora. The lesions became so severe that the birds could eat only

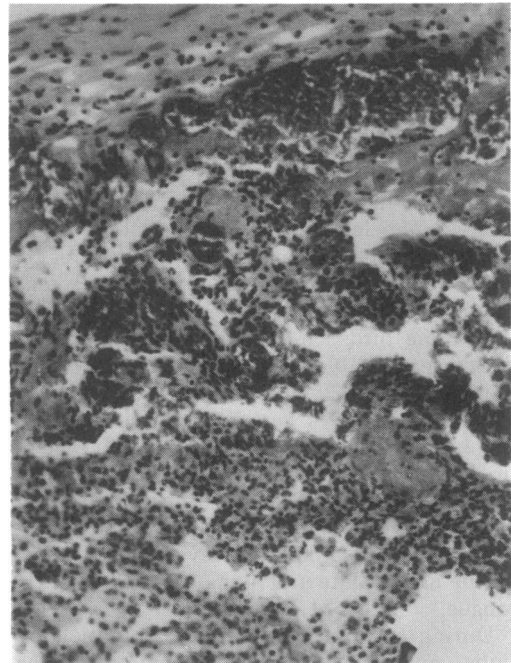


FIG. 5. Photomicrograph of an oral lesion caused by ingestion of fusariotoxin T-2 in the young chicken. The magnification is $\times 320$, and the surface of the lesion is at the top of the picture.

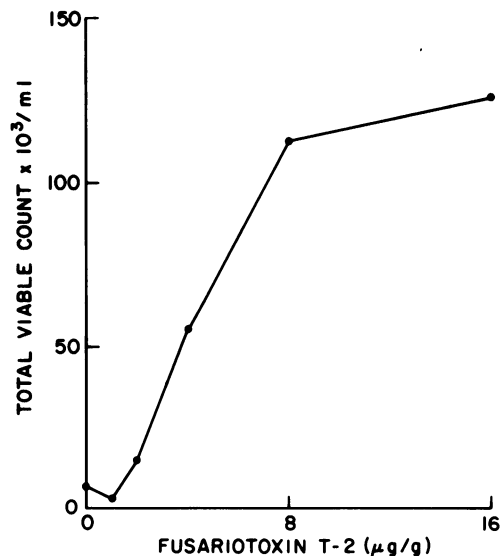


FIG. 6. Effect of dietary fusariotoxin T-2 on the total viable bacterial count in the mouth fluid of the chicken.

with difficulty. This condition apparently impaired the growth rate without affecting feed-conversion efficiencies, in contrast to the effect of aflatoxin on conversion efficiencies (22). Evidently T-2 toxin does not affect the chicken in the same manner as aflatoxin, which interferes with protein synthesis by inhibiting ribonucleic acid polymerase (20). These data agree with a previous report (19) that feed inoculated with *Fusarium* strains produces a yellowish-white fibrinous deposit in the mouths of goslings which can be removed easily.

The microbial flora of the mouths of chickens with lesions produced by dietary fusariotoxin T-2 appeared to be secondary invaders not actively participating with the highly irritating toxin. The bacteria isolated from mouth swabs of experimental birds were found also in control birds, although in lesser numbers. The predominant bacteria were *E. coli* and *S. epidermidis*. The strains of *S. epidermidis* examined were negative for deoxyribonuclease, coagulase, and hemolysins. These factors are often associated with virulence of staphylococci (11). *S. aureus*, which often contains these factors and which is a virulent organism, was not isolated. The localization of the bacteria near the surfaces and detritus of the lesions as seen in the tissue sections suggests a secondary role for the bacteria associated with T-2 toxicosis. Failure to isolate microorganisms from the blood and internal organs of the affected birds also suggests a secondary role for the increased numbers of microorganisms in the mouth. Localized infections of chickens with enterobacteria usually result in a septicemia and infiltration of internal organs with these organisms (J. R. Harris, *personal communication*). In addition, the oral lesions seen in humans afflicted with ATA contain large numbers of avirulent cocci and rods (16).

F. moniliforme was isolated from the mouth fluid of about half of the experimental birds; several other fungi were isolated from less than 5% of the birds. Their incidence in control birds was identical. All these fungi have been reported as common contaminants of cereal grains (14) which composed the bulk of the diet in these experiments. Consequently, these fungi would appear to be adventitious and not even secondary invaders. In this regard, the failure to isolate *C. albicans* from the oral lesions is important since this microorganism reportedly causes oral lesions in chickens (4).

The role of fusariotoxin T-2 in moldy corn

toxicosis of animals is uncertain, although the toxin was isolated as the result of an investigation of the disease (1, 10). None of the original descriptions of the disease (9, 10) mention the occurrence of oral lesions that appear to be characteristic after ingestion of dietary T-2 toxin. However, Palyusik, Szep, and Szoke (15) reported that feed inoculated with *Fusarium* strains produces fibrinous lesions in the mouths of goslings. Also, necrotic lesions have been noted in the angles of the mouths of some turkey poults dying from eating corn invaded by *F. tricinctum* (8). Perhaps this confusion results from the failure of all investigators to examine the mouths of animals during necropsy. Additional field cases in which the mouth is examined may resolve this point.

The present status of ATA, as it is denominated by the Soviet government, is uncertain despite its being a major health problem in Russia for almost two decades (16). Confusion surrounding this disease is reflected in the listing by Mayer (16) of 14 synonyms for the disease. Mayer preferred endemic panmyelotoxicosis as the name, but Joffe (13), who was involved in some of the original research, preferred septic angina. Nevertheless, it is generally accepted that this disease is caused by ingestion of grain infected with *F. sporotrichoides*, now considered to be synonymous with *F. tricinctum* (23). The disease is thought by clinicians to develop in four stages, although these admittedly are more or less subjective and artificial divisions of the disease development. A few hours after eating toxic grain, victims experience a sensation of generalized burning of the upper gastrointestinal tract, and this symptom progresses to a mild inflammation. The second stage is usually symptomless except for destructive changes in the bone marrow. The third stage is initiated by the sudden appearance of hemorrhagic areas of the skin and is characterized by all features of typical total atrophy of the bone marrow (panmyelophthisis), including necrotic lesions of the mouth and throat (septic angina). Survivors enter the stage of convalescence (16). The toxic principle(s) responsible for the disease does not appear to have been isolated, although several claims have been made (17). The best claim appears to be that of Olifson who, according to Mayer (17), isolated four substances which were identified only tentatively and which were not submitted to definitive toxicological evaluations. Joffe (14) gave the structures of three of the substances. One was reported to be a steroidal unsaturated δ

lactone reminiscent of the cardiac-active steroids. As noted by Bamberg et al. (3), these compounds act specifically on heart muscle and not as skin irritants or on the bone marrow. The other two toxins were reported to be long-chain, unsaturated thiocarboxylic acids, and these compounds as a class have low toxicity (3).

In the United States, *F. tricinctum* was implicated in moldy corn toxicosis of farm animals (9, 10); two toxic compounds, diacetoxyscirpenol and the closely related T-2 toxin, were isolated (1) by using as a bioassay the rabbit skin test prescribed in ATA (17). As might be expected, T-2 toxin is a potent skin irritant in rabbits, rats, and mice. Toxicological evaluations have concentrated on T-2 toxin with consequential neglect of diacetoxyscirpenol and many other chemically related toxic compounds isolated from related fungi (1, 2, 18). Data from our study show that dietary T-2 toxin produces dose-related oral lesions in chickens.

Several features suggest that fusariotoxin T-2 causes or is involved in ATA. T-2 toxin caused a severe inflammation and dermatitis (1) in laboratory workers who accidentally contacted it. A similar occupational hazard to the Russian investigators of ATA was reported (17). T-2 toxin was isolated (1) by using as a bioassay the official test (17) to detect grains causing ATA. Dietary T-2 toxin in rats caused an inflammation about the mouth and nose (15), and a similar inflammation was observed in victims during the first stage of ATA (16). In chickens, the dose-related oral lesions caused by T-2 toxin appear similar to those occurring during the third or necrotic angina stage of ATA (16). When topically applied, T-2 toxin caused intradermal hemorrhages, edema, and empurpling in rats (15) similar to the hemorrhagic spots and diathesis of the third stage of ATA. The main piece of evidence missing from the correlation of T-2 toxicosis with ATA is the devastation of the bone marrow and its hematological sequelae, which are characteristic of ATA but which have not been reported with T-2 toxin. This difference may be the result of neglect or the failure to use the proper experimental animal. The Russian investigators reported a similar failure to elicit typical changes of ATA in the hematopoietic system of most animals fed toxic grain, and they found that the cat was the preferred experimental animal for these changes (13, 17).

Since *F. tricinctum* strain T-2 from which T-2 toxin was isolated produces at least three

toxins (2) and since many toxins are produced by the genus *Fusarium* (3), it must be considered that typical ATA is the result of several toxins acting in concert. An attraction of this hypothesis is that variations in the relative levels of the different toxins might be expected to result in variations of the symptoms. It is intriguing that, although 92% of all cases of ATA displayed the inflammatory response of the upper gastrointestinal tract typical of the first stage of ATA, there are at least four clinical varieties of the third stage of ATA, and only 44% of all cases displayed the necrotic-hemorrhagic response considered typical of the third stage (16). It is interesting that solaniol, a toxic metabolite of *F. solani* chemically related to T-2, produces extensive cellular degeneration and karyorrhexis of the bone marrow of mice (12), as do three similar toxins produced by *F. nivale* (3). It would seem worthwhile to investigate for interactions with others toxins produced by *F. tricinctum* and to look specifically for the effects of T-2 toxin on the hematopoietic system. Then, perhaps the responsibility for ATA can be assigned to specific chemical entities and additional insights can be gained into the hazards to public and animal health posed by mycotoxins.

ACKNOWLEDGMENTS

We thank Sharon West, E. Y. Hickman, and Nancy Goodwin for technical assistance and C. F. Conant for identifying the *F. moniliforme*.

LITERATURE CITED

- Bamberg, J. R., N. V. Riggs, and F. M. Strong. 1968. The structures of toxins from two strains of *Fusarium tricinctum*. *Tetrahedron* 24:3329-3336.
- Bamberg, J. R., and F. M. Strong. 1969. Mycotoxins of the trichothecane family produced by *Fusarium tricinctum* and *Trichoderma lignorum*. *Phytochemistry* 88:2405-2410.
- Bamberg, J. R., F. M. Strong, and E. B. Smalley. 1970. Toxins from moldy cereals. *J. Agr. Food Chem.* 17: 443-450.
- Beister, H. E., and L. H. Schwarte. 1965. Diseases of poultry, 5th ed. The Iowa State University Press, Ames.
- Beneke, E. S., and A. L. Rogers. 1971. Medical mycology manual. Burgess Publishing Co., Minneapolis.
- Bruning, J. L., and B. L. Kintz. 1968. Computational handbook of statistics. Scott Foresman Co., Glenview, Ill.
- Burmeister, H. R. 1971. T-2 toxin production by *Fusarium tricinctum* on solid substrate. *Appl. Microbiol.* 21:739-742.
- Christensen, C. M., R. A. Meronuck, G. H. Nelson, and J. C. Behrens. 1972. Effects on turkey poults of rations containing corn invaded by *Fusarium tricinctum* (Cda.) Syn. & Hans. *Appl. Microbiol.* 23:177-179.
- Forgacs, J., and W. L. Carl. 1962. Mycotoxicoses. *Advan. Vet. Sci.* 7:273-382.
- Gilgan, M. W., E. B. Smalley, and F. M. Strong. 1966.

- Isolation and partial characterization of a toxin from *Fusarium tricinctum* on moldy corn. Arch. Biochem. Biophys. 114:1-3.
11. Harry, E. G. 1967. Some characteristics of *Staphylococcus aureus* isolated from the skin and upper respiratory tract of domesticated and wild (feral) birds. Res. Vet. Sci. 8:490-499.
 12. Ishii, K., K. Sakai, Y. Ueno, H. Tsunoda, and M. Enomoto. 1971. Solaniol, a toxic metabolite of *Fusarium solani*. Appl. Microbiol. 22:718-720.
 13. Joffe, A. Z. 1960. Toxicity and antibiotic properties of some *Fusaria*. Bull. Res. Council. Isr. 80:81-95.
 14. Joffe, A. Z. 1965. Toxin production by cereal fungi causing toxic alimentary aleukia in man, p. 77-85. In G. N. Wogan (ed.), Mycotoxins in foodstuffs. The M.I.T. Press, Cambridge, Mass.
 15. Marasas, W. F. O., J. R. Bamberg, E. B. Smalley, F. M. Strong, W. L. Ragland, and P. E. Degurse. 1969. Toxic effects on trout, rats, and mice of T-2 toxin produced by the fungus *Fusarium tricinctum* (Cd.) Synd. Hans. Toxicol. Appl. Pharmacol. 15:471-482.
 16. Mayer, C. F. 1953. Endemic panmyelotoxicosis in the Russian grain belt. Part one: The clinical aspects of alimentary toxic aleukia (ATA); a comprehensive review. Mil. Surg. 113:173-189.
 17. Mayer, C. F. 1953. Endemic panmyelotoxicosis in the Russian grain belt. Part two: The botany, phytopathology, and toxicology of Russian cereal food. Mil. Surg. 113:295-315.
 18. Mirocha, C. J., C. M. Christensen, and G. H. Nelson. 1968. Toxic metabolites produced by fungi implicated in mycotoxicoses. Biotech. Bioeng. 10:469-482.
 19. Palyusik, M., I. Szep, and F. Szoke. 1968. Data on susceptibility to mycotoxins on day-old goslings. Acta Vet. Hung. Tomus 18:363-372.
 20. Pong, R. S., and G. N. Wogan. 1969. Time course alterations of rat liver polysome profiles induced by aflatoxin B₁. Biochem. Pharmacol. 18:2357-2361.
 21. Raper, K. B., and D. I. Fennell. 1965. The genus *Aspergillus*. The Williams & Wilkins Co., Baltimore.
 22. Smith, J. W., C. H. Hill, and P. B. Hamilton. 1971. The effect of dietary modifications on aflatoxicosis in the broiler chicken. Poultry Sci. 100:768-774.
 23. Snyder, W. C., and H. N. Hansen. 1945. The species concept in *Fusarium* with reference to discolor and other sections. Amer. J. Bot. 32:657-666.