

# Original Article

## Total shoulder arthroplasty versus hemiarthroplasty for glenohumeral arthritis: A systematic review of the literature at long-term follow-up

Michel P. J. van den Bekerom<sup>1</sup>, Pieter C. Geervliet<sup>2</sup>, Matthijs P. Somford<sup>3</sup>, Maaïke P. J. van den Borne<sup>3</sup>, Ronald Boer<sup>3</sup>

### ABSTRACT

**Introduction:** The optimal surgical treatment of end-stage primary glenohumeral osteoarthritis remains controversial. The objective of this article is to systematically review the current available literature to formulate evidence-based guidelines for treatment of this pathology with an arthroplasty.

**Materials and Methods:** A systematic literature search was performed to identify all articles from 1990 onward that presented data concerning treatment of glenohumeral arthritis with total shoulder arthroplasty (TSA) or head arthroplasty (HA) with a minimal follow-up of 7 years. The most relevant electronic databases were searched.

**Results:** After applying the inclusion and exclusion criteria, we identified 18 studies (of the initial 832 hits). The search included a total of 1,958 patients (HA: 316 and TSA: 1,642) with 2,111 shoulders (HA: 328 + TSA: 1,783). The revision rate for any reason in the HA group (13%) was higher than in the TSA group (7%) ( $P < 0.001$ ). There was a trend of a higher complication rate (of any kind) in the TSA group (12%) when compared with the HA group (8%) ( $P = 0.065$ ). The weighted mean improvement in anteflexion, exorotation and abduction were respectively 33°, 15° and 31° in the HA group and were respectively 56°, 21° and 48° in the TSA group. Mean decrease in pain scores was 4.2 in the HA and 5.5 in the TSA group.

**Conclusion:** Finally, we conclude that TSA results in less need for revision surgery, but has a trend to result in more complications. The conclusions of this review should be interpreted with caution as only Level IV studies could be included.

**Level of Evidence:** IV.

**Key words:** Arthroplasty, complication, glenoid, humerus, osteoarthritis, revision rate, shoulder, systematic review

### INTRODUCTION

The total shoulder replacement is possibly the first documented replacement of a large joint in the human body. In 1893, Jules Emile Péan inserted a platinum cylinder with a rubber head in a 37-years-old patient with tuberculosis of the shoulder. The survival of the prosthesis was 2 years.<sup>[1]</sup> Since then

both design and survival rates have improved significantly. Modern shoulder replacement was introduced by Neer in the 1950s for the treatment of proximal humeral fractures.<sup>[2,3]</sup> Subsequent modifications and the introduction of glenoid resurfacing broadened the indications to other disease processes, including end-stage glenohumeral osteoarthritis. If non-operative treatment for osteoarthritis fails, the surgical options

Access this article online

Website:

[www.internationalshoulderjournal.org](http://www.internationalshoulderjournal.org)

DOI:

10.4103/0973-6042.118915

Quick Response Code:



Departments of Orthopaedic Surgery, <sup>1</sup>OLVG, Amsterdam, <sup>2</sup>Gemini Hospital, Den Helder, <sup>3</sup>Amphia Hospital, Breda, The Netherlands

Address for correspondence:

Dr. Michel P.J. Van Den Bekerom, Department of Orthopaedic Surgery, OLVG, P.O. Box 95500, Oosterpark 9, 1090 HM Amsterdam, The Netherlands. E-mail: [bekerom@gmail.com](mailto:bekerom@gmail.com)

Please cite this article as: van den Bekerom MP, Geervliet PC, Somford MP, van den Borne MP, Boer R. Total shoulder arthroplasty versus hemiarthroplasty for glenohumeral arthritis: A systematic review of the literature at long-term follow-up. *Int J Shoulder Surg* 2013;7:110-5.

commonly considered are humeral head arthroplasty (HA) (with or without the stem) and total shoulder arthroplasty (TSA). The optimal surgical treatment of end-stage primary glenohumeral osteoarthritis remains controversial. HA has the benefits of decreased operative time, decreased blood loss and less technical difficulty, yet there is concern regarding the progression of glenoid arthritic changes even with bone loss and the need for future revision surgery or conversion to TSA.<sup>[4]</sup> TSA is associated with increased operative time and blood loss, is technically more challenging and incurs risks of potential glenoid loosening and polyethylene wear.

Radnay *et al.*<sup>[5]</sup> performed a systematic review and meta-analysis regarding the treatment of primary glenohumeral osteoarthritis and concluded that in comparison with HA, TSA significantly improves pain relief, range of motion and patient satisfaction and has a significantly lower rate of revision surgery. However, this conclusion is not based on the long-term outcome studies.

When deciding to perform a HA or a TSA two factors are very relevant, the possibility of glenoid loosening in TSA versus the possibility of glenoid erosion when performing a HA. The most common databases were assessed to compare the revision rates of both types of arthroplasty with long-term follow-up. The objective of this article is to systematically review the current available literature to formulate evidence-based guidelines to treat glenohumeral arthritis with arthroplasty. Secondly, we will formulate guidelines and recommendations for future research.

## MATERIALS AND METHODS

### Inclusion and exclusion criteria

We reviewed the titles and abstracts of all relevant articles from 1990 onward. A predefined set of criteria was followed to determine whether or not to include the material. Relevant data was selected from articles written in the English, German and Dutch languages in which arthroplasty were used as the form of treatment for glenohumeral osteoarthritis. All treatments comprised of a minimal follow-up of 7 years and all types of glenohumeral osteoarthritis were included (idiopathic, rheumatic, post-traumatic, osteonecrosis, rotator cuff arthropathy). Gleno-humeral osteoarthritis was defined as a joint disease and further characterized by several factors—loss of cartilage, subchondral sclerosis, cyst formation, deterioration of the joint and the formation of new bone (osteophytes) around the joint. History, physical examination and radiographs were all used to determine a diagnosis.

Articles concerned with arthroplasties performed after a proximal humeral or glenoid fracture or with additional bone grafting and biologic resurfacing of the glenoid were not considered. Excluded from the review were articles reporting on the results of revision operations or articles dealing with biochemical studies as well as

any article concentrating on the survival of the glenoid component or stem. Articles that did not report on new patient series, such as review articles and expert opinions were not used. In addition, abstracts of scientific meetings that were not published as full text articles were not considered and any case reports on 5 or less patients were excluded. Any data presented in more than one article was only included once.

### Identification of studies

A wide-ranging and comprehensive search was performed with the assistance of a clinical librarian. This search was limited to adult patients and included the following Mesh terms: Shoulder, arthroplasty, revision, survival, complication, function, pain, outcome, humerus and glenoid [Figure 1]. The PubMed/MedLine, Cochrane Clinical Trial Register and Embase databases were searched for studies performed from 1990 to October 2011. All resulting publications were additionally manually checked to verify that they met the inclusion criteria. A review of the title and abstract was performed in order to identify the relevant articles. The above mentioned criteria were then applied to the full text to determine articles for inclusion in this review. The reviews were done independently by MB and PG with disagreements handled through a group discussion. Disagreements that remained unresolved were handled through arbitration by a third author, MS. Studies were not blinded for author, affiliation and source.

### Data extraction

Once the initial review of the articles was complete, several data points were collected from the articles meeting the inclusion criteria: Number of patients, gender, age and type of arthroplasty, follow-up, function, pain, revision rate and general complications. A further review was done to reassess the data and determine if any of the articles met the inclusion criteria. Most studies had differing inclusion criteria, resulting in a different outcome measures. This prohibited a proper meta-analysis and comparison. The following outcome measures were compared: Pain scores, functional outcome, revision rate, complication rate and range of motion.

### Quantitative analysis

The results of the included studies were pooled for dichotomous and continuous outcome measures. Dichotomous outcome measures were compared with the Chi-square test.

For continuous outcome measures, a weighted mean was calculated based on the means (and the standard deviation

Shoulder arthroplasty OR shoulder arthroplasties  
OR total shoulder replacement OR total shoulder  
arthroplasty OR humeral head replacement OR shoulder  
hemiarthroplasty OR shoulder hemiarthroplasties  
OR shoulder hemi-arthroplasties OR shoulder hemi-  
arthroplasty) AND (osteoarthritis OR arthritis)

**Figure 1:** PubMed/MedLine search strategy

[SD's]) of the included studies. Lack of adequate reporting of the SD's prohibited a statistical evaluation and comparison of two types of arthroplasties for continuous outcome measures. A *P* value of less than 0.05 was considered significant.

## Methodological quality

In order to determine methodological quality, the studies were accessed and assigned a level of evidence defined by the Centre for Evidence Based Medicine (<http://www.cebm.net>). In general, the following levels are defined in studies on therapy or prognosis: Level I is attributed to well-designed and performed randomized controlled trials; Level II is attributed to cohort studies; Level III is attributed to case control studies; Level IV is attributed to case series; and Level V is attributed to expert opinion articles [Table 1]. These evidence levels were assigned by the two authors, XX and XX, with disagreement resolved through discussion. Recommendations for clinical practices were formulated based on the level assigned and a grade was added. Grade A meant treatment options were supported by strong evidence (consistent with Level I or II studies); Grade B meant treatment options were supported by fair evidence (consistent with Level III or IV studies); Grade C meant treatment options were supported by either conflicting or poor quality evidence (Level IV studies); and Grade D was used when insufficient evidence existed to make a recommendation [Table 2].

## RESULTS

The initial search resulted in 832 hits. After applying the in- and exclusion criteria, we identified 18 series that report on the results of TSA,<sup>[6-17]</sup> or HA<sup>[5,12,18-21]</sup> [Figure 2]. The included studies are summarized in Table 3. All studies were case series (level of evidence: IV). The first study was published in 1995<sup>[5]</sup> and the most recent in 2011.<sup>[14,18]</sup> 11 series were from the US and seven were from Europe. The smallest study was from Betts *et al.*<sup>[6]</sup> and the largest from Walch *et al.*<sup>[14]</sup> The search included a total of 1958 patients (HA: 307 and TSA: 1642) with 2111 shoulders (HA: 319 + TSA: 1783) in both groups. The mean age in the HA group was 55 years and 64 years in the TSA group. The male/female ration in the HA group was 1/1.1 and 1/2.5 in the TSA group. The shoulder pathologies for which the arthroplasty was performed are summarized in Table 4.

As many studies did report a mean for continuous outcome measures, but without a SD, we calculated a weighted mean as a result no statistical comparison was possible due to the lack of reporting SD's. Pooling of functional outcome data and pain scores was not possible subsequent to a lack of data.

## Revisions

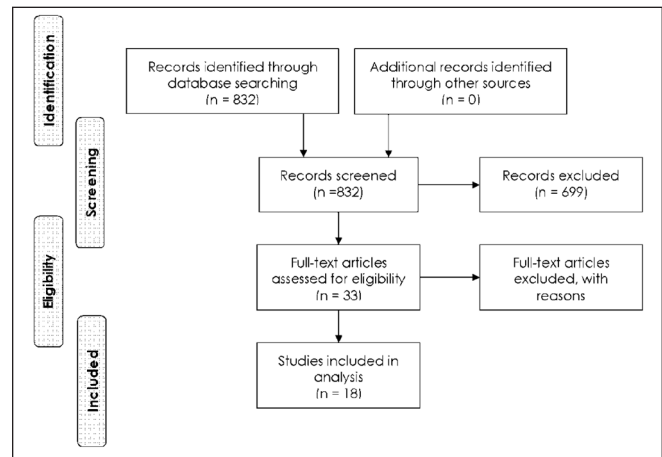
Revision rate was reported by all but one study.<sup>[11]</sup> The revision rate for any reason in the HA group (13%) was higher than in the TSA group (7%) (*P* < 0.001). No difference was made between revisions of the humeral or glenoid component. The revision rate was calculated of all 1884 (328 HA + 1556 TSA)

**Table 1: Levels of evidence in intervention studies**

Level I	High quality prospective randomized clinical trial
Level II	Prospective comparative study
Level III	Retrospective case control study
Level IV	Case series
Level V	Expert opinion

**Table 2: Grades of recommendation (given to various treatment options based on the level of evidence supporting that treatment)**

Grade A	Treatment options are supported by strong evidence (consistent with Level I or II studies)
Grade B	Treatment options are supported by fair evidence (consistent with Level III or IV studies)
Grade C	Treatment options are supported by either conflicting or poor quality evidence (Level IV studies)
Grade D	When insufficient evidence exists to make a recommendation



**Figure 2:** Flowchart summarizing the selection procedure for the articles eligible for systematic reviewing

shoulders. In the HA group five revisions were performed for other reasons than painful glenoid or glenoid arthritis. Almost all patients with glenoid erosion were revised to a TSA.

## Complications

Complication rate was reported by all studies; although, the exact type of complication was not mentioned in all articles. There was a trend of a higher complication rate (of any kind) in the TSA group (12%) when compared with the HA group (8%) (*P* = 0.065). This rate could be calculated over 1746 (328 HA + 1418 TSA) shoulders.

## Range of movement

Improvement in the range of movement was reported by all series in the HA group<sup>[5,12,18-21]</sup> and by ten series in the TSA group.<sup>[8-17]</sup> The weighted mean improvement in anteflexion, exorotation and abduction were respectively 33°, 15° and 31° in the HA group. The weighted mean improvement in anteflexion, exorotation and abduction were respectively 56°, 21° and 48° in

**Table 3: Characteristics of included studies**

Author	Year	Country	n=shoulder (patients)	Type of prosthesis
<b>Hemi arthroplasty</b>				
Bartelt <i>et al.</i> <sup>[18]</sup>	2011	USA	20	13 Cofield, 5 Bio-modular, 1 Neer, 1 Howmedica (cemented)
Krishnan <i>et al.</i> <sup>[19]</sup>	2007	USA	36 (34)	10 cemented and 26 cementless
Rispoli <i>et al.</i> <sup>[20]</sup>	2006	USA	51	29 Neer II, 18 Cofield, 4 Bio-modular
Sperling <i>et al.</i> <sup>[12]</sup>	2007	USA	95	Only totals for HA and TSA were reported
Cofield <i>et al.</i> <sup>[5]</sup>	1995	USA	67 (64)	Uncemented humeral head replacement and 1 cemented
Wirth <i>et al.</i> <sup>[21]</sup>	2006	USA	50 (43)	DePuy global shoulder modular prosthesis
<b>Total shoulder arthroplasty</b>				
Betts <i>et al.</i> <sup>[6]</sup>	2009	Scotland	14 (12)	Neer II, glenoid cemented, humerus uncemented
Deshmukh <i>et al.</i> <sup>[7]</sup>	2005	USA	320 (267)	Neer II (287), Kirschner II (16), Gristina (13), Dana (2), Cofield (1), Michael-Reese (1)
Kasten <i>et al.</i> <sup>[8]</sup>	2010	Germany	96 (88)	Tornier cemented keeled PE glenoid and 93 cemented Tornier stem, 3 uncemented Tornier
Khan <i>et al.</i> <sup>[9]</sup>	2009	UK	25	Aequalis
Raiss <i>et al.</i> <sup>[10]</sup>	2008	Germany	21	Aequalis
Rosenberg <i>et al.</i> <sup>[11]</sup>	2007	UK	90	Uncemented bio-modular
Rosenberg <i>et al.</i> <sup>[11]</sup>	2007	UK	103	Initial Nottingham uncemented
Rosenberg <i>et al.</i> <sup>[11]</sup>	2007	UK	34	Recent Nottingham
Sperling <i>et al.</i> <sup>[12]</sup>	2007	USA	187	Only totals for HA and TSA were reported
Tammachote <i>et al.</i> <sup>[13]</sup>	2009	USA	100 (94)	Neer II, metal backed glenoid or PE
Walch <i>et al.</i> <sup>[15]</sup>	2011	Europe	333 (295)	Aequalis, cemented PE convex-back keeled glenoid component
Torchia <i>et al.</i> <sup>[17]</sup>	1997	USA	114 (101)	Neer press-fit or cemented humeral component, glenoid cemented PE
Young <i>et al.</i> <sup>[15]</sup>	2011	France	263 (247)	Aequalis, cemented 3 <sup>rd</sup> gen, keeled flat back PE
Taunton <i>et al.</i> <sup>[16]</sup>	2008	USA	83 (78)	Uncemented humeral and metal backed glenoid component

HA=Head arthroplasty; TSA=Total shoulder arthroplasty; PE=Poly-ethylene

**Table 4: Results**

Type arthroplasty	HA	TSA
Articles	6	12
Patients	307	1642
Shoulders	319	1783
Mean age	55	64
Male/female	1/1.1	1/2.5
OA/AVN/RA/other or unknown*	178/6/127/17	950/7/303/458
Revisions (for any reason)**	42/328=13%	109/1556=7%***
Complications	26/328=8%	168/1418=12%****
Improvement in anteflexion	33°	56°
Improvement in exorotation	15°	21°
Improvement in abduction	31°	48°
Pain decrease	4.2	5.5

\*This ratio does not correspond with total included patients at baseline;

\*\*Not all articles report revision rate; \*\*\* $\chi^2$ ,  $P<0.001$ ; \*\*\*\* $\chi^2$ ,  $P=0.065$ .

HA=Head arthroplasty; TSA=Total shoulder arthroplasty; OA=Osteoarthritis; AVN=Avascular necrosis; RA=Rheumatoid arthritis

the TSA group. A statistical comparison was not possible due to the missing SD's reported in the included articles.

### Pain decrease

Four studies concerning TSA<sup>[6,9,12,16]</sup> and 4<sup>[12, 18, 20,21]</sup> reporting a decrease in pain after HA were included in this analysis. Mean decrease in pain scores was 4.2 in the HA group and 5.5 in the TSA group. Scores reported on a 5 point scale were calculated

to a 10 point scale and pain scores from constant scores were not included in this analysis.

## DISCUSSION

The objective of this systematic review was to collect evidence concerning the long-term outcome of HA and TSA and to compare these two treatments. After including 18 articles, we concluded that TSA results in less revision surgery, but results in more complications. This is the first review with a strict methodology based on a large sample size, which compares the long-term (mean FU of included studies was at least 7 years) outcome of HA and TSA for osteoarthritis of the shoulder.

The conclusions of this review should be interpreted with caution due some limitations. Firstly, only Level IV studies could be included; there are no randomized or controlled trials with a long-term (>7 years) follow-up. There are differences in some baseline characteristics and duration of follow-up between the 2 groups. A relation between underlying diagnosis and risk of revision of both arthroplasties was described.<sup>[22]</sup> There is also a relation between gender and revision rates, with male gender having twice the risk of revision of shoulder arthroplasties.<sup>[23-25]</sup> Based on a series of patients with a TSA, Henn *et al.* concluded that younger patients have greater expectations of a TSA, which may have implications for the



outcome and implant longevity.<sup>[26]</sup> Farnig *et al.*<sup>[27]</sup> concluded that implant survival is largely driven by factors associated with increased activity and age. We did not evaluate body mass index and comorbidities as these were not associated with an increased risk of revision.<sup>[22]</sup>

There are only 18 publications, which report on the long-term results of total or hemi shoulder arthroplasty. This low number is astonishing when considering the increasing number of shoulder arthroplasties performed annually in the western world.<sup>[28]</sup> And that the first arthroplasty was performed in 1893, with the shoulder arthroplasty being popularized in the fifties by Neer.<sup>[23]</sup>

Comparison of the continuous outcome measures (pain, range of movement) was not possible due to lack of reporting of SD's in the original articles. The differences between anteflexion, exorotation and abduction were in favor of the TSA, respectively 23°, 6° and 17°.

Many studies are performed by high volume and designer groups so the results will probably be better than in lower volume centers. Hammond *et al.* conclude that patients of surgeons with higher average annual caseloads of TSA and HA have decreased complication rates and hospital lengths of stay compared with patients of surgeons who perform fewer of these procedures.<sup>[29]</sup>

We included articles from 1990 (with minimal follow-up of 7 years) so all arthroplasties performed from 1983 and later will be included in our analysis. The design of the arthroplasties and especially of the glenoid components has improved in these years. Strauss *et al.*<sup>[28]</sup> reviewed the literature and concluded that no definitive conclusions can be made with respect to an optimal design. Biomechanical and early clinical data indicate that pegged, curved-back, cemented prostheses with a radial mismatch of 4-7 mm provides an improved opportunity for stable long-term fixation, provided that it is implanted with the most advanced cement preparation techniques, in the proper version and is fully seated.<sup>[28]</sup>

Current review and other recent other systematic reviews<sup>[25,30,31]</sup> conclude that TSA has some advantages over HA. Despite this, many HAs are still used for primary glenohumeral arthritis.<sup>[32]</sup> We propose careful consideration of both options, but analysis of existing evidence shows a preference toward TSA. Some surgeons state that a HA can always be converted to a TSA in cases of symptomatic glenoid erosion. Carroll *et al.* however, concluded that the results of a revision of a HA to a TSA are inferior to those of primary TSA and this operation should be considered as a salvage procedure.<sup>[4]</sup>

For future research projects, it would be interesting to report the long-term results of previously reported RCT's or to initiate a large multicenter trial. Ideally, these long-term follow-up multicenter trials would have a sample size calculation, use computer randomization, would focus on patient related outcome measures and would have blinding of the patients and outcome assessors.

## CONCLUSIONS

1. TSA results in less need for revision surgery when compared to hemiarthroplasty (Grade C).
2. TSA has a trend to result in more complications when compared to hemiarthroplasty (Grade C).

## ACKNOWLEDGMENT

This study was presented on the Annual Amphibia Shoulder Meeting. The authors are grateful to Hanny Vriends for her help with the systematic search and collecting the required articles. The authors did not receive any outside funding or grants in support of their research for or preparation of this work. Neither they nor a member of their immediate families received payments or other benefits or a commitment or agreement to provide such benefits from a commercial entity. No commercial entity paid or directed or agreed to pay or direct, any benefits to any research fund, foundation, division, center, clinical practice or other charitable or non-profit organization with which the authors or a member of their immediate families, are affiliated or associated.

## REFERENCES

1. The classic: On prosthetic methods intended to repair bone fragments. *Clin Orthop Relat Res* 1973;94:4-7.
2. Neer CS 2<sup>nd</sup>. Articular replacement for the humeral head. *J Bone Joint Surg Am* 1955;37-A:215-28.
3. Neer CS 2<sup>nd</sup>. Indications for replacement of the proximal humeral articulation. *Am J Surg* 1955;89:901-7.
4. Carroll RM, Izquierdo R, Vazquez M, Blaine TA, Levine WN, Bigliani LU. Conversion of painful hemiarthroplasty to total shoulder arthroplasty: Long-term results. *J Shoulder Elbow Surg* 2004;13:599-603.
5. Cofield RH, Frankle MA, Zuckerman JD. Humeral head replacement for glenohumeral arthritis. *Semin Arthroplasty* 1995;6:214-21.
6. Betts HM, Abu-Rajab R, Nunn T, Brooksbank AJ. Total shoulder replacement in rheumatoid disease: A 16- to 23-year follow-up. *J Bone Joint Surg Br* 2009;91:1197-200.
7. Deshmukh AV, Koris M, Zurakowski D, Thornhill TS. Total shoulder arthroplasty: Long-term survivorship, functional outcome, and quality of life. *J Shoulder Elbow Surg* 2005;14:471-9.
8. Kasten P, Pape G, Raiss P, Bruckner T, Rickert M, Zeifang F, *et al.* Mid-term survivorship analysis of a shoulder replacement with a keeled glenoid and a modern cementing technique. *J Bone Joint Surg Br* 2010;92:387-92.
9. Khan A, Bunker TD, Kitson JB. Clinical and radiological follow-up of the aequalis third-generation cemented total shoulder replacement: A minimum ten-year study. *J Bone Joint Surg Br* 2009;91:1594-600.
10. Raiss P, Aldinger PR, Kasten P, Rickert M, Loew M. Total shoulder replacement in young and middle-aged patients with glenohumeral osteoarthritis. *J Bone Joint Surg Br* 2008;90:764-9.
11. Rosenberg N, Neumann L, Modi A, Mersich IJ, Wallace AW. Improvements in survival of the uncemented Nottingham total shoulder prosthesis: A prospective comparative study. *BMC Musculoskelet Disord* 2007;8:76.
12. Sperling JW, Cofield RH, Schleck CD, Harmsen WS. Total shoulder arthroplasty versus hemiarthroplasty for rheumatoid arthritis of the shoulder: Results of 303 consecutive cases. *J Shoulder Elbow Surg* 2007;16:683-90.
13. Tammachote N, Sperling JW, Vathana T, Cofield RH, Harmsen WS, Schleck CD. Long-term results of cemented metal-backed

- glenoid components for osteoarthritis of the shoulder. *J Bone Joint Surg Am* 2009;91:160-6.
14. Walch G, Young AA, Melis B, Gazielly D, Loew M, Boileau P. Results of a convex-back cemented keeled glenoid component in primary osteoarthritis: Multicenter study with a follow-up greater than 5 years. *J Shoulder Elbow Surg* 2011;20:385-94.
  15. Young A, Walch G, Boileau P, Favard L, Gohlke F, Loew M, et al. A multicentre study of the long-term results of using a flat-back polyethylene glenoid component in shoulder replacement for primary osteoarthritis. *J Bone Joint Surg Br* 2011;93:210-6.
  16. Taunton MJ, McIntosh AL, Sperling JW, Cofield RH. Total shoulder arthroplasty with a metal-backed, bone-ingrowth glenoid component. Medium to long-term results. *J Bone Joint Surg Am* 2008;90:2180-8.
  17. Torchia ME, Cofield RH, Settergren CR. Total shoulder arthroplasty with the neer prosthesis: Long-term results. *J Shoulder Elbow Surg* 1997;6:495-505.
  18. Bartelt R, Sperling JW, Schleck CD, Cofield RH. Shoulder arthroplasty in patients aged fifty-five years or younger with osteoarthritis. *J Shoulder Elbow Surg* 2011;20:123-30.
  19. Krishnan SG, Nowinski RJ, Harrison D, Burkhead WZ. Humeral hemiarthroplasty with biologic resurfacing of the glenoid for glenohumeral arthritis. Two to fifteen-year outcomes. *J Bone Joint Surg Am* 2007;89:727-34.
  20. Rispoli DM, Sperling JW, Athwal GS, Schleck CD, Cofield RH. Humeral head replacement for the treatment of osteoarthritis. *J Bone Joint Surg Am* 2006;88:2637-44.
  21. Wirth MA, Tapscott RS, Southworth C, Rockwood CA Jr. Treatment of glenohumeral arthritis with a hemiarthroplasty: A minimum five-year follow-up outcome study. *J Bone Joint Surg Am* 2006;88:964-73.
  22. Singh JA, Sperling JW, Cofield RH. Revision surgery following total shoulder arthroplasty: Analysis of 2588 shoulders over three decades (1976 to 2008). *J Bone Joint Surg Br* 2011;93:1513-7.
  23. Fox TJ, Cil A, Sperling JW, Sanchez-Sotelo J, Schleck CD, Cofield RH. Survival of the glenoid component in shoulder arthroplasty. *J Shoulder Elbow Surg* 2009;18:859-63.
  24. Martin SD, Zurakowski D, Thornhill TS. Uncemented glenoid component in total shoulder arthroplasty. Survivorship and outcomes. *J Bone Joint Surg Am* 2005;87:1284-92.
  25. Singh JA, Sperling J, Buchbinder R, McMaken K. Surgery for shoulder osteoarthritis. *Cochrane Database Syst Rev* 2010;10:CD008089.
  26. Henn RF 3<sup>rd</sup>, Ghomrawi H, Rutledge JR, Mazumdar M, Mancuso CA, Marx RG. Preoperative patient expectations of total shoulder arthroplasty. *J Bone Joint Surg Am* 2011;93:2110-5.
  27. Farnig E, Zingmond D, Krenek L, Soohoo NF. Factors predicting complication rates after primary shoulder arthroplasty. *J Shoulder Elbow Surg* 2011;20:557-63.
  28. Strauss EJ, Roche C, Flurin PH, Wright T, Zuckerman JD. The glenoid in shoulder arthroplasty. *J Shoulder Elbow Surg* 2009;18:819-33.
  29. Hammond JW, Queale WS, Kim TK, McFarland EG. Surgeon experience and clinical and economic outcomes for shoulder arthroplasty. *J Bone Joint Surg Am* 2003;85-A:2318-24.
  30. Bryant D, Litchfield R, Sandow M, Gartsman GM, Guyatt G, Kirkley A. A comparison of pain, strength, range of motion, and functional outcomes after hemiarthroplasty and total shoulder arthroplasty in patients with osteoarthritis of the shoulder. A systematic review and meta-analysis. *J Bone Joint Surg Am* 2005;87:1947-56.
  31. Radnay CS, Setter KJ, Chambers L, Levine WN, Bigliani LU, Ahmad CS. Total shoulder replacement compared with humeral head replacement for the treatment of primary glenohumeral osteoarthritis: A systematic review. *J Shoulder Elbow Surg* 2007;16:396-402.
  32. Rasmussen JV, Jakobsen J, Brorson S, Olsen BS. The Danish shoulder arthroplasty registry: Clinical outcome and short-term survival of 2,137 primary shoulder replacements. *Acta Orthop* 2012;83:171-3.
  33. Norris TR, Iannotti JP. Functional outcome after shoulder arthroplasty for primary osteoarthritis: A multicenter study. *J Shoulder Elbow Surg* 2002;11:130-5.

**Source of Support:** Nil, **Conflict of Interest:** There are no conflicts of interest.

## New features on the journal's website

### Optimized content for mobile and hand-held devices

HTML pages have been optimized of mobile and other hand-held devices (such as iPad, Kindle, iPod) for faster browsing speed.

Click on **[Mobile Full text]** from Table of Contents page.

This is simple HTML version for faster download on mobiles (if viewed on desktop, it will be automatically redirected to full HTML version)

### E-Pub for hand-held devices

EPUB is an open e-book standard recommended by The International Digital Publishing Forum which is designed for reflowable content i.e. the text display can be optimized for a particular display device.


Click on **[EPub]** from Table of Contents page.

There are various e-Pub readers such as for Windows: Digital Editions, OS X: Calibre/Bookworm, iPhone/iPod Touch/iPad: Stanza, and Linux: Calibre/Bookworm.

### E-Book for desktop

One can also see the entire issue as printed here in a 'flip book' version on desktops.

Links are available from Current Issue as well as Archives pages.

Click on  View as eBook