

# Solitary Plexiform Neurofibroma of the Gingiva: Unique Presentation in the Oral Cavity

SURAMYA S.<sup>1</sup>, PRATIBHA SHASHIKUMAR<sup>2</sup>, SHREESHYLA H.S.<sup>3</sup>, SHEELA KUMAR G.<sup>4</sup>

## ABSTRACT

Neurofibromas are benign tumours originating from the nerve sheath. Amongst the histological variants, plexiform types are considered exclusive. These are poorly circumscribed, locally invasive and may exhibit sarcomatous potential. Plexiform neurofibromas are key features of Neurofibromatosis – 1 and their solitary intra-oral presentation is uncommon.

The following case report describes a unique case of an isolated solitary plexiform neurofibroma of the maxillary anterior gingival region in a middle aged female patient.

**Key words:** Neurofibroma, Plexiform, Anterior gingiva

## INTRODUCTION

Neurofibroma is a benign nerve sheath neoplasm of heterogenous origin. Although the specific cell type involved is controversial, based on the electron microscopic and the radiographic studies conducted schwann cells and perineural fibroblasts are the main originating cells [1].

Under the classification given by Shklar and Meyer in 1963; it can be seen as a solitary lesion or multiple as a part of generalised syndrome of Neurofibromatosis [2]. The two forms don't differ except in the presence of systemic and hereditary factors in the multiple form as a constituent of Neurofibromatosis [3]. Neurofibromatosis in itself is a genetically inherited autosomal dominant disease. The cause of a solitary neurofibroma is unknown [4]. Plexiform neurofibroma is an unusual histologic variant of neurofibroma.

Past literature reports that the frequency of solitary neurofibromas in the oral cavity remains 6.5% especially in lesions not associated with neurofibromatosis type -1 [5]. Also, the presence of a plexiform neurofibroma in the oral cavity is rare [6].

Here, we report an interesting case of a middle aged female with an unusual presentation of solitary plexiform neurofibroma in the anterior maxillary region of the gingiva. The patient exhibited no systemic manifestations of neurofibromatosis.

## CASE REPORT

A 57-year-old female patient reported to the outpatient department, Department of Periodontology, JSSDCH, with a chief complaint of a painless round soft tissue growth of the gums in the upper front region of the mouth. Following the extraction of a tooth

3 years back, the growth was first noticed by the patient. Since then, there had been gradual development of the growth to its present size. There was no history of associated pain or bleeding related to the growth.

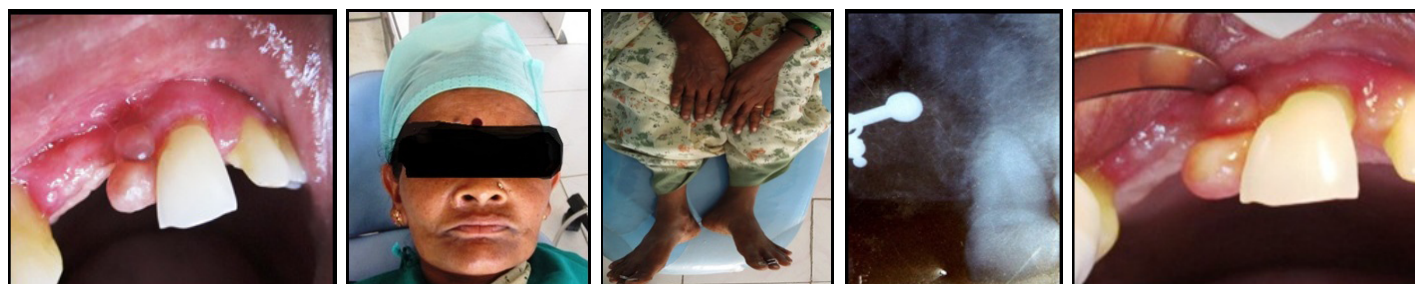On physical examination the patient appeared healthy with the normal size and weight. There the medical history was insignificant. Also, no pertinent family history of the similar growths was reported.

On intra-oral examination, there existed a peculiar growth corresponding to the edentulous area of 11 [Table/Fig-1]. The bilobulated pedunculated growth was located on the marginal ridge and extended to the palatal aspect. The two lobules were of unequal size with the smaller towards the labial aspect around 0.75mm in diameter and the bigger in the palatal aspect measuring 2mm. The mass as a whole was well circumscribed, firm in consistency and covered with normal mucosa

On extra-oral examination no such growth was noted in any other part of the body [Table/Fig-2,3]. Patient was partially edentulous. Other intra-oral findings included periodontal pockets and teeth with grade III mobility. The oral hygiene maintenance of the patient was unsatisfactory

On the basis of the clinical examination and the history given by the patient, fibro epithelial polyp and pyogenic granuloma were initially suspected. Traumatic fibroma was ruled out due to the absence of any contributory factor.

Intra-oral radiograph was advised and did not reveal any significant feature [Table/Fig-4].



[Table/Fig-1]: Intra-oral presentation of the growth

[Table/Fig-2 & 3]: Extraoral presentation of the patient - no similar growths observed

[Table/Fig-4]: No significant radiographic feature

[Table/Fig-5]: Surgical excision

Excisional biopsy of the peculiar mass followed by histopathological examination was planned as the treatment approach.

The growth was surgically excised under local anesthesia using 2% lignocaine with 1: 80,000 adrenaline [Table/Fig-5]. The lesion was held by a tissue holding forceps and removed from the base with the help of no. 15 blade. Along with it 2mm of healthy tissue was included to compare it with the normal anatomical tissue of the region. Bleeding was controlled with the help of gauze pieces. Periodontal pack was given to protect the surgical site which was removed after one week. The patient was put under analgesics for three days. No post-operative complications were reported.

The excised mass was washed with 0.9 % normal saline, stored in 10 % formalin and sent to the department of Oral Pathology for routine histopathological evaluation [Table/Fig-6]. The patient has been evaluated for 12 months post-operatively with no fresh complaints [Table/Fig-7].

On histopathologic examination the H and E stained sections showed superficial stratified squamous parakeratinized epithelium [Table/Fig-8]. Connective tissue showed presence of tumour mass consisting of cells arranged in fascicles [Table/Fig-9]. The cells were elongated and spindle shaped consisting of thin wavy nucleus and scanty cytoplasm [Table/Fig-10]. Presence of numerous nerve bundles was noted. The surrounding stroma consisted of connective tissue fibrils, fibroblasts and few blood vessels.

Based on these findings the definitive diagnosis of Plexiform Neurofibroma was given.

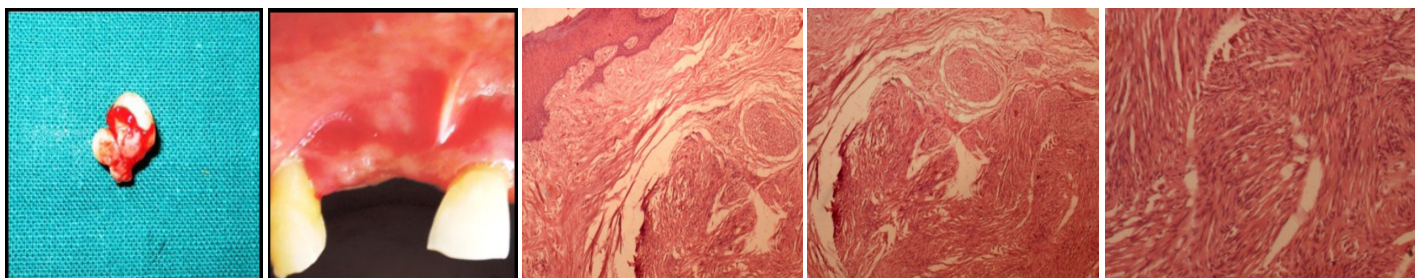
Other benign oral peripheral nerve tumours include schwannoma, nerve sheath myxoma, mucosa neuroma, palisade encapsulated neuroma, traumatic neuroma and granular cell tumor [5].

According to the available literature, among the 66 neurofibromas in the facial region, the following distribution has been found: tongue – 12; palate - 12; mandibular ridge/vestibule-15; maxillary ridge/vestibule-9; buccal mucosa -10; lip-4; mandibular intrabony – 2; gingiva-1 [10]. Thus, the tongue is the most common intra-oral site and the occurrence of neurofibroma on the gingiva as seen in this case is rare.

Previously, unilateral gingival enlargement associated with neurofibromatosis-1 has been described in a patient with neurofibroma in the attached gingival of the lingual aspect of the lower central incisors [11]. To the best of our knowledge, very few cases of isolated gingival neurofibromas not associated with systemic disease have been reported.

The differential diagnosis for other commonly seen gingival swellings include pyogenic granuloma, peripheral giant cell granuloma, peripheral fibroma, parulis, exostosis, gingival cyst, eruption cyst, congenital epulis of newborn and generalized hyperplasia [12].

Plexiform neurofibroma is a specific variant of neurofibroma exhibiting a bizarre histopathologic picture. It is poorly circumscribed, locally invasive and leads to great deal of deformity. Blending of myxoid and collagenous stromal elements is usually seen [12]. These lesions produce a typical “bag of worms” appearance. Plexiform neurofibromas are considered to be pathognomonic for



**[Table/Fig-6]:** Excised growth

**[Table/Fig-7]:** Post operative view (1month)

**[Table/Fig-8]:** Overlying epithelium and underlying connective tissue with tumor cells in well demarcated fascicles. (40)

**[Table/Fig-9]:** Nodular tumor mass consisting of nerve tissue in fascicles and irregular pattern in connective tissue (100X)

**[Table/Fig-10]:** Spindle cells with thin wavy nuclei and faint cytoplasm. (400X)

## DISCUSSION

Neurofibromatosis is a hereditary condition resulting as a widespread developmental defect of the nerve sheath [7]. Although, the disease became widely recognized as a pathological in the late 19<sup>th</sup> century: it was only recently, that its two subsets have been defined [8]. They are associated with Neurofibromatosis type-1 and Neurofibromatosis type-2 [4]. The former is more common and accounts for about 90% of the cases [9].

Neurofibromas are benign tumours of nerve cell origin. They are mostly seen as a part of neurofibromatosis-I and the presence as a solitary condition is uncommon. The World Health Organization (WHO) has subdivided neurofibromas into 2 broad categories: dermal and plexiform. Dermal neurofibromas arise from a single peripheral nerve, while plexiform neurofibromas are associated with multiple nerve bundles. Other clinicopathologic subtypes include localized neurofibroma (sporadic neurofibroma), diffuse neurofibroma, plexiform neurofibroma, and epithelioid neurofibroma [3].

Solitary neurofibroma is a benign, slowly growing, relatively circumscribed, but non encapsulated tumor diagnosed by absence of other features of the associated systemic disease. Oral lesions are associated with as much as 72% of the multiple form in patients with neurofibromatosis. Intra-oral presentation is extremely rare in case of the solitary type of neurofibromas [9].

neurofibromatosis-1 [3]. Their occurrence as a solitary form in the oral cavity is exceedingly rare [6]. They are usually diagnosed in children and occurrence after adolescence is uncommon [9].

Neurofibromas may exhibit sarcomatous alteration in 3%–15% of cases; especially in multiple neurofibromatosis [6]. Occasionally, the malignant transformation of Plexiform Neurofibroma is reported. These have poor prognosis and are designated as a malignant peripheral nerve sheath tumor [3].

The present case is unique as the presentation of lesion was sporadic and no associated family history was reported. A thorough examination of the patient was performed for the various manifestations of neurofibromatosis-1 (like cafe – au lait spots, lisch nodules, axillary freckling etc). The disease was ruled out due to the absence of the same. Clinical manifestations of neurofibromatosis have not been detected over the follow up period of 12 months. As neurofibromas are more often seen in younger individuals, the older age of this particular patient deserves special mention. Since the gingiva remains a less common intra-oral site; this further highlights the unusual nature of the present case.

Solitary neurofibromas are treated by complete excision and have little chances of recurrence [12]. Similar treatment protocol was followed for the peculiar mass in the given case. The patient had reported with no complications over the follow up period of 12 months and is kept under observation.

## CONCLUSION

The diagnosis of any intra-oral atypical growth can be challenging. On initial presentation a variety of differentials like fibroma, epulis, pyogenic granuloma etc can be suspected. These are mostly benign but may have malignant potential. Even though, the presence of growths involving the peripheral nerves in the oral cavity is not very common; if present it may lead to paresthesia or be a part of a systemic disease. Thus, clinical examination should be accompanied with histopathologic examination which remains the gold standard. Considering the risk of adversities posed by such abnormal growths, prompt treatment should be administered and the patient should be kept on follow up.

## REFERENCES

- [1] Holt J. Neurofibromatosis in children. *AJR*. 1978; 130:615-39.
- [2] D Richards. Neurofibroma of the oral cavity. *British journal of the oral surgery*. 1983; 21:36-43.
- [3] Indraneel Bhattacharya. Oral neurofibroma. Medscape reference-Drugs, diseases and procedures: Update August 2011.
- [4] Shafers, Hiney, Levy. Shafers textbook of oral pathology. Sixth edition. Elsevier. 2010: 198.
- [5] Marcia Sampaio Campos, et al. Clinicopathologic and immunohistochemical features of oral neurofibroma. *Acta odontologica scandinavica*. 2012; 70:577-82.
- [6] C Alati, et al. Solitary plexiform neurofibroma of the oral cavity. A case report. *International journal of oral maxillofacial surgery*. 1966; 25:379-80.
- [7] RB Lucas. Pathology of tumours of the oral tissues. Fourth edition. *Churchlivingstone* 1984: 213-17.
- [8] Ahn MS, et al. The early history of the neurofibromatosis. Evolution of the concept of neurofibromatosis type 2. *Archives of Otolaryngology - Head and Neck Surgery*. 1996 Nov;122(11):1240-9.
- [9] NP Zwane, et al. Solitary oral plexiform neurofibroma: review of literature and report of a case. *Oral oncology*. 2011: 47; 449-51.
- [10] Motoyoshi et al. solitary neurofibroma of the floor of the mouth: a case report. *Case reports in otolaryngology*. 2011:3 pages.
- [11] Bekisz, et al. Diffuse but unilateral gingival enlargement associated with von Recklinghausen neurofibromatosis: A case report. *Journal of clinical periodontology*. 2000;27 (5):361-5.
- [12] Regezi JA, Sciubba J. Oral Pathology: Clinical-Pathologic Correlations. Fifth Edition. *Saunders*. 2003:37-38,172.

### PARTICULARS OF CONTRIBUTORS:

1. Post Graduate Student, Department of Periodontology, JSS Dental College and Hospital, Mysore, Karnataka, India.
2. Reader, Department of Periodontology, JSS Dental College and Hospital, Mysore, Karnataka, India.
3. Lecturer, Department of Oral Pathology, JSS Dental College and Hospital, Mysore, Karnataka, India.
4. Professor and Head, Department of Periodontology, JSS Dental College and Hospital, Mysore, Karnataka, India.

### NAME, ADDRESS, E-MAIL ID OF THE CORRESPONDING AUTHOR:

Dr. Suramya S.  
Post Graduate Student, Department Of Periodontology, Jss Dental College And Hospital, Mysore, Karnataka, India.  
Phone: 9886550945, E-mail: suramya.1986@gmail.com

Date of Submission: **May 22, 2013**  
Date of Peer Review: **Jun 24, 2013**  
Date of Acceptance: **Jul 25, 2013**  
Date of Online Ahead of Print: **Aug 10, 2013**  
Date of Publishing: **Sept 10, 2013**

FINANCIAL OR OTHER COMPETING INTERESTS: None.