

## THE AZYGOS LOBE OF THE LUNG

BY E. H. SHANNON,

*Radiologist, St. Michael's Hospital,**Toronto*

IN the course of routine radiographic examinations of the chest, extending over a period of several years, an abnormality in the right upper lung was noted on two or three occasions, the nature of which was obscure. This abnormality took the form of a curved linear shadow running downwards and somewhat outwards from the apical region to a variable distance from the lateral aspects of the vertebræ, then passing in a smooth curvature

mesially and downwards to about the level of the second costal cartilage. At the lower end the shadow expanded into an elongated and roughly triangular density which varied in size from 0.5 to 3 mm. In one case the shape assumed was cylindrical, the diameter being about 3 mm. over a length of about 3.5 cm. It was felt, in the first instance met with, that the condition might represent a pleural band, though its general contour and

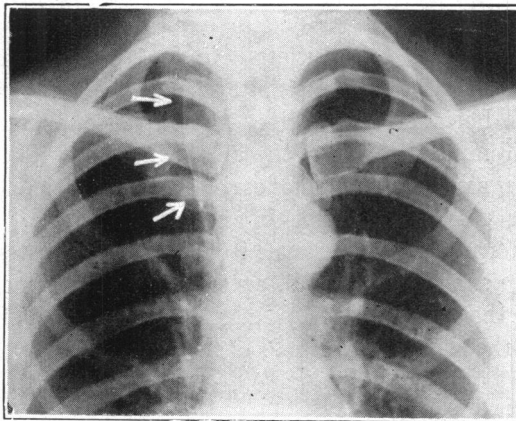


FIG. 1.—(Case 1). Age 33. Azygos lobe is clearly outlined. No important chest findings.

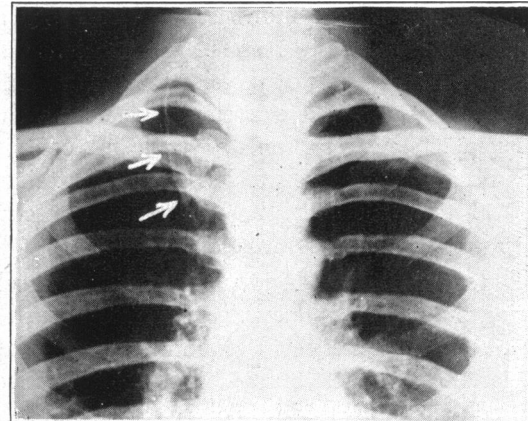


FIG. 2.—(Case 2). Age 33. Referred for roentgen examination of heart. No important chest findings. Arrows indicate pleural reflection of azygos lobe.

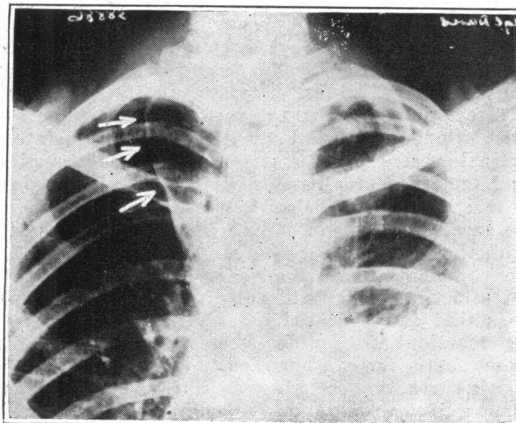


FIG. 3.—(Case 3). Age 18. Azygos lobe shown in right upper lobe. Infiltration upper third both lungs, involving azygos lobe on right side, with effusion in left base.

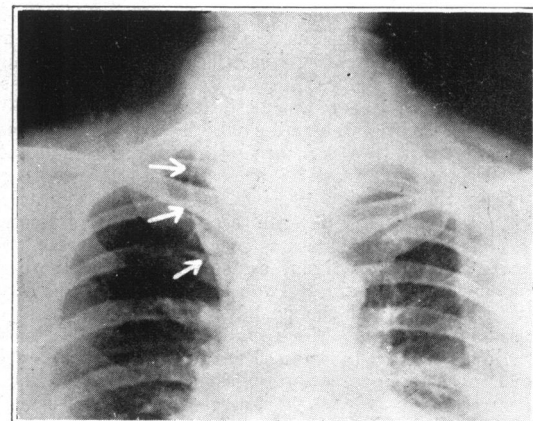


FIG. 4.—(Case 4). Age 42. Colloid goitre. Referred to demonstrate possible substernal thyroid. Typical azygos lobe and with shadow of a small substernal thyroid visible on both sides.

symmetry were rather against this view. The abnormality was not associated with deviation of the trachea, such as would probably have been present had the condition been due to a substernal thyroid, nor was the appearance that of a large persisting thymus gland. Later, when a second, almost identical, case was found, it was apparent that we were dealing with a condition the identity of which was not established and which probably was developmental.

Reference was made to the work of Wessler and Jaches<sup>1</sup> who, it was found, had in 1923 reported a similar falciform shadow presenting the general form mentioned above. These authors observed that the shadow was always found on the right side in the apical region, and, while its significance was not clear, they believed it to have no clinical importance. A subsequent review of the literature showed that Velde,<sup>2</sup> in 1927, had suggested that the cause of the x-ray shadow might be an azygos lobe of the lung, but had been unable to confirm his opinion by post-mortem findings. The first mention of the existence of an accessory lobe in the right apex was found to have been made by Wrisberg in 1778 from anatomical studies, the structure being therefore sometimes designated the *lobus Wrisbergi*. In 1928, Bendick and Wessler<sup>3</sup> described a series of 50 cases showing this condition, seen over a period of 15 years, in which the presence of an azygos lobe had in 2 instances been confirmed by autopsy. Stoloff,<sup>4</sup> in 1929, published a report of 6 cases. St. Craur,<sup>5</sup> in the same year, described briefly 3 cases of azygos lobe and also observed the fact that a substernal thyroid gland, a large thymus and pleuritic bands simulated the anomaly. Nelson and Simon<sup>6</sup> recently have reported 4 more cases.

Normally, the azygos vein proceeds up the posterior mediastinum on the anterior surfaces of the vertebral bodies slightly to the right of the mid-line, passing over the intercostal arteries, with the thoracic aorta and thoracic duct to the left. At the fourth, or sometimes the third, dorsal vertebra it bends forward and to the right, curves over the right bronchus and right pulmonary artery, and descends slightly to open into the posterior surface of the superior vena cava.

In describing variations of the lobes and fissures, Piersol<sup>7</sup> remarks that "the azygos major vein may be displaced outwards so that, instead of curving over the root of the lung, it may make a deep fissure in the upper part of the lung, marking off an extra lobe." It is apparent that the lateral displacement of the vein represents a maintenance of its fetal position. It has, moreover, been shown, by injection of the bronchial tree in the post-mortem specimen, that the supply of the azygos lobe is derived from a branch of the eparterial bronchus. Had the accessory lobe originated as a primary developmental defect its bronchus would have been given off as a separate branch from the right main trunk.<sup>3</sup>

The reflection of the parietal pleura resulting from the aberrant course of the vein as it sweeps forward and downward through the lung is responsible for the fine crescentic shadow in the apical region, the pleura being visualized by reason of an antero-posterior projection which shows it, as it were, edge on. The expanded triangular lower end of the curved line is due to a cross-sectional view of the vena azygos at its point of confluence with the superior caval vein. The size of the lobe thus demarcated may be so small as to be concealed by the great vessels, or may be of the size shown in the accompanying roentgenograms. A slight obliquity in the course of the vein, or a film centred above or below it in the horizontal plane, will project its shadow as a drop-like structure, or show it as an elongated triangular or cylindrical density.

The anomaly must be differentiated from a substernal thyroid gland, a large thymus, and pleural bands, as observed above. In addition, Gianturco<sup>8</sup> remarks that the structure may be simulated by the edge of an annular bronchiectasis at the apex, by the edge of cavities and of a spontaneous circumscribed pneumothorax.

The 4 cases here described are presented merely to direct attention to the structure, the recognition of which, as will be seen, has been accomplished only comparatively recently. There are no features in any of the cases of particular interest clinically. Case 3 presented the typical radiographic appearance of a tuberculous infection involving the upper third of both lungs, with pleuritis with effusion at the left base, the distribution and character of the

infiltration in the right apical region being in nowise changed by the pleural reflection of the azygos lobe. A case of pleural effusion of the fissure has been reported, and Müller cites an instance in which the bronchus was so narrowed by pressure from the aberrant azygos vein that multiple dilatations and diffuse fibrosis of the lobe resulted. The chief importance however of the recognition of the anomaly lies in the avoidance of erroneous in-

terpretations of its structure in terms of disease.

## REFERENCES

1. WESSLER AND JACHES, *Clinical Roentgenology of Diseases of the Chest*, The Southworth Co., Troy, N.Y., 1923, 17.
2. VELDE, *Fortschr. a. d. Geb. d. Röntgenstrahlen*, 1927, 36: 315.
3. BENDICK AND WESSLER, *Am. J. Roent. Rad. Therapy*, 1928, 20: 1.
4. STOLOFF, *Am. J. Roent. Rad. Therapy*, 1929, 22: 465.
5. ST. CLAUDE, *Quint. Med.*, 1929, 10: 479.
6. NELSON AND SIMON, *Brit. M. J.*, 1931, 1: 9.
7. PIEBOLS, *Human Anatomy*, J. B. Lippincott Co., Phila., 4th Ed., 1846.
8. GIANTURCO, *Arch. di Radiol.*, 1929, 7: 745.

### ACUTE MERCURY POISONING: REPORT OF TWENTY-ONE CASES WITH SUGGESTIONS FOR TREATMENT

BY B. I. JOHNSTONE, B.Sc., M.B.

*From the Department of Medicine, Henry Ford Hospital*

*Detroit*

MERCURY compounds have been used in medicine for centuries, but only within the past fifty years has acute mercury poisoning assumed an important rôle. About 1880, bichloride solutions began to be used as antiseptics, and their introduction resulted in a sudden and large increase in the number of reported instances of mercury poisoning. These commonly followed irrigation of the vagina, uterus or surgical wounds. Moreover, within the past two decades, mercury compounds have become more commonly used as suicidal or homicidal agents.

Between the years 1918 and 1928, 21 patients with acute mercury poisoning were treated in the Henry Ford Hospital. The main details regarding them are outlined in the accompanying table and are used as a basis for a discussion of the problem. All preparations of mercury are poisonous if absorbed, and once the drug has entered the circulation the mode of action in each case is very similar. Death has been reported as having been due to each of the various pharmacopœal preparations. The metal volatilizes at temperatures above 41° C. and the vapour is quite poisonous. In the liquid form however metallic mercury can scarcely be considered dangerous. Instances are on record where large doses have been taken without ill effect. That small amounts are absorbed is, however, evident from the finding of the metal in the urine of patient No. 7, who swallowed metallic mercury with suicidal intent. Such absorption is brought about by the formation of soluble mercury compounds in the intestinal tract, especially if the

metal remains in the bowel for several days. Unguentum hydrargyri dilutum is a common representative preparation into the composition of which metallic mercury enters. Poisoning from blue ointment is usually mild, as in cases Nos. 8 and 13. Death, however, may result from its use.

Mercury is commonly found in the urine of dentists and in people with amalgam tooth fillings. The tests commonly used are capable of detecting mercury in very low dilutions. Vogel and Lee's method is sensitive to 1/40 mg. in 50 c.c. of the solution to be tested, and Elliott claims that his technique can detect 1/15,000 mg. of mercury in 500 c.c. of distilled water. The amounts excreted in individuals with amalgam in the teeth are very small. It has not been proved that these quantities are harmful except in the extremely susceptible person. Martinet reports a patient in whom severe acute symptoms resulted from absorption from an amalgam tooth filling. Calomel in susceptible individuals may prove fatal and mercuric oxide, both the red and the yellow, have occasionally been the cause of death. MacNider has shown that naturally nephropathic dogs are susceptible to acute mercury poisoning and it seems reasonable to believe that patients with nephritis are less able to withstand large doses of this drug. More recently, since the introduction and intravenous use of such organic mercurial compounds as mercurochrome, metaphen, merbaphen and salyrgan, acute poisoning has occurred in susceptible individuals from their injudicious use.