

## CLINICAL TECHNIQUES AND TECHNOLOGY

# Ectopic lingual goiter treated by transoral robotic surgery

## *Gozzo della tiroide linguale asportato mediante chirurgia robotica transorale*

R. PELLINI, G. MERCANTE, P. RUSCITO, G. CRISTALLI, G. SPRIANO

Department of Otolaryngology, Head and Neck Surgery, "Regina Elena" National Cancer Institute, Rome, Italy

## SUMMARY

Multinodular goiter in lingual thyroid is quite rare. Surgical removal is indicated in symptomatic patients and when cancer is suspected. An external approach is most often used, but is associated with morbidity and sequelae. In this study, we present for the first time the technique of transoral robotic surgery (TORS) for removal of a massive lingual goiter. Prospective patient data were collected, including demographics, medical history, symptoms, comorbidities and drugs prescribed. The da Vinci Surgical System was used for a transoral approach to the oropharynx. The technique was validated in a 31-year-old woman with signs and symptoms of multinodular goiter presenting since childhood. The procedure required 115 min, with intervals as follows: tracheotomy, 25 min; robot setting time, 20 min; and console time, 70 min. TORS is feasible in cases of multinodular goiter in a lingual thyroid. The procedure appears to be safe, with quick recovery of swallowing and speech.

KEY WORDS: Lingual thyroid goiter • Transoral robotic surgery • Thyroid ectopias

## RIASSUNTO

*Il gozzo multinodulare è raramente presente a livello della tiroide linguale. L'asportazione chirurgica è indicata nei pazienti sintomatici e qualora si sospetti un cancro. L'approccio per via esterna è il più usato, ma è associato con morbilità e sequele. In questo studio, presentiamo per la prima volta, la tecnica di chirurgia robotica transorale (TORS) per la rimozione di un enorme gozzo della tiroide linguale. I dati relativi alla paziente sono stati raccolti in maniera prospettica, considerando: dati demografici, storia clinica, sintomi, comorbidità e farmaci assunti. Il "Da Vinci Surgical System" è stato utilizzato per l'approccio transorale all'orofaringe. La tecnica è stata eseguita in una donna di 31 anni con segni e sintomi di gozzo multinodulare presenti dall'infanzia. La procedura è durata 115 minuti suddivisi nei seguenti intervalli: tracheotomia, 25 minuti; installazione del robot, 20 minuti; tempo chirurgico alla console, 70 minuti. La TORS è eseguibile in caso di localizzazione di gozzo multinodulare a livello della tiroide linguale. La procedura sembra essere sicura con rapida ripresa deglutitoria e fonatoria.*

PAROLE CHIAVE: Gozzo della tiroide linguale • Chirurgia robotica transorale • Ectopie tiroidee

Acta Otorhinolaryngol Ital 2013;33:343-346

## Introduction

Lingual thyroid results from the failure of descent of the thyroid gland from the foramen cecum to a definitive position in the anterior neck. Normally, migration of the gland starts during the fourth embryonic week. The gland initially is attached to the foramen cecum by the thyroglossal duct, which atrophies beginning in the seventh embryological week. The pathogenesis of the migration defect is unclear; some Authors postulate that maternal anti-thyroid antibody inhibits growth and migration of the embryonic thyroid.

The lingual thyroid, first described by Hickman in 1869, is the most common location for thyroid ectopias, with 400 previously reported cases<sup>1</sup>, and a reported prevalence of about 1 in 200,000, with a female predilection. Lin-

gual thyroid is usually asymptomatic, and its malignant transformation is no more common than that of a normally placed thyroid gland<sup>2</sup>, with an estimated incidence of 1%<sup>3</sup>. Multinodular goiter in a lingual thyroid is quite rare, with very few cases described in the literature<sup>4,5</sup>. In about 70% of cases, lingual thyroid is the only functioning thyroid tissue<sup>6</sup> that shows symptomatic enlargement or inflammation. Diagnosis is based on physical examination and imaging<sup>7</sup>. The management of lingual thyroid includes observation, suppressive therapy, radioactive iodine treatment and surgery.

Surgery is indicated in symptomatic patients presenting with dyspnoea, dysphagia, speech impairment, throat fullness, or obstructive sleep apnoea. In most cases, a transcervical or transmandibular approach is required, with

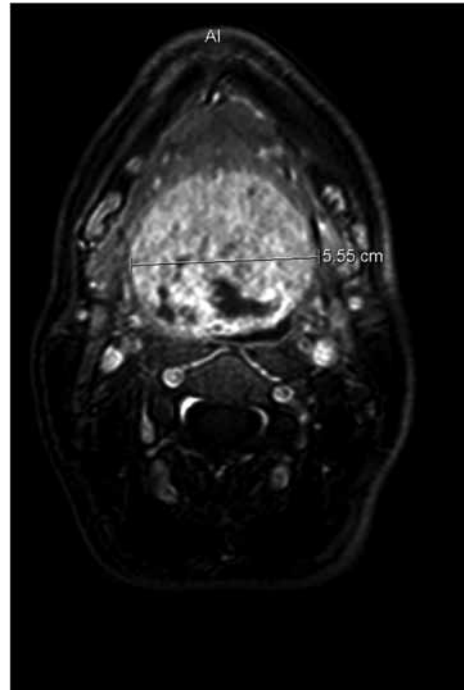
consequent morbidity related to the splitting of the lip, tongue and mandible. A minimally-invasive endoscopically guided technique for lingual thyroidectomy has been proposed by Terris<sup>8</sup>, but no case of large ectopic multinodular lingual goiter treated with a transoral approach has been reported in the literature. We present the first case of ectopic lingual goiter treated by transoral robotic surgery (TORS).

### Clinical techniques and technologies

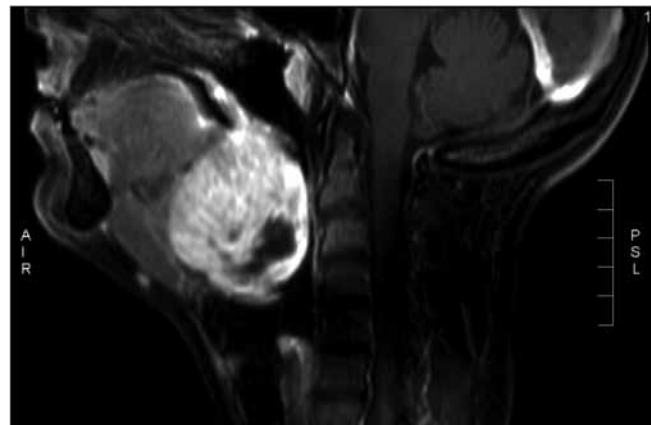
Prospective patient data were collected, including demographic information, medical history, symptoms, comorbidities and drugs prescribed. Preoperative assessment included physical examination, transnasal video endoscopy, blood tests for thyroid function assessment and head and neck magnetic resonance imaging. The local ethics committee approved the use of transoral robotic-assisted surgery for oropharyngeal tumours. The da Vinci Surgical System (Intuitive Surgical Inc, Sunnyvale, California) was used for a transoral approach to the oropharynx. Surgery was performed by a trained attending surgeon experienced in endoscopic and robotic surgery. The feasibility of the technique was validated in a 31-year-old woman who presented with the following symptoms from childhood: croaky voice, sensation of a foreign body in the throat and dysphagia. She had been on suppressive therapy (100 mcg of levothyroxine daily) since the age of 20 years. Thyroid function test results were normal, and no comorbidities were reported. Fibre-optic nasal endoscopy revealed a mass arising from the base of the tongue. MRI showed a 5.6 × 5.4 × 4.6 cm mass localized in the base of the tongue with areas of necrosis and heterogeneous contrast enhancement (as seen in large goiters) completely occluding the oropharynx (Figs. 1, 2). No thyroid tissue was present in the anterior neck.

The patient was placed on the operating table in a supine position. A tracheotomy under local anaesthesia was performed to secure the airways during conventional intubation. A cuffed tracheostomy tube was positioned using the da Vinci Surgical System. The surgeon was seated at the console and a second surgeon worked at the head of the patient. Access to the pharynx was achieved with a suspended 645001 FK retractor (Olympus®).

Three 5-mm robotic arms were employed, with a 30-degree stereoscopic high-definition video camera on the central arm, Maryland forceps to grasp and retract on the left, and a spatula cautery for dissection and coagulation on the right. The incision of the mucosal layer started from the cranial aspect of the mass at the level of foramen cecum (Fig. 3), and the goiter was progressively detached from the lingual muscles using cautery dissection. Lateral retraction of the partially detached mass allowed visualization and dissection of the lateral border of the goiter. The procedure was completed upon reaching the glosso-



**Fig. 1.** Contrast-enhanced axial T1-weighted magnetic resonance imaging showing a 5.6 × 5.4 × 4.6 cm smooth mass with a defined boundary at the base of the tongue.



**Fig. 2.** Contrast-enhanced sagittal T1-weighted magnetic resonance imaging showing a 5.6 × 5.4 × 4.6 cm smooth mass with a defined boundary at the base of the tongue.

epiglottic vallecula, with removal of the specimen in one block (Fig. 3). Adequate haemostasis was performed with an estimated blood loss of 130 ml. No reconstruction was performed, leaving the surgical bed to heal by secondary intention. The procedure required 115 min, with intervals as follows: tracheotomy, 25 min; robot setting time, 20 min; and console time, 70 min. The FK retractor was removed with no signs of tongue damage. A nasogastric feeding tube was installed, and short-term antibiotics and analgesics were delivered. The tracheostomy tube was removed 48 hours after surgery. The postoperative period was uneventful, and the nasogastric feeding tube was re-

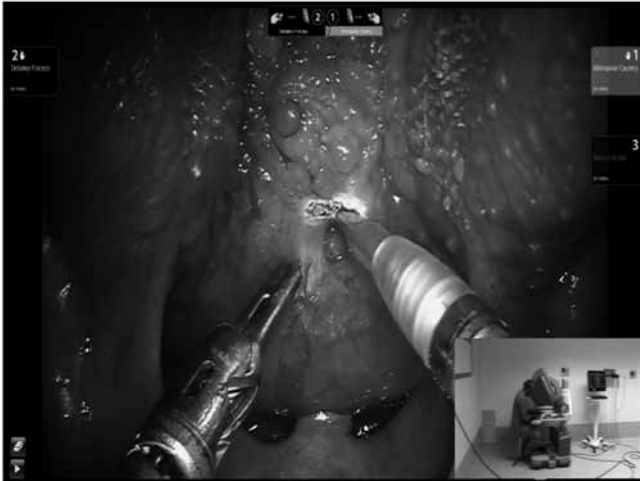

Fig. 3. TORS resection of ectopic lingual goiter.

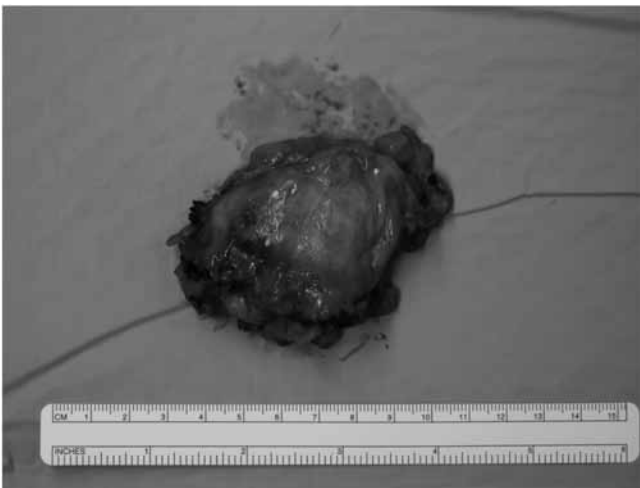


Fig. 4. The specimen was completely removed en bloc.

moved on the third postoperative day when the patient was started on a soft diet. The patient was discharged on the fourth postoperative day, and complete healing of the surgical bed was accomplished within 3 weeks. The final pathology report confirmed the diagnosis of ectopic lingual multinodular goiter.

## Discussion

Degeneration of goiter in an ectopic lingual thyroid is a rare event. Surgery is the common option for large masses, and several external approaches to the pharynx have been proposed, including transcervical<sup>10</sup> or transmandibular with or without splitting the lip and tongue<sup>11-13</sup>. These procedures allow wide exposure for safe removal of the lesion, but lead to substantial functional and aesthetic sequelae and, in most cases, prolonged hospitalization. A transoral approach has been proposed by some authors.

Visual access was provided, in most cases by endoscopic viewing, and dissection was performed using traditional instruments, CO<sub>2</sub> laser<sup>14</sup>, or harmonic shears<sup>9</sup>. TORS is presently used for different otorhinolaryngologic areas<sup>15,16</sup>. To the best of our knowledge, TORS for the treatment of ectopic lingual thyroid has not yet been described. As reported by Terris<sup>9</sup>, a transoral approach for removal of the ectopic lingual thyroid reduces hospitalization times, bleeding and morbidity related to the procedure, in comparison to external approaches. In addition to being minimally invasive, TORS provides the following advantages:

- better view of the surgical field due to high magnification, three-dimensional visualization and optical orientation;
- four-handed surgery (including the assistant), which allows tissue manipulation and retraction comparable with open surgery; and
- six degrees of motion due to wristed instruments that allow the surgeon to reach, under direct vision, areas around the corner.

The absolute local contraindication is related to the difficult exposition of the oropharynx, due to a limited opening of the mouth or the patient's habitus. TORS for treatment of ectopic lingual goiter is feasible, requires a short learning curve, and appears to be safe. Temporary tracheotomy can be useful for airway management at the induction of anesthesia, avoiding the use of a nasotracheal tube in the pharynx during surgery. TORS can be considered an effective treatment for surgical removal of ectopic lingual goiter.

## References

- 1 Hickman W. *Congenital tumour of the base of the tongue passing down the epiglottis on the larynx and causing death by suffocation sixteen hours after death (sic.)*. Trans Path Soc Lond 1869;20:160.
- 2 Toso A, Colombani F, Averono G, et al. *Lingual thyroid causing dysphagia and dyspnoea. Case reports and review of the literature*. Acta Otorhinolaryngol Ital 2009;29:213-7.
- 3 Kalan A, Tariq M. *Lingual thyroid gland: clinical evaluation and comprehensive management*. Ear Nose Throat J 1999;78:340-9.
- 4 Zackaria M, Chisholm EJ, Tolley NS, et al. *Multinodular goitre in lingual thyroid: case report*. J Laryngol Otol 2010;124:349-51.
- 5 Hze-Khoong EP, Xu L, Shen S, et al. *Ectopic lingual thyroid with a multinodular goiter*. Surgery 2013;153:294-6.
- 6 Thomas G, Hoilat R, Daniels JS, et al. *Ectopic lingual thyroid: a case report*. Int J Oral Maxillofac Surg 2003;32:219-21.
- 7 Lee CC, Chen CY, Chen FH, et al. *Imaging of huge lingual thyroid gland with goitre*. Neuroradiology 1998;40:335-7.
- 8 Giovagnorio F, Cordier A, Romeo R. *Lingual thyroid: value of integrated imaging*. Eur Radiol 1996;6:105-7.

- <sup>9</sup> Terris DJ, Seybt MW, Vaughters RB III. *A new minimally invasive lingual thyroidectomy technique*. *Thyroid* 2010;20:1367-9.
- <sup>10</sup> Vairaktaris E, Semergidis T, Christopoulou P, et al. *Lingual thyroid: a new surgical approach – a case report*. *J Cranio-maxillofac Surg* 1994;22:307-10.
- <sup>11</sup> Wu ZX, Zheng LW, Dong YJ, et al. *Modified approach for lingual thyroid transposition: report of two cases*. *Thyroid* 2008;18:465-8.
- <sup>12</sup> Atiyeh BS, Abdelnour A, Haddad FF, et al. *Lingual thyroid: tongue-splitting incision for transoral excision*. *J Laryngol Otol* 1995;109:520-4.
- <sup>13</sup> Zitsman JL, Lala VR, Rao PM. *Combined cervical and intraoral approach to lingual thyroid: a case report*. *Head Neck* 1998;20:79-82.
- <sup>14</sup> Hafidh MA, Sheahan P, Khan NA, et al. *Role of CO<sub>2</sub> laser in the management of obstructive ectopic lingual thyroids*. *J Laryngol Otol* 2004;118:807-9.
- <sup>15</sup> Dallan I, Castelnuovo P, Vicini C, et al. *The natural evolution of endoscopic approaches in skull base surgery: robotic-assisted suegrey?* *Acta Otorhinolaryngol Ital* 2011;31:390-4.
- <sup>16</sup> Mercante G, Ruscito P, Pellini R, et al. *Transoral robotic surgery (TORS) for tongue base tumours*. *Acta Otorhinolaryngol Ital* 2013;33:230-5.

Received: November 3, 2012 - Accepted: March 6, 2013

Address for correspondence: Giuseppe Mercante, Department of Otolaryngology, Head and Neck Surgery, "Regina Elena" National Cancer Institute, via Elio Chianesi 53, 00144 Rome, Italy. Tel. +39 06 52666770. Fax +39 06 52662015. E-mail: mercante.giuseppe@gmail.com