

# Current and emerging treatment options for Peyronie's disease

Ahmet Gokce  
Julie C Wang  
Mary K Powers  
Wayne JG Hellstrom

Department of Urology,  
Tulane University – School of  
Medicine, New Orleans, LA, USA

**Abstract:** Peyronie's disease (PD) is a condition of the penis, characterized by the presence of localized fibrotic plaque in the tunica albuginea. PD is not an uncommon disorder, with recent epidemiologic studies documenting a prevalence of 3–9% of adult men affected. The actual prevalence of PD may be even higher. It is often associated with penile pain, anatomical deformities in the erect penis, and difficulty with intromission. As the definitive pathophysiology of PD has not been completely elucidated, further basic research is required to make progress in the understanding of this enigmatic condition. Similarly, research on effective therapies is limited. Currently, nonsurgical treatments are used for those men who are in the acute stage of PD, whereas surgical options are reserved for men with established PD who cannot successfully penetrate. Intralesional treatments are growing in clinical popularity as a minimally invasive approach in the initial treatment of PD. A surgical approach should be considered when men with PD do not respond to conservative, medical, or minimally invasive therapies for approximately 1 year and cannot have satisfactory sexual intercourse. As scientific breakthroughs in the understanding of the mechanisms of this disease process evolve, novel treatments for the many men suffering with PD are anticipated.

**Keywords:** oral therapy, intralesional treatment, topical therapy, extracorporeal shockwave therapy, traction devices, plication, incision and grafting, penile prosthesis.

## Introduction

Peyronie's disease (induratio penis plastica; PD) is a condition of the penis, characterized by the presence of localized fibrotic plaques in the tunica albuginea and affecting 3.2–8.9% of the adult male population.<sup>1–3</sup> The true prevalence of PD may be even higher as many patients are reluctant to discuss their condition with a physician or may not seek medical help if the symptoms are not disabling.<sup>4</sup> At present, most authorities support the hypothesis that PD generally arises from repetitive (micro)trauma to the erect penis during sexual activities. However, not all penile trauma leads to the development of PD. Abnormal wound healing appears to be more common in men with PD and there is evidence for a genetic predisposition.<sup>5</sup> Furthermore, studies have shown that risk factors for atherosclerosis and endothelial dysfunction such as hypertension, dyslipidemia, diabetes mellitus, and smoking are more common in men with PD.<sup>6–8</sup>

The underlying etiology of PD appears to be an imbalance between profibrotic and antifibrotic substances. Profibrotic substances include transforming growth factor  $\beta$ -1 (TGF- $\beta$ 1), fibrin, plasminogen activator inhibitor-1, and tissue inhibitors of metalloproteinases, and are found to be overexpressed or aberrantly expressed.<sup>9</sup> Antifibrotic substances include matrix metalloproteinases, which are a class of molecules responsible

---

Correspondence: Wayne JG Hellstrom  
Tulane University Health Sciences  
Center, 1430 Tulane Avenue,  
SL-42 New Orleans, LA, USA  
Tel +1 504 988 5372  
Fax +1 504 988 5059  
Email [whellst@tulane.edu](mailto:whellst@tulane.edu)

for collagen degradation.<sup>10</sup> The wound healing cascade begins with exposure of platelets to collagen and the release of chemoattractant molecules such as TGF- $\beta$ 1, platelet-derived growth factor, tumor necrosis factor- $\alpha$ , interleukin-1, and fibrin, which act as a matrix for repair.<sup>9</sup> Inhibition of the fibrinolytic system or an inability to degrade the intravasated fibrin leads to its persistence in the tunica and continues to exert a proinflammatory response.<sup>11</sup> This response ultimately leads to the formation of a palpable plaque secondary to the excessive deposition of collagen and extracellular matrix, with disorganization of collagen fibers and loss of elastic fibers.<sup>11</sup> There are other theories on plaque formation which include cytokine and/or growth factor overexpression and free radical production.<sup>12</sup>

PD usually presents in men aged 40–70 years and has two phases. The acute phase, lasting for 6–18 months, is often characterized by the development of penile curvature and onset of pain with erection. The acute phase is followed by a chronic phase, characterized by negligible penile pain, and the establishment of a stable penile abnormality.<sup>6</sup> Patients presenting with PD can exhibit any single or combination of penile plaque, curvature, pain, and erectile dysfunction (ED). Plaques are typically located on the dorsal or lateral aspect of the penis, causing an upward or lateral deflection during erection. As many patients are embarrassed by or unaware of their PD, they are unlikely to mention the topic unless specifically questioned by a treating physician.<sup>13</sup> PD is generally a progressive disorder that uncommonly resolves completely. It is difficult to predict an individual's prognosis at the initiation of the disease. Only penile pain, if present, resolves spontaneously within the first year in the majority of patients.<sup>14</sup> In most circumstances, PD progressively worsens over time, as reported in 48% of men with PD in a recent study.<sup>15</sup> Two-thirds of patients with PD are likely to have risk factors for arterial disease and therefore will develop ED over the long term.<sup>8</sup> Treatment options are chosen based upon disease severity, patient preference, and surgeon's training. Options include oral medications, intralesional injection therapy, plication procedures, incision and grafting, and placement of a penile prosthesis with or without manual modeling or other ancillary straightening techniques.<sup>2</sup>

## Nonsurgical treatment of PD

Numerous nonsurgical treatment options have been utilized since PD was first descriptively named in 1743. The majority of studies evaluating oral medications lack controls or an adequate number of subjects, are of short duration, and focus on reduction of deformity as the critical measurement

of outcome.<sup>16</sup> Despite various reports in the literature of deformity stabilization and/or reduction outcomes, recent guidelines indicate that the available evidence shows generally no significant benefit from oral therapies for reducing penile deformity.<sup>16,17</sup> However, the standard of care still involves an initial trial of either oral or intralesional treatment at first presentation.<sup>13</sup> An accepted goal of medical therapy is to shorten the acute phase of PD in order to stabilize the plaque or diminish disease progression.<sup>18</sup>

## Oral therapy

### Vitamin E (tocopherol)

Vitamin E is a fat soluble natural antioxidant that theoretically plays a role in DNA repair.<sup>13</sup> Its antioxidant properties have been hypothesized to inhibit nitric oxide synthesis as well as oxygen free radical-induced fibrosis in human cavernosal cells.<sup>19</sup> Despite double-blind, placebo-controlled, randomized studies showing no significant improvement, tocopherol remains the most common nonsurgical therapy because of its safety, availability, and low cost.<sup>20,21</sup>

### Potassium para-aminobenzoate (Potaba<sup>®</sup>)

Potassium para-aminobenzoate was first introduced in 1959 as an oral therapy for PD after it was shown to decrease collagen production in vitro when added to fibroblast cells.<sup>22</sup> Its hypothesized mechanism of action involves the enhancement of three endogenous antifibrotic processes: oxygen uptake, glycosaminoglycan secretion, and monoamine oxidase activity.<sup>23</sup> Two double-blind, placebo-controlled, randomized studies evaluating the efficacy of Potaba have been published. Shah et al in 1983 reported improvement of symptoms, particularly pain, when compared to placebo; however, these findings were not statistically significant.<sup>24</sup> In a more recent study in 2005, Weidner et al published results that demonstrated significant stabilization of preexisting penile deviation and reduction of plaque size, but no significant reduction of pain or preexisting curvature.<sup>25</sup> Potaba is currently a first-line therapy for PD because of its tolerability and availability.<sup>23</sup>

### Colchicine

The mechanism of action of colchicine remains unknown but it is hypothesized to reduce lactic acid production, which decreases uric acid deposition and decrease collagen synthesis.<sup>13</sup> Akkus et al demonstrated a reduction in plaque size, degree of curvature, and pain symptoms in response to colchicine therapy.<sup>26</sup> In another uncontrolled study, Kadioglu et al demonstrated that the efficacy of colchicine increases when used in specified patient groups without any vascular

disease risk factors, presenting in the first 6 months of disease, a degree of curvature less than 30 degrees, and without ED.<sup>27</sup> A recent nonrandomized study demonstrated that using tocopherol with colchicine in the early stages of PD reduced plaque size, curvature, and pain.<sup>28</sup> A recent study by Akman et al retrospectively evaluated patients that were treated with colchicine in the acute phase of PD. They found that the predictive factors for curvature alterations in PD patients were mild deformities mainly in those with lateral curvature, which mostly shifted to the dorsal side after treatment.<sup>29</sup> However, another double-blind placebo-controlled study by Safarinejad demonstrated no difference in pain relief, plaque size, or penile curvature.<sup>30</sup> Further studies are necessary to clarify the beneficial effects of colchicine in the treatment of PD. The side effects include nausea, vomiting, and diarrhea.<sup>13</sup>

### Tamoxifen

Tamoxifen is a nonsteroidal antiestrogen. Its mechanism of action is unknown but it is hypothesized to modulate TGF- $\beta$ 1, which reduces fibrosis.<sup>13</sup> Two uncontrolled studies, Apaydin et al in 1998<sup>31</sup> and Ralph et al in 1992,<sup>32</sup> reported a decrease of plaque size, penile deviation, and pain. However the results of a double-blind, placebo-controlled randomized study done by Teloken et al reported that the effect on curvature, plaque size, and pain was not significant.<sup>33</sup> In the absence of a demonstrable benefit, this drug is not routinely recommended for the treatment of PD.

### L-carnitine

L-carnitine's mechanism of action is not fully understood but it is hypothesized to increase mitochondrial respiration, which decreases free radical formation.<sup>34</sup> Biagiotti and Cavallini performed a double-blind, randomized study in 2001 that compared acetyl-L-carnitine with tamoxifen, which was previously shown to have no benefit over placebo, and demonstrated that acetyl-L-carnitine was more effective in reducing pain and disease progression.<sup>35</sup> Cavallini et al in 2002 compared the efficacy of oral propionyl-L-carnitine or tamoxifen combined with intralesional verapamil injections. They demonstrated that the combination of propionyl-L-carnitine and verapamil was efficacious and suggested it as the treatment of choice for advanced PD.<sup>36</sup> Another double-blind, placebo-controlled, randomized study by Safarinejad et al in 2007 found that oral propionyl-L-carnitine treatment was not superior to placebo.<sup>20</sup> It is possible that an insufficient dose of this agent was used in light of a recent review suggesting that the minimum dose necessary for an effect was at least 3–3.5 g per day.<sup>37</sup> The drug has a relatively safe

profile, with reported side effects of mild euphoria and gastrointestinal upset.<sup>34</sup>

### Pentoxifylline

Pentoxifylline is a nonspecific phosphodiesterase inhibitor with a hypothesized mechanism of action of upregulating cyclic adenosine monophosphate and decreasing type I collagen production, which remedies the abnormal collagen phenomenon.<sup>34</sup> Valente et al in 2003 collected data from in vivo and in vitro models that demonstrated decreased levels of profibrotic factors and plaque size after treatment with pentoxifylline.<sup>38</sup> Other studies document that pentoxifylline reduced calcium content in the plaque and collagen fiber deposition and altered elastogenesis by antagonizing the effects of TGF- $\beta$ 1.<sup>39–41</sup> Safarinejad et al conducted a double-blind, placebo-controlled, randomized study that reported a significant effect of pentoxifylline therapy on reducing penile curvature and plaque volume particularly in patients in the early stages of established PD.<sup>42</sup> These somewhat promising results with pentoxifylline need further confirmation. This drug is associated with relatively mild side effects, most commonly nausea, dizziness, and headache.<sup>34</sup>

### Phosphodiesterase type 5 (PDE5) inhibitors

PDE5 inhibitors have been shown to decrease oxidative stress-associated inflammatory changes, as observed in the pathophysiology of PD. Its mechanism of action results in an increase of cavernosal smooth muscle levels of cyclic guanosine monophosphate. PDE5 inhibitors, when given continuously over long periods, induce an elevation of nitric oxide and cyclic guanosine monophosphate which act as antifibrotic agents to reduce collagen deposition, profibrotic factor release, oxidative stress, and myofibroblast numbers.<sup>11</sup> Levine and Latchamsetty demonstrated that sildenafil was a safe, effective, and well-tolerated first-line therapy for PD patients with ED.<sup>43</sup> In another study by Levine et al, sildenafil reduced the incidence of postoperative ED in patients who underwent surgical correction of PD using pericardial grafting after plaque incision. However these results were not statistically significant.<sup>44</sup> Valente et al performed a study in a rat model with a PD-like plaque induced by TGF- $\beta$ 1, demonstrating that sildenafil caused a reduction in plaque size.<sup>38</sup> Ferrini et al performed a similar rat model study with a PD-like plaque elicited by TGF- $\beta$ 1 or fibrin injection into the tunica albuginea. Long-term oral treatment with vardenafil slowed and reversed the early stages of the PD-like plaque in this rat model.<sup>45</sup> Chung et al reported septal scar resolution and improved International Index of Erectile Function-5

questionnaire symptom scores in a study with low-dose daily tadalafil.<sup>46</sup> Palmieri et al concluded that extracorporeal shockwave therapy (ESWT) in addition to 5 mg of tadalafil once daily produced significant improvement in erectile function and quality of life for patients with PD and ED.<sup>47</sup> Further studies are mandated before any of these methods of treatment can be recommended.

The oral pharmacotherapies as evaluated by randomized controlled trials are summarized in Table 1.

## Intralesional injection therapy

### Corticosteroids

The mechanism of action of corticosteroids was hypothesized to inhibit phospholipase A2 and suppress immune response.<sup>48</sup> Historically, the first documented use of intralesional corticosteroids for PD was reported by Bodner et al in 1954, which noted a decrease in plaque size and penile pain following therapy.<sup>49</sup> Follow-up studies demonstrated that corticosteroid injections had no therapeutic benefit,<sup>50,51</sup> as seen in the single-blinded, placebo-controlled, randomized study performed by Cipollone et al in 1998, which showed no statistically significant benefit.<sup>52</sup> Lack of evidence for benefit and side effects such as local tissue atrophy, fibrosis, and immune suppression currently limit the clinical use of this option. Therefore corticosteroid injections are not currently recommended as an intralesional therapy for PD.<sup>23</sup>

### Collagenase

Collagenase, also classified as specific matrix metalloproteinase-1, 8, and 13, degrades interstitial collagens, specifically type II collagen.<sup>13</sup> The therapeutic potential of collagenase was initially introduced more than two decades ago in both in vitro and in vivo studies by Gelbard et al.<sup>53,54</sup> These researchers utilized highly purified clostridial collagenases to test their effect on various human tissues in vitro, including human pericardium, human corpus cavernosum,

tunica albuginea, and PD plaques. These experiments with collagenase resulted in a remarkable reduction in the size of the PD plaque, along with microscopic fraying and dispersal of collagen bundles, when compared with plaques injected with normal saline. Moreover, elastic fibers, vascular smooth muscle, and axonal myelin sheaths were not affected by collagenase application.<sup>53</sup> In the following period, the investigators performed an in vivo pilot study that injected intralesional collagenase in 31 men with PD.<sup>54</sup> After 4 weeks of treatment, 65% of patients exhibited objective improvement, 93% reported elimination of pain, and intercourse was restored in 75% of patients. Additionally, the researchers noted that penile plaques were either significantly altered or disappeared in four patients and reduced by 20%–100% in 16 others. Studies have reported that immunoglobulin G antibodies to collagenase were higher in men with PD versus healthy men, implying that intralesional collagenase has a documented benefit.<sup>55</sup> A double-blind, placebo-controlled, randomized study demonstrated a significant response with collagenase injections in patients with small plaques and minor penile deformity.<sup>56</sup> Although not placebo-controlled, a recent study employing two intralesional collagenase injections within 24–72 hours over three injection cycles demonstrated improvement with decreases in both plaque size and penile curvature in men with PD.<sup>57</sup> Collagenase can be used in both the acute and chronic phases of PD. Because of its potential efficacy, intralesional collagenase has just completed phase III clinical trials in men with PD. Collagenase is associated with minimal adverse side effects such as injection site pain, ecchymosis, and rarely corporal rupture.<sup>13,23</sup>

### Verapamil

Verapamil is a calcium channel antagonist that augments collagenase activity, increases cytokine expression associated with early inflammation and wound formation, and inhibits in vitro fibroblast proliferation in PD plaques.<sup>58,59</sup> Levine et al in 1994 reported that intralesional verapamil injection resulted

**Table 1** Efficacy of oral therapy evaluated by randomized trials

Treatment	Study	Mode of study	Effect
Vitamin E (tocopherol)	Safarinejad et al <sup>20</sup>	Placebo-controlled, double-blind	No significant difference
Potaba®	Shah et al <sup>24</sup>	Placebo-controlled, double-blind	No significant difference
	Weidner et al <sup>25</sup>	Placebo-controlled, double-blind	Decreased plaque size in treatment arm
Colchicine	Safarinejad <sup>30</sup>	Placebo-controlled, double-blind	No significant difference
Tamoxifen	Teloken et al <sup>33</sup>	Placebo-controlled, double-blind	No significant difference
L-carnitine	Biagiotti and Cavallini <sup>35</sup>	Double-blind	Decreased plaque size, curvature, and penile pain
Pentoxifylline	Safarinejad et al <sup>42</sup>	Placebo-controlled, double-blind	Decreased penile curvature and plaque volume in early chronic Peyronie's disease

in a significant reduction in penile curvature.<sup>60</sup> Additional uncontrolled studies have reported a decrease in penile pain, curvature, deformity, an increase in girth and rigidity, improved erectile function, and subjective softening of the plaque.<sup>61,62</sup> Rehman et al performed the only randomized placebo-controlled study in 1998 with verapamil injection therapy and demonstrated that there was no statistically significant change in penile curvature reduction.<sup>63</sup> Because only one study evaluating the efficacy of verapamil included a placebo arm, more controlled studies are required. Verapamil remains a relatively safe and inexpensive form of therapy with minor adverse effects such as nausea, lightheadedness, penile pain, and ecchymosis.<sup>23</sup>

### Interferons

Interferons are cytokines that play a regulatory role in the inflammatory response of the immune system. Interferon- $\alpha$ -2b inhibits the proliferation of fibroblasts, increases collagenase activity, decreases collagen production, and has been used in a number of studies for intralesional injection treatment of PD.<sup>18</sup> Initial *in vitro* studies demonstrated the inhibitory role of interferon- $\alpha$  and interferon- $\beta$  on collagen production in fibroblasts derived from Peyronie's plaques.<sup>64</sup> Since then, several studies confirmed the beneficial effect in men with PD.<sup>65-68</sup> Two single-blind, placebo-controlled studies showed a statistically significant benefit of interferon- $\alpha$ -2b with improvements in penile curvature, plaque size and density, penile pain on erection, erectile function, and penile hemodynamics. This therapy is associated with minor side effects such as sinusitis, minor penile swelling with ecchymosis, and flu-like symptoms of fever, chills, and arthralgia.<sup>69,70</sup> The use of over-the-counter anti-inflammatory agents prior to intralesional injection can abrogate the flu-like such effect.

Randomized controlled intralesional therapy studies are summarized in Table 2.

### Topical therapy and iontophoresis

Aminopropionitrile, hydrocortisone, and verapamil are topical medications with varying results in the treatment of PD.<sup>71-74</sup> Iontophoresis is the utilization of electrokinetic

transport of charged molecules for the enhancement of transdermal drug delivery to diseased tissue, particularly plaques in PD.<sup>75</sup> Martin et al demonstrated that topically administered verapamil gel was not present in the tunica albuginea at excisional surgery the next day,<sup>73</sup> but was detected to a small degree in PD plaques after iontophoresis.<sup>76</sup> In spite of initial successful reports with iontophoresis of dexamethasone and verapamil,<sup>77-79</sup> recent double-blind placebo-controlled randomized trials failed to demonstrate statistically significant improvements in penile curvature. Greenfield et al suggest iontophoresis in patients whose major complaint is pain or those who have mild penile curvature and do not wish to undergo intralesional therapy or surgical correction of their penile curvature.<sup>80</sup>

### Extracorporeal shockwave therapy (ESWT)

Penile ESWT has been proposed as a possible nonsurgical PD treatment, but few reports have reported any beneficial effects.<sup>81,82</sup> Most studies did not observe any significant improvement in penile curvature.<sup>83-85</sup> An exploratory meta-analysis in 2004 by Hauck et al did not reveal any significant benefits of ESWT on improvement of penile curvature or plaque size.<sup>86</sup> Two double-blind, placebo-controlled, randomized trials have been published. Chitale et al did not observe any significant benefit of ESWT on PD.<sup>87</sup> Palmieri et al demonstrated that ESWT appears to expedite pain resolution compared to the natural course of the disease.<sup>88</sup> Currently, ESWT is not recommended as a treatment for PD because it has not been shown to improve or even stabilize the plaque or penile curvature.<sup>89</sup>

### Penile traction devices

Gradual expansion of tunica tissue by traction exerted by a penile extender device induces new connective tissue formation.<sup>90</sup> Preliminary studies conducted by Levine et al and Gontero et al have demonstrated nonsignificant curvature reduction and increased penile length.<sup>91,92</sup> Further long-term controlled studies are necessary. Raheem et al suggested that

**Table 2** Efficacy of intralesional therapy evaluated by randomized trials

Treatment	Study	Mode of study	Effect
Corticosteroids	Cipollone et al <sup>52</sup>	Placebo-controlled, single-blind	No significant difference between treatment and placebo
Collagenase	Gelbard et al <sup>56</sup>	Placebo-controlled, double-blind	Decreased curvature and plaque size
Verapamil	Rehman et al <sup>63</sup>	Placebo-controlled, single-blind	No significant difference between treatment and placebo
Interferons	Judge et al <sup>69</sup>	Placebo-controlled, single-blind	Significant improvement in penile curvature, plaque size, penile pain, and erectile function
	Hellstrom et al <sup>70</sup>	Placebo-controlled, single-blind	

vacuum pump therapy may have similar effects on improving penile curvature and pain symptoms.<sup>93</sup>

## Surgical options for PD

The ideal candidate for surgical intervention for PD is a patient whose plaque has stabilized (normally at least 12 months since diagnosis) and penile curvature prevents satisfactory sexual intercourse. Attempts at medical management are attempted initially but, with more severe curvature – normally greater than 60 degrees – surgery may be considered as a primary treatment. Concomitant ED is always evaluated when deciding on surgical options for patients with severe PD.<sup>94</sup>

A proposed treatment algorithm for PD is provided in Figure 1.

## Penile plication

For a patient with less severe penile curvature, one option includes shortening the side directly opposite to the curvature to equalize in length both sides of the penis. The ideal candidate for this is a man with adequate penile length, curvature less than 60 degrees, good preoperative erectile function, and no hourglass defect.<sup>95</sup> In one study, patients underwent penile plication and greater than 80% of participants agreed that their residual curvature was decreased to less than

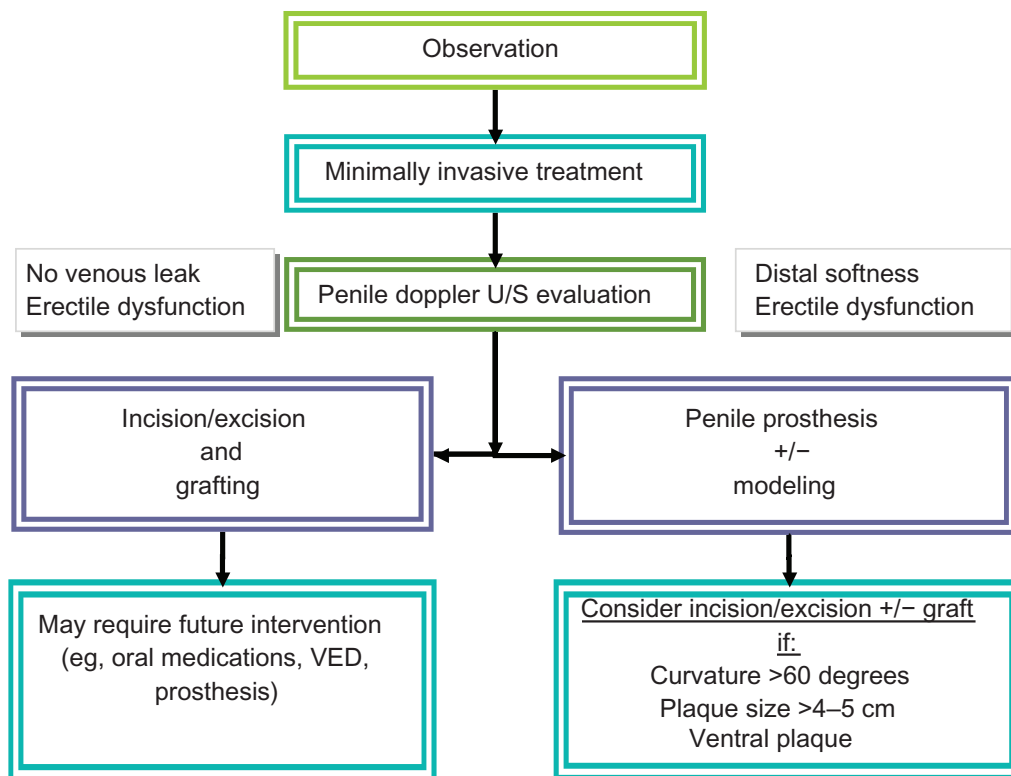
20 degrees and their rigidity was equivalent or better than before the procedure. The intuitive common complaint with this procedure is loss of penile length. Such men had their penile length measured before and after the procedure, with a surprising overall length change of +0.6 cm.<sup>96</sup>

Tunica albuginea plication can be performed using a variety of techniques. The Yachia procedure involves degloving the penis and making a longitudinal incision in the tunica albuginea opposite the plaque.<sup>97</sup> The edges are then brought together horizontally using sutures which shorten the unaffected side and overall straightening of the penis.<sup>98</sup> The Essed–Schroeder technique doesn't involve entry or violation of the venoocclusive mechanism; instead sutures are placed in the tunica albuginea and tightened to effectively plicate and straighten the penis.<sup>97,99</sup> Overall, success rates of plication procedures range from 70%–100% with rates of patient satisfaction typically over 80%.<sup>96,100–109</sup>

Data published about plication techniques are summarized in Table 3.

## Incision and grafting procedures

A more invasive approach involves incising the plaque to release penile curvature and using a graft to augment the missing tunica albuginea. Patients with extensive curvature



**Figure 1** Algorithm for treatment of Peyronie's disease.

**Abbreviations:** U/S, ultrasound; VED, vacuum erection device.

**Table 3** Data published on plication techniques

Author	Date of Publication	Patient #	Procedure Type	% Straight	% with ED	Diminished Sensation%	Mean follow up duration (months)
Ralph et al <sup>103</sup>	1995	359	Nesbit	89	2	2	Not reported
Daitch et al <sup>101</sup>	1999	183	Modified corporoplasty	89	4	Not reported	24.1
Gholami et al <sup>104</sup>	2002	132	I6-dot plication technique	85	3	Not reported	31
Syed et al <sup>105</sup>	2003	50	Nesbit	90	Not reported	21	84
Savoca et al <sup>106</sup>	2004	218	Nesbit	86.3	13	11	89
Rolle et al <sup>107</sup>	2005	50	Nesbit	100	0	Not reported	Not reported
Bella et al <sup>108</sup>	2006	23	Minimally invasive plaque excision	91	Not reported	4	25
Greenfield et al <sup>109</sup>	2006	68	Tunica albuginea plication (modified Nesbit)	99	7.3	4	29
Taylor et al <sup>96</sup>	2008	90	Tunica plication	93	12	36	72

(greater than 60 degrees), multiple areas of plaque, or those without adequate penile length are candidates for incision and grafting. Similar to penile plication, the penis is degloved exposing Buck's fascia. The fascia is then entered, avoiding the dorsally located neurovascular bundles. Peyronie's plaques have a firm texture due to fibrotic changes and can be easily distinguished from the surrounding tunica albuginea. An artificial erection is induced and over the area of the plaque a Y-type or H-type incision is made for tunical release. The tunical defect is then measured and a graft is constructed 10% larger to accommodate possible graft contracture during the healing process.<sup>110</sup> The graft is sutured into the defect in a watertight manner and Buck's fascia is then reapproximated. A final artificial erection is induced to assess for potential vascular leakage. The circumcision is closed in a routine fashion with a mild compression dressing. Most procedures are done on an outpatient basis.

Postoperatively, patients may be advised to use a penile stretching device on a daily basis, possibly with oral medications such as a low-dose PDE5 inhibitor.<sup>13,91,111</sup> The use of a PDE5 inhibitor hypothetically increases penile blood flow. Patient satisfaction ranges from 35%–75% with the main complaints postoperatively being decreased penile length and new onset ED.<sup>95</sup>

The type of graft used often depends on the surgeon's preference. Saphenous vein, buccal mucosa, acellular porcine dermal matrix, pericardium, and small intestine submucosa are just some of the many available grafts. Buccal mucosa exhibits good elasticity but concerns about oral numbness and mouth tightness demand more long-term follow-up with this approach.<sup>95,112</sup> Small intestine submucosa contains collagen, fibroblast growth factor, and fibronectin,

which are vital in the healing process.<sup>113–114</sup> Recurrence (up to 33% within 3 months), hematoma, infection, and penile shortening have brought this graft material into question.<sup>115</sup> Preputial dermal flaps were initially promising but high recurrence, presence of inclusion cysts, and poor patient satisfaction have since been reported.<sup>116</sup> Pericardial grafts have the benefit of not requiring a harvest site and exhibit substantial tensile strength.<sup>117</sup> The pericardium acts as a scaffold that tunica albuginea grows into and with time the graft is enzymatically dissolved.<sup>118</sup>

## Penile prosthesis implantation

Because PD is often associated with ED, preoperative penile vascular studies using color duplex Doppler ultrasound is recommended.<sup>94,110</sup> If a venous leak is identified it is suggested that a PDE5 inhibitor be tried prior to penile prosthesis placement.<sup>13</sup> In one study, up to 61% of patients with venous leak responded to oral drugs, changing the need for an inflatable penile prosthesis.<sup>119</sup> Penile prosthesis has the advantage of both straightening the curvature and providing patients with ED a functional erection. Both malleable and inflatable devices can be used, however higher satisfaction rates are achieved with the inflatable version. The success rate of penile straightening using penile prosthesis for patients with concomitant PD is higher if the curvature is less than 30 degrees. In men with more severe penile curvatures, incision and grafting or plication procedures may be necessary with simultaneous placement of an inflatable penile prosthesis. When comparing inflatable penile prosthesis to incision and grafting, postoperative erectile function domain scores were significantly higher for patients who had undergone inflatable penile prosthesis implantation. While

this approach to surgery offers very good outcomes, there are also still risks that need to be fully discussed with the patient. These include infection, device malfunction, repeat operation, and erosion complications.<sup>120</sup>

In patients with minimal curvature (less than 30 degrees), placement of the prosthesis alone results in penile straightening by acting as a tissue expander and softening the plaque over time. Commonly, manual modeling is used in combination with a penile prosthesis to correct mild to moderate curvatures.<sup>120</sup> Once the prosthesis is inserted, the device is inflated and the surgeon can assess the degree of penile straightening. When the device alone cannot straighten the penis, force is applied to bend the penis in the direction opposite to the curvature.<sup>117</sup> This helps to stretch or fracture the plaque and straighten the penis. The success rate with the modeling technique is very high.<sup>121</sup> In patients with bottleneck deformities or with severe curvature (greater than 60 degrees), manual modeling alone is less likely to be effective; in such cases incision in the plaque with or without grafting can be performed as previously described.<sup>117</sup>

## Conclusion

PD is not an uncommon disorder, with recent epidemiologic studies documenting a prevalence of 3–9% of adult men affected. The actual prevalence of PD may be even higher. As the definitive pathophysiology of PD has not been completely elucidated, further basic research is required to make progress in the understanding of this enigmatic condition. Currently, nonsurgical treatments are used for those men who are in the acute stage of PD, whereas surgical options are reserved for men with established PD who cannot successfully penetrate. Future oral treatment options may be directed toward increasing tissue expression of matrix metalloproteinases or inhibition of tissue inhibitors of metalloproteinase activity. This area of research will evolve rapidly as the molecular mechanisms underlying PD are further elucidated. Intralesional treatments are growing in clinical popularity as a minimally invasive approach for the initial treatment of PD. Surgical approaches are considered only when men with PD do not respond to medical or minimally invasive therapies for at least 1 year and when patients cannot have satisfactory sexual intercourse. As scientific breakthroughs in the understanding of the mechanisms of this disease evolve, novel treatments for the many men suffering with PD are anticipated.

## Disclosure

The authors report no conflicts of interest in this work.

## References

- Mulhall JP, Creech SD, Boorjian SA, et al. Subjective and objective analysis of the prevalence of Peyronie's disease in a population of men presenting for prostate cancer screening. *J Urol*. 2004;171:2350–2353.
- Bella AJ, Perelman MA, Brant WO, Lue TF. Peyronie's disease (CME). *J Sex Med*. 2007;4:1527–1538.
- Taylor FL, Levine LA. Peyronie's Disease. *Urol Clin North Am*. 2007;34:517–534.vi.
- Rosen R, Catania J, Lue T, et al. Impact of Peyronie's disease on sexual and psychosocial functioning: qualitative findings in patients and controls. *J Sex Med*. 2008;5:1977–1984.
- Chung E, De Young L, Brock GB. Rat as an animal model for Peyronie's disease research: a review of current methods and the peer-reviewed literature. *Int J Impot Res*. 2011;23:235–241.
- Usta MF, Bivalacqua TJ, Jabren GW, et al. Relationship between the severity of penile curvature and the presence of comorbidities in men with Peyronie's disease. *J Urol*. 2004;171:775–779.
- Bjekic MD, Vlajinac HD, Sipetic SB, Marinkovic JM. Risk factors for Peyronie's disease: a case-control study. *BJU Int*. 2006;97:570–574.
- Kadioglu A, Tefekli A, Erol B, Oktar T, Tunc M, Tellaloglu S. A retrospective review of 307 men with Peyronie's disease. *J Urol*. 2002;168:1075–1079.
- El-Sakka AI, Hassoba HM, Chui RM, Bhatnagar RS, Dahiya R, Lue TF. An animal model of Peyronie's-like condition associated with an increase of transforming growth factor beta mRNA and protein expression. *J Urol*. 1997;158:2284–2290.
- Del Carlo M, Cole AA, Levine LA. Differential calcium independent regulation of matrix metalloproteinases and tissue inhibitors of matrix metalloproteinases by interleukin-1beta and transforming growth factor-beta in Peyronie's plaque fibroblasts. *J Urol*. 2008;179:2447–2455.
- Gonzalez-Cadavid NF, Rajfer J. Treatment of Peyronie's disease with PDE5 inhibitors: an antifibrotic strategy. *Nat Rev Urol*. 2010;7:215–221.
- Lin CS, Lin G, Wang Z, Maddah SA, Lue TF. Upregulation of monocyte chemoattractant protein 1 and effects of transforming growth factor-beta 1 in Peyronie's disease. *Biochem Biophys Res Commun*. 2002;295:1014–1019.
- Hellstrom WJ. Medical management of Peyronie's disease. *J Androl*. 2009;30:397–405.
- Gelbard MK, Dorey F, James K. The natural history of Peyronie's disease. *J Urol*. 1990;144:1376–1379.
- Mulhall JP, Schiff J, Guhring P. An analysis of the natural history of Peyronie's disease. *J Urol*. 2006;175:2115–2118; discussion 2118.
- Ralph D, Gonzalez-Cadavid N, Miron V, et al. The management of Peyronie's disease: evidence-based 2010 guidelines. *J Sex Med*. 2010;7:2359–2374.
- Montorsi F, Adaikan G, Becher E, et al. Summary of the recommendations on sexual dysfunctions in men. *J Sex Med*. 2010;7:3572–3588.
- Gur S, Limin M, Hellstrom WJ. Current status and new developments in Peyronie's disease: medical, minimally invasive and surgical treatment options. *Expert Opin Pharmacother*. 2011;12:931–944.
- Ahuja SK, Sikka SC, Hellstrom WJ. Stimulation of collagen production in an in vitro model for Peyronie's disease. *Int J Impot Res*. 1999;11:207–212.
- Safarinejad MR, Hosseini SY, Kolahi AA. Comparison of vitamin E and propionyl-L-carnitine, separately or in combination, in patients with early chronic Peyronie's disease: a double-blind, placebo controlled, randomized study. *J Urol*. 2007;178:1398–1403; discussion 1403.
- Shindel AW, Bullock TL, Brandes S. Urologist practice patterns in the management of Peyronie's disease: a nationwide survey. *J Sex Med*. 2008;5:954–964.
- Zarafonietis CJ, Horrax TM. Treatment of Peyronie's disease with potassium para-aminobenzoate (potaba). *J Urol*. 1959;81:770–772.
- Trost LW, Gur S, Hellstrom WJ. Pharmacological Management of Peyronie's Disease. *Drugs*. 2007;67:527–545.
- Shah PJR GN, Adib RS, Pryor JP. A multicentre double-blind controlled clinical trial of potassium-paraaminobenzoate (Potaba) in Peyronie's disease. *Prog Reprod Biol Med*. 1983;61–67.



25. Weidner W, Hauck EW, Schnitker J. Potassium paraaminobenzoate (POTABA) in the treatment of Peyronie's disease: a prospective, placebo-controlled, randomized study. *Eur Urol.* 2005;47:530–535; discussion 535–536.
26. Akkus E, Carrier S, Rehman J, Breza J, Kadioglu A, Lue TF. Is colchicine effective in Peyronie's disease? A pilot study. *Urology.* 1994;44:291–295.
27. Kadioglu A, Tefekli A, Koksall T, Usta M, Erol H. Treatment of Peyronie's disease with oral colchicine: long-term results and predictive parameters of successful outcome. *Int J Impot Res.* 2000;12:169–175.
28. Prieto Castro RM, Leva Vallejo ME, Regueiro Lopez JC, et al. Combined treatment with vitamin E and colchicine in the early stages of Peyronie's disease. *BJU Int.* 2003;91:522–524.
29. Akman T, Sanli O, Uluocak N, et al. The most commonly altered type of Peyronie's disease deformity under oral colchicine treatment is lateral curvature that mostly shifts to the dorsal side. *Andrologia.* 2011;43:28–33.
30. Safarinejad MR. Therapeutic effects of colchicine in the management of Peyronie's disease: a randomized double-blind, placebo-controlled study. *Int J Impot Res.* 2004;16:238–243.
31. Apaydin E, Semerci B, Kefi A, Cikili N, Gursan A, Mulazimoglu N. The use of tamoxifen in the treatment of Peyronie's disease. *Int J Impot Res.* 1998;10:S57.
32. Ralph DJ, Brooks MD, Bottazzo GF and Pryor JP. The treatment of Peyronie's disease with tamoxifen. *Br J Urol.* 1992;70:648–651.
33. Teloken C, Rhoden EL, Grazziotin TM, Ros CT, Sogari PR, Souto CA. Tamoxifen versus placebo in the treatment of Peyronie's disease. *J Urol.* 1999;162:2003–2005.
34. Smith JF, Walsh TJ, Lue TF. Peyronie's disease: a critical appraisal of current diagnosis and treatment. *Int J Impot Res.* 2008;20:445–459.
35. Biagiotti G, Cavallini G. Acetyl-L-carnitine vs tamoxifen in the oral therapy of Peyronie's disease: a preliminary report. *BJU Int.* 2001;88:63–67.
36. Cavallini G, Biagiotti G, Koverech A, Vitali G. Oral propionyl-L-carnitine and intraplaque verapamil in the therapy of advanced and resistant Peyronie's disease. *BJU Int.* 2002;89:895–900.
37. Karlic H, Lohninger A. Supplementation of L-carnitine in athletes: does it make sense? *Nutrition.* 2004;20:709–715.
38. Valente EG, Vernet D, Ferrini MG, Qian A, Rajfer J, Gonzalez-Cadavid NF. L-arginine and phosphodiesterase (PDE) inhibitors counteract fibrosis in the Peyronie's fibrotic plaque and related fibroblast cultures. *Nitric Oxide.* 2003;9:229–244.
39. Smith JF, Shindel AW, Huang YC, et al. Pentoxifylline treatment and penile calcifications in men with Peyronie's disease. *Asian J Androl.* 2011;13:322–325.
40. Shindel AW, Lin G, Ning H, et al. Pentoxifylline attenuates transforming growth factor-beta1-stimulated collagen deposition and elastogenesis in human tunica albuginea-derived fibroblasts part 1: impact on extracellular matrix. *J Sex Med.* 2010;7:2077–2085.
41. Lin G, Shindel AW, Banie L, et al. Pentoxifylline attenuates transforming growth factor-beta1-stimulated elastogenesis in human tunica albuginea-derived fibroblasts part 2: Interference in a TGF-beta1/Smad-dependent mechanism and downregulation of AAT1. *J Sex Med.* 2010;7:1787–1797.
42. Safarinejad MR, Asgari MA, Hosseini SY, Dadkhah F. A double-blind placebo-controlled study of the efficacy and safety of pentoxifylline in early chronic Peyronie's disease. *BJU Int.* 2010;106:240–248.
43. Levine LA, Latchamsetty KC. Treatment of erectile dysfunction in patients with Peyronie's disease using sildenafil citrate. *Int J Impot Res.* 2002;14:478–482.
44. Levine LA, Greenfield JM, Estrada CR. Erectile dysfunction following surgical correction of Peyronie's disease and a pilot study of the use of sildenafil citrate rehabilitation for postoperative erectile dysfunction. *J Sex Med.* 2005;2:241–247.
45. Ferrini MG, Kovanez I, Nolazco G, Rajfer J, Gonzalez-Cadavid NF. Effects of long-term vardenafil treatment on the development of fibrotic plaques in a rat model of Peyronie's disease. *BJU Int.* 2006;97:625–633.
46. Chung E, Deyoung L, Brock GB. The role of PDE5 inhibitors in penile septal scar remodeling: assessment of clinical and radiological outcomes. *J Sex Med.* 2011;8:1472–1477.
47. Palmieri A, Imbimbo C, Creta M, Verze P, Fusco F, Miron V. Tadalafil once daily and extracorporeal shock wave therapy in the management of patients with Peyronie's disease and erectile dysfunction: results from a prospective randomized trial. *Int J Androl.* 2011.
48. Tranchant C, Braun S, Warter JM. [Mechanism of action of glucocorticoids: role of lipocortins]. *Rev Neurol (Paris).* 1989;145: 813–818.
49. Bodner H, Howard AH, Kaplan JH. Peyronie's disease: cortisone-hyaluronidase-hydrocortisone therapy. *J Urol.* 1954;72:400–403.
50. Winter CC, Khanna R. Peyronie's disease: results with dermo-jet injection of dexamethasone. *J Urol.* 1975;114:898–900.
51. Williams G, Green NA. The non-surgical treatment of Peyronie's disease. *Br J Urol.* 1980;52:392–395.
52. Cipollone G, Nicolai M, Mastropimiano G, Iantorno R, Longeri D, Tenaglia R. [Betamethasone versus placebo in Peyronie's disease]. *Arch Ital Urol Androl.* 1998;70:165–168.
53. Gelbard MK, Walsh R, Kaufman JJ. Collagenase for Peyronie's disease experimental studies. *Urol Res.* 1982;10:135–140.
54. Gelbard MK, Lindner A, Kaufman JJ. The use of collagenase in the treatment of Peyronie's disease. *J Urol.* 1985;134:280–283.
55. Hamilton RG, Mintz GR, Gelbard MK. Humoral immune responses in Peyronie's disease patients receiving clostridial collagenase therapy. *J Urol.* 1986;135:641–647.
56. Gelbard MK, James K, Riach P, Dorey F. Collagenase versus placebo in the treatment of Peyronie's disease: a double-blind study. *J Urol.* 1993;149:56–58.
57. Jordan GH. The use of intralesional clostridial collagenase injection therapy for Peyronie's disease: a prospective, single-center, non-placebo-controlled study. *J Sex Med.* 2008;5:180–187.
58. Roth M, Eickelberg O, Kohler E, Erne P, Block LH. Ca<sup>2+</sup> channel blockers modulate metabolism of collagens within the extracellular matrix. *Proc Natl Acad Sci USA.* 1996;93:5478–5482.
59. Mulhall JP, Anderson MS, Lubrano T, Shankey TV. Peyronie's disease cell culture models: phenotypic, genotypic and functional analyses. *Int J Impot Res.* 2002;14:397–405.
60. Levine LA, Merrick PF, Lee RC. Intralesional verapamil injection for the treatment of Peyronie's disease. *J Urol.* 1994;151: 1522–1524.
61. Lasser A, Vandenberg TL, Vincent MJ, Hellstrom WJ. Intraplaque verapamil injection for treatment of Peyronie's disease. *J La State Med Soc.* 1998;150:431–434.
62. Levine LA, Goldman KE, Greenfield JM. Experience with intraplaque injection of verapamil for Peyronie's disease. *J Urol.* 2002;168:621–625; discussion 625–626.
63. Rehman J, Benet A, Melman A. Use of intralesional verapamil to dissolve Peyronie's disease plaque: a long-term single-blind study. *Urology.* 1998;51:620–626.
64. Duncan MR, Berman B, Nseyo UO. Regulation of the proliferation and biosynthetic activities of cultured human Peyronie's disease fibroblasts by interferons-alpha, -beta and -gamma. *Scand J Urol Nephrol.* 1991;25:89–94.
65. Polat O, Gul O, Ozbey I, Ozdickici M, Bayraktar Y. Peyronie's disease: intralesional treatment with interferon alpha-2 A and evaluation of the results by magnetic resonance imaging. *Int Urol Nephrol.* 1997;29:465–471.
66. Ahuja S, Bivalacqua TJ, Case J, Vincent M, Sikka SC, Hellstrom WJ. A pilot study demonstrating clinical benefit from intralesional interferon alpha 2B in the treatment of Peyronie's disease. *J Androl.* 1999;20: 444–448.
67. Astorga R, Cantero O, Contreras D, et al. Intralesional recombinant interferon alpha-2b in Peyronie's disease. *Arch Esp Urol.* 2000;53:665–671.
68. Brake M, Loertzer H, Horsch R, Keller H. Treatment of Peyronie's disease with local interferon-alpha 2b. *BJU Int.* 2001;87:654–657.

69. Judge IS, Wisniewski ZS. Intralesional interferon in the treatment of Peyronie's disease: a pilot study. *Br J Urol.* 1997;79:40–42.
70. Hellstrom WJ, Kendirci M, Matern R, et al. Single-blind, multicenter, placebo controlled, parallel study to assess the safety and efficacy of intralesional interferon alpha-2B for minimally invasive treatment for Peyronie's disease. *J Urol.* 2006;176:394–398.
71. Gelbard M, Lindner A, Chvapil M, Kaufman J. Topical beta-aminopropionitrile in the treatment of Peyronie's disease. *J Urol.* 1983;129:746–748.
72. Miller HC, Ardizzone J. Peyronie disease treated with ultrasound and hydrocortisone. *Urology.* 1983;21:584–585.
73. Martin DJ, Badwan K, Parker M, Mulhall JP. Transdermal application of verapamil gel to the penile shaft fails to infiltrate the tunica albuginea. *J Urol.* 2002;168:2483–2485.
74. Fitch W, 3rd, Easterling WJ, Talbert RL, Bordovsky MJ, Mosier M. Topical verapamil HCl, topical trifluoperazine, and topical magnesium sulfate for the treatment of Peyronie's disease--a placebo-controlled pilot study. *J Sex Med.* 2007;4:477–484.
75. Singh J, Maibach HI. Topical iontophoretic drug delivery in vivo: historical development, devices and future perspectives. *Dermatology.* 1993;187:235–238.
76. Levine LA, Estrada CR, Shou W, Cole A. Tunica albuginea tissue analysis after electromotive drug administration. *J Urol.* 2003;169:1775–1778.
77. Riedl CR, Plas E, Engelhardt P, Daha K, Pfluger H. Iontophoresis for treatment of Peyronie's disease. *J Urol.* 2000;163:95–99.
78. Di Stasi SM, Giannantoni A, Stephen RL, Capelli G, Giurioli A, Jannini EA, Vespasiani G. A prospective, randomized study using transdermal electromotive administration of verapamil and dexamethasone for Peyronie's disease. *J Urol.* 2004;171:1605–1608.
79. Di Stasi SM, Giannantoni A, Capelli G, et al. Transdermal electromotive administration of verapamil and dexamethasone for Peyronie's disease. *BJU Int.* 2003;91:825–829.
80. Greenfield JM, Shah SJ, Levine LA. Verapamil versus saline in electromotive drug administration for Peyronie's disease: a double-blind, placebo controlled trial. *J Urol.* 2007;177:972–975.
81. Skolarikos A, Alargof E, Rigas A, Deliveliotis C, Konstantinidis E. Shockwave therapy as first-line treatment for Peyronie's disease: a prospective study. *J Endourol.* 2005;19:11–14.
82. Srirangam SJ, Manikandan R, Hussain J, Collins GN and O'Reilly PH. Long-term results of extracorporeal shockwave therapy for Peyronie's disease. *J Endourol.* 2006;20:880–884.
83. Michel MS, Ptaschnyk T, Musial A, et al. Objective and subjective changes in patients with Peyronie's disease after management with shockwave therapy. *J Endourol.* 2003;17:41–44; discussion 44.
84. Strebel RT SS, Sautter T, Hauri D. Extracorporeal shock wave therapy for Peyronie's disease does not correct penile deformity. *Int J Impot Res.* 2004;16:448–451.
85. Hauck EW, Hauptmann A, Bschiepfer T, Schmelz HU, Altinkilic BM, Weidner W. Questionable efficacy of extracorporeal shock wave therapy for Peyronie's disease: results of a prospective approach. *J Urol.* 2004;171:296–299.
86. Hauck EW, Mueller UO, Bschiepfer T, Schmelz HU, Diemer T, Weidner W. Extracorporeal shock wave therapy for Peyronie's disease: exploratory meta-analysis of clinical trials. *J Urol.* 2004;171:740–745.
87. Chitale S, Morsey M, Swift L, Sethia K. Limited shock wave therapy vs sham treatment in men with Peyronie's disease: results of a prospective randomized controlled double-blind trial. *BJU Int.* 2010;106:1352–1356.
88. Palmieri A, Imbimbo C, Longo N, et al. A first prospective, randomized, double-blind, placebo-controlled clinical trial evaluating extracorporeal shock wave therapy for the treatment of Peyronie's disease. *Eur Urol.* 2009;56:363–369.
89. Hauck EW, Diemer T, Schmelz HU, Weidner W. A critical analysis of non-surgical treatment of Peyronie's disease. *Eur Urol.* 2006;49:987–997.
90. Taylor FL, Levine LA. Non-surgical therapy of Peyronie's disease. *Asian J Androl.* 2008;10:79–87.
91. Levine LA, Newell M, Taylor FL. Penile traction therapy for treatment of Peyronie's disease: a single-center pilot study. *J Sex Med.* 2008;5:1468–1473.
92. Gontero P, Di Marco M, Giubilei G, et al. Use of penile extender device in the treatment of penile curvature as a result of Peyronie's disease. Results of a phase II prospective study. *J Sex Med.* 2009;6:558–566.
93. Raheem AA, Garaffa G, Raheem TA, et al. The role of vacuum pump therapy to mechanically straighten the penis in Peyronie's disease. *BJU Int.* 2010;106:1178–1180.
94. Ralph DJ. Long-term results of the surgical treatment of Peyronie's disease with plaque incision and grafting. *Asian J Androl.* 2011;13:797.
95. Djinovic R. Penile corporoplasty in Peyronie's disease: which technique, which graft? *Curr Opin Urol.* 2011;21:470–477.
96. Taylor FL, Levine LA. Surgical correction of Peyronie's disease via tunica albuginea plication or partial plaque excision with pericardial graft: long-term follow up. *J Sex Med.* 2008;5:2221–2228; discussion 2229–2230.
97. Serefoglul EC, Hellstrom WJ. Treatment of Peyronie's Disease: 2012 Update. *Curr Urol Rep.* 2011;12:444–452.
98. Kadioglu A, Kucukdurmaz F, Sanli O. Current status of the surgical management of Peyronie's disease. *Nat Rev Urol.* 2011;8:95–106.
99. Essed E, Schroeder FH. New surgical treatment for Peyronie disease. *Urology.* 1985;25:582–587.
100. Yachia D. Modified corporoplasty for the treatment of penile curvature. *J Urol.* 1990;143:80–82.
101. Daitch JA, Angermeier KW, Montague DK. Modified corporoplasty for penile curvature: long-term results and patient satisfaction. *J Urol.* 1999;162:2006–2009.
102. Rehman J, Benet A, Minsky LS, Melman A. Results of surgical treatment for abnormal penile curvature: Peyronie's disease and congenital deviation by modified Nesbit plication (tunica shaving and plication). *J Urol.* 1997;157:1288–1291.
103. Ralph DJ, al-Akraa M, Pryor JP. The Nesbit operation for Peyronie's disease: 16-year experience. *J Urol.* 1995;154:1362–1363.
104. Gholami SS, Lue TF. Correction of penile curvature using the 16-dot plication technique: a review of 132 patients. *J Urol.* 2002;167:2066–2069.
105. Syed AH, Abbasi Z, Hargreave TB. Nesbit procedure for disabling Peyronie's curvature: a median follow-up of 84 months. *Urology.* 2003;61:999–1003.
106. Savoca G, Scieri F, Pietropaolo F, Garaffa G, Belgrano E. Straightening corporoplasty for Peyronie's disease: a review of 218 patients with median follow-up of 89 months. *Eur Urol.* 46: 2004;610–614; discussion 613–614.
107. Rolle L, Tamagnone A, Timpano M, Destefanis P, Fiori C, Ceruti C, Fontana D. The Nesbit operation for penile curvature: an easy and effective technical modification. *J Urol.* 2005;173:171–173; discussion 173–174.
108. Bella AJ, Beasley KA, Obied A, Brock GB. Minimally invasive intracorporeal incision of Peyronie's plaque: initial experiences with a new technique. *Urology.* 2006;68:852–857.
109. Greenfield JM, Lucas S, Levine LA. Factors affecting the loss of length associated with tunica albuginea plication for correction of penile curvature. *J Urol.* 175: 2006;175:238–241.
110. Richardson B, Pinsky MR, Hellstrom WJ. Incision and grafting for severe Peyronie's disease (CME). *J Sex Med.* 2009;6:2084–2087; quiz 2088.
111. Moncada-Iribarren IJJ, Martinez-Salamanca JJ, Cabello R, Hernandez C. Managing penile shortening after Peyronie's disease surgery. *J Urol.* 2007;177:252.
112. Dublin N, Stewart LH. Oral complications after buccal mucosal graft harvest for urethroplasty. *BJU Int.* 2004;94:867–869.
113. Santucci RA, Barber TD. Resorbable extracellular matrix grafts in urologic reconstruction. *Int Braz J Urol.* 2005;31:192–203.
114. Sievert KD, Tanagho EA. Organ-specific acellular matrix for reconstruction of the urinary tract. *World J Urol.* 2000;18:19–25.
115. Breyer BN, Brant WO, Garcia MM, Bella AJ, Lue TF. Complications of porcine small intestine submucosa graft for Peyronie's disease. *J Urol.* 2007;177:589–591.

116. Tornehl CK, Carson CC. Surgical alternatives for treating Peyronie's disease. *BJU Int.* 2004;94:774–783.
117. Kendirci M, Hellstrom WJ. Critical analysis of surgery for Peyronie's disease. *Curr Opin Urol.* 2004;14:381–388.
118. Leungwattanakij S, Bivalacqua TJ, Reddy S, Hellstrom WJ. Long-term follow-up on use of pericardial graft in the surgical management of Peyronie's disease. *Int J Impot Res.* 2001;13:183–186
119. Mulhall J, Anderson M, Parker M. A surgical algorithm for men with combined Peyronie's disease and erectile dysfunction: functional and satisfaction outcomes. *J Sex Med.* 2005;2:132–138.
120. Wilson SK, Delk JR 2nd. A new treatment for Peyronie's disease: modeling the penis over an inflatable penile prosthesis. *J Urol.* 1994;152:1121–1123.
121. Wilson SK, Cleves MA, Delk JR, 2nd. Long-term followup of treatment for Peyronie's disease: modeling the penis over an inflatable penile prosthesis. *J Urol.* 2001;165:825–829.

### Research and Reports in Urology

#### Publish your work in this journal

Research and Reports in Urology is an international, peer-reviewed, open access journal publishing original research, reports, editorials, reviews and commentaries on all aspects of adult and pediatric urology in the clinic and laboratory including the following topics: Pathology, pathophysiology of urological disease; Investigation and treatment of

Submit your manuscript here: <http://www.dovepress.com/research-and-reports-in-urology-journal>

urological disease; Pharmacology of drugs used for the treatment of urological disease. The manuscript management system is completely online and includes a very quick and fair peer-review system, which is all easy to use. Visit <http://www.dovepress.com/testimonials.php> to read real quotes from published authors.

Dovepress